

Outcome of Y to V Medial Canthoplasty With Medial Canthal Tendon Plication for the Correction of Blepharophimosis-Ptois-Epicanthus Inversus Syndrome

Molham A Elbakary

Molham A Elbakary, Oculoplasty Unit, Department of Ophthalmology, Faculty of Medicine, Tanta University, Egypt

Correspondence to: Molham A Elbakary, MD, Oculoplasty Unit, Department of Ophthalmology, Faculty of Medicine, Tanta University, Egypt.

Email: melbakary75@yahoo.com

Telephone: +201148282205 Fax: +20403407734

Received: March 22, 2015 Revised: May 12, 2015

Accepted: May 16, 2015

Published online: June 1, 2015

ABSTRACT

AIM: Evaluation of the results of Y to V medial canthoplasty with medial canthal tendon (MCT) plication for the correction of Blepharophimosis-Ptois-Epicanthus inversus Syndrome (BPES).

MATERIALS AND METHODS: Prospective interventional case series which included 15 cases of BPES. Two stages management was used in all cases. The first stage was Y to V medial canthoplasty with MCT plication. 3 months later, ptosis was corrected by bilateral frontalis suspension or maximum levator resection in the more ptotic eyelid in patients with asymmetric ptosis. Data regarding margin reflex distance 1 (MRD1), horizontal palpebral fissure length (HPFL), inner intercanthal distance (IICD), and the ratio of IICD to HPFL were recorded before and after surgery and were statistically analyzed. Post operative IICD/HPFL ratio of 1.5 or less was considered successful outcome.

RESULTS: The mean age of patients was 3.7 ± 0.8 years. According to the postoperative IICD/HPFL, 12 patients (80%) had successful outcome. The preoperative IICD had a mean of 37.6 ± 1.5 mm, which was reduced post operative to a mean of 33.0 ± 2.3 mm. The HPFL improved from preoperative mean 21 ± 1.2 mm to postoperative mean 24.2 ± 1.4 mm. The mean preoperative IICD/HPFL ratio was 1.8 ± 0.2 which was reduced post operative to a mean of 1.37 ± 0.2 . The MRD1 improved from preoperative mean of 1 ± 0.4 mm to 3.6 ± 0.3 mm post operative. The main complication recorded was undercorrection which was observed in 3 patients (20%).

CONCLUSION: The two stages management using simple procedures as Y to V medial canthoplasty with MCT plication followed by frontalis suspension or maximum levator resection yielded satisfactory results in the correction of complicated deformity as BPES.

© 2015 ACT. All rights reserved.

Key words: Blepharophimosis; Medial canthoplasty; MCT plication

Elbakary MA. Outcome of Y to V Medial Canthoplasty With Medial Canthal Tendon Plication for the Correction of Blepharophimosis-Ptois-Epicanthus Inversus Syndrome. *International Journal of Ophthalmic Research* 2015; 1(1): 28-31 Available from: URL: <http://www.ghrnet.org/index.php/ijor/article/view/1148>

INTRODUCTION

Blepharophimosis-ptosis-epicanthus inversus syndrome (BPES) is an uncommon congenital disorder characterized by a narrowed horizontal palpebral aperture, ptosis, epicanthus inversus, and telecanthus. It typically has bilateral features, although not always symmetrical^[1,2]. This syndrome is inherited as an autosomal disease, but also can be manifested as a result of new genetic mutations and sporadic cases without family history of the disease can occur. Several studies confirmed the presence of mutations such as deletion or translocation of the FOXL2 gene, which maps to chromosome 3q21-24^[3,4]. Surgical treatment for BPES is one of the most complex in the field of eyelid surgery due to the presence of multiple deformities. Many surgical techniques have been described to address the epicanthus inversus and accompanying telecanthus including Y to V flaps, the Mustarde technique, the 5-flap technique, medial canthal tendon shortening or plication, and transnasal wiring, and none of them is free from criticism^[5-9]. Some authors recommended that medial canthoplasty should be performed first followed by ptosis correction, while others recommended one stage. Therefore, there is no unanimous consensus on BPES correction with respect to either

staging or choice of surgical techniques^[9-13].

This study was conducted to evaluate the outcome of 2 stages management of BPES using Y to V medial canthoplasty with medial canthal tendon plication followed by frontalis suspension or maximum levator resection.

METHODS

This prospective interventional case series included 15 patients with BPES who underwent corrective surgeries at Oculoplasty unit, Tanta University Eye Hospital. The study adhered to the principles of the declaration of Helsinki, and was approved by the institutional ethical committee. All patients underwent a full ophthalmological evaluation that included visual acuity, ocular motility, slit lamp examination when possible and fundus examination. Margin reflex distance 1 (MRD1) was measured as the distance between the corneal light reflex and upper lid margin centrally in the primary position, horizontal palpebral fissure length (HPFL) was measured from the precise point of contact of the upper with the lower lid medially to the lateral canthus, inner intercanthal distance (IICD) was measured from the precise point of contact of the upper with the lower lid on both sides, and the ratio of IICD to HPFL was calculated. All these measurements were recorded before and after surgery and were statistically analyzed. The first stage was to perform medial canthoplasty using the Y to V technique with medial canthal tendon plication. All procedures were performed under general anesthesia. A Y was marked on the medial canthal skin with the base of the stem in the desired new position of the medial canthus, which was a point half the distance from the pupil center to the midpoint of the nasal bridge. The other point of the stem was marked just nasal to the medial canthus. The incisions were made with a no 15 Bard-Parker blade, and the flaps were undermined with scissors to expose the medial canthal tendon (MCT) (Figure 1). Any dense fibrous tissue or excessive orbicularis muscle between skin and the MCT were removed. The MCT was shortened via plication using 5-0 prolene sutures. The sutures were fixed to the periosteum posterior to the original insertion of the tendon on the frontal process of the maxilla. The subcutaneous tissue of the medial canthus was fixed to the MCT with a 6-0 vicryl suture. The incision was closed with 6-0 prolene sutures, which were removed 7-10 days post operative.

The correction of ptosis was done 3 months later. Fox pentagon frontalis suspension using atehbond 3-0 sutures was used in the majority of cases. Maximum levator resection was used in patients with asymmetric ptosis requiring unilateral surgery.

To compare the preoperative and post operative measurements of HPFL, IICD, IICD/HPFL ratio and MRD1, t-test for paired variables was used. A P less than 0.05 level of probability was considered statistically significant. The ratio between IICD and HPFL normally ranges between 1.0 and 1.2, so post operative result less than 1.3 was considered good. Post operative IICD/HPFL ratio of 1.3-1.5 was considered acceptable, while ratio more than 1.5 was considered poor correction. 3 months after the medial canthoplasty, the parents were asked to evaluate the medial canthal scar on a 3 grades scale, where grade 1 referred to minimally visible scar, grade 2 moderately visible but not annoying scar, and grade 3 which referred to markedly visible disfiguring scar.

RESULTS

The study included 15 patients. Nine were females (60%) and 6 were (40%) males. The age of the patients ranged between 3 and 5

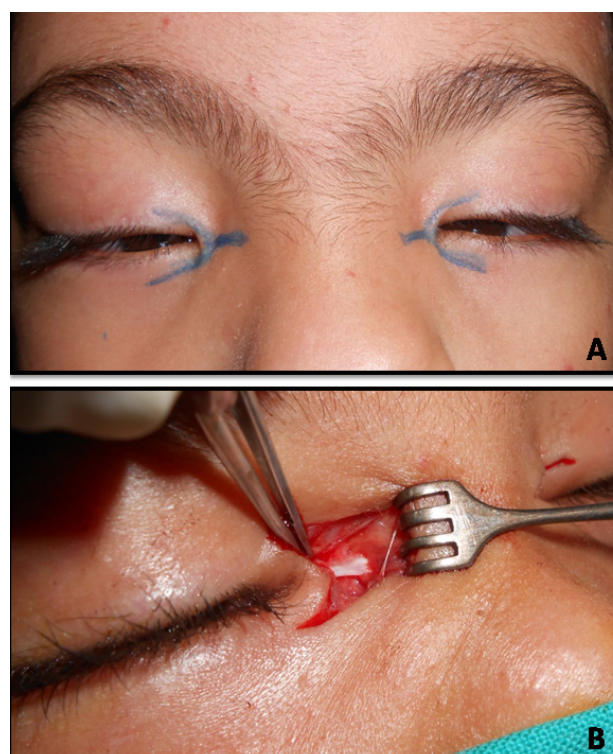


Figure 1 Intra-operative photos of Y to V medial canthoplasty. A) Fashioning of the Y incision. B) Exposure of the medial canthal tendon.

years with a mean 3.7 ± 0.8 years. All the procedures were done under general anesthesia. The first stage was Y to V medial canthoplasty with medial canthal tendon plication. Two patients (13.3%) had moderate ptosis and didn't prefer to undergo 2nd stage surgery for ptosis correction. Three (20%) patients had asymmetric ptosis and were seeking for unilateral ptosis correction in the side with more severe ptosis, which was done by maximum levator resection. In the remaining 10 patients, bilateral frontalis suspension was used for ptosis correction.

All eyelid measurements showed post operative significant improvement. The preoperative IICD ranged between 36 and 40 mm with a mean of 37.6 ± 1.5 mm, which was reduced post operative to range from 30 to 35 mm with a mean of 33.0 ± 2.3 mm ($P = 0.012$). The HPFL improved from preoperative mean 21 ± 1.2 mm (range 19.0 to 22.0 mm) to post operative mean 24.2 ± 1.4 mm (range 22.5 to 26.0 mm) ($P = 0.003$). The range of the preoperative IICD/HPFL ratio was 1.6 to 2.0 with a mean of 1.8 ± 0.2 . This ratio improved post operative to a mean of 1.37 ± 0.2 (range 1.15 to 1.6) ($P = 0.021$). According to the postoperative IICD/HPFL, 12 patients (80%) had successful outcome. Five patients (33.3%) had good results with postoperative IICD/HPFL less than 1.3, while 7 patients (46.7%) had acceptable results with postoperative ratio 1.3-1.5 (fig 2). Lastly, the MRD1 in ptosis operated patients improved from pre operative mean of 1 ± 0.4 mm (range 0.5 to 1.5 mm) to 3.6 ± 0.3 mm post operative (range 3.0 to 4.0 mm).

The main complication recorded was undercorrection which was observed in 3 patients (20%) who had post operative IICD/HPFL ratio greater than 1.5. Although this ratio showed post operative improvement in these patients, it was still away from the normal range. Two patients (13.3%) showed marked visible scarring in the medial canthal region. Other complications as infection, granuloma formation, or lacrimal passages injuries were not recorded.

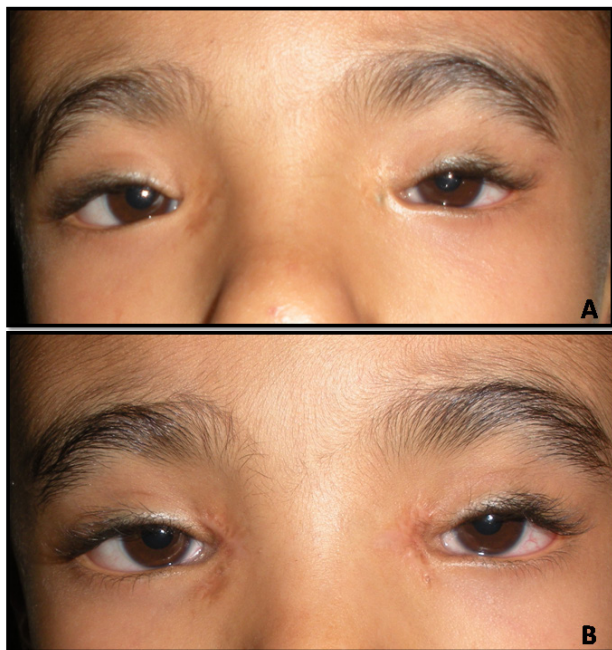

Figure 2 Patient with acceptable result of Y to V medial canthoplasty. A) Pre-operative showing IICD/HPFL ratio 1.9. B) Post-operative after the first stage surgery showing improvement of the IICD/HPFL ratio to 1.5.

DISCUSSION

BPES is an uncommon condition hence it is difficult to study the surgical outcome on large numbers of patients. Patients with BPES undergo multiple periocular operations mostly during childhood. Occasionally these are performed urgently to preserve visual functions, but most are an endeavour to improve patient's facial features^[10]. Correction of BPES is difficult and controversial due to the complexity of the defects, the large number of different techniques employed, and the possibility of using a one stage or a multiple stage procedure^[9]. Many surgeons believe that the epicanthus inversus and telecanthus should be addressed before ptosis surgery because the tension created by the respective surgeries opposes each other. When ptosis correction surgery and medial canthoplasty are performed at the same time, the vertical and horizontal lengths pull against each other. The patients are at high risk for insufficiency or loosening of the medial canthoplasty and poor elevation of the upper eyelid. Therefore, it was advocated that the first stage is to correct epicanthus and telecanthus, then ptosis can be corrected 3-6 months later^[5,8,10,14]. This regimen of two stages surgery was used in this study.

Other surgeons advocated one stage surgical repair of BPES and reported satisfactory results. This approach would decrease the number of total procedures and reduce the time needed for surgical rehabilitation, reducing the health costs and patient/parental discomfort^[9,12,15]. To avoid the tendency for loosening of the medial canthoplasty associated with one stage surgery, Wu et al recommended 4 mm overcorrection of telecanthus using a transnasal wiring procedure, and they also concluded that patients with severe ptosis are not good candidates for one stage procedure^[16].

On the other hand, Beckingsale *et al* recommended to start with ptosis surgery to avoid amblyopia in patients with severe ptosis. They recorded a rate of 39% of amblyopia among patients of their study. But 46% of amblyopia were attributed to strabismus, 9% to astigmatism and 18% to mixed causes^[17]. The risk of developing amblyopia in unilateral ptosis is higher than in bilateral symmetric

ptosis as is found in the majority of BPES patients because in this condition the patient adopts a characteristic elevation of the chin and extension of the neck that seems to diminish the risk of amblyopia development, and consequently the need for early ptosis correction^[9].

The first stage surgery (medial canthoplasty) is performed to eliminate the epicanthal fold and shorten the IICD. It is traditionally recommended to perform it between 3 and 5 years of age. Before 3 years of age the face is not sufficiently developed, and late surgery may result in more prominent scarring^[5,8,18]. The age of the patients in this study ranged between 3 and 5 years with a mean 3.7 ± 0.8 years. Various techniques for the epicanthus correction have been described. One of the most widely used methods is that which was described by Mustarde^[6,19]. Meticulous measurements and mapping out of lines and angles are necessary for this procedure. Some believe that the geometric basis of these flaps is too complicated, and the design is confusing. The transposition of various flaps may be challenging and a significant amount of flap trimming may be required before suturing^[5,7,20]. Sebastia *et al* reported the use of Z-epicanthoplasty which is simpler to perform and yielded results similar to Mustarde flaps^[9]. Sa *et al* used the skin redraping method^[8]. This method was originally described to correct epicanthic folds for cosmetic concerns. It was used to correct epicanthic folds in Asian patients with satisfactory results^[21]. Li *et al* reported better results with the Y to V procedure especially in patients older than 10 years^[5]. The Y to V medial canthoplasty was used in this study and yielded good satisfactory results.

There is also controversy about the correction of telecanthus. Some authors prefer the use of transnasal wiring, the technique which was originally described by Callahan. It provides a more effective traction of the ligaments and better reduction of the intercanthal distance. It's especially beneficial in one stage procedure to avoid the tendency of recurrence. It underwent many modifications including the use of Y shaped titanium miniplates or the use of titanium medial canthal screws. However, it is well known that it's the treatment with more morbidity and is difficult to implement. It has the risk of infection, nasal bleeding, and lacrimal injuries^[9,16,22-24].

A plication of the medial canthal tendon with fixation of the subcutaneous tissue to the canthal tendon seems to be effective in the surgical correction of telecanthus in patients with BPES. The tendon must be sutured as far posteriorly as possible to create a posteriorly directed tension vector. This creates the most natural anatomical reconstruction possible. The use of this procedure by a broader surgical practitioner base with less experience may not be the most appropriate^[5,8,10,12,25].

As regards ptosis correction, frontalis suspension is preferred in patients with no or minimal levator function, which is the case in patients with BPES. Autogenous fascia lata is the most appropriate material for the use in frontalis suspension, but there are insufficient amounts of this material in children younger than 3 years of age. Donor fascia lata provides a reasonable alternative that decreases the attendant morbidity and reduces the complexity of the procedure^[16,26,27]. When fascia lata is not available, whether autogenous or donor, synthetic materials can be used.

Other authors consider levator resection as a more physiologic procedure, with a better eyelid crease and involves no brow scars. Blomgren and Holmstrom suggested that Levator resection can be used for all types of congenital ptosis. Mauriello *et al* reported that maximal levator resection is indicated for severe congenital ptosis and poor to absent levator function, especially if the ptosis is unilateral^[28,29]. In this series, frontalis suspension was used in 10 patients, and maximum levator resection was used in 3 patients

who had asymmetric ptosis requiring unilateral surgery. MRD1 significantly improved from 1 ± 0.4 mm preoperative to 3.6 ± 0.3 mm post operative.

In conclusion, there are various strategies and complicated techniques that have been suggested for the management of BPES. Two stages surgeries using the least complex procedures as Y to V medial epicanthoplasty, medial canthal tendon plication, frontalis suspension or maximum levator resection can yield acceptable results in the correction of this complicated deformity.

CONFLICT OF INTERESTS

The author has no conflicts of interest to declare.

REFERENCES

- Zlotogora J, Sagi M, Cohen T. The blepharophimosis, ptosis, and epicanthus inversus syndrome: delineation of two types. *Am J Hum Genet* 1983;35: 1020–1027.
- Kohn R, Romano PE. Blepharoptosis, blepharophimosis, epicanthus inversus, and telecanthus – a syndrome with no name. *Am J Ophthalmol* 1971;72: 625–632.
- Merrill U, Berggreen S, Hansen L, Mikkelsen M, Henningsen K. Partial deletion of the short arm of chromosome 3. *Eur J Pediatr* 1981;136: 211–216.
- De Baere E, Dixon MJ, Small KW et al. Spectrum of FOXL2 gene mutations in blepharophimosis-ptosis-epicanthus inversus (BPES) families demonstrates a genotype–phenotype correlation. *Hum Mol Genet* 2001;15: 1591–1600.
- Li H, Li D, Jie Y, Qin Y. Multistage Correction of Blepharophimosis: Our Rationale for 18 Cases. *Aesth Plast Surg* 2009;33: 576–581.
- Mustardé JC. Epicanthus and telecanthus. *Br J Plast Surg* 1963;16: 346–356.
- Anderson RL, Nowinski TS. The five-flap technique for blepharophimosis. *Arch Ophthalmol* 1989;107:448–452.
- Sa HS, Lee JH, WooKI, Yoon-Duck Kim YD. A New Method of Medial Epicanthoplasty for Patients with Blepharophimosis-Ptosis Epicanthus Inversus Syndrome. *Ophthalmology* 2012;119: 2402–2407.
- Sebastia R, Neto GH, Fallico E, Lessa S, Solari HP, Ventura MP. A One-Stage Correction of the Blepharophimosis Syndrome Using a Standard Combination of Surgical Techniques. *Aesth Plast Surg* 2011;35: 820–827.
- Taylor A, Strike PW, Tyers AG. Blepharophimosis-ptosis-epicanthus inversus syndrome: objective analysis of surgical outcome in patients from a single unit. *Clin Exp Ophthalmol* 2007;35: 262–269.
- Leon-Mateos A, Ginarte M, Ruiz-Ponte C, Carracedo A, Toribio J. Blepharophimosis-ptosis-epicanthus inversus syndrome (BPES). *Int J Dermatol* 2007;46: 61–63.
- Nakajima T, Yoshimura Y, Onishi K, Sakakibara A. Onestage repair of blepharophimosis. *Plast Reconstr Surg* 1991;87: 24–31.
- Huang WQ, Qiao Q, Zhao R, Wang XJ, Fang XQ. Surgical strategy for congenital blepharophimosis syndrome. *Chin Med J (Engl)* 2007;120: 1413–1415.
- Friedhofer H, Nigro MV, Filho AC, Ferreira MC. Correction of blepharophimosis with silicone implant suspensor. *Plast Reconstr Surg* 2006;117: 1428–1434.
- Karacaoglan N, Sahin U, Ercan U, Bozdogan N. One-stage repair of blepharophimosis: a new method. *Plast Reconstr Surg* 1994;93: 1406–1409.
- Wu SY, Ma L, Tsai YJ, Kuo JZ C. One-stage correction for blepharophimosis syndrome. *Eye* 2008;22: 380–388.
- Beckingsale PS, Sullivan TJ, Wong VA, Oley C. Blepharophimosis: a recommendation for early surgery in patients with severe ptosis. *Clin Exp Ophthalmol* 2003;31: 138–142.
- Mustardé JC. Epicanthus, telecanthus, blepharophimosis and related conditions. In: Mustardé JC, ed. *Repair and Reconstruction in the Orbital Region: A Practical Guide*. 2nd ed. Edinburgh: Churchill Livingstone; 1980:346–51.
- Mustardé J. Congenital deformities in the orbital region. *Proc R Soc Med* 1971;64: 1121–1134.
- Nowinski TS. Correction of telecanthus in the blepharophimosis syndrome. *Int Ophthalmol Clin* 1992;32: 157–164.
- Oh YW, Seul CH, Yoo WM. Medial epicanthoplasty using the skin redraping method. *Plast Reconstr Surg* 2007;119: 703–710.
- Callahan A. Correction of blepharophimosis. In: Troutman RC, Converse JM, Smith B (eds) *Plastic and reconstructive surgery of the eye and adnexa*. Butterworths, Washington. 1962
- Mauriello JA Jr, Caputo AR. Treatment of congenital forms of telecanthus with custom-designed titanium medial canthal tendon screws. *Ophthalm Plast Reconstr Surg* 1994;10: 195–199.
- Shore JW, Rubin PA, Bilyk JR. Repair of telecanthus by anterior fixation of cantilevered miniplates. *Ophthalmology* 1992;99: 1133–1138.
- Tronina SA, Bobrova NE, Khrenenko VP. Clinical and anatomical substantiation of levator resection in the complex surgical treatment of BPES. *Orbit* 2006;25: 5–10.
- Deenstra W, Melis P, Kon M, Werker P. Correction of severe blepharoptosis. *Ann Plast Surg* 1996;36: 348–353.
- Wheatcroft SM, Vardy SJ, Tyers AG. Complications of fascia lata harvesting for ptosis surgery. *Br J Ophthalmol* 1997;81: 581–583.
- Blomgren I, Holmstrom H. Anterior levator resection in congenital genuine blepharoptosis. A follow-up of 55 operated eyelids. *Scand J Plast Reconstr Surg* 1986;20: 189–195.
- Mauriello JA, Wagner RS, Caputo AR, Natale B, Lister M. Treatment of congenital ptosis by maximal levator resection. *Ophthalmology* 1985;93: 466–469.

Peer reviewer: Michael K. Yoon, MD, Ophthalmic Plastic Surgery Massachusetts Eye and Ear Infirmary, 243 Charles Street, Boston, MA 02114, USA.