

Macular Hole Surgery Without Postoperative Prone Position and Spectral-Domain Optical Coherence Tomography Imaging in Gas-Filled Eyes

Fumihiko Yagi

Fumihiko Yagi, Department of Ophthalmology, Toho University Ohashi Medical Center, Tokyo, Japan

Correspondence to: Fumihiko Yagi, MD, Department of Ophthalmology, Toho University Ohashi Medical Center, 2-17-6 Ohashi, Meguro, Tokyo, 153-8515, Japan.

Email: fyagi@med.toho-u.ac.jp

Telephone: +81-3-3468-1251 Fax: +81-3-3468-2926

Received: May 25, 2015 Revised: July 16, 2015

Accepted: July 21, 2015

Published online: September 6, 2015

© 2015 ACT. All rights reserved.

Key words: Gas tamponade; Macular hole; Optical coherence tomography; Retinal-imaging; Without face-down positioning

Yagi F. Macular Hole Surgery Without Postoperative Prone Position and Spectral-Domain Optical Coherence Tomography Imaging in Gas-Filled Eyes. *International Journal of Ophthalmic Research* 2015; 1(2): 41-44 Available from: URL: <http://www.ghrnet.org/index.php/ijor/article/view/1224>

ABSTRACT

AIM: To evaluate whether spectral-domain optical coherence tomography (SD-OCT) can be used to determine if macular hole (MH) closure occurred in gas-filled eyes without postoperative face-down positioning.

METHODS: This retrospective, consecutive, observational case series included 19 eyes of 19 MH patients who underwent vitrectomy with SF₆ gas tamponade without postoperative face-down positioning. The MHs of all patients were evaluated using SD-OCT before and at 3 hours after surgery; daily until confirming the MH status; and at 1 and 3 months postoperatively.

RESULTS: Three hours after surgery, no interpretable images were obtained for any of the 19 eyes. On postoperative day 1, sufficiently clear images were obtained by SD-OCT to determine MH closure in 10 eyes (52.6%), 16 eyes (84.2%) on postoperative day 2, and 18 eyes (94.7%) on postoperative day 3. Clear images of the remaining eye were not obtained until postoperative day 5, likely due to pupillary capture of the intraocular lens. All MHs closed after the first surgery.

CONCLUSIONS: Hole closure can be precisely determined by postoperative day 5 using SD-OCT. If SD-OCT images through gas reveal that the hole is still open, then face-down positioning should be used so that residual gas in the vitreous cavity can close the hole, or a second vitrectomy should be planned.

INTRODUCTION

Since 1991, idiopathic macular holes (MHs) at stage 2, 3, and 4 have been treated successfully, as described by Kelly and Wendel^[1]. The surgical procedure includes pars plana vitrectomy, removal of the adherent cortical vitreous, peeling of epiretinal membranes, total air-gas exchange, and SF₆ gas tamponade, with strict occiput-up postoperative positioning for at least 1 week and a reported anatomic closure rate of 58%. Vitrectomy with gas tamponade is now considered essential for successful MH surgery, and strict occiput-up positioning for at least 1 week has become a widely accepted standard postoperative routine. The face-down position is uncomfortable, however, and extended periods of such positioning can also prolong immobilization, leading to ulnar nerve neuropathy^[2] and pressure sores^[3].

Tornambe *et al*^[4] first challenged the necessity of face-down positioning in MH surgery in 1997. In their study of 33 MH patients without face-down positioning using 15% C₃F₈ gas for the tamponade, the primary closure rate was 79% and the overall rate was 85%. We reported favorable anatomic and functional results by vitrectomy with internal limiting membrane (ILM) peeling and 20% SF₆ gas tamponade for MH surgery without postoperative face-down positioning^[5,6]. Although performing MH surgery without postoperative face-down positioning remains controversial, it is more comfortable for the patient and we observed no complications. The

face-down position is not necessary if MH closure is confirmed early in the postoperative period. The face-down position should only be initiated when the MH has not closed.

In 2000, Kasuga *et al*^[7] reported MH closure in 4 of 7 (58%) gas-filled eyes based on time-domain optical coherence tomography (TD-OCT) on postoperative day (POD) 1. Eckardt *et al*^[8] and Masuyama *et al*^[9] used spectral-domain OCT (SD-OCT) to determine MH closure in gas-filled eyes.

The purpose of the present study was to evaluate whether SD-OCT can be used to determine MH closure in gas-filled eyes after vitrectomy without face-down positioning.

METHODS

This retrospective case series included 19 eyes of 19 patients undergoing MH surgery performed by a single surgeon without postoperative face-down positioning. The procedures were performed between May 2009 and December 2011 at the Department of Ophthalmology, Toho University Ohashi Medical Center, Tokyo, Japan. Exclusion criteria were patients whose MH duration was longer than 6 months or unknown, who had secondary MH, such as that due to trauma, chronic cystoid macular edema, or high myopia and patients with clear lenses. After thoroughly explaining the risks and benefits of MH surgery without postoperative face-down positioning, we obtained written informed consent from all patients. This study was approved by Toho University Ohashi Medical Center Institutional Review Board (No.20-22), which followed the provisions of the Declaration of Helsinki.

MH was diagnosed by both stereoscopic biomicroscopy and SD-OCT and graded according to the Gass classification^[10].

The surgical procedure involved cataract extraction and intraocular lens implantation in all phakic eyes before standard 20-gauge three-port vitrectomy. Core vitrectomy was followed by surgical creation of a posterior hyaloid detachment in eyes with stage 2 or 3 MH. Indocyanine green diluted to a concentration of 0.125% was used to aid peeling of the ILM. The ILM was peeled beyond a radius of 1 disc diameter around the MH. Fluid-air exchange was performed, with no attempt to aspirate fluid from the MH, and the vitreous cavity was exchanged with double-filtered 20% SF₆ gas in all cases. Patients were prohibited from assuming a face-down or face-up position until the gas was completely absorbed.

Preoperative data collected included age at the time of surgery; sex; eye (left or right); visual acuity (VA); and MH stage, size, and duration. The MH status of all patients was evaluated by stereoscopic biomicroscopy and SD-OCT before and at 3 hours after surgery; daily until confirming the MH status; and 1 and 3 months postoperatively. VA was also examined before and at 1 and 3 months after surgery using a decimal chart, and the values were then converted to the logarithm of the minimum angle of resolution (log MAR) scale. We evaluated the longevity of 20% SF₆ gas bubbles until confirmation of MH closure or non-closure after surgery. The Statistical Package for the Social Sciences version 17.0 (SPSS Inc., Chicago, IL) was used for statistical analyses. The numerical data were analyzed using repeated measures analysis of variance (ANOVA). A p value of less than 0.05 was considered statistically significant.

Optical coherence tomography examination

The entire macular area was scanned by SD-OCT (3D OCT-1000, Topcon, Tokyo, Japan) with the patient in the seated position to avoid missing the MH. Using a raster scan program, 512×170 area scans (horizontal×vertical) were possible within the 6×6 mm² area.

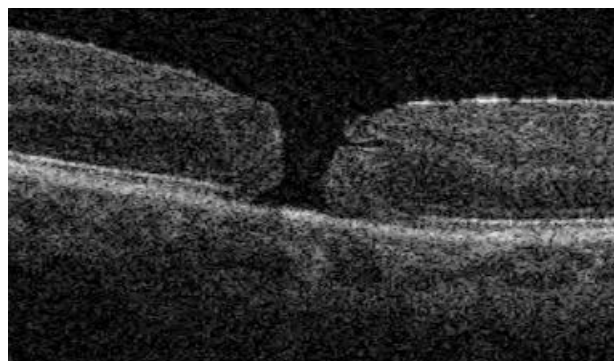


Figure 1 Preoperative optical coherence tomographic (OCT) image obtained from Case 15. Preoperative OCT image showing a stage 4 macular hole.

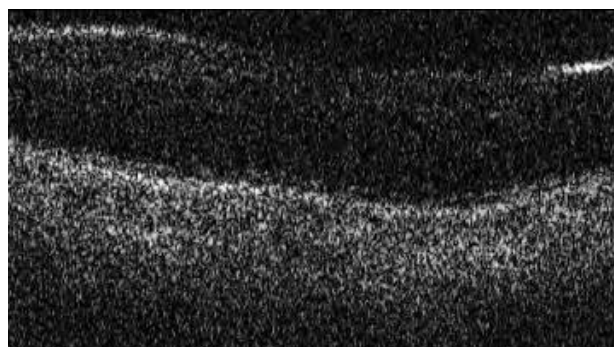


Figure 2 Optical coherence tomographic (OCT) image obtained from Case 15, one day after surgery. OCT image obtained through SF₆ gas tamponade on postoperative day 1 showing that the macular hole had closed.

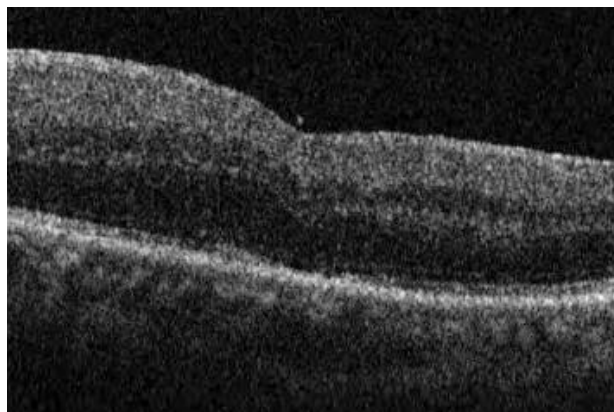


Figure 3 Optical coherence tomographic (OCT) image obtained from Case 15, 9 days after surgery. OCT image obtained on postoperative day 9 showing that the macular hole had closed, through the vitreous humor.

Thus, it is unlikely that an unclosed MH was overlooked using this method. MH closure by SD-OCT was defined as the absence of an interruption of the internal line of the inner retina in any macular area. If MH was not closed, face-down positioning was initiated to allow for any residual gas in the vitreous cavity to close the MH.

RESULTS

Of the 19 patients, 9 (47.4%) were women and 10 (52.6%) were men, with a mean age of 66.7 years (range, 54-79). Among the 19 eyes, 5 (26.3%) had stage 2 MH, 11 (57.9%) stage 3 MH, and 3 (15.8%) stage 4 MH. Mean MH size was 0.34 disc diameters (range,

0.2-0.6). MH had been present for a mean of 2.1 months (range, 1-6 months). Of the 19 eyes, 18 (94.7%) were phakic and 1 (5.3%) was pseudophakic.

Three hours postoperatively, no interpretable images were obtained for any of the 19 eyes, likely due to media opacity. On POD 1, comparatively clear images were obtained for 10 of the 19 eyes (52.6%), allowing for MH closure to be determined by SD-OCT through the gas. The imaging success rate was 84.2% (16 of 19 eyes) on POD 2 and 94.7% (18 of 19 eyes) on POD 3. Sufficiently clear images were not obtained for the remaining eye (case 12) until POD 5, likely due to pupillary capture of the intraocular lens postoperatively. Of the 19 MHs, all holes closed after the first surgery and none of the eyes showed reopening of the MH.

The preoperative mean VA (log MAR) of 0.69 was significantly improved to 0.46 at 1 month and 0.33 at 3 months after surgery ($P < 0.0001$, repeated measures ANOVA). The mean longevity of 20% SF₆ gas bubbles, until confirmation of MH closure or non-closure by postoperative SD-OCT under the vitreous humor, was 9.0 days (range 6-11 days).

Iatrogenic retinal tear requiring endophotocoagulation occurred intraoperatively in 7 eyes (36.8%). One (5.3%) eye (case 2) had postoperative rhegmatogenous retinal detachment that required additional surgery to reattach the retina. Patient data are shown in the table 1.

DISCUSSION

Jumper *et al*^[11] used silicone oil for the tamponade instead of gas and obtained evaluable TD-OCT images in 5 of 7 eyes (71.4%) with MH on POD 1. In 2 of these 5 eyes, the MH had not yet closed although the foveal cysts had resolved by this time. Sato *et al*^[12] also using TD-OCT to evaluate MH closure, reported a decrease in the subretinal fluid and foveal cysts on POD 1 in one eye with SF₆ gas tamponade, but MH closure was not complete until POD 2. Kasuga *et al*^[7] acquired good TD-OCT images through the gas in 4 of 7 eyes (57.1%) with MH using SF₆ gas tamponade on POD 1, and the MH in all four eyes was closed. Because the TD-OCT images of these eyes revealed no changes in the anatomic configuration of the macula over the following 3 months, the authors concluded that they were able to confirm the success of the MH surgery within 24 hours after surgery.

Eckardt *et al*^[8] reported obtaining SD-OCT images for MH closure by using a special setting of the SD-OCT system. The SD-OCT was rotated 90 degrees by attaching it to a special support so that the OCT measuring light entered the lower part of the eye with the patient in a prone position. They reported that imaging was possible for 25 of 33 eyes (75.8%) at 24 hours after surgery, for 29 eyes (87.9%) at 48 hours after surgery, and all eyes at POD 3 using an air tamponade. Masuyama *et al*^[9] reported that imaging was possible using 16% SF₆ gas as the tamponade for 3 of 5 eyes (60.0%) at 3 hours after surgery, and for 13 of 16 eyes (81.3%) on POD 1 and 2 by SD-OCT. Sano *et al*^[13] reported that the postoperative status of the MH could be determined in 24 of 26 eyes (92%) on POD 1 by SD-OCT. Goto *et al*^[14] reported imaging success rate was 22 of 25 eyes (88.0%) on POD 1 and 23 of 24 eyes (95.8%) on POD 2 by SD-OCT. Hasler and Prunte^[15] were able to evaluate the macula by TD-OCT during the immediate postoperative period, and determined that the MH was closed in two eyes half-filled with air on POD 1 and the MH was closed in 28 of 30 eyes (93.3%) while in 2 eyes (6.7%) the MH was not closed on POD 3, based on images obtained with the measuring beam passing through the vitreous humor. When the beam passed through gas-filled eyes, however, a clear image could not be obtained because of a strong light reflection from the posterior surface of the gas. A detailed examination of the macular area was hampered by strong signals from the intravitreal gas, corneal edema, and vitreous opacity.

Tornambe *et al*^[4] first challenged the necessity of face-down positioning in MH surgery in 1997. In 2001, Simcock and Scialia^[16] reported that face-down positioning might not be necessary for stage 2 and 3 MH. In 2007, there were three reports in which face-down positioning was not used after MH surgery^[17-19]. In these three studies, ILM peeling and 12% to 18% C₃F₈ gas tamponade were performed without subsequent face-down positioning, and anatomic hole closure rates of 87.5% to 92% were achieved with a single operation. In 2008, Carvounis *et al*^[20] reported the results of 25-gauge vitrectomy with ILM peeling and 10% to 20% SF₆ gas tamponade without face-down positioning. Anatomic success was achieved in 88.6% (39 of 44) of eyes with a single operation. In 2012, we reported that results for vitrectomy with ILM removal and 20% SF₆ gas tamponade without postoperative face-down positioning for MH, and the anatomic hole closure rate was 93.9% (31 of 33) for eyes

Table 1 Patient data.

Case	Sex	Age (years)	Eye	Symptom duration (months)	Pre operative VA (log MAR)	Post operative VA (log MAR)	Hole stage	Hole size (DD)	MH status	Confirme time (days)	1/2 gas (days)
1	M	77	R	2	1	0.5	3	0.3	Closed	2	10
2	M	72	L	1	0.7	1	3	0.3	Closed	2	10
3	M	60	R	2	1	0.4	3	0.5	Closed	2	11
4	F	70	R	1	0.4	-0.1	3	0.2	Closed	1	8
5	M	66	R	2	1	0.2	3	0.2	Closed	1	7
6	F	62	R	2	0.5	0.1	4	0.3	Closed	1	8
7	F	65	L	5	1	0.5	3	0.3	Closed	2	6
8	F	66	R	1	0.7	0.3	3	0.2	Closed	1	8
9	F	54	L	2	0.2	0.2	3	0.2	Closed	3	8
10	F	79	R	1	0.7	0.3	2	0.3	Closed	2	10
11	F	69	R	6	1	0.5	3	0.6	Closed	1	9
12	F	70	L	2	1	0	3	0.5	Closed	5	10
13	M	71	R	1	0.5	0.5	3	0.6	Closed	1	11
14	F	57	L	1	0.7	0.1	2	0.3	Closed	1	11
15	M	55	L	1	0.3	0.3	4	0.5	Closed	1	9
16	M	66	L	1	0.7	0	2	0.2	Closed	1	8
17	M	79	R	6	1	1	2	0.3	Closed	1	9
18	M	66	R	2	0.3	0.2	4	0.5	Closed	3	11
19	M	63	R	1	0.4	0.2	2	0.2	Closed	1	7

M: male, F: female, L: left, R: right, VA: visual acuity, log MAR: logarithm of minimum angle of resolution, DD: disc diameter, MH: idiopathic macular hole, MH status: MH status after first surgery, Confirmed time: time at which MH closure or non-closure under gas was confirmed by spectral domain optical coherence tomography postoperatively, 1/2 gas: time at which MH closure or non-closure under vitreous humor was confirmed by spectral domain optical coherence tomography postoperatively

with a single operation^[6]. These results suggest that vitrectomy with ILM peeling and gas tamponade without postoperative face-down positioning leads to excellent hole closure rates, comparable with those achieved using conventional vitrectomy techniques with face-down positioning.

In the present study, comparatively clear SD-OCT images were obtained to determine MH closure in 10 of 19 eyes (52.6%) on POD 1, 16 of 19 eyes (84.2%) on POD 2, 94.7% (18 of 19 eyes) on POD 3, and all eyes on POD 5. It is very difficult to compare the imaging success rate of the present study with those of the other studies that used SD-OCT (i.e., Eckardt *et al*^[8], Masuyama *et al*^[9], Sano *et al*^[13] and Goto *et al*^[14]), however, because of the small sample size of these five studies. Postoperative face-down positioning, however, leads to the accumulation of a considerable amount of keratic precipitates in the central cornea, which could affect the coherence of the measuring light. Our findings indicate that vitrectomy for MH without face-down positioning achieved favorable anatomic and functional results. These surgical methods may spare patients the potentially unnecessary inconvenience of postoperative face-down positioning.

The limitations of this study include the lack of a concurrent control group and the fact that a single vitreoretinal surgeon performed all procedures. Therefore, we did not obtain data comparing the results between different surgical procedures or between surgeons, nor did we evaluate the accuracy of the success rate.

In conclusion, based on the present result, MH closure can be decisively determined during the first 5 postoperative days using SD-OCT. For 19 eyes of 19 patients, we performed vitrectomy with ILM peeling and SF₆ gas tamponade for MH without postoperative face-down positioning and achieved favorable anatomic and functional results based on SD-OCT images obtained through gas-filled eyes. These surgical methods may spare patients the potentially unnecessary inconvenience of postoperative face-down positioning. Moreover, if there is no or only incomplete closure of the MH, face-down positioning can be initiated to allow the residual gas in the vitreous cavity to close the hole, or a second vitrectomy should be performed.

CONFLICT OF INTERESTS

The author have no conflicts of interest to declare.

REFERENCES

1. Kelly NE, Wendel RT. Vitreous surgery for idiopathic macular holes. Results of a pilot study. *Arch Ophthalmol* 1991; 109: 654-659.
2. Holekamp NM, Meredith TA, Landers MB, Snyder WB, Thompson JT, Berman AJ, Williams S. Ulnar neuropathy as a complication of macular hole surgery. *Arch Ophthalmol* 1999; 117: 1607-1610.
3. Vincent JM, Peyman GA, Ratnakaram R. Bilateral ulnar decubitus as a complication of macular hole surgery. *Ophthalmic Surg Lasers Imaging* 2003; 34: 485-486.

4. Tornambe PE, Poliner LS, Grote K. Macular hole surgery without face-down positioning. A pilot study. *Retina* 1997; 17: 179-185.
5. Yagi F, Sato Y, Takagi S, Tomita G. Idiopathic macular hole vitrectomy without postoperative face-down positioning. *Jpn J Ophthalmol* 2009; 53: 215-218.
6. Yagi F, Sato Y, Takagi TS, Tomita G. Macular hole surgery. *Ophthalmology* 2012; 119: 647-648.
7. Kasuga Y, Arai J, Akimoto M, Yoshimura N. Optical coherence tomography to confirm early closure of macular holes. *Am J Ophthalmol* 2000; 130: 675-676.
8. Eckardt C, Eckert T, Eckardt U, Porkert U, Gesser C. Macular hole surgery with air tamponade and optical coherence tomography-based duration of face-down positioning. *Retina* 2008; 28: 1087-1096.
9. Masuyama K, Yamakiri K, Arimura N, Sonoda Y, Doi N, Sakamoto T. Posturing time after macular hole surgery modified by optical coherence tomography images: a pilot study. *Am J Ophthalmol* 2009; 147: 481-488.
10. Gass JDM. Reappraisal of biomicroscopic classification of stages of development of macular hole. *Am J Ophthalmol* 1995; 119: 752-759.
11. Jumper JM, Gallemore RP, McCuen BW, Toth CA. Features of macular hole closure in the early postoperative period using optical coherence tomography. *Retina* 2000; 20: 232-237.
12. Sato H, Kawasaki R, Yamashita H. Observation of idiopathic full-thickness macular hole closure in early postoperative period as evaluated by optical coherence tomography. *Am J Ophthalmol* 2003; 136: 185-187.
13. Sano M, Inoue M, Taniuchi S, Kunita D, Hiraoka T, Hirakata A. Ability to determine postoperative status of macular hole in gas-filled eyes by spectral-domain optical coherence tomography. *Clin Exp Ophthalmol* 2011; 39: 885-892.
14. Goto K, Mizukawa K, Kiryu J. Factors affecting imaging of spectral-domain optical coherence tomography in gas-filled eyes after macular-hole surgery. *Jpn J Ophthalmol* 2012; 56: 236-244.
15. Hasler PW, Prunte C. Early foveal recovery after macular hole surgery. *Br J Ophthalmol* 2008; 92: 645-649.
16. Simcock PR, Scalia S. Phacovitrectomy without prone posture for full thickness macular holes. *Br J Ophthalmol* 2001; 85: 1316-1319.
17. Merkur AB, Tuli R. Macular hole repair with limited nonsupine positioning. *Retina* 2007; 27: 365-369.
18. Tranos PG, Peter NM, Nath R, Singh M, Dimitrakos S, Charteris D, Kon C. Macular hole surgery without prone positioning. *Eye* 2007; 21: 802-806.
19. Rubinstein A, Ang A, Patel CK. Vitrectomy without postoperative posturing for idiopathic macular holes. *Clin Exp Ophthalmol* 2007; 35: 451-461.
20. Carvounis PE, Kopel AC, Kuhl DP, Heffez J, Pepple K, Holz ER. 25-gauge vitrectomy using sulfur hexafluoride and no prone positioning for repair of macular holes. *Retina* 2008; 28: 1188-1192.

Peer reviewer: Lorenzo Iuliano, Ophthalmology Department, San Raffaele Scientific Institute, Vita-Salute University, Via Olgettina, 60, 20132 Milan, Italy.