

Total Lens Dislocation Caused by Pseudexfoliation

Peter Glasman, Ivan Yip, Carl Groenwald, Anshoo Choudhary

Peter James Glasman, Ivan Yip, Carl Groenwald, Anshoo Choudhary, St. Paul's Eye Unit, Royal Liverpool University Hospital, Liverpool, United Kingdom

Correspondence to: Peter James Glasman, St. Paul's Eye Unit, Royal Liverpool University Hospital, Liverpool, United Kingdom

Email: peter.glasman@doctors.net.uk

Telephone: +44-151-7062000

Received: January 27, 2015

Revised: February 10, 2015

Accepted: February 14, 2015

Published online: June 1, 2015

ABSTRACT

Pseudoexfoliation (PXF) is a well-known cause of complications during cataract surgery, particularly dropped nucleus and vitreous loss. Such complications must be managed by appropriate vitreoretinal intervention.

© 2015 ACT. All rights reserved.

Key words: Cataract surgery; Complications; Vitreous loss

Glasman PJ, Yip I, Groenwald C, Choudhary A. Total Lens Dislocation Caused by Pseudexfoliation. *International Journal of Ophthalmic Research* 2015; 1(1): 32-33 Available from: URL: <http://www.ghrnet.org/index.php/ijor/article/view/1232>

INTRODUCTION

A 78 year old lady underwent cataract surgery. Pseudoexfoliation (PXF) and phacodonesis were noted pre-operatively, but the eye was otherwise healthy. The intraocular pressure was normal, the pupil dilated well and there was no glaucomatous neuropathy. On the operating table, the crystalline lens was quite mobile but capsulorrhexis and hydrodissection were completed satisfactorily. All the zonules appeared to be weak as there was no decentration in

any particular direction. However, the lens was too mobile to safely continue phacoemulsification and it was therefore decided to stabilise the lens with insertion of a capsular tension ring. Just as the ring was inserted, the entire lens dislocated into the vitreous cavity and required removal by pars plana vitrectomy (Figure 1).

DISCUSSION

PXF is a systemic disorder of unknown cause whereby amyloid-like proteins are abnormally deposited throughout the body. The condition can be found worldwide but is much more common in certain geographical areas, particularly Scandinavia. The chief manifestations are in the eye, where it can be discerned by slit lamp examination; it is a common cause of secondary glaucoma and is also associated with complications during cataract surgery, owing to lens/zonular instability. However, it may also manifest itself systemically, with evidence implicating PXF in cardiovascular diseases such as abdominal aortic aneurysm^[1], renal artery stenosis^[2], heart disease and stroke^[3].

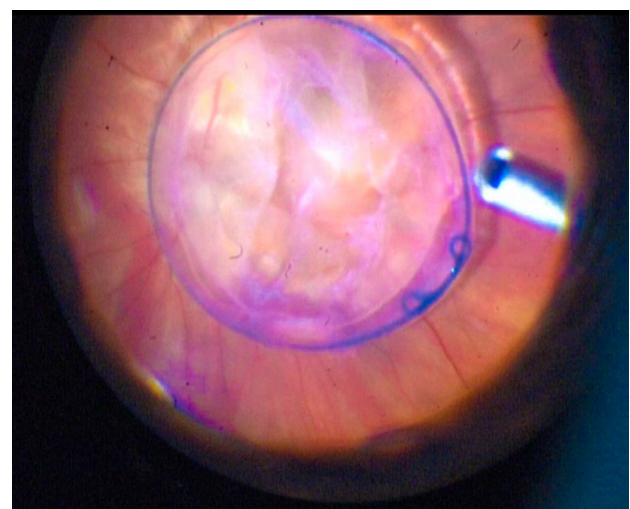


Figure 1 legend Dropped nucleus and intra-capsular tension ring.

PXF is strongly associated with complications during cataract surgery, with a vitreous loss rate of up to 27%^[4]. Surgical strategies which may be indicated include pupil enlargement manoeuvres (stretching, iris hooks or the Malyugin ring), extreme caution when inflating the anterior chamber or performing hydrodissection and capsular tension ring or sutured tension ring (Cianni) segment insertion. In cases where phacodonesis is evident pre-operatively, it may be wise to refer the patient to a vitreo-retinal surgeon.

CONFLICT OF INTERESTS

The Corresponding Author has the right to grant on behalf of all authors and does grant on behalf of all authors, a worldwide licence to the Publishers and its licensees in perpetuity, in all forms, formats and media (whether known now or created in the future), to (1) publish, reproduce, distribute, display and store the Contribution; (2) translate the Contribution into other languages, create adaptations, reprints, include within collections and create summaries, extracts and/or, abstracts of the Contribution; (3) create any other derivative work(s) based on the Contribution; (4) to exploit all subsidiary rights in the Contribution; (5) the inclusion of electronic links from the Contribution to third party material where-ever it may be located; and

(6) licence any third party to do any or all of the above.

All authors have read and understood the policy on declaration of interests and declare the following interests: none.

All authors have contributed to the preparation of the article and take responsibility for the information contained herein.

REFERENCES

1. Pseudoexfoliation syndrome and aneurysms of the abdominal aorta. Schumacher S *et al.* *Lancet* 2001, 357: 359-60.
2. Renal artery stenosis and abdominal aorta aneurysm in patients with pseudoexfoliation syndrome. Gonen KA, Gonen T, Gumus B. *Eye* 2013, 27(6):735-41.
3. Shrum KR, Hattenhauer MG, Hodge D (2000) Cardiovascular and cerebrovascular mortality associated with ocular pseudoexfoliation. *Am J Ophthalmol* 129: 83-86.
4. Naumann GO, Schlötzer-Schrehardt U, Kühle M (1998) Pseudoexfoliation syndrome for the comprehensive ophthalmologist. Intraocular and systemic manifestations. *Ophthalmology* 105: 951-968.

Peer reviewer: Gabor Hollo, MD, PhD, DSc, Professor of Ophthalmology, Department of Ophthalmology, Semmelweis University, Maria u. 39. Budapest, Hungary.