

## Long-Term Follow-up of a Case With Persistent Pupillary Membrane Treated by Sequential Argon-YAG Laser Membranectomy

Ting-Hsuan Lin, Tzu-Lun Huang, Pei-Yuan Su, Pei-Yao Chang, Ih-Jane Yang, Jia-Kang Wang

Ting-Hsuan Lin, Tzu-Lun Huang, Pei-Yuan Su, Pei-Yao Chang, Ih-Jane Yang, Jia-Kang Wang, Department of Ophthalmology, Far Eastern Memorial Hospital, New Taipei City, Taiwan

Ting-Hsuan Lin, Department of Medicine, Kaohsiung Medical University, Kaohsiung City, Taiwan

Ih-Jane Yang, Jia-Kang Wang, Department of Medicine, National Yang Ming University, Taipei City, Taiwan

Jia-Kang Wang, Department of Healthcare Administration and Department of Nursing, Oriental Institute of Technology, New Taipei City, Taiwan

Jia-Kang Wang, Department of Medicine, National Taiwan University, Taipei City, Taiwan

Tzu-Lun Huang, Institute of Medical Sciences, Tzu Chi University, Hualien City, Taiwan

Pei-Yuan Su, Department of Medicine, Fu Jen Catholic University, New Taipei City, Taiwan

Correspondence to: Jia-Kang Wang, Department of Ophthalmology, Far Eastern Memorial Hospital, 21, Sec. 2, Nan-Ya South Road, Pan-Chiao District, New Taipei City, 220, Taiwan

Email: [jiakangw2158@gmail.com](mailto:jiakangw2158@gmail.com)

Telephone: +886-2-89667000 Fax: +886-2-27903225

Received: July 8, 2015 Revised: August 26, 2015

Accepted: September 1, 2015

Published online: September 6, 2015

### ABSTRACT

**PURPOSE:** To report a case with extensive persistent pupillary membrane treated by sequential argon-YAG laser membranectomy.

**CASE REPORT:** A 33-year-old female had a prominent persistent pupillary membrane obstructing the visual axis of the right eye, thereby preventing measurement of refraction even after mydriasis. Her uncorrected vision was 20/400. Firstly, the argon laser was used to photocoagulate the part of the membrane adhering to the

iris surface and so to prevent any bleeding caused by the YAG laser. Secondly the YAG laser was used to photodisrupt the membrane remnant attached to the iris. Mild pigment dispersion was found in the anterior chamber, without associated microhemorrhages after the laser treatments. Spontaneous reabsorption of the free floating membrane occurred 1 week after the membranectomy. After an 8-year follow-up period, her right corrected visual acuity increased to 20/40 with high myopia. No ocular complications or membrane recurrence were noted.

**CONCLUSION:** Sequential argon-YAG laser membranectomy may effectively be used to treat persistent pupillary membrane without any long-term risk of major side effects.

© 2015 ACT. All rights reserved.

**Key words:** Iris; Persistent pupillary membrane; Sequential argon-YAG laser membranectomy

Lin TH, Huang TL, Su PY, Chang PY, Yang IJ, Wang JK. Long-Term Follow-up of a Case With Persistent Pupillary Membrane Treated by Sequential Argon-YAG Laser Membranectomy. *International Journal of Ophthalmic Research* 2015; 1(2): 66-68 Available from: URL: <http://www.ghrnet.org/index.php/ijor/article/view/1284>

### BACKGROUND

Persistent pupillary membranes (PPMs) are a common congenital anomaly seen in about 95% of newborns<sup>[1,2]</sup> and due to an incomplete involution of the *tunica vasculosa lentis*<sup>[1]</sup>. The membranes are seen originating at the collarette of the iris and either bridge the pupil to the collarette on the opposite side or may have one end free floating<sup>[2]</sup>. They mostly do not require treatment since PPMs usually undergo considerable atrophy during the first year of life<sup>[3]</sup>. However, dense membranes that cause visual impairment must be removed.

## CASE REPORT

A 33-year-old female patient with bilateral PPM and high myopia was seen in our clinic. The right eye had no previous treatment and the patient was aware of longstanding blurred vision in the right eye. The PPM in the left eye had been treated with surgical excision at the age of 9 years. This treatment appeared to be successful with best-corrected visual acuity (BCVA) of 20/40, although there was now a high degree of myopia (-16 D). The anterior and posterior segments and intraocular pressure (IOP) in the right eye were normal except for the prominent PPM (Figure 1), which was not associated cataract. Her right uncorrected vision was 20/400. A retinoscope or auto-refractor could not measure the refraction, even after mydriasis, due to obstruction by the dense PPM. Visual acuity remained 20/400 after pinhole correction, and long axial length measured by optical biometry (IOLMaster, Zeiss Co., Berlin, Germany) was 28.32 mm. Sequential argon-YAG membranectomy was performed to remove the PPM in July 2006. Under topical anesthesia and dilated pupil conditions, the light was focused with an Abraham capsulotomy lens. The argon laser (PUREPOINT<sup>®</sup>, Alcon Laboratories Inc., Fort Worth, TX, USA) was used to photocoagulate the part of the PPM attached to the iris surface to prevent bleeding caused by the YAG laser. The argon laser settings were spot size 100  $\mu$ m, energy 300 mW, and duration 0.1 second for 30 applications (Figure 2). The Nd:YAG laser (3000-LE, Alcon Laboratories Inc., Fort Worth, TX, USA) with energy set to 1-5 mJ for 30 applications was used to photodisrupt the PPM remnant adhering to the iris (Figure 2). All laser procedures were completed in one session. Spontaneous absorption of the free floating PPM had occurred by 1 week after the membranectomy. Mild pigment dispersion was found in the anterior chamber, without associated microhemorrhages. Increased IOP up to 25 mmHg was found one hour after the laser treatments. The patient was treated with topical 0.5% timolol twice a day and dexamethasone ophthalmic solution four times a day to lower the IOP and the inflammation in the chamber. The patient recovered fully without medical management 1 week after the laser therapy. After 8 years of follow-up, her right BCVA was 20/40 with high myopia of -15 D and her right eye (Figure 3) and left eye were free of recurrent or residual PPM. The appearance of the pupil was not different between laser and surgically treated eyes. Spectral-domain optical coherence tomography showed normal macular anatomy. No ocular complications, such as cataract and hyphema, were noted.

## DISCUSSION

Before the era of ophthalmic lasers, surgical excision was essential for removal of PPMs. The surgery was technically simple, but might carry some operational risks, such as secondary cataract, hyphema, infection, wound disruption, or even epithelial ingrowth<sup>[4-7]</sup>. In 1987, Vega *et al*<sup>[3]</sup> first successfully treated dense PPM with Nd: YAG laser irradiation. The technique is noninvasive and effective, can be performed in an outpatient clinic without the risk of intraoperative and postoperative complications associated with conventional surgery, and the period of vision recovery is quick, most likely one week. Kumar *et al*<sup>[4]</sup>, also reported the same results for the use of Nd: YAG laser membranectomy for removing PPM. However, temporary microhemorrhages were found following photodisruption of the remnant strands of PPM in two reports<sup>[3,4]</sup>.

When our patient came to the clinic for examination, an extensive PPM was discovered. Because of poor vision not corrected by glasses, removal of the membrane was advocated. We used a sequential

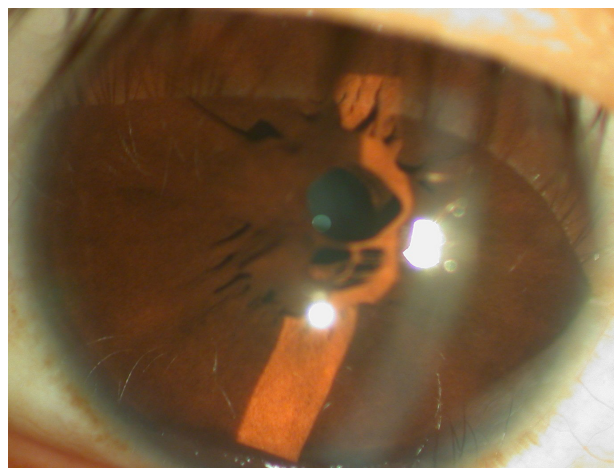


Figure 1 The extensive persistent pupillary membrane.

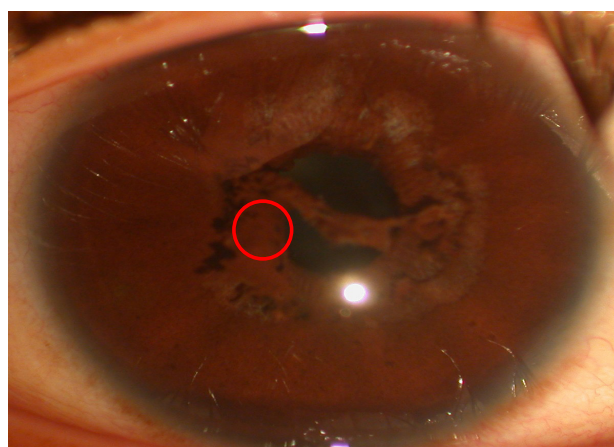


Figure 2 Charring on the strands of the pupillary membrane near the lower part of the collarette of the iris after argon laser photocoagulation, and the severed strands on the upper part of the membrane following photodisruption by the Nd:YAG laser without microhemorrhage.

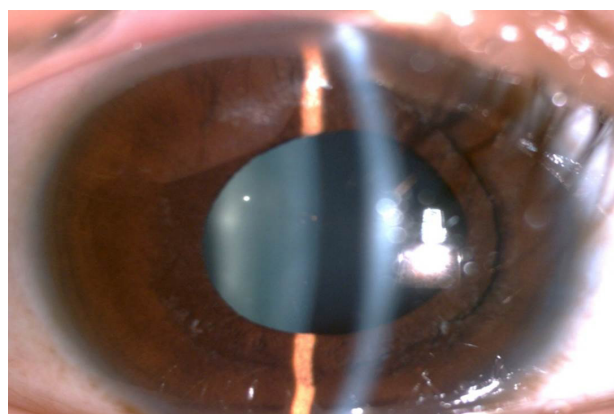


Figure 3 Absence of the pupillary membrane at the 8-year follow-up.

argon-YAG laser method to remove the PPM without causing bleeding of the iris. The method was inspired by the sequential argon-YAG laser iridotomy procedure used to treat angle-closure glaucoma<sup>[8]</sup>. The argon laser is a thermal laser, which can produce a coagulative effect on the surface of the iris, thereby averting subsequent hemorrhage<sup>[9]</sup>. The Nd:YAG laser is used to photodisrupt the PPM strands. Little deposition of dispersed iris pigments occur in the anterior chamber following such laser treatment, and this

dispersion disappears the next day. When glaucoma occurs, it is mild, temporary, secondary, and can be controlled medically. Large PPMs may remain vascularized or persist as vascularized fragments that do not spontaneously absorb after birth<sup>[10]</sup>. Following laser membranectomy, the free floating non-vascularized PPM can disappear without sequelae in one week. Although ours was the first attempt to use the modified laser technique for removal of PPM, the good anatomical and visual results persisted long-term.

The stenopaeic effect of the PPM may account for the lack of deprivation amblyopia. A circle at the center of the membrane acted as a pinhole and prevented total obstruction of the central visual axis. Visual acuity can improve after removal of the membrane.

In conclusion, sequential argon-YAG laser membranectomy is noninvasive, effective for removal of PPMs, and prevents small hemorrhages that usually follow laser treatment. To our knowledge, this is the first case of PPM managed by the modified laser technique. The anatomical and visual improvement is long-lasting.

## CONFLICT OF INTERESTS

The authors have no conflicts of interest to declare.

## REFERENCES

- 1 Kolin T, Murphee L. Hyperplastic persistent pupillary membrane. *Am J Ophthalmol* 1997;123:839-841.
- 2 Lu HY, Wang TW, Wang WH, Hu CC. Surgical removal of persistent pupillary membrane with stegmann scissors. *Acta Soc Ophthalmol Sinicae* 2002;41:147-152.
- 3 Vega LF, Sabates R. Neodymium: YAG laser treatment of persistent pupillary membrane. *Ophthalmic Surg* 1987;18:452-454.
- 4 Kumar H, Sakhuja N, Sachdev MS. Hyperplastic pupillary membrane and laser therapy. *Ophthalmic Surg* 1994;25:189-190.
- 5 Han KE, Kim CY, Chung JL, Hong JP, Sgrignoli B, Kim EK. Successful argon laser photocoagulation of diffuse epithelial ingrowth following concomitant persistent pupillary membrane removal and phacoemulsification. *J Cataract Refract Surg*. 2012;38:906-11.
- 6 Gupta R, Kumar S, Sonika, Sood S. Laser and surgical management of hyperplastic persistent pupillary membrane. *Ophthalmic Surg Lasers Imaging* 2003;34:136-9.
- 7 Kraus CL, Lueder GT. Clinical characteristics and surgical approach to visually significant persistent pupillary membranes. *J AAPOS* 2014;18:596-599.
- 8 Wang JK, Lai PC. An unusual presentation of angle closure glaucoma treated by phacoemulsification. *J Cataract Refract Surg* 2004;30:1371-1373.
- 9 Kapoor KG, Baratz KH, Barkmeier AJ. Laser photocoagulation of an avulsed persistent pupillary membrane vessel causing recurrent hyphema. *Clin Experiment Ophthalmol* 2013;41:513-515.
- 10 Kotamarthi V, Sarodia O, Woodruff GH. Spontaneous hyphema secondary to a vascularized fragment of persistent pupillary membrane. *Eye (Lond)* 2001;15:240-241.

**Peer reviewer:** Shengli Mi, Associate Professor, Room 102, J Building, Tsinghua Campus, University Town, Nanshan district, Shenzhen, China.