

## A Review of Intravitreal Treatment Alternatives Used as an Adjunctive Therapy in Coats' Disease

Melih Parlak, Ali Osman Saatci

Melih Parlak, Department of Ophthalmology, Klinikum Konstanz, Konstanz, Germany

Ali Osman Saatci, Department of Ophthalmology, Dokuz Eylul University Medical School, Izmir, Turkey

Correspondence to: Ali Osman Saatci, Mustafa Kemal Sahil Bulvarı, No:73, A Blok D:9, 35320 Narlıdere/Izmir, Turkey

Email: [osman.saatci@yahoo.com](mailto:osman.saatci@yahoo.com)

Telephone: +90-532-7437071 Fax: +90-232-4123099

Received: September 15, 2015 Revised: December 9, 2015

Accepted: December 12, 2015

Published online: December 29, 2015

### ABSTRACT

**AIM:** To review the intravitreal treatment alternatives used as an adjunctive therapy in Coats' disease.

**CONTEXT:** The goal of therapy in Coats' disease is essentially to obliterate all retinal nonperfused areas and ablate retinal vascular abnormalities in order to provide subretinal fluid resolution and regression of hard exudates whenever feasible. However, both anti-VEGFs and steroids are also administered intravitreally to improve the anatomic and functional outcome in cases with Coats' disease by many clinicians nowadays.

**METHODS:** A comprehensive literature search in the databases of Pubmed and Cochrane Library was conducted in July 2015 to obtain all manuscripts related to Coats' disease and intravitreal treatment.

**Results:** Among 71 search results, 34 relevant studies, predominately in the form of case reports and small case series were included. These were evaluated in detail and summarized in this report.

**CONCLUSIONS:** There is a growing body of literature on the use of intravitreal agents as an adjunctive treatment for Coats' disease. However there is still open questions, particularly regarding the drug choice and long-term safety. Coming years will ascertain the place of intravitreal pharmacotherapy, which may find a niche in the treatment armamentarium of Coats' disease.

**Key words:** Bevacizumab; Coats' disease; Dexamethasone implant; Laser photocoagulation; Ozurdex; Pegaptanib; Ranibizumab

Parlak M, Saatci AO. A Review of Intravitreal Treatment Alternatives Used as an Adjunctive Therapy in Coats' Disease. *International Journal of Ophthalmic Research* 2015; 1(3): 71-76 Available from: URL: <http://www.ghrnet.org/index.php/ijor/article/view/1366>

### INTRODUCTION

Coats' disease was first described in 1908 by George Coats as a retinal vascular disorder characterized by retinal telangiectasia and severe intraretinal and subretinal exudation<sup>[1]</sup>. It mainly affects young male individuals during the childhood and presents mostly unilateral. However, Coats' disease can also present in adults and bilaterally<sup>[2]</sup>. Its prevalence is estimated as <1:100.000<sup>[3]</sup>.

The pathogenesis of Coats' disease is still somewhat unclear. Black *et al*<sup>[4]</sup>, suggested that Coats' telangiectasia could be secondary to somatic mutation in the NDP gene, which results in the deficiency of Norrin within the developing retina. A vessel malformation and breakdown of the blood-retinal barrier at the endothelial level are thought to be the main pathological process of Coats' disease. Weakening of the vessel wall structure leads to the formation of telangiectasia and aneurysms, peripheral capillary dropout, progressive intraretinal and/or subretinal exudation and retinal detachment<sup>[5]</sup>. In recent years angiogenic cytokines such as vascular endothelial growth factor (VEGF), were also investigated in Coats' disease.

### CLINICAL FEATURES, DIAGNOSIS AND CLASSIFICATION

The most common presenting signs and symptoms are leukocoria, strabismus and decreased vision<sup>[6]</sup>. Sometimes asymptomatic children are recognized during routine ophthalmoscopy. In the early phase, the anterior segment is usually inconspicuous. Ciliary injection, corneal edema, rubeosis iridis can only be seen in advanced disease due to retinal detachment and neovascular glaucoma. Typical fundoscopic

findings of Coats' disease are retinal vascular changes such as telangiectasia, microaneurysms, calibre variations, tortuosity and intraretinal and/or subretinal exudates (Figure 1a and b). Progressive subretinal exudation can lead to a total retinal detachment and several related complications<sup>[7]</sup>.

In the majority of cases it is possible to establish the diagnosis with the clinical examination alone. Fluorescein angiography (FA) is an important diagnostic tool, which can demonstrate the vascular abnormalities, breakdown of the inner blood-retinal barrier and capillary dropout. Imaging modalities, like ultrasound, computerized tomography and magnetic resonance imaging, can be helpful in the differential diagnosis in difficult cases<sup>[8]</sup>.

Shields *et al*<sup>[9]</sup> have classified the Coats' disease into 5 stages as follows: only retinal telangiectasia in stage 1; telangiectasia and exudation in stage 2 (2A:extrafoveal exudation; 2B:foveal exudation); exudative retinal detachment (RD) in stage 3 (3A:subtotal RD; 3B:total RD); total RD with glaucoma in stage 4; and advanced end-stage disease defined as stage 5. This classification seems to be helpful for the therapeutic management and for prediction of prognosis.

## TREATMENT

There are several treatment modalities for the Coats' disease, depending on the disease stage during the initial presentation. The primary objective is to obliterate the abnormal vasculature and eradicate the nonperfused retinal areas. This management aims at reducing the exudation and capillary dropout and thereby preserving the vision (Figure 2 a,b,c,d).

Shields *et al*<sup>[10]</sup> proposed a stepwise therapy approach according to their classification:

Patients in stage 1 can be followed conservatively or abnormal vessels can be treated by photocoagulation.

Stage 2 disease should be managed with cryo- and/or laser ablation depending on the severity and localisation.

Cryotherapy is preferable in stage 3 if the detachment is shallow. Surgical reattachment may be required if the retina is bullously detached.

In stage 4, eyes are with ocular pain due to glaucoma and enucleation can be required.

In Stage 5, eyes are generally blind but comfortable and don't require aggressive treatment.

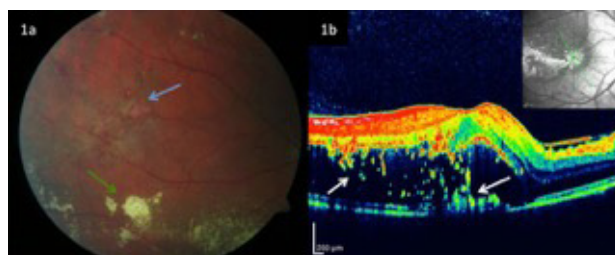
In the last decade, intravitreal pharmacotherapy played an important role in ophthalmic practice. Vascular endothelial growth factor inhibitors and corticosteroids are established treatment options in many retinal vascular diseases, like diabetic retinopathy and retinal vein occlusion.

On the other hand, retinopathy of prematurity (ROP) is the most common retinal vascular disorder in childhood. And especially in this field, VEGF inhibitors have come widespread in use<sup>[11,12]</sup>. However, there are significant concerns regarding their long-term safety<sup>[13,14]</sup>.

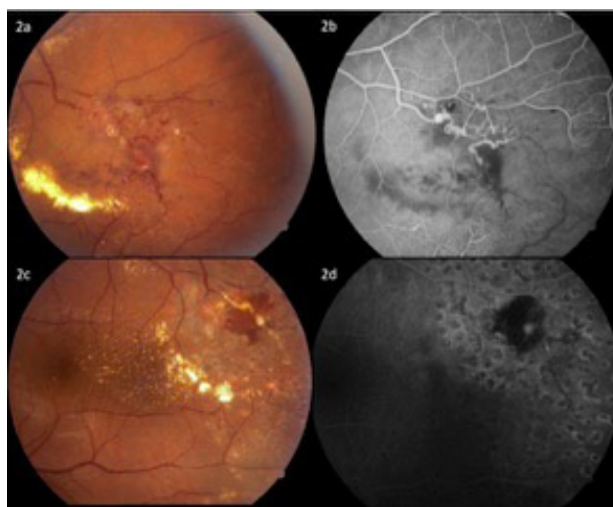
This study reviews the therapeutic value of intravitreal agents used as an adjunctive therapeutic option in Coats' disease.

## VEGF INHIBITORS (BEVACIZUMAB, RANIBIZIMAB, PEGAPTANIB, AFLIBERCEPT)

Vascular endothelial growth factor is one of the most important intraocular angiogenic cytokines, which influences the vascular permeability<sup>[15]</sup>. Markedly elevated VEGF levels were measured in Coats' disease. He *et al*<sup>[16]</sup>, analysed the VEGF levels from subretinal



**Figure 1** a: Color fundus photography of a 20-year-old male patient with Coats' disease in stage 2B (right eye), showing the retinal telangiectasia (blue arrow) and yellow subretinal exudates (green arrow). b: Oblique Axial OCT-image showing the severe serous retinal detachment and irregular hyperreflectivity corresponding to subretinal exudates (white arrows).



**Figure 2** a: Pretreatment color fundus picture of a 35-year-old male, who was treated with a single session of laser photocoagulation. Teleangiectasia, sausage-like calibre variations, subretinal yellow exudations are seen. b: Fundus fluorescein angiography, showing the lightbulb hyperfluorescence and large areas of retinal nonperfusion. c and d: Posttreatment appearance; occluded teleangiectasia, scattered laser scars and partial resorption of subretinal exudates.

fluid in patients with Coats' disease and compared it with the eyes with rhegmatogenous retinal detachment. Mean intraocular VEGF level in eyes with Coats' disease was 2,394.5 pg/mL, compared to 15.3 pg/mL in eyes with rhegmatogenous retinal detachment. In one of these cases with stage 2B Coats' disease intravitreal bevacizumab was administered, which provided a significant reduction in macular edema and VEGF level, while visual acuity was also improved. Kase *et al*<sup>[17]</sup> analyzed VEGF and VEGF-receptor (VEGFR) expression in enucleated eyes with Coats' disease. They found a significant immunoreactivity for VEGF and VEGFR-2 in macrophages and endothelia of abnormal vessels, where VEGFR-1 and VEGFR-3 were not expressed. A relatively larger and controlled study by Zhao *et al*<sup>[18]</sup>, also revealed a correlation between VEGF level in aqueous humour and disease severity.

A few anecdotal case reports showed some promising clinical results with the use of anti-VEGFs. Sun *et al*<sup>[19]</sup>, reported of a 2-year-old boy with stage 4 Coats' disease, who had undergone an unsuccessful scleral buckle surgery with cryotherapy. A dramatic response was obtained after two intravitreal pegaptanib injections. The pre-treatment VEGF concentration in aqueous humour was 908 pg/ml and reduced to 167 pg/mL after the treatment. Kaul *et al*<sup>[20]</sup>, reported a similar good outcome with pegaptanib as an adjunctive treatment after laser photocoagulation and cryotherapy in a 16-year-old girl.

The most commonly used VEGF inhibitor in Coats' disease is bevacizumab, a whole VEGF antibody. Table 1 gives a summary of the previous publications on bevacizumab and ranibizumab in Coats' disease. In a recent retrospective case series by Villegas *et al*<sup>[21]</sup>, treatment outcomes of 24 children with Coats' disease were discussed. All 24 children received intravitreal bevacizumab injections (mean 4,6; range 2-9 number) and laser treatment (mean 7,4; range 3-15 sessions) during a mean follow-up of 22,4 months. With a relatively standardized treatment protocol they achieved a complete resolution of exudative retinal detachment with anatomic improvement in all 24 children. No case of neovascular glaucoma was noted and thereby no enucleation was required. Unfortunately, the clinical staging and functional outcomes were not given in this work. Ray *et al*<sup>[22]</sup>, reviewed the clinical course of their treated children with Coats' disease over the last decade. Ten patients who received adjuvant intravitreal bevacizumab were compared with 10 severity-matched patients treated only with ablative therapy. All patients in the bevacizumab group were successfully treated, while the ablative therapy failed in two patients of the control group and even one of these required enucleation. Zheng *et al*<sup>[23]</sup>, reported the treatment outcomes of 14 paediatric and five adult patients with Coats' disease. Most of them were in stage 3A and 3B. All patients were initially treated with a single dose of intravitreal bevacizumab. Follow-up treatments, such as laser photocoagulation, cryotherapy, surgery, and reinjection of bevacizumab, were performed as needed. After a follow-up of at least 6 months, all of the paediatric patients showed a resolution of subretinal fluid and exudation, and regression of the telangiectasia. No patient experienced an ocular or systemic adverse event attributable to the intravitreal bevacizumab administration. Fibrotic vitreoretinal changes were present in two adult patients at the initial presentation even before the intravitreal treatment.

Increase in tractional forces was observed following the intravitreal anti-VEGF injections in other retinal vascular diseases<sup>[24-26]</sup>. Jonas *et al*<sup>[24]</sup> suggested that this is probably related to the involution of neovascular tissue due to rapid decrease of VEGF levels. After evaluating their data, Ramasubramanian and Shields<sup>[27]</sup> suggested to be prudent in the use of bevacizumab in patients with Coats' disease. Their retrospective case series comprised of 8 children, who were treated with adjunctive intravitreal bevacizumab in addition to cryotherapy ( $n=8$ , 100%) and laser photocoagulation ( $n=4$ , 50%). They observed vitreoretinal fibrosis in the 4 patients (50%), which was not present initially. To the best to our knowledge this is the only paper reporting a high rate of vitreoretinal fibrosis in eyes with Coats' disease. It should be taken into account that all patients in this series were treated with at least one cryotherapy session. Thereby, the role of intravitreal anti-VEGF causing an increase in the traction seems to be still somewhat uncertain.

Experience with ranibizumab is limited in Coats' disease when compared to bevacizumab (Table 1). In the largest published case series, Gaillard *et al*<sup>[28]</sup> treated 9 patients with severe Coats' disease in stage 3B (5 eyes) and stage 4 (4 eyes) with adjunctive intravitreal ranibizumab in addition to conventional ablative therapy. They observed a progressive retinal reattachment in all cases on an average of 2 months after the injection, which facilitated further treatments, like cryotherapy and laser photocoagulation. In two third of these patients a single intravitreal ranibizumab injection was sufficient (mean: 1,77 inj.; range: 1-4). Despite the relatively advanced presenting stage, anatomical success could be achieved in 8 of 9 patients, showing a similar positive effect as bevacizumab without any systemic adverse event. These eyes developed no late recurrence during a mean follow-up of 50 months.

The temporary effect of VEGF inhibitors should be considered, too. Several studies demonstrated later ROP recurrences, treated with intravitreal VEGF antibodies alone, compared to conventional laser therapy in ROP<sup>[29,30]</sup>. Unlike ROP, ablative treatments cannot be waived in Coats' disease. Nevertheless it remains uncertain, whether VEGF antibodies can induce late recurrences in Coats' disease, because the present comparative studies did not focus on this aspect. However it should be taken into account and experience should be expanded, accordingly.

Aflibercept, a recombinant fusion protein with a VEGF-binding portion, has prevailed in treatment of retinal diseases<sup>[31]</sup>. To the best of our knowledge, there are currently no published reports on the use of aflibercept in children, neither with Coats' disease, nor with ROP. In a preclinical study by Tokunaga *et al*<sup>[32]</sup>, aflibercept was used in a mouse model of oxygen-induced retinopathy. They found that Aflibercept is effective at regressing neovascularization, but they observed increased areas of avascular retina and corresponding decreased electroretinographic amplitudes. Today aflibercept remains to be studied carefully as an appropriate anti-VEGF agent, before of clinical application in children.

## CORTICOSTEROIDS (TRIAMCINOLONE ACETONIDE, DEXAMETHASONE IMPLANT)

Corticosteroids influence the vascular permeability with their anti-inflammatory properties. By downregulation of local cytokines and chemokines they can fix the permeability of the outer blood-retinal barrier and promote the resorption of exudation. Thereby they found a niche in the treatment armamentarium of retinal vascular diseases<sup>[33-35]</sup>.

Triamcinolone acetonide was the first corticosteroid used intravitreally in Coats' disease. Bergstrom *et al*<sup>[36]</sup>, treated 5 children with Coats' disease in stage 3A and 3B with an initial 4mg intravitreal Triamcinolone (IVTA) injection and ablative cryotherapy 4 weeks to 4 month after injection. The success in reduction of subretinal fluid was overshadowed by the high rates of intraocular pressure rise (4/5; 80%) and cataract formation (3/5; 60%). Three patients subsequently developed inoperable rhegmatogenous retinal detachments with severe proliferative vitreoretinopathy. Finally, only one of the five patients had a reattached retina without a dense cataract and with a post treatment visual acuity of 1/200.

On the contrary to this report, Othman *et al*<sup>[37]</sup> achieved significant visual improvement in 14 of 15 cases with stage 3 Coats' disease, who were treated with intravitreal triamcinolone in combination with other treatment modalities, such as laser photocoagulation and/ or cryotherapy. Nevertheless cataract developed in 5 patients aged between 1 and 4 years. However the follow-up was only 12 months in 4 children, which was relatively short to determine the final outcome.

A different approach, regarding the use of IVTA, was described by Ghazi *et al*<sup>[38]</sup>. They suggested IVTA as a single alternative to surgical drainage, rather than an adjuvant treatment option. In their case series comprised of 4 children with Coats' disease in stage 3-4, they report an almost total resolution of subretinal fluid with a single IVTA injection. No comments were made about complications, perhaps due to the short follow-up.

Previous reports on the management of Coats' disease with adjunctive IVTA seems to be associated with fast resorption of subretinal fluid, so that the retina is more accessible to further ablative treatments. Unfortunately, the high risk of cataract and glaucoma should be the mishaps and long-term follow-up of these patients is mandatory.

Table 1 Examples of drugs incorporated in SILN or NLC, used lipid, surfactant and preparation method.

Author / Year	Study design	Number of eyes	Mean age	Disease Stage	Number of IVI	Intervention	Anatomic success	Functional results (BCVA)	Follow-up (months)
Venkatesh et al[45] (2008)	Case series	2	15 years	2-2	1-1	IV Bevacizumab>Laser photocoagulation (after 6 weeks)	Stabilization of the disease	HM; 20/800	12
Alvares-Rivera et al[46] (2008)	Case report	1	10 years	2	1	IV Bevacizumab alone	Reduction of subretinal fluid and redistribution of the exudates	CF at 1m	n.a.
Entezari et al[47] (2009)	Case report	1	13 years	2	3	3 consecutive iv Bevacizumab inj. with 6-weeks interval	Significant reduction of macular edema and exudation, partial regression of peripheral vascular lesions	20/20	12
Kaul et al[20] (2010)	Case series	2	7; 2 years	3B; 3B	1-1	1) SRF drainage+SF6 injection+iv Bevacizumab 2) External needle drainage of the SRF and laser photocoagulation followed by injection of SF6 and intravitreal bevacizumab	1) Reattachment of the retina and reduction of telangiectasia and exudation 2) Marked improvement in the retinal exudation and telangiectasia with reattachment of the posterior pole	CF at 2m	6
Zhao et al[18] (2010)	Case report	1	3 years	3B	4	iv Bevacizumab alone	Anatomical success with decrease of subretinal exudates and fluid	20/125	10
Ramasubramanian, et al[27] (2011)	Case series	8	88 months	1-5	1-4 (mean:1.75)	IV Bevacizumab (%100; n=8) + cryotherapy (%100; n=8)+laser (%50; n=4)	Resolution of retinopathy (n=8, 100%), Resolution of SRF (n=8, 100%), Resolution of retinal exudation (n=6, 75%), Vitreous fibrosis (n=4, 50%)	n.a.	n.a.
Ray et al[22] (2012)	Case series	10	15.4 months	n.a.	1-3 (mean: 2.5)	IV Bevacizumab+cryotherapy (n=9) ±laser (n=4)	Resolved exudative detachment in all cases (n:10)	n.a.	15.4
Lin et al[48] (2013)	Case series	6	7 years	2B-3B	1-4	IV Bevacizumab monthly until the SRF completely resorbed+Laser/cryotherapy	Resolution of subretinal exudation (5/6)	LP -0,8	48
Raouf et al[49] (2013)	Case report	1	34 years	2A	2	IV Bevacizumab+ Pascal laser photocoagulation	Complete regression	1.2	12
Zheng et al[23] (2013)	Case series	14 children, 5 adults	6,9 years (children), 33,6 years (adults)	2-3B	1-5	initial IV Bevacizumab ±laser± cryotherapy±surgery	Resolution of SRF and exudation, and regression of the telangiectasia (n=19)	Significant improvement in children	6
Villegas et al[21] (2014)	Case series	24	62 months	n.a.	4.6	IV Bevacizumab+laser photocoagulation (in all cases)	Resolution of exudative retinal detachment, ablation of vascular telangiectasia, and anatomic improvement of the retina (n=24)	n.a.	22.4
Kodama et al[50] (2014)	Case series	2	13 years	3A, 3A	1.1	Initial laser photocoagulation, IV Bevacizumab+laser during recurrence	Resolution of serous retinal detachment	1.0 and 0.7	12
Florentzis et al[51] (2015)	Case report	1	22 months	3A	6	IV Bevacizumab+cryotherapy+laser	Retinal reattachment, resolution of subretinal exudates	0,8	28
Gaillard et al[28] (2014)	Case series	9	13 months	3B-4	1-4	IV Ranibizumab +laser +cryotherapy	Globe survival with anatomical success in 8 of the 9 eyes	no LP - 0.063	50
Lin et al[48] (2013)	Case report	1	9 years	2B	4	4xIV Ranibizumab, 1x IV Bevacizumab, 1xcryotherapy, 7xlaser	Retinal reattachment, resolution of subretinal exudates	0.8	14
Teh et al[52] (2014)	Case report	1	20 years	2B	1	1xIV Ranibizumab+1xcryotherapy+1xlaser	Reduction in telangiectatic vessels and resorption of intraretinal and subretinal exudates	0.1	2

IV: intravitreal; n.a.: not available; LP: light perception; CF: counting finger; IVI: intravitreal injection; SRF: subretinal fluid; ±: combination treatments with different medications were excluded.

**Table 2 Summary of reports on intravitreal triamcinolone and Ozurdex in Coats' disease.**

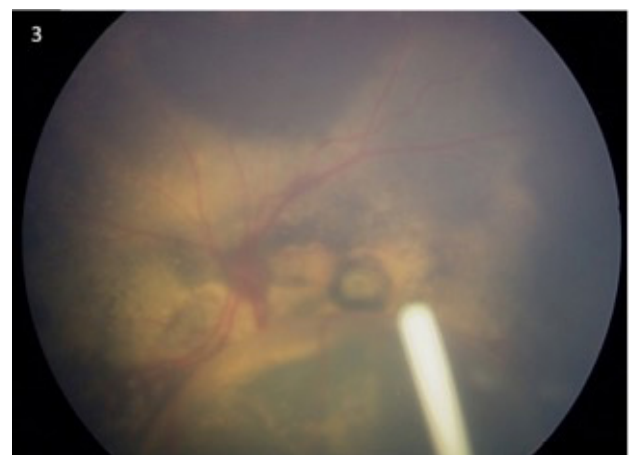
Triamcinolone acetamide										
Author / Year	Study design	Number of eyes	Mean age	Disease Stage	Number of IVI	Intervention	Outcome	Functional results (BCVA)	Adverse events	Follow-up (months)
Bergstrom et al[36] (2008)	Case series	5	6.4 years	3B	1	Initial 4mg IVTA; cryotherapy 1 month to 4 months after IVTA (4/5; %80) injection. Cryotherapy at the same time as of IVTA injection in 1 case.	Retinal reattachment in 2 of 5 cases.	NLP-1/200	IOP rise (4/5; 80%) Cataract (3/5; 60%)	12.6
Ghazi et al[38] (2008)	Case series	4	3.25 years	3B-4	1-2	Initial 1-4mg IVTA injection following laser photocoagulation.	Almost total resolution of SRF within 4 weeks following a single injection.	n.a.	No short term complications	< 6
Kimura et al[53] (2009)	Case report	1	32 years	1	2	Laser photocoagulation, afterwards IVTA 4 mg	Resolution of macular edema.	20/50	None	28
Othman et al[37] (2009)	Case series	15	4.3 years	3A, 3B	1	Initial 4 mg IVTA combined with SRF drainage (6/15; %40); Peripheral laser ablation and or cryotherapy 4 weeks after IVTA (13/15; %87). Pars plana vitrectomy in 1 case (%7).	Significant reduction of macular edema and exudation, partially regression of peripheral vascular lesions.	LP-6/60	IOP rise (1/15; %7); cataract formation (5/15; %33)	34 (12-61)
<b>Ozurdex implant</b>										
Martinez-Castillo et al[43] (2012)	Case report	1	46 years	3B	1	Ozurdex implant, afterwards 3 consecutive laser sessions with 15-day intervals.	Complete resolution of the exudative retinal detachment.	20/25	n.a.	12
Saatci et al[44] (2013)	Case report	1	7 years	3A	1	Simultaneous intravitreal Ozurdex implantation and indirect laser photocoagulation.	Retinal reattachment, gradual resolution of macular exudates.	0.1	Transient pressure rise	6

NLP: light perception; LP: light perception, IVTA: intravitreal triamcinolone acetamide, IVI: intravitreal injection; SRF: subretinal fluid, n.a.: not available; IOP: intraocular pressure. \*Combination treatments with different medications were excluded.

Ozurdex (Allergan Inc., Irvine, CA, USA) is a biodegradable dexamethasone sustained-release intravitreal implant delivering 0.7 mg of potent preservative-free dexamethasone directly within the vitreous cavity. It is approved by the FDA for the use of macular edema associated with retinal vein occlusion, noninfectious posterior uveitis and diabetic maculopathy<sup>[34,25,39]</sup>. Because of its anti-inflammatory properties with a favourable side-effect, it became an important treatment option also in childhood eye diseases<sup>[40,41]</sup>.

Lei et Lam<sup>[42]</sup>, reviewed their treatment outcomes of 4 paediatric patients with macular edema, including a 4-year-old boy with Coats' disease. He was previously treated unsuccessfully with multiple laser sessions and repeated intravitreal bevacizumab injections. After three Ozurdex implantations the macular edema decreased and visual acuity slightly improved. During the follow-up of 65 months a significant lens opacification was observed. Intraocular pressure increased only after repeated implantations, which could be satisfactorily managed with topical IOP-lowering agents. Martinez-Castillo *et al*<sup>[43]</sup>, treated a patient with Coats' disease in adulthood, initially with Ozurdex implant and observed in already 1 week a complete resolution of the exudative retinal detachment, allowing further laser photocoagulation. One year after the Ozurdex implantation the patient gained a favourable visual outcome of 20/25, without any ocular complications.

Previously, we described two children with Coats' disease in stage 3A, where we used Ozurdex in addition to laser photocoagulation<sup>[44]</sup>. The first case, a 12-year-old boy was initially treated with 5 monthly ranibizumab injections in addition to two photocoagulation sessions. As subretinal exudation remained almost the same, we administered a single Ozurdex implantation, which contributed to resolution of the exudation. The second case was managed with indirect laser photocoagulation and a simultaneous intravitreal 0.7-mg dexamethasone implant injection. Macular exudates gradually resolved and visual acuity increased. In both cases a slight intraocular pressure rise was noted which was successfully managed with an antiglaucomatous medication. In view of these case reports, the Ozurdex implant seems to be an effective adjuvant treatment option, which can facilitate an effective ablative treatment, tighten the abnormal vessel structure and provide an acceleration of subretinal fluid resorption (Figure 3). As like with other corticosteroids, caution is advised regarding the potential risk for cataract development and intraocular pressure rise especially in young ages. The main benefit of this implant is that it requires fewer interventions in comparison to



**Figure 3** Retcam fundus image (Clarity Medical Systems, California/USA); left eye of a 12-year-old boy with stage 3A Coats' disease, who was treated with Ozurdex implant adjunctive to laser photocoagulation.

VEGF antibodies and requires less general anaesthesia in paediatric age. A summary of published case reports about steroids in Coats' disease is given in table 2.

To our best knowledge; two other sustained-release fluocinolone acetonide devices namely Retisert (Bausch & Lomb, Rochester, NY, USA), and Iluvien (Alimera Science, Alpharetta, GA, USA) have not been administered in Coats disease so far.

## CONCLUSION

Depending upon the clinical stage, several treatment modalities can be employed in patients with Coats' disease. The hallmark of the therapy is the ablative treatment techniques (photocoagulation and cryotherapy) wherever appropriate. On the other hand, intravitreal pharmacotherapy can be used as an adjunctive treatment to ablation in order to achieve faster resolution and better visual outcome. Initially, VEGF inhibitors would likely be preferred to steroids, because of unfavourable local adverse effects, like cataract or glaucoma.

Coming years will ascertain the place of intravitreal pharmacotherapy in Coats' disease.

## CONFLICT OF INTERESTS

The authors have no conflicts of interest to declare.

## REFERENCES

- Coats G. Forms of retinal disease with massive exudation. *R Lond Ophthalmic Hosp Rep* 1908;17:440-525.
- Shields JA, Shields CL, Honavar SG, Demirci H. Clinical variations and complications of Coats' disease in 150 cases: The 2000 Sanford Gifford memorial lecture. *Am J Ophthalmol* 2001;131:561-571.
- Orphanet Report Series (2015) Number 1, July 2015; Prevalence and incidence of rare diseases. Available from [http://www.orpha.net/consor/cgibin/OC\\_Exp.php?Lng=GB&Expert=190](http://www.orpha.net/consor/cgibin/OC_Exp.php?Lng=GB&Expert=190)
- Black GC, Perveen R, Bonshek R, et al. Coats' disease of the retina (unilateral retinal telangiectasis) caused by somatic mutation in the NDP gene: a role for norrin in retinal angiogenesis. *Hum Mol Genet* 1999;8:2031-2035.
- Fernandes BF, Odashiro AN, Maloney S, et al. Clinical histopathological correlation in a case of coats' disease. *Diagn Pathol* 2006;1:24.
- Berk TA, Oner HF, Saatci AO. Underlying pathologies in secondary strabismus. *Strabismus* 2000;8:69-75.
- Mulvihill A, Morris B. A population-based study of Coats disease in the United Kingdom II: investigation, treatment, and outcomes. *Eye (Lond)* 2010;24:1802-1807.
- Saatci AO, Tekin NF, Saatci I, Memisoglu B, Kavukcu S. Coats' disease and calcification: a case report. *Metab Pediatr Syst Ophthalmol* 1996-1997;19-20:21-22.
- Shields JA, Shields CL, Honavar SG, Demirci H, Cater J. Classification and management of Coats disease. The 2000 Proctor Lecture. *Am J Ophthalmol* 2001;131:572-583.
- Shields JA, Shields CL. Review: Coats disease: the 2001 Luescher T. Mertz lecture. *Retina* 2002;22:80-91.
- Stahl A, Göpel W. Screening and Treatment in Retinopathy of Prematurity. *Dtsch Arztebl Int.* 2015;112:730-735.
- Hwang CK, Hubbard GB, Hutchinson AK, Lambert SR. Outcomes after Intravitreal Bevacizumab versus Laser Photocoagulation for Retinopathy of Prematurity: A 5-Year Retrospective Analysis. *Ophthalmology* 2015;122:1008-1015.
- Mititelu M, Chaudhary KM, Lieberman RM. An evidence-based meta-analysis of vascular endothelial growth factor inhibition in pediatric retinal diseases: part 1. Retinopathy of prematurity. *J Pediatr Ophthalmol Strabismus.* 2012;49:332-340.
- Klufas MA, Chan RV. Intravitreal anti-VEGF therapy as a treatment for retinopathy of prematurity: what we know after 7 years. *J Pediatr Ophthalmol Strabismus.* 2015;52:77-84.
- Chaudhary KM, Mititelu M, Lieberman RM. An evidence-based review of vascular endothelial growth factor inhibition in pediatric retinal diseases: part 2. Coats' disease, best disease, and uveitis with childhood neovascularization. *J Pediatr Ophthalmol Strabismus* 2013;50:11-19.
- He YG, Wang H, Zhao B, Lee J, Bahl D, McCluskey J. Elevated vascular endothelial growth factor level in Coats' disease and possible therapeutic role of bevacizumab. *Graefes Arch Clin Exp Ophthalmol.* 2010;248:1519-21.
- Kase S, Rao NA, Yoshikawa H, et al. Expression of vascular endothelial growth factor in eyes with Coats' disease. *Invest Ophthalmol Vis Sci* 2013;54:57-62.
- Zhao Q, Peng XY, Chen FH, Zhang YP, Wang L, You QS, Jonas JB. Vascular endothelial growth factor in Coats' disease. *Acta Ophthalmol* 2014;92:e225-8.
- Sun Y, Jain A, Moshfeghi DM. Elevated vascular endothelial growth factor levels in Coats disease: rapid response to pegaptanib sodium. *Graefes Arch Clin Exp Ophthalmol* 2007;245:1387-1388.
- Kaul S, Uparkar M, Mody K, Walinjar J, Kothari M, Natarajan S. Intravitreal anti-vascular endothelial growth factor agents as an adjunct in the management of Coats' disease in children. *Indian J Ophthalmol* 2010;58:76-78.
- Villegas VM, Gold AS, Berrocal AM, Murray TG. Advanced Coats' disease treated with intravitreal bevacizumab combined with laser vascular ablation. *Clin Ophthalmol* 2014;8:973-976.
- Ray R, Barañano DE, Hubbard GB. Treatment of Coats' disease with intravitreal bevacizumab. *Br J Ophthalmol* 2013;97:272-277.
- Zheng XX, Jiang YR. The effect of intravitreal bevacizumab injection as the initial treatment for Coats' disease. *Graefes Arch Clin Exp Ophthalmol* 2014;252:35-42.
- Jonas JB, Schmidbauer M, Rensch F. Progression of tractional retinal detachment following intravitreal bevacizumab. *Acta Ophthalmol.* 2009;87:571-572.
- Krishnan R, Goverdhan S, Lochhead J. Intravitreal pegaptanib in severe proliferative diabetic retinopathy leading to the progression of tractional retinal detachment. *Eye* 2009;23:1238-1239.
- Arevalo JF, Maia M, Flynn HW Jr, Saravia M, Avery RL, Wu L. Tractional retinal detachment following intravitreal bevacizumab (Avastin) in patients with severe proliferative diabetic retinopathy. *Br J Ophthalmol* 2008;92:213-216.
- Ramasubramanian A, Shields CL. Bevacizumab for Coats' disease with exudative retinal detachment and risk of vitreoretinal traction. *Br J Ophthalmol.* 2012;96:356-359.
- Gaillard MC, Mataftsi A, Balmer A, Houghton S, Munier FL. Ranibizumab in the management of advanced Coats disease Stages 3B and 4: long-term outcomes. *Retina* 2014;34:2275-2281.
- Mintz-Hittner HA, Kennedy KA, Chuang AZ; BEAT-ROP Cooperative Group. Efficacy of intravitreal bevacizumab for stage 3+ retinopathy of prematurity. *N Engl J Med* 2011;364:603-615.
- Hu J, Blair MP, Shapiro MJ et al. Reactivation of retinopathy of prematurity after bevacizumab injection. *Arch Ophthalmol* 2012;130:1000-1006.
- Diabetic Retinopathy Clinical Research Network. Aflibercept, bevacizumab, or ranibizumab for diabetic macular edema. *N*