

Phacoemulsification in the Case of Colobomatous Macrophtalmos with Microcornea Syndrome

Kemal Tekin, Cagri Ilhan, Mustafa Koc, Pelin Yilmazbas, Murat Uzel

Kemal Tekin, Cagri Ilhan, Murat Uzel, Ankara Ulucanlar Eye Research Hospital, Ankara, Turkey

Mustafa Koc, Department of Corneal Diseases, Ankara Ulucanlar Eye Research Hospital, Ankara, Turkey

Pelin Yilmazbas, Department of Retinal Diseases, Ankara Ulucanlar Eye Research Hospital, Ankara, Turkey

Correspondence to: Kemal Tekin, MD, Ulucanlar Eye Research and Education Hospital, Ankara, 06240, Turkey.

Email: Kemal_htepe@hotmail.com

Telephone: +90 312 312 62 61 Fax: +90 312 312 48 27

Received: October 15, 2015 Revised: December 12, 2015

Accepted: December 16, 2015

Published online: December 29, 2015

globe and myopia is a very rare condition and cataract surgery in these eyes has some difficulties compared to normal eyes.

© 2015 ACT. All rights reserved.

Key words: Phacoemulsification; Macrophtalmos; Microcornea

Tekin K, Ilhan C, Koc M, Yilmazbas P, Uzel M. Phacoemulsification in the Case of Colobomatous Macrophtalmos with Microcornea Syndrome. *International Journal of Ophthalmic Research* 2015; 1(3): 86-89 Available from: URL: <http://www.ghrnet.org/index.php/ijor/article/view/1418>

ABSTRACT

Purpose: To report phacoemulsification surgery in a case of colobomatous macrophtalmos with microcornea syndrome. **Case report:** A 72-year-old male presented with complaints of low vision was evaluated. Biomicroscopic examination of anterior segment revealed cataract and microcornea for both eyes and the finding of microcornea was confirmed by Pentacam HR (Oculus). Dilated fundus examination of left eye revealed retinochoroidal and optic nerve coloboma in the lower half and ultrasonography of the right eye showed that retina was attached but the axial length was more than normal. Phacoemulsification and intraocular lens implantation were planned for the patient who was considered to be colobomatous macrophtalmos with microcornea syndrome accompanied by cataract. Ultrasound bio-microscopy (UBM) could not be performed because of the patient's narrow interpalpebral rim and non-cooperation. Uneventful phacoemulsification was applied to the patient under topical anesthesia. However because of advanced zonular dialysis, intraocular lens implantation could not be performed. **Conclusion:** Colobomatous macrophtalmos with microcornea syndrome which is characterized by microcornea, retinochoroidal coloboma, increased axial length of the

INTRODUCTION

Coloboma which arises due to the closure defect of fetal embryonic fissure is mostly seen as sporadic cases. It is usually located at the inferior nasal quadrant and can affect lens, uveal tissue, retina and optic nerve. Visual acuity is variable according to the status of macula and papillomacular nerve fiber bundle. More than half of the cases are bilateral. The other findings that are associated with coloboma are astigmatism, microphtalmia, microcornea, iris/cilium body coloboma, choroidal detachment, persistent fetal vascularization, retinal dysplasia, retinoschisis and retinal detachment^[1].

Colobomatous macrophtalmos with microcornea syndrome which is characterized by microcornea, retinochoroidal coloboma, increased axial length of the globe and myopia is a very rare condition, it is mostly inherited in autosomal dominant pattern with variable expression^[2,3]. This syndrome may be accompanied by cornea plana, iridocorneal angle anomalies, shallow anterior chamber and increased intraocular pressure^[4].

In this case report, we aimed to share methods and results of cataract surgery of the patient with colobomatous macrophtalmos with microcornea syndrome.

CASE REPORT

Seventy-two year old male patient presented with complaints of low vision in the right eye. He told that he had the complaint of low vision since childhood but there was significant decrease in visual acuity in recent months. There wasn't any important feature in the patient's background and family history. The best corrected visual acuity according to Snellen chart was hand motion at 1 feet (20/1250) in the right eye and 20/100 in the left eye. Intraocular pressures measured by Goldmann applanation tonometry were within the normal limits in both eyes. Biomicroscopic examination of anterior segment revealed microcornea 9.5mm × 10mm (vertical diameter was measured 9,5 mm, horizontal diameter was measured 10 mm by slit lamp of the biomicroscope), iris coloboma at inferior quadrant, phacodonesis and grade 4 cataract according to the lens opacities classification system III in the right eye (Figure 1). Microcornea 9,5mm × 10mm and grade 2 nuclear cataract were also detected in the left eye, but iris coloboma wasn't observed in this eye. Because posterior segment of right eye wasn't seen in the dilated fundus examination, A-scan and B-scan orbital ultrasonographies were performed. Ultrasonography of the right eye showed that retina was attached but the axial length was longer than normal. Dilated fundus examination of left eye revealed retinochoroidal and optic nerve coloboma in the lower half. White to white distance were measured 10 mm by Pentacam HR (Oculus) in both eyes and microcornea suspicion was confirmed (Figure 2). Optical coherence tomography (Spectralis OCT, Heidelberg Engineering) which was applied in order to study for subclinical detachment confirmed optic nerve and retinal coloboma however,

subretinal and/or intraretinal fluid weren't detected in the left eye (Figure 3).

Phacoemulsification and intraocular lens implantation were planned for the patient who was considered to be colobomatous macrophtalmos with microcornea syndrome accompanied by cataract. Axial length was measured 30,58 mm in the right eye by using A-scan ultrasonography and 25,98 mm in the left eye by using LS-900 Lenstar (Haag-Streit, Swiss) preoperatively. Intraocular lens (IOL) power of the right eye was calculated -0,50 diopters according

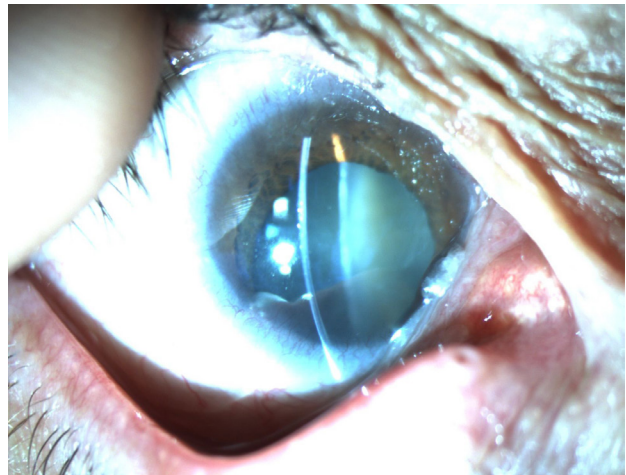


Figure 1 Preoperative colored photograph of the right eye shows that microcornea, iris and lens coloboma at inferior quadrant and accompanying cataract.

OCULUS - PENTACAM

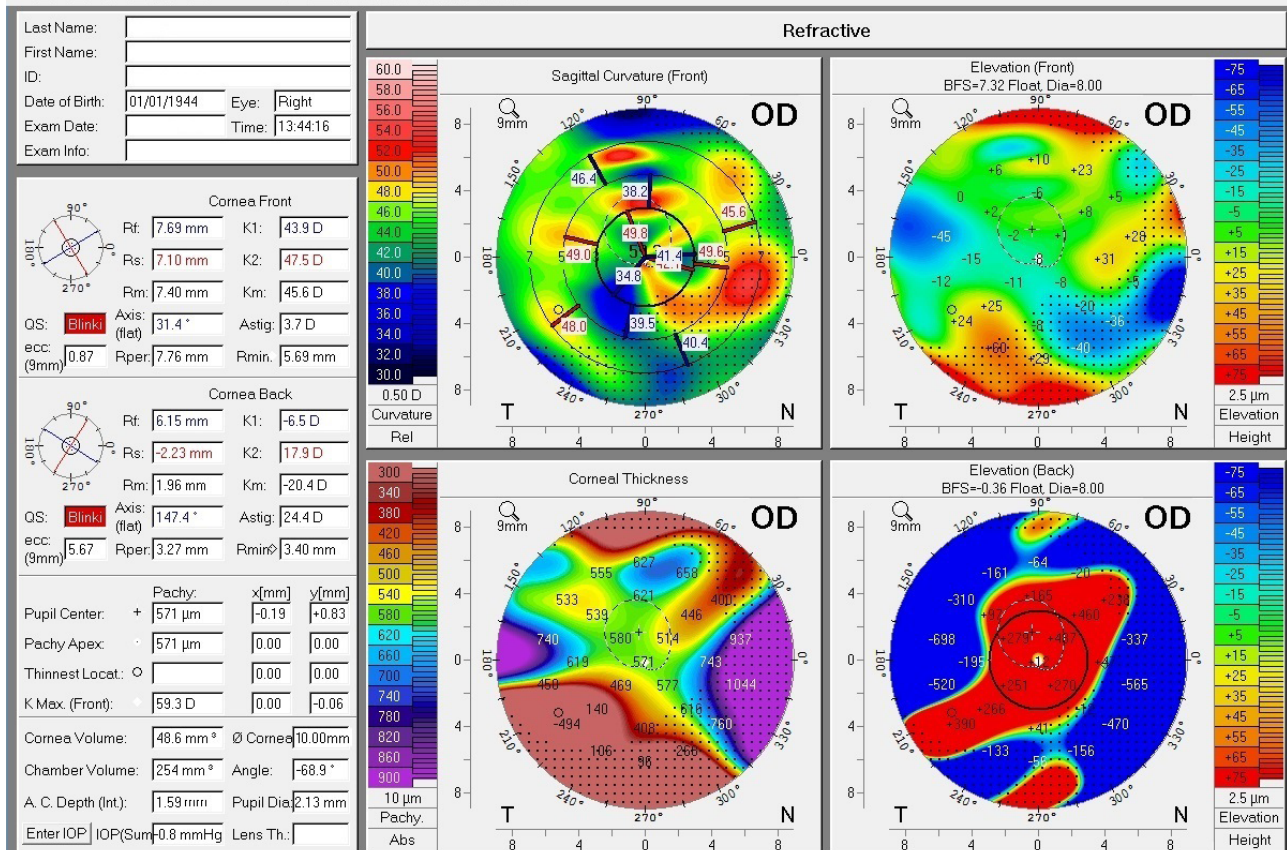


Figure 2 Pentacam HR of the right eye reveals that irregular astigmatism, microcornea and decreased anterior chamber depth and chamber volume.

to SRK/T formula. Ultrasound bio-microscopy (UBM) could not be performed preoperatively because of the patient's narrow interpupillary rim and non-cooperation. Written informed consent was obtained from the patient and uneventful phacoemulsification was applied under topical anesthesia. However because of advanced zonular dialysis, IOL implantation could not be performed. On the first postoperative day, uncorrected visual acuity according to Snellen chart was 20/200 and fundus examination revealed retinochoroidal coloboma and optic nerve coloboma (Figure 4). Because of uncorrected visual acuity according to Snellen chart was 20/50 and anterior segment examination was uneventful on first month control, secondary IOL implantation was not planned (Figure 5).

DISCUSSION

The close relationship between uveal and optic nerve colobomas with microcornea and microphtalmia is known^[5]. However coexistence of macroftalmia with coloboma is a very rare condition. For the first time in 1984, Bateman *et al*^[2] mentioned colobomatous macrophthalmos with microcornea syndrome. They described this syndrome by the combination of microcornea (the most extensive corneal diameter is less than or equal to 10 mm), uveal coloboma (iris, choroid, retina and/or optic nerve head can be affected), an increase in axial length of globe and myopia. The findings of our case are fully compatible with this syndrome. In addition Bateman *et al*^[2] reported case series showing autosomal dominant inheritance, while sporadic cases have also been reported such as in our case^[6].

Cataract and retinal detachment are one of the most frequent ocular pathologies showing coexistence with coloboma^[7]. The separation of membrane which is located on colobomatous area and liquefied vitreous spread into the subretinal space from there are thought to develop retinal detachment. The relative coloboma excavation is described by calculating the ratio of the depth of coloboma to the axial length and increased risk of retinal detachment has been reported in cases that this ratio is over 0.15%^[7]. The subclinical detachments can be revealed by the method of optical coherence tomography in these cases^[8]. OCT was done to rule out accompanying subclinical detachment in our case and detachment was not observed.

Phacoemulsification in eyes with coloboma is more problematic compared to normal eyes. In these cases, zonular dialysis, phacodonesis, poor pupillary dilatation, capsular laxity can be observed and can be faced with difficulty in capsulorhexis due to these findings^[9]. In the study of Khokhar *et al*^[9], they placed the intraocular lens in 19 of 22 (86%) cases which had only choroid coloboma despite the difficulties at the stage of surgery, while intraocular lens implantation could not be done in 3 of 6 cases which had coloboma accompanied by microcornea. In our case, IOL implantation could not be performed because of marked shallow anterior chamber and advanced zonular dialysis. However, because the calculated IOL power was low due to long axial length, in spite of aphakia he had relatively good visual acuity. There was only one case report similarly to our case which had colobomatous macrophthalmos accompanied by dense cataract and underwent to phacoemulsification surgery^[10]. In this case mentioned about, significant refractive deviation experienced after the surgery and necessitated IOL exchange was performed.

As far as we know, our case is the second case of colobomatous macrophthalmos with microcornea accompanied by dense cataract which underwent phacoemulsification procedure. It is the first case in which aphakia was preferred in the management of case and relatively significant improvement in visual acuity was obtained.

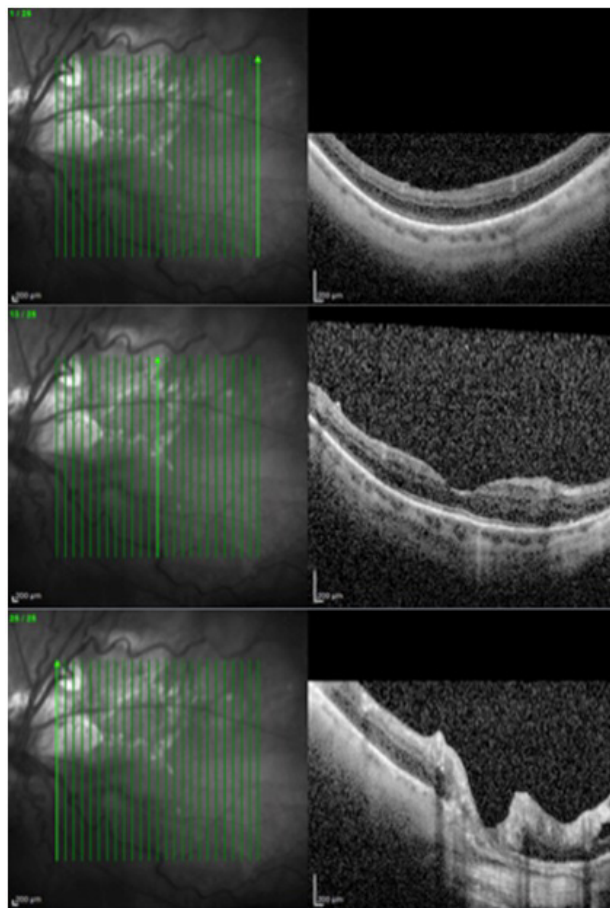


Figure 3 Optical coherence tomography reveals that retinochoroidal coloboma on the left eye.

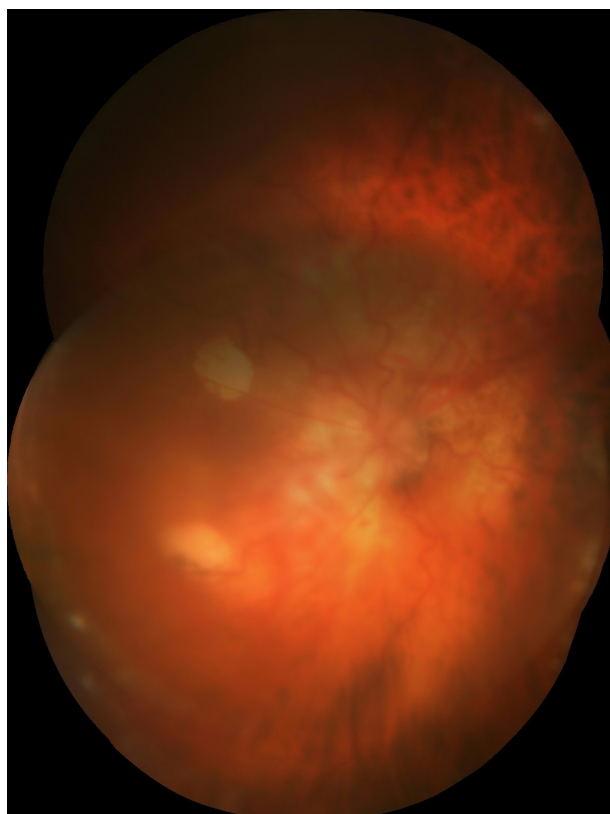


Figure 4 Colored fundus photograph of the right eye shows that retinochoroidal and optic nerve coloboma.

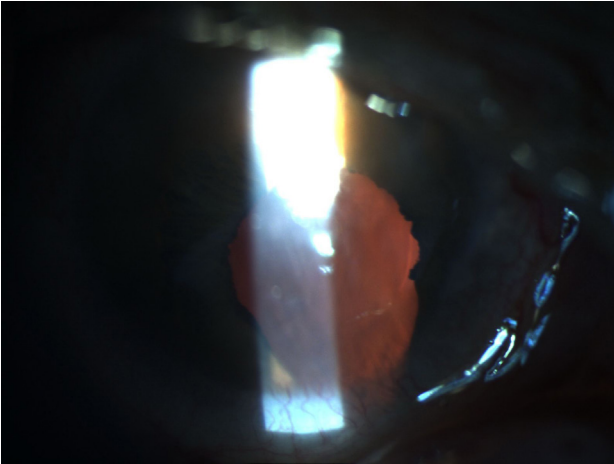


Figure 5 Anterior segment photograph of the right eye shows that clear cornea and uneventful anterior chamber with aphakia on first month control postoperatively.

CONFLICT OF INTERESTS

The authors have no conflicts of interest to declare.

REFERENCES

- 1 Nicholson B, Ahmad B, Sears JE. Congenital optic nerve malformations. *Int Ophthalmol Clin.* 2011; 51:49-76.
- 2 Bateman JB, Maumenee IH. Colobomatous macrophthalmia with microcornea. *Ophthalmic Paediatr Genet.* 1984; 4:59-66.
- 3 Pallotta R, Fusilli P, Sabatino G, Verrotti A, Chiarelli F. Confirmation of the colobomatous macrophthalmia with microcornea syndrome: report of another family. *Am J Med Genet.* 1998; 763:252-254.
- 4 Toker E, Elcioglu N, Ozcan E, Yenice O, Ogut M. Colobomatous macrophthalmia with microcornea syndrome: report of a new pedigree. *Am J Med Genet A.* 2003; 121: 25-30.
- 5 Hornby SJ, Adolph S, Gilbert CE, Dandona L, Foster A. Visual acuity in children with coloboma: clinical features and a new phenotypic classification system. *Ophthalmology.* 2000; 107:511-520.
- 6 Seung HK, Kim HK, Nam WH. A case of retinal detachment in colobomatous macrophthalmos with microcornea syndrome. *Korean J Ophthalmol.* 2009; 23:312-314.
- 7 Venincasa VD, Modi YS, Aziz HA, Ayres B, Zehetner C, Shi W, Murray TG, Flynn HW Jr, Berrocal AM. Clinical and Echographic Features of Retinochoroidal and Optic Nerve Colobomas. *Invest Ophthalmol Vis Sci.* 2015; 56:3615-3620.
- 8 Gopal L, Khan B, Jain S, Prakash VS. A clinical and optical coherence tomography study of the margins of choroidal colobomas. *Ophthalmology.* 2007; 114:571-580.
- 9 Khokhar S, Gupta S, Kusumesh R, Kumar G. Outcomes of phacoemulsification in eyes with congenital choroidal coloboma. *Graefes Arch Clin Exp Ophthalmol.* 2013; 25110:2489-2490.
- 10 Brannan SO, Kyle G. Bilateral microcornea and unilateral macrophthalmia resulting in incorrect intraocular lens selection. *J Cataract Refract Surg.* 1999; 257:10

Peer reviewer: Rahul Bhargava, Professor of Ophthalmology, Santosh Medical College, 1, Ambedkar Road, Ghaziabad, India.