

Steroids for Treatment of Retinal Vein Occlusion

Shwu Jiuan Sheu

Shwu Jiuan Sheu, Department of Ophthalmology, Kaohsiung Veterans General Hospital, Kaohsiung, Taiwan

Shwu Jiuan Sheu, School of Medicine, National Yang-Ming University, Taipei, Taiwan

Correspondence to: Shwu-Jiuan Sheu, MD, 386 Ta-Chung 1st Road, Department of Ophthalmology, Kaohsiung Veterans General Hospital, Kaohsiung, Taiwan.

Email: sjiuansheu@gmail.com

Telephone: +88673468217

Fax: +88673468054

Received: October 6, 2015

Revised: November 12, 2015

Accepted: November 15, 2015

Published online: March 28, 2016

ABSTRACT

Retinal vein occlusion (RVO) is the second most common retinal vascular disease in adults. In both types of RVO, macular edema (ME) is a major cause of visual impairment. Treatment modalities have improved substantially in recent years, from laser photocoagulation to intravitreal pharmacotherapy. The breakdown of blood-retinal barrier due to VEGF and inflammatory mediator plays an important role in the pathogenesis of ME. These pathways lead to the treatment by using anti-VEGF and corticosteroid. The outcomes of anti-VEGF therapy are unprecedented, but responses to treatment may vary and frequent injections are required. Corticosteroids have been used as a treatment strategy for ME secondary to RVO based on evidence revealing that inflammation plays a crucial role in RVO. This article will focus on a brief review on the use of corticosteroid on treatment of ME 2nd to RVO. Evidence available from prospective, multicenter clinical studies and from a selective literature search is reported.

© 2016 The Authors. Published by ACT Publishing Group Ltd.

Key words: Macular Edema; Retinal Vein Occlusion; Steroid

Sheu SJ. Steroids for treatment of Retinal Vein Occlusion. *International Journal of Ophthalmic Research* 2016; 2(1): 104-109 Available from: URL: <http://www.ghrnet.org/index.php/ijor/article/view/1459>

INTRODUCTION

Retinal vein occlusion (RVO) is the second most common retinal vascular disease in adults. The prevalence increases with age. RVO can be divided into two main types; the prevalence of branch RVO (BRVO) is approximately fivefold higher than that of central RVO (CRVO)^[1-2]. CRVO can be further classified into ischemic or nonischemic CRVO. In both types of RVO, macular edema (ME) is a major cause of visual impairment. The pathogenesis of ME secondary to RVO is complex; it is believed to be the result of both vascular alteration and an inflammatory process. Previous studies reported that several inflammatory mediators and cytokines, including angiotensin, prostaglandins, interleukins, VEGF, MCP-1, MMPs, ICAM1, and VCAM-1, were involved in the development of ME secondary to RVO. The major mediators were angiotensin II, VEGF and prostaglandins. Based on the current knowledge, inflammation is considered the primary response mechanism to mechanical damage in RVO, and VEGF expression occurs as a secondary mechanism. Both ischemic and inflammation can initiate VEGF production. VEGF production can simultaneously be induced by other factors and initiate a cascade of other factors^[3]. Both inflammation and vascular alterations interact to promote disease progression. Consequently, the process is self-propagating if patients are not treated early.

Treatment of ME secondary to RVO mainly targets various points in the pathogenesis pathway. Treatment modalities have improved substantially in recent years. Before the era of intravitreal pharmacotherapy, treatment guidelines were formulated according to the results of the Central Vein Occlusion Study and Branch Vein Occlusion Study, which recommended observation for CRVO and grid laser photocoagulation for BRVO without spontaneous resolution 3 months after disease onset, respectively^[4-5]. Pharmacotherapy has recently substantially advanced the management of ME, and several effective treatments are currently available.

Currently, the major treatment aimed at major pathways by using anti-VEGF and corticosteroid. The outcomes of anti-VEGF therapy are unprecedented, but responses to treatment may vary and frequent injections are required^[6-13]. Corticosteroids have been used as a treatment strategy for ME secondary to RVO based on

evidence revealing that inflammation plays a crucial role in RVO^[14]. The anti-inflammatory, antiangiogenic, and antipermeability effects of corticosteroids counteract key pathologic processes involved in the development of ME. However, the efficacy of corticosteroids is greatly affected by the routes of administration. Direct intravitreal delivery can bypass the blood-retinal barrier and results in a high local drug concentration and improved systemic safety. The ability to safely deliver therapeutic drug levels to the posterior segment of the eye without the need for frequent dosing calls the development of sustained drug release via implantable devices or injectable particles recently^[15].

This article will focus on a brief review of the use of corticosteroid on ME 2nd to retinal vein occlusion. The review was based on PubMed search from 2011 to 2015, excluding those with small case number or short follow up time. The Standard Care versus Corticosteroid for Retinal Vain Occlusion (SCORE) was included since the study represents the most cited study on this topic.

TRIAMCINOLONE ACETONIDE (TA)

TA is a synthetic steroid of glucocorticoid family, and is one of the first pharmacologic agents used for the treatment of macular edema. The efficacy of TA has been proved in large series; however, the adverse effects such as glaucoma and cataract are major limitations of its use. The Standard Care versus Corticosteroid for Retinal Vain Occlusion study represents the most cited study on this topic and showed that the results of intravitreal administration of triamcinolone (TA) were similar to those of a grid laser in treating ME secondary to BRVO and that intravitreal administration of TA considerably benefited patients with ME secondary to CRVO^[16-17]. However, TA-related elevated intraocular pressure (IOP) and cataract progression are critical concerns, especially in patients receiving 4 mg of TA compared to 1mg. There were several prospective and retrospective case series studies about the effect of TA monotherapy or in combined with laser, bevacizumab or tissue plasminogen activator (tPA) on ME 2nd to RVO.

Although the results were not consistent in the literatures, the effect of TA was supported by most of the reports. In case of BRVO, intravitreal bevacizumab (IVB) works faster than intravitreal TA (IVTA), but needs more injection number. On the contrary, TA seems works better than or as effective as IVB in ME 2nd to CRVO. IVB needs more injection than IVTA^[18-22]. In patients with CRVO and poor vision, both IVB and IVTA were effective on reducing ME, but no significant effect on vision^[23]. IVTA combined with either laser, IVB or tPA work well and reduce the frequency of injection^[24,25]. Like the results from SCORE study, the main drawback of IVTA is the development of cataract and glaucoma^[18-25]. Low dose (2mg) IVTA appeared to be safer with similar effect^[26].

OMAR study compare the risks and benefits of Ozurdex (dexamethasone) and preservative free TA for refractory cystoid macular edema in RVO. Patients were initially treated with at least three injections of bevacizumab monotherapy and later received one of the Intravitreal steroids because of refractory CME. Adding steroids to bevacizumab for refractory CME in RVO patients improved significantly the anatomical outcome, but did not affect visual acuity. Injection frequency decreased significantly after adding steroids, more significantly in Ozurdex groups compared with IVTA groups. There was no difference between TA and DEX regarding anatomical or functional outcomes or rates of side effects. Starting steroid addition to anti-VEGF therapy earlier in the course of the disease may yield better functional results^[27].

FLUOCINOLONE ACETONIDE

Retisert, a nonbiodegradable fluocinolone acetonide intravitreal implant has a sustained quantity of drug (approximate 0.5µg/d) for up to three years. This delivery system has shown effects on chronic noninfectious uveitis and chronic diabetic macular edema. There were two study reports on ME 2nd to CRVO up to now, one 12-month and another one three-year^[28,29]. At 12 months result, VA improved and macular edema decreased in a significant proportion of implanted eyes with chronic, CRVO-associated macular edema. Cataract developed in all five phakic patients and 13 of the 14 eyes required medical or surgical intervention of IOP lowering interventions^[28].

The other three-year study assessed long-term visual outcomes and adverse events from a Fluocinolone acetonide sustained drug delivery implant. At 1, 2, and 3 years after implantation, mean visual acuity showed gains of 4.5 ($P < 0.52$), 8.2 ($P < 0.07$), and 3.4 ($P = 0.64$) letters, respectively, and 32%, 56%, and 50% of study eyes, respectively, showed at least a 10-letter gain in ETDRS score. At these same time points, mean CFT improved at all time points. During the study period, all phakic eyes ultimately underwent cataract extraction, and 5 eyes underwent glaucoma surgery. Although the efficacy of Fluocinolone is significant, the rate of cataract extraction is 100% during 3 years^[29].

Iluvien is an injectable, non-erodible, non-biodegradable intravitreal insert that releases approximately 0.19 mg fluocinolone acetonide for up to 36 months (0.2 µg/day). It has been approved by US Food and drug Administration for the treatment of diabetic macular edema in patients who have previously been treated with corticosteroid and have not experienced a significant rise in intraocular pressure. It was shown to have less complication compared to retisert^[30]. However, there was no report on this product on ME 2nd to RVO yet. A randomized, double-masked pilot study, named FAVOR (Fluocinolone Acetonide for Vein Occlusion in Retina), compares two doses of Iluvien (0.232 and 0.45 microgram per day) is now undergoing.

DEXAMETHASONE INTRAVITREAL IMPLANT (DEX IMPLANT)

Oxurdex, a slow-release dexamethasone implants (DEX implant) (Ozurdex®, Allergan Inc., Irvine, USA), was reported to be effective in reducing ME and have been approved for treating diabetic macular edema and ME secondary to uveitis or RVO.

GENEVA study is the phase III study presented that Dexamethasone intravitreal implant can both reduce the risk of vision loss and improve the speed and incidence of visual improvement in eyes with ME secondary to BRVO or CRVO^[31,32]. With 1 or 2 doses of Dexamethasone implant 0.7 mg at 6-month interval demonstrated the efficacy and safety in treating RVO patients. The subgroup analysis of GENEVA study showed patients with shorter duration of ME had better outcome. The shorter duration of ME in eyes with RVO at the time of first treatment with the Dexamethasone intravitreal implant 0.7 mg is associated with a significantly likelihood of achieving clinically meaningful improvements in VA or retinal thickness^[32]. Steroid related complications, such as cataract and glaucoma did happen, but much less than IVTA or Retisert. Over 12 months, cataract progression occurred in 90 of 302 phakic eyes (29.8%) that received 2 DEX implant 0.7 mg injections versus 5 of 88 sham-treated phakic eyes (5.7%); cataract surgery was performed in 4 of 302 (1.3%) and 1 of 88 (1.1%) eyes, respectively. In the

group receiving two 0.7-mg DEX implants ($n = 341$), a ≥ 10 -mmHg intraocular pressure (IOP) increase from baseline was observed in (12.6% after the first treatment, and 15.4% after the second). The IOP increases were usually transient and controlled with medication or observation; an additional 10.3% of patients initiated IOP-lowering medications after the second treatment^[31].

SHASTA study is a large-scale chart review, retrospective study of real world use of Ozurdex in ME 2nd to RVO. Several reports have been published since 2014. It evaluated the efficacy, safety and reinjection interval of DEX implant in RVO patients ≥ 2 DEX implant treatments in real world setting. The improvement of BCVA change is significant at different endpoints. Mean peak changes in BCVA from baseline at 4 weeks to 20 weeks after the first, second, third, fourth, fifth and sixth DEX implant injections were also statistically significant. The study demonstrated the clinical use of two or more DEX implants, either alone or in combination with common adjunctive RVO treatments, is effective and safe. Decreases in macular edema and improvements in VA continued to be seen after each subsequent DEX implant injection^[33]. In the subgroup analysis, Singer et al compared DEX implant monotherapy versus in combination therapy when treating RVO patients. It demonstrated that treatment with 2 or more DEX implants is safe and effective in the treatment of RVO-associated ME when used alone, as well as when used in combination with other RVO treatments. Increases in IOP that occurred were usually controlled with topical medication^[34]. Another subgroup analysis by Dugel et al, evaluated the efficacy of DEX implant on treatment-naïve RVO patients. After the first through sixth implants, mean changes from baseline BCVA ranged from +3.0 to +8.0 lines, and mean decrease from baseline CRT ranged from 241-259 μm . The study demonstrated that treatment with 2 or more DEX implants, alone or with other adjunctive RVO treatment, improves VA, reduces CRT, and has an acceptable safety profile in patients with newly diagnosed and previously untreated RVO – associated macular edema^[35]. The long-term efficacy and safety profile of Ozurdex on ME 2nd to RVO were further documented by other case series. The incidence of cataract ranged from 0 to 29.8% and the incidence of intervention needed high pressure ranged from 1.2 to 13.3% in the literatures^[36-40].

Although a phase III trial suggested that the optimal interval for repeated DEX implants is 6 months, recent post marketing reports revealed that a range of 3.2-5.5 months is suitable for an as-needed treatment protocol^[38,41-44]. The absence of standardized criteria for retreatment with DEX led to variation in the reported suitable timing for repeated injections.

Even though a previous study reported a significantly greater mean VA improvement in treatment-naïve eyes than in previously treated eyes, our previous study showed that the response in patients who had refractory ME after at least three previous interventions was similar to the whole group^[38,40]. The effect on chronic or refractory ME 2nd to RVO were supported by other studies too. CHROME study demonstrated that DEX implants alone or combined with other treatments and/or procedures resulted in functional and anatomic improvements in long-standing ME associated with RVO^[36]. Sharareh et al tested the efficacy of DEX implant in patients with recalcitrant ME secondary to RVO. For the subgroup patients who do not have resolution of macular edema after treatment with intravitreal bevacizumab, they may respond to treatment with DEX implant well^[45].

Two prospective studies compared the efficacy and safety in treating RVO between Bevacizumab and DEX implant. Both showed that two drugs provided no significantly different effect on either

BCVA improvements or CRT reductions^[46,47]. A retrospective study by Kim showed that bevacizumab PRN monthly and DEX implant PRN at 6-month intervals, yielded functionally and anatomically comparable outcomes at 12 months. The Dex group needed less injection than the other one^[48].

A prospective study done by Singer et al showed that the combination of Ozurdex and bevacizumab is synergistic, increasing VA and prolonging the time between injections, compared with either of these medication alone^[40]. Mayer et al compared the efficacy and safety of three intravitreal bevacizumab loading injections followed by a DEX implant versus DEX implant monotherapy. At 12 months follow-up, combined treatment showed slightly better functional outcome for CRVO patients. In BRVO patients, there were no significant difference between both groups^[39]. A 6-month randomized-controlled study showed that DEX implant as an adjunct treatment to bevacizumab produces greater improvements in macular thickness compared to bevacizumab monotherapy^[49].

The first study to evaluate the efficacy and safety of sequential therapy with ranibizumab followed by DEX implant in comparison with DEX implant monotherapy for macular edema secondary to RVO showed the sequential therapy was more effective than DEX implant monotherapy in treating macular following RVO^[50]. The benefit of combined anti-VEGF and DEX implant especially the sequential one indirectly prove the complex pathogenesis of ME 2nd to RVO.

CASE PRESENTATIONS

Case 1

A 70 y/o male came with chief complaint of blurred vision in his right eye for one and half year, which had been treated three times by intravitreal injection of avastin and focal photocoagulation once before first ozurdex injection. He denied any systemic disease. At baseline visit, vision was 6/30, mild cataract, tortuous vessels beneath superior vascular arcade with macular edema of 503 μm central macular thickness (CRT) on optical coherent tomography (OCT). Fluorescein angiography (FAG) showed slightly delayed filling of right temporo-upper retinal branch vein, limited nonperfusion area above fovea with dye leakage and pooling in the macula of right eye at late phase. After the first injection of ozurdex, the macular thickness decreased a lot. Additional focal photocoagulation was applied to the nonperfusion area shown on FAG. 2 months after ozurdex injection. The macular edema recurred to 390 μm CRT half year after first ozurdex injection and he received 2nd injection another 3 months later due to the persistent edema. The macular edema resolved soon after 2nd ozurdex injection and persisted until 5 months later, when mild recurrence (CRT 290 μm) which was resolved again after 3rd ozurdex injection. The patient received phacoemulsification with intraocular lens implantation 19 months after first ozurdex injection. The effect last for 6 month after each injection. However, macular edema recurred 3 months after cataract surgery. The recurrence of macular edema after cataract surgery might due to the disease itself or another inflammation response after cataract surgery, like Irvine-Gass syndrome (Figure 1).

Case 2

A 49 y/o female without any systemic disease came with chief complaint of blurred vision in her right eye for one year. She had received intravitreal injection of avastin for 4 times, lucentis 3 times and panretinal photocoagulation at local clinic. At initial visit, she had the typical clinical picture of central retinal vein occlusion with macular edema and scattered laser scars in her right eye. The

baseline CRT was 545µm. She responded well after first ozurdex injection and received 4 injections in 2 years with a mean interval of 6 month between each injection. The intraocular pressure (IOP) elevation (29 mmHg) was noted at 2.5 months after 1st injection and

was controlled by alphagan P eye drop for short term. The pressure elevated to around 21-22 mmHg about the same time after each injection. She had 6/10 vision and no record of cataract progression at 20-month follow up (Figure 2).

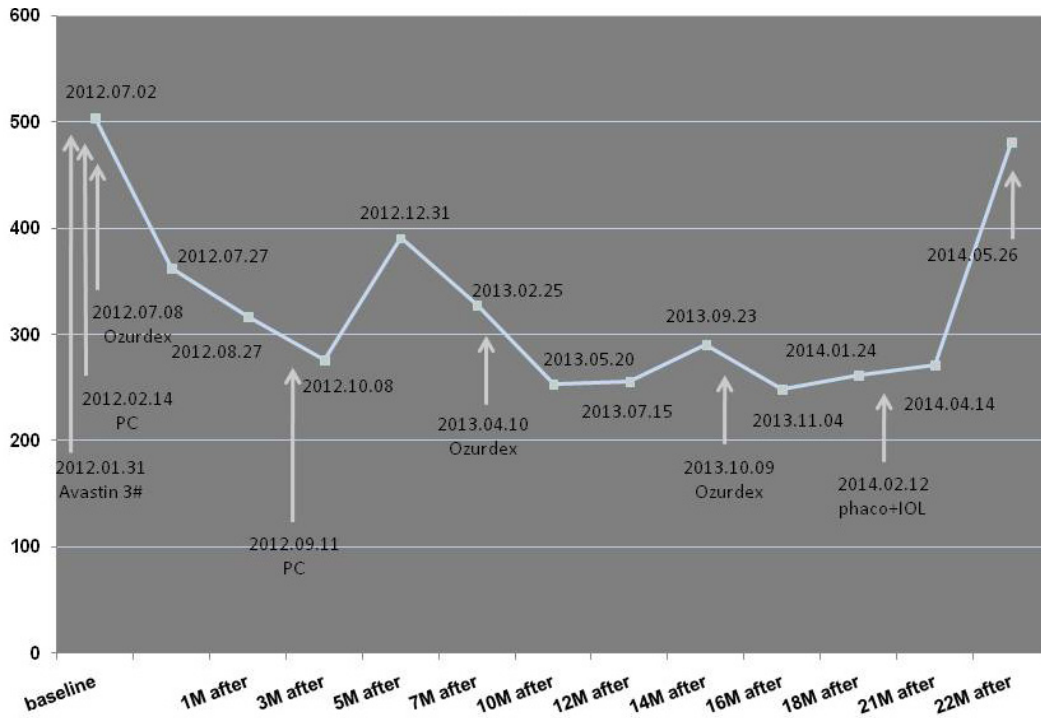


Figure 1 This 70 y/o male had history of blurred vision and received three times by intravitreal injection of avastin and focal photocoagulation once based on the diagnosis of branch retinal vein occlusion before first DEX injection. The CRT improved after each injection. The effect last for 6 month after each injection. However, macular edema recurred 3 months after cataract surgery. The recurrence of macular edema after cataract surgery might due to the disease itself or another inflammation response after cataract surgery.

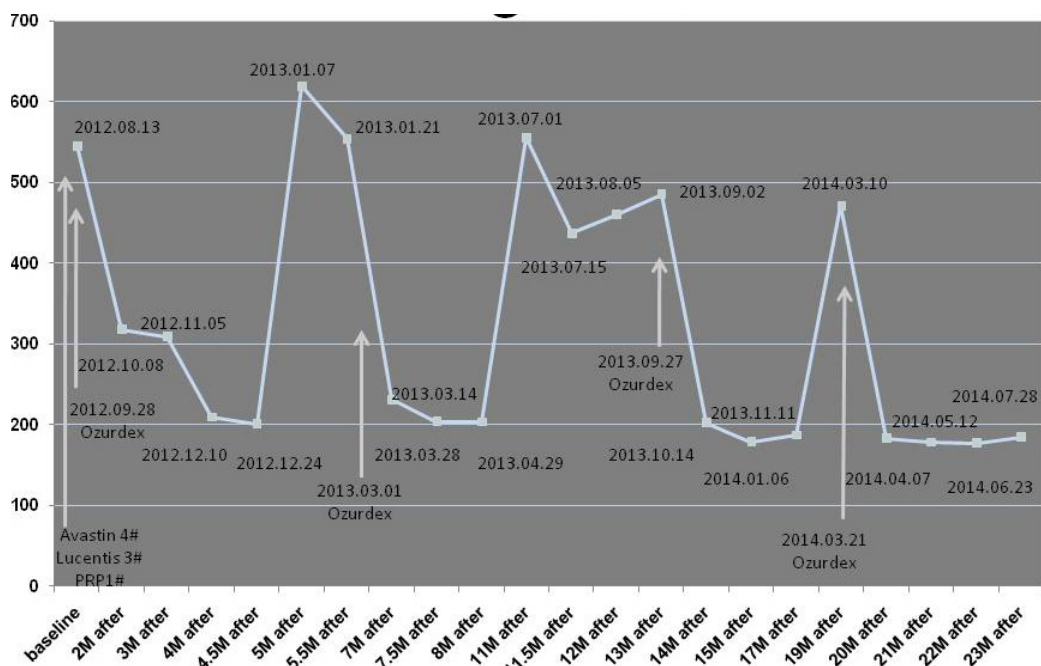


Figure 2 This 49 y/o female had received intravitreal injection of avastin for 4 times, lucentis 3 times and panretinal photocoagulation under the diagnosis of central vein occlusion before the first DEX implants injection. She responded well after first ozurdex injection and received 4 injections in 2 years with a mean interval of 6 month between each injection. Mild elevation of intraocular pressure (IOP) elevation was noted at 2.5 months after 1st injection and was controlled by alphagan P eye drop for short term. The glaucoma recurred about the same time after each injection, but controlled by one medication and resolved with time. She had 6/10 vision and no record of cataract progression at 20-month follow up.

CONCLUSIONS

RVO is the second most common retinal vascular disease in adults. Macular edema is a major cause of visual impairment in both types of RVO. Large multicenter clinical trials have triggered a paradigm shift in the management of DME, from laser photocoagulation to intravitreal pharmacotherapy. Corticosteroids have been used as a treatment strategy for ME secondary to RVO based on evidence revealing that inflammation plays a crucial role in RVO. Steroid related complications such as cataract and glaucoma remain to be an issue to be concerned in use of intravitreal steroid. The recent development of slow releasing intravitreal implant helps to prolong the efficacy and decrease the complication as well as decreased financial burden and intervention related risk in individual patient.

CONFLICT OF INTERESTS

The author declare that they do not have conflict of interests.

REFERENCES

- Hayreh, S.S., Zimmerman, M.B., Podhajsky, P. Incidence of various types of retinal vein occlusion and their recurrence and demographic characteristics. *American Journal of Ophthalmology* 117(4):429-441, 1994.
- Rogers, S., McIntosh, R.L., Cheung, N., Lim, L., Wang, J.J., Mitchell, P., Kowalski, J.W., Nguyen, H., Wong, T.Y.; International Eye Disease Consortium. The prevalence of retinal vein occlusion: pooled data from population studies from the United States, Europe, Asia, and Australia. *Ophthalmology* 117(2):313-9, 2010.
- Yoshimura, T., Sonoda, K.-H., Sugahara, M., Mochizuki, Y., Enaida, H., et al. Comprehensive Analysis of Inflammatory Immune Mediators in Vitreoretinal Diseases. *PLoS ONE* 4(12): e8158, 2009. doi:10.1371/journal.pone.0008158.
- The Branch Vein Occlusion Study Group. Argon laser photocoagulation for macular edema in branch vein occlusion. *American Journal of Ophthalmology* 98(3):271-282, 1984.
- [No authors listed]. A randomized clinical trial of early panretinal photocoagulation for ischemic central vein occlusion. The Central Vein Occlusion Study Group N report. *Ophthalmology* 102(10):1434-44, 1995.
- Coscas, G., Loewenstein A., Augustin, A., et al. Management of retinal vein occlusion: consensus document. *Ophthalmologica* 226:4-28, 2011.
- Campochiaro, P.A., Heier, J.S., Feiner, L., et al.; BRAVO Investigators. Ranibizumab of macular edema following branch retinal vein occlusion: six-month primary end point results of a phase III study. *Ophthalmology* 117:1102-12, 2010.
- Brown, D.M., Campochiaro, P.A., Singh, R.P., et al, CRUISE Investigators. Ranibizumab for macular edema following central retinal vein occlusion: six-month primary end point results of a phase III study. *Ophthalmology* 117:1124-33, 2010.
- Epstein, D.L., Algever, P.V., von Wendt, G., Seregard, S., Kvanta, A. Benefit from bevacizumab for macular edema in central retinal vein occlusion: twelve-month results of a prospective, randomized study. *Ophthalmology* 119: 2587-91, 2012.
- Brown, D.M., Heier, J.S., Clark, W.L., et al. Intravitreal aflibercept injection for macular edema secondary to central retinal vein occlusion: 1-year results from the phase 3 COPERNICUS study. *Am J Ophthalmol* 155:429-437, 2013.
- Mitry, D., Bunce, C., Charteris, D. Anti-vascular endothelial growth factor for macular oedema secondary to branch retinal vein occlusion. *Cochrane Database Syst Rev* 31;1:CD009510, 2013. doi: 10.1002/14651858.CD009510.pub2.
- Yoon YH, Kim HK, Yoon HS, Kang SW, Kim JG, Park KH, Jo YJ, Lee JY, Lee DH. Korean RVO Study Group. Improved visual outcome with early treatment in macular edema secondary to retinal vein occlusions: 6-month results of a Korean RVO study. *Jpn J Ophthalmol* 58(2):146-54, 2014
- Wu L, Arevalo F, Berrocal MH, Maria M, Roca JA, Morales-Canton V, Alezzandrini AA, Diaz-Llopis MJ. Comparison of two doses of intravitreal bevacizumab as primary treatment for macular edema secondary to central retinal vein occlusion. Results of the Pan American Collaborative Retinal Study Group at 24 months. *Retina* 30:1002-11, 2010.
- Deobhakta, A., Louis K. Chang, L.K. Inflammation in retinal vein occlusion. *Int J Inflamm* 2013:438412. doi: 10.1155/2013/438412.
- Hazirolan D, Pleyer U. Think global-act local: intravitreal drug delivery systems in chronic noninfectious uveitis. *Ophthalmic Res* 49:59-65,2013.
- SCORE Study Research Group. A randomized trial comparing the efficacy and safety of intravitreal triamcinolone with standard care to treat vision loss associated with macular edema secondary to branch retinal vein occlusion: the Standard Care vs Corticosteroid for Retinal Vein Occlusion (SCORE) Study report 6. *Arch Ophthalmol* 127:1115-28, 2009.
- SCORE Study Research Group. A randomized trial comparing the efficacy and safety of intravitreal triamcinolone with observation to treat vision loss associated with macular edema secondary to central retinal vein occlusion: the Standard Care vs Corticosteroid for Retinal Vein Occlusion (SCORE) Study report 5. *Arch Ophthalmol* 127:1101-14, 2009.
- Gokce G, Sobaci G, Durukan AH, Erdurman FC. The comparison of intravitreal triamcinolone and bevacizumab in patients with macular edema secondary to branch retinal vein occlusion. *Clin Ophthalmol* 8:355-62,2014.
- Ramezani A, Esfandiari H, Entezari M, Moradian S, Soheilian M, Dehsarvi B, Yaseri M. Three intravitreal bevacizumab versus two intravitreal triamcinolone injections in recent onset central vein occlusion. *Acta Ophthalmol* 92:e530-9, 2014.
- Ramezani A, Esfandiari H, Entezari M, Moradian S, Soheilian M, Dehsarvi B, Yaseri M. Three intravitreal bevacizumab versus two intravitreal triamcinolone injections in recent-onset branch retinal vein occlusion. *Graefes Arch Clin Exp Ophthalmol.* 250:1149-60,2012.
- Higashiyama T1, Sawada O, Kakinoki M, Sawada T, Kawamura H, Ohji M. Prospective comparisons of intravitreal injections of triamcinolone acetonide and bevacizumab for macular oedema due to branch retinal vein occlusion. *Acta Ophthalmol.* 91:318-24,2013.
- Ding X1, Li J, Hu X, Yu S, Pan J, Tang S. Prospective study of intravitreal triamcinolone acetonide versus bevacizumab for macular edema secondary to central retinal vein occlusion. *Retina.* 31:838-45,2011.
- Lim JW, Na KI. A comparative study between intravitreal triamcinolone and bevacizumab for macular edema due to central retinal vein occlusion with poor vision. *Indian J Ophthalmol.* 59:93-6,2011.
- Yamamoto T, Kamei M, Sayanagi K, Matsumura N, Nishida K, Sakaguchi H, Tsujikawa M, Tano Y. Simultaneous intravitreal injection of triamcinolone acetonide and tissue plasminogen activator for central retinal vein occlusion: a pilot study. *Br J Ophthalmol.* 95:69-73,2011.
- Ali RI, Kapoor KG1, Khan AN, Gibran SK. Efficacy of combined intravitreal bevacizumab and triamcinolone for branch retinal vein occlusion. *Indian J Ophthalmol.* 62:396-9,2014.
- Chuang LH, Yeung L, Wang NK, Chen SL, Ku WC, Lai CC. Secondary Ocular Hypertension After Intravitreal Injection with 2 mg or 4mg of Triamcinolone in Retinal Vein Occlusion. *Journal of Ocular Pharmacology and Therapeutics* 26:325-328,2010.
- Ozkok A, Saleh OA, Sigford DK, Heroman JW, Schaal S. THE OMAR STUDY: Comparison of Ozurdex and Triamcinolone

- Acetonide for Refractory Cystoid Macular Edema in Retinal Vein Occlusion. *Retina*. 35:1393-400,2015.
28. Ramchandran RS, Fekrat S, Stinnett SS, Jaffe GJ. Fluocinolone acetonide sustained drug delivery device for chronic central retinal vein occlusion: 12-month results. *Am J Ophthalmol*. 146:285-291,2008.
 29. Jain N, Stinnett SS, Jaffe GJ. Prospective study of a fluocinolone acetonide implant for chronic macular edema from central retinal vein occlusion: thirty-six-month results. *Ophthalmology*. 119(1):132-7,2012.
 30. Cunha-Vaz, Ashton P for the FAME Study Group. Sustained delivery fluocinolone acetonide vitreous implant: long-term benefit in patients with chronic diabetic macular edema. *Ophthalmology* 121:1892-1903, 2014.
 31. Haller, J.A., Bandello, F., Belfort, R. Jr., et al, Ozurdex GENEVA Study Group. Dexamethasone intravitreal implant in patients with macular edema related to branch or central retinal vein occlusion twelve-month study results. *Ophthalmology* 118(12):2453-60, 2011.
 32. Yeh WS1, Haller JA, Lanzetta P, Kuppermann BD, Wong TY, Mitchell P, Whitcup SM, Kowalski JW. Effect of the duration of macular edema on clinical outcomes in retinal vein occlusion treated with dexamethasone intravitreal implant. *Ophthalmology*. 119(6):1190-8,2012.
 33. Capone, A. Jr, Singer, M.A., Dodwell, D.G., Dreyer, R.F., Oh, K.T., Roth, D.B., Walt, J.G., Scott, L.C., Hollander, D.A. Efficacy and safety of two or more dexamethasone intravitreal implant injections for treatment of macular edema related to retinal vein occlusion (Shasta study). *Retina* 34(2):342-51, 2014. doi: 10.1097/IAE.0b013e318297f842.
 34. Singer MA, Capone A Jr, Dugel PU, Dreyer RF, Dodwell DG, Roth DB, Shi R, Walt JG, Scott LC, Hollander DA; SHASTA Study Group. Two or more dexamethasone intravitreal implants as monotherapy or in combination therapy for macular edema in retinal vein occlusion: subgroup analysis of a retrospective chart review study. *BMC Ophthalmol*. 1;15:33,2015.
 35. Dugel PU, Capone A Jr, Singer MA, Dreyer RF, Dodwell DG, Roth DB, Shi R, Walt JG, Scott LC, Hollander DA; SHASTA Study Group. Two or more dexamethasone intravitreal implants in treatment-naïve patients with macular edema due to retinal vein occlusion: subgroup analysis of a retrospective chart review study. *BMC Ophthalmol*. 4;15:118,2015.
 36. Lam WC, Albiani DA, Yoganathan P, Chen JC, Kherani A, Maberley DA, Oliver A, Rabinovitch T, Sheidow TG, Tourville E, Wittenberg LA, Sigouin C, Baptiste DC. Real-world assessment of intravitreal dexamethasone implant (0.7 mg) in patients with macular edema: the CHROME study. *Clin Ophthalmol*. 10;9:1255-68,2015.
 37. Battaglia Parodi M, Iacono P, Sacconi R, Parravano M, Varano M, Bandello F. Dexamethasone implant for macular edema secondary to central vein occlusion in patients younger than 50 years. *Retina*. 35:1381-6,2015.
 38. Sheu SJ, Wu TT, Horng YH. Efficacy and safety of dexamethasone intravitreal implant for treatment of refractory macular edema secondary to retinal vein occlusion in Taiwan. *J Ocul Pharmacol Ther*. 2015 Jun 11. [Epub ahead of print]
 39. Mayer WJ, Wolf A, Kernt M, Kook D, Kampik A, Ulbig M, Hari-toglou C. Twelve-month experience with Ozurdex for the treatment of macular edema associated with retinal vein occlusion. *Eye (Lond)*. 27:816-22,2013.
 40. Singer MA, Bell DJ, Woods P, Pollard J, Boord T, Herro A, Porbandarwalla S. Effect of combination therapy with bevacizumab and dexamethasone intravitreal implant in patients with retinal vein occlusion. *Retina*. 2012 Jul;32(7):1289-94,2012.
 41. Coscas, G., Augustin, A., Bandello, F., de Smet, M.D., Lanzetta, P., Staurenghi, G., Parravano, M.C., Udaondo, P., Moisseiev, E., Soubrane, G., Yatziv, Y., Loewenstein, A. Retreatment with Ozurdex for macular edema secondary to retinal vein occlusion. *Eur J Ophthalmol* 24(1):1-9, 2014. doi: 10.5301/ejo.5000376. Epub 2013 Oct 14.
 42. Schmitz, K., Maier, M., Clemens, C.R., Höhn, F., Wachtlin, J., Lehmann, F., Bertelmann, T., Rüdiger, K., Horn, M., Bezatis, A., Spital, G., Meyer, C.H.; German Retinal Vein Occlusion Group. Reliability and safety of intravitreal Ozurdex injections. The ZERO study. *Ophthalmologie* 111(1):44-52, 2014. doi: 10.1007/s00347-012-2737-2.
 43. Moisseiev, E., Goldstein, M., Waisbourd, M., Barak, A., Loewenstein, A. Long-term evaluation of patients treated with dexamethasone intravitreal implant for macular edema due to retinal vein occlusion. *Eye (Lond)* 27(1):65-71, 2013. doi: 10.1038/eye.2012.226.
 44. Querques, L., Querques, G., Lattanzio, R., Gigante, S.R., Del Turco, C., Corradetti, G., Cascavilla, M.L., Bandello, F. Repeated Intravitreal Dexamethasone Implant (Ozurdex®) for Retinal Vein Occlusion. *Ophthalmologica* 229(1):21-5, 2013. doi: 10.1159/000342160.
 45. Sharareh B, Gallemore R, Taban M, Onishi S, Wallsh J. Recalcitrant macular edema after intravitreal bevacizumab is responsive to an intravitreal dexamethasone implant in retinal vein occlusion. *Retina*. 33:1227-31,2013.
 46. Gado AS, Macky TA. Dexamethasone intravitreal implant versus bevacizumab for central retinal vein occlusion-related macular oedema: a prospective randomized comparison--response. *Clin Experiment Ophthalmol*. 43(5):497-8,2015.
 47. Guignier B1, Subilia-Guignier A, Fournier I, Ballonzoli L, Speeg-Schatz C, Gaucher D. Prospective pilot study: efficacy of intravitreal dexamethasone and bevacizumab injections in the treatment of macular oedema associated with branch retinal vein occlusion. *Ophthalmologica*. 230:43-9,2013.
 48. Kim M, Lee DH, Byeon SH, Koh HJ, Kim SS, Lee SC. Comparison of intravitreal bevacizumab and dexamethasone implant for the treatment of macula oedema associated with branch retinal vein occlusion. *Br J Ophthalmol*. 99:1271-6,2015.
 49. Maturi RK, Chen V, Raghinaru D, Bleau L, Stewart MW. A 6-month, subject-masked, randomized controlled study to assess efficacy of dexamethasone as an adjunct to bevacizumab compared with bevacizumab alone in the treatment of patients with macular edema due to central or branch retinal vein occlusion. *Clin Ophthalmol*. 8:1057-64,2014.
 50. Iu LP, Zhao P, Yeung IY, Fung NS, Lee JW, Wong RL, Chong V, Wong IY. Sequential therapy with ranibizumab and dexamethasone intravitreal implant is better than dexamethasone monotherapy for macular oedema due to retinal vein occlusion. *Br J Ophthalmol*. 99:210-4,2015.