

## Anti-VEGF Therapy for Retinal Vein Occlusion

Danzmann L, Pielen A, Bajor A

Danzmann L, Pielen A, Bajor A, University Eye Hospital, Hannover Medical School, Hannover, Germany

Correspondence to: L. Danzmann, University Eye Hospital, Hannover Medical School, Hannover, Germany.

Email: [Danzmann.Lisa@mh-hannover.de](mailto:Danzmann.Lisa@mh-hannover.de)

Received: September 15, 2015 Revised: October 9, 2015

Accepted: October 12, 2015

Published online: March 28, 2016

### ABSTRACT

Current recommendations for treatment of macular edema secondary to BRVO or CRVO favour intravitreal anti-VEGF agents compared to intravitreal steroids. An upload of 3 injections is reasonable to address intravitreal VEGF levels. Prognosis for visual improvement is good and time to treatment is crucial. There is evidence that an early targeted laser photocoagulation of ischemic areas may lead to additional treatment effects, less injections and improved prognosis if administered early after RVO. In the course of the disease patients must be frequently monitored for recurrence of edema to initiate re-treatment and for conversion to ischemic RVO. Ischemia, proliferations and rubeosis iridis must not be treated with intravitreal anti-VEGF alone. Laser treatment of peripheral retina remains the standard-of-care to treat ischemia. In this article we review up-to-date information on intravitreal anti-VEGF therapy in RVO, international guidelines, safety and efficacy of treatment. We discuss new insights on factors that may improve prognosis or burden of intravitreal treatment. And we discuss the role of ischemia in RVO.

© 2016 The Authors. Published by ACT Publishing Group Ltd.

**Key words:** Retinal Vein Occlusion; Macular Edema; Anti-VEGF; Ranibizumab; Bevacizumab; Aflibercept; Dexamethasone

Danzmann L, Pielen A, Bajor A. Anti-VEGF Therapy for Retinal Vein Occlusion. *International Journal of Ophthalmic Research* 2016; 2(1): 110-116 Available from: URL: <http://www.ghrnet.org/index.php/ijor/article/view/1498>

### INTRODUCTION

Visual impairment following branch or central retinal vein occlusion (BRVO/ CRVO) is secondary to macular edema. VEGF is among multiple factors the best investigated target which induces and sustains macular edema in RVO. Intravitreal anti-VEGF agents target the macular edema and resolution may lead to visual improvement. The sooner the macular edema is treated, the better is the response and prognosis for the patient<sup>[1,2]</sup>. Morphological changes (macular edema) occur before functional impairment (visual acuity), so close monitoring of patients is warranted after initial anti-VEGF therapy to treat as soon macular edema reoccurs<sup>[1,3]</sup>. Long-standing macular edema leads to structural changes like atrophy of retinal pigment epithelium and loss of photoreceptors which prevent visual improvement<sup>[4]</sup>. Retinal ischemia significantly impairs the prognosis if the macula is involved. Significant peripheral ischemia, defined as > 5 papillary diameters (PD) in BRVO and > 10 PD in CRVO as it was established in the CVOS and BVOS trials, leads to a higher risk to provoke neovascularization of the iris or the retina<sup>[5,6]</sup>. If unmet by regional retinal photocoagulation, ischemia may result in vitreous haemorrhage and neovascular glaucoma. Recent studies have even called for the 5 PD limit for patients with CRVO. The risk of developing neovascularization in CRVO with a ischemia area of >5 PD is almost 9% within 3 years<sup>[7]</sup>. Anti-VEGF treatment in RVO does not target ischemia. During the course of the disease ischemia must be repeatedly evaluated to detect conversion from non-ischemic to ischemic RVO. Recent investigations show that the combination of anti-VEGF with targeted laser photocoagulation of avascular peripheral retina may improve patients' prognosis and lead to a reduced number of injections<sup>[8,9]</sup>.

In this article we review up-to-date information on intravitreal anti-VEGF therapy in RVO, international guidelines, safety and efficacy of treatment. We discuss new insights on factors that may improve prognosis or burden of intravitreal treatment. And we discuss the role of ischemia in RVO.

### ANTI-VEGF AGENTS

Ranibizumab (Lucentis<sup>®</sup>, Novartis Pharma AG, Switzerland, and

Genentech, Inc., USA) and Aflibercept (Eylea<sup>®</sup>, Bayer Pharma AG, Germany, and Regeneron Pharmaceuticals, Inc., USA) are approved for intravitreal anti-VEGF treatment for macular edema in RVO. Bevacizumab (Avastin<sup>®</sup>, Roche, Switzerland, and Genentech, Inc., USA) is frequently used off-label because of the striking cost-difference but also due to late approval of any anti-VEGF agent for RVO. Pegaptanib (Macugen<sup>®</sup>, Pfizer) was not investigated further in RVO.

Ranibizumab is a 48 kDa monovalent monoclonal antibody fragment. The antigen-binding Fab without the Fc domain shows a good binding affinity to all forms of VEGF and an increased affinity to VEGF-A<sup>[10]</sup>. Since FcRn binding is prevented the systemic half-life is short, approximately 2 h following intravitreal injection. The distribution across all retinal layers to the choroidal vasculature is facilitated<sup>[11,12]</sup>.

Aflibercept is a 115 kDa receptor Fc fusion protein, composed of domains of the human VEGF receptor 1 and 2, which shows a higher affinity to bind VEGF compared to ranibizumab and bevacizumab<sup>[1,13-15]</sup>. Because of the intact Fc region, aflibercept is likely to be subject to FcRn recycling, which is supported by a serum half-life of approximately 5–6 days following intravenous administration<sup>[13,16]</sup>.

Bevacizumab is a 149 kDa full-length, bivalent monoclonal antibody against VEGF-A<sup>[10]</sup>. It is salvaged from proteolytic catabolism and recycled via binding to FcRn in endothelial cells, resulting in a long systemic half-life of approximately 20 days following intravenous infusion [Avastin (bevacizumab) solution for intravenous infusion prescribing information].

In a study comparing systemic exposure and systemic VEGF suppression of different anti-VEGF agents following intravitreal injection 56 patients with wet age-related macular degeneration received intravitreal ranibizumab (0.5 mg), bevacizumab (1.25 mg), or aflibercept (2.0 mg). Serum pharmacokinetics and plasma free VEGF concentrations were evaluated after the first and third injection in each patient. The study showed notable differences in systemic pharmacokinetics and pharmacodynamics among anti-VEGF treatments after intravitreal administration. All three agents rapidly moved into the bloodstream, but ranibizumab very quickly cleared, whereas bevacizumab and aflibercept demonstrated longer systemic exposure and produced a marked reduction in plasma free VEGF<sup>[17]</sup>.

Agents were approved for intravitreal treatment of macular edema in RVO without comparison between substances but comparison to sham treatment<sup>[1]</sup>. Head-to-head trials to compare safety and efficacy in RVO are rare but needed to guide us in clinical routine. Recent and future investigations should focus on comparative trials.

## GUIDELINES

After diagnosing macular edema secondary to RVO, therapy should be initiated promptly. Substances currently in clinical use are either VEGF-inhibitors or dexamethasone implant injected into the vitreous. Treatment with VEGF-inhibitors starts with an “upload” of 3 monthly injections, followed by re-evaluation with spectral-domain optical coherence tomography (OCT) and re-treatment. On the basis of published recommendations and evidence we developed a Figure to present our recommendations (Figure 1)<sup>[1,18-20]</sup>.

A recent guideline well illustrating the treatment of RVO is a consensus of an expert panel in Canada<sup>[18]</sup>. The therapy algorithm suggests a baseline assessment with a clinical evaluation as well as assessment for neovascularization and macular edema with OCT.

If vision is impaired due to macular edema following CRVO or BRVO, macular edema should be treated with a loading dose of 3 monthly anti-VEGF injections initially. For macular edema with a visual acuity better than 20/40 observation and close follow-up can be considered as an alternative, as the expert panel decided for their consensus. With visual acuity better than 20/40 there is no study experience since patients were excluded in randomized controlled clinical trials (RCTs) with such a good vision<sup>[18]</sup>. But recent data show better prognosis for patients the sooner treatment is initiated. Thus early treatment of macular edema is recommended regardless of the degree of visual impairment.

After 3 monthly injections there is a re-evaluation with testing of visual acuity and OCT (Figure 1). If there is still evidence of fluid on OCT and improved or stable visual acuity, further intravitreal anti-VEGF injections are recommended. If macular edema does not respond as well as expected and visual acuity stays the same or worsens, fluorescein angiography should be considered to assess for macular and peripheral ischemia and other complications. Patients with no fluid on OCT should be evaluated frequently (initially monthly) and re-treated referring to a pro re nata (PRN)-scheme. Grid laser or anti-VEGF switch are opportunities for patients with BRVO and suboptimal response to anti-VEGF. Intravitreal steroids or an anti-VEGF switch can be an alternative for patients with CRVO and suboptimal response to anti-VEGF.

Intravitreal injections can be administered in a PRN scheme with single injections or in a set of 3 monthly treatments. On average, patients need 7-8 injections in the first year<sup>[1]</sup>. Therefore, it seems reasonable to re-treat with 3 monthly injections and re-evaluate again after the whole set. This reduces the burden of frequent appointments. Another option for anti-VEGF treatment that is currently being tested and increasingly favoured in clinical settings is the “Treat-and-Extend” scheme. It is widely used in wet age related macular degeneration<sup>[21,22]</sup>, but evidence from RCTs in RVO is missing. With this scheme the number of visits might be reduced even more. If there is no fluid on OCT, the interval to the next injection is enlarged by 2 weeks (up to a maximum of a 12-week interval) and there is an injection, despite a dry macula. If there is fluid on OCT, the interval to the next injection is shortened by 2 weeks (up to a minimum of a 4-week interval). With this mechanism the best interval for an individual patient maybe found (at least in wet AMD). But there is currently no evidence supporting the treat-and-extend algorithm for macular edema in RVO.

If neovascularization with the risk of vitreous haemorrhage appears secondary to RVO, laser photocoagulation of the peripheral ischemic retina is first line treatment. Adjunctive to laser anti-VEGF could be considered, but anti-VEGF alone is not an option to treat neovascularization in RVO.

## EFFICACY

**Anti-VEGF and steroids are efficient.** Pielon *et al* conducted a systematic review regarding “Efficacy and Safety of Intravitreal Therapy in Macular Edema Due to Branch and Central Retinal Vein Occlusion”<sup>[1]</sup>. For both, intravitreal steroids and anti-VEGF agents, efficacy could be shown in randomized controlled trials. Anti-VEGF agents show a better gain of BVCA compared to steroids after 12 months of treatment, but comparison is impaired because of different conditions and treatment regimen.

**In CRVO,** (Table 1) aflibercept and bevacizumab led to the greatest gain in visual acuity<sup>[1]</sup>. After 12 months patients treated with 2 mg aflibercept gained +16.2 letters (8.5 injections) compared

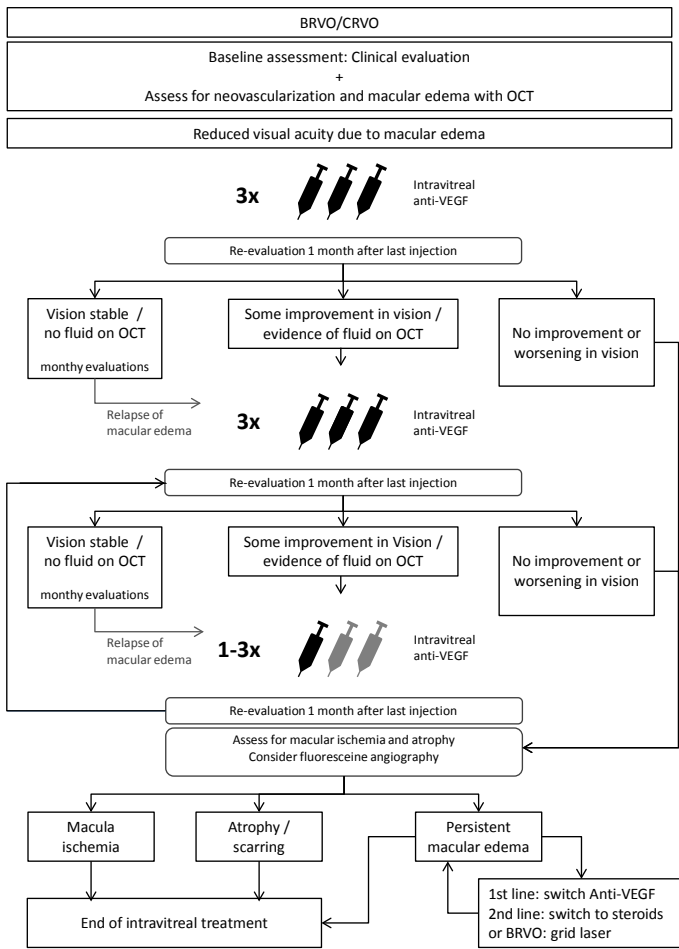


Figure 1 Therapy of Retinal Vein Occlusion\_Revision

to baseline and patients treated with 1.25 mg bevacizumab achieved +16.1 letters (8 injections). A therapy with 0.5 mg ranibizumab improved visual acuity by +13.9 letters (8.8 injections). Triamcinolone improved BCVA (best corrected visual acuity) by +2 letters (1.8 injections) and was significantly better compared to observation.

Aflibercept was administered with a dose of 2 mg every 4 weeks for 6 months followed by a monthly PRN scheme<sup>[23, 24]</sup>. Bevacizumab was given in a dose of 1.25 mg every 6 weeks<sup>[25]</sup>. In the CRUISE study 0.5 mg ranibizumab was given monthly in a PRN scheme<sup>[26]</sup>. Triamcinolone achieved less gain of letters, but also needed fewest injections<sup>[27, 28]</sup>. But direct comparison of the studies is difficult because of the different study design.

In BRVO, (Table 2) best improvement of BCVA was found for ranibizumab with +18.3 letters (8.4 injections)<sup>[1]</sup>. In comparison, bevacizumab seems to achieve similar results (+15 to +17 letters), but interpretation is limited by the very low number of participants in the bevacizumab-RCT. The dosage regime of ranibizumab was 0.5 mg monthly for 6 months followed by monthly PRN<sup>[29]</sup>. The 24 week results of the VIBRANT-study show that monthly injections of 2mg aflibercept provide significantly greater visual benefit than the previous gold standard grid laser photocoagulation with a gain of +17.0 letters<sup>[30]</sup>. The 12 month results are not yet published.

In the Geneva Study dexamethasone implants with 0.35 mg and 0.7 mg were injected once or twice into the vitreous of patients with BRVO or CRVO with an interval of 6 months for one year and compared to sham<sup>[31]</sup>. 60 days after the first injection 30 % had an improvement in BCVA of equal or more than 15 letters. If at day 180 BCVA was < 84 or retinal thickness was > 250 µm patients could receive a dexamethasone implant with 0,7 mg regardless of their former group. 60 days after the second injection 32 % had an improvement in BCVA of equal or more than 15 letters.

Table 1 Change in best-corrected visual acuity in letters in randomized controlled trials (RCT) investigating anti-VEGF agents for macular edema secondary to central retinal vein occlusion.

RCT	Agent	Treatment regimen	12 months	24 months	48 months
SCORE	Triamcinolon	Every 3 months	+ 2		
CRUISE	Ranibizumab	Monthly/ 6 months followed by PRN	+ 13.9	HORIZON + 12.0	RETAIN + 14.0
	Sham	Sham + Ran. PRN from month 6	+ 7.3	+ 7.6	
Epstein	Bevacizumab	Every 6 weeks	+ 16.1		
	Sham	Sham + Bev. Every 6 weeks	+ 4.6		
COPERNICUS	Aflibercept	Monthly/ 6 months followed by PRN	+ 16.2	+ 13.0	
	sham	Sham + Afl. PRN from month 6	+ 3.8	+ 1.5	
GALILEO	Aflibercept	Monthly/ 6 months followed by PRN	+ 16.9	+ 13.1	
	Sham	PRN from month 12	+ 3.8	Sham + Afl. + 6.2	
GENEVA	Dexamethason	Every 6 months	+ 2 (approx.)		
	Sham + Dex.	Every 6 months	-1 (approx.)		

Table 2 Change in best-corrected visual acuity in letters in randomized controlled trials (RCT) investigating anti-VEGF agents for macular edema secondary to branch retinal vein occlusion.

RCT	Agent	Treatment regimen	12 months	24 months	48 months
SCORE	Triamcinolone	1 mg PRN/ every 3 months	+ 5.7		
		4 mg PRN/ every 3 months	+ 4.0		
		Grid PRN/ every 3 months	+ 4.2		
BRAVO	Ranibizumab	Monthly/ 6 mo, followed by PRN	+ 18.3	HORIZON + 17.5	RETAIN + 20.0
	Sham	Sham + Ran. PRN from month 6	+ 12.1		
Russo	Bevacizumab	1.25 mg PRN	+ 15.5	+ 15.6	
		Grid	+ 10.0		
Donati	Bevacizumab	1.25 mg monthly	+ 15.0		
		1.25 mg + Grid monthly	+ 20.0		
GENEVA	Dexamethason	every 6 months	+ 6 (approx.)		
	Sham	Sham + Dex. every 6 months	+ 6 (approx.)		
VIBRANT	Aflibercept	Monthly/ 6 mo followed by PRN	+ 17.0		
	Sham/ Grid		+ 6.9		

## SAFETY

**Anti-VEGF and steroids are safe.** Evidence from multiple trials show that serious adverse events are rare. If intravitreal injections are given under sterile conditions the risk of endophthalmitis is low. Endophthalmitis occurred in 0.0 – 0.9%<sup>[1]</sup>. There is a difference of adverse events of steroids compared to anti-VEGF. Cataract progression was observed in 10.7% of patients receiving one dexamethasone implant (sham/ 0.7 mg Ozurdex) compared to 29.8% of patients after two Ozurdex 0.7 mg implants versus 5.7% of sham patients<sup>[1, 31]</sup>. IOP rise occurred in every third patient after Ozurdex implant at day 60 and was most often treated with local anti-glaucomatous therapy, but 1.3% of patients underwent glaucoma surgery (versus none in sham treated patients). Therefore, there should be a restricted indication for using intravitreal corticosteroids especially for young patients and patients with known steroidresponse as well as late stage glaucoma. A possible luxation of the implant into the anterior chamber in patients with aphakia or a defect capsule can lead to endothelial damage and reduced visual acuity. Overall, the ocular risk profile seems to be favourable for anti-VEGF agents in comparison to steroids.

The systemic risk seems to be comparable low. There is no major known systemic adverse event. There might be a slightly increased chance for cardiovascular risks. But patient numbers of the randomized controlled trials are not calculated to investigate systemic risks. Reliable evidence is available from systematic reviews and meta-analysis. There are no signs for an increased risk of cardiovascular adverse events, e.g. Pielen *et al* did not find any significant differences in observation versus treatment group for myocardial infarction, cerebrovascular accident or nonocular haemorrhage<sup>[1]</sup>.

Results from RCTs demonstrate the efficacy and safety of intravitreal corticosteroids and anti-VEGF agents for macular edema secondary to retinal vein occlusion. Comparison of 12 month data suggests that VEGF-inhibitors might be superior to corticosteroids, but comparison of results is limited because of the lack of head-to-head trials, differences in duration of macular edema at baseline and different treatment regimens<sup>[1]</sup>.

## LONG-TERM OUTCOMES

Ranibizumab patients (BRAVO and CRUISE) were followed up until 2 years in the HORIZON trial and showed sustained visual improvement with a relatively low mean number of ranibizumab injections in the second year<sup>[32]</sup>.

Longest follow-up data for ranibizumab treatment in RVO currently is 48 months available from the results of the RETAIN study<sup>[33]</sup>. Overall, visual improvement at 6 months in CRVO (+14.0 letters) and BRVO (+20.1 letters) could be maintained until 48 months. Prognosis differed between CRVO patients depending on the response to anti-VEGF treatment. After 4 years nearly half of the CRVO patients (44%) had edema resolution with a mean improvement in BCVA of +25.2 letters (resolved macular edema had been defined as no intraretinal fluid for 6 months after the last injection). Of these patients, 71% had received their last ranibizumab injection within  $\leq 2$  years. CRVO patients with unresolved edema had a mean improvement of +4.3 letters.

In the BRVO group, results were even better. Half of the patients (50%) showed edema resolution and gained +25.9 letters compared to +17.1 letters in the group of patients with unresolved ME. 76% of Patients with resolved edema had received their last injection within

$\leq 2$  years.

## TIME TO TREATMENT

**Time to treatment is crucial.** Secondary analysis of all trials shows that early treatment of macular edema secondary to RVO is more effective than delayed treatment<sup>[1, 34]</sup>. The sooner the macular edema is treated, the better the structural response (resolved edema). The longer the consequent re-treatment, the better is the prognosis for sustained visual acuity. The clinical trials for approval of ranibizumab and aflibercept (CRUISE, BRAVO, GALILEO, COPERNICUS, VIBRANT) all showed that the sham group receiving anti-VEGF injections after 6-12 months delay had worse results than the group of patients treated with anti-VEGF injections from baseline<sup>[1, 18]</sup>. The treatment delay of 6 months in the sham/control group led to a smaller gain of letters in BCVA. Long-term data show that the groups of later treated patients did not reach comparable gains in BCVA even over a longer time span of continued intravitreal treatment. Time between occlusion and treatment is a critical factor for the therapeutic effect and patients' prognosis.

## PROGNOSIS – PREDICTIVE FACTORS

Early IVB treatment may suppress macular edema recurrence in BRVO. Yamada *et al* investigated the predictive factors for recurrence of macular edema after successful intravitreal bevacizumab therapy in BRVO<sup>[2]</sup>. Patients were classified into an effective group and an ineffective group, based on whether the central retinal thickness (CRT) decreased to  $<250\mu\text{m}$  or remained  $>250\mu\text{m}$  throughout the first 3 postoperative months. The effective group was then divided into a recurrent group in which macular edema had once resolved but recurred afterward, and a nonrecurrent group in which the resolution of macular edema was permanent. The investigation of predictive factors showed a significantly shorter elapsed time for the nonrecurrent group than for the recurrent group ( $15.7 \pm 8.9$  vs.  $29.7 \pm 29.5$  weeks, respectively;  $P = 0.036$ ). Other preoperative factors such as age, gender and visual acuity showed no significant difference. This leads to the conclusion that early intravitreal treatment with bevacizumab in BRVO may suppress macular edema recurrence.

Duration of macular edema has a direct impact on the results of intravitreal treatment<sup>[1]</sup>. In GENEVA, only 16.4% of patients were treated with intravitreal dexamethasone implant after a disease duration  $< 3$  months, the majority presented with macular edema duration between 3 and 6 months (51.3%) or longer (32.3%). In trials investigating triamcinolone (SCORE BRVO/ CRVO) and anti-VEGF agents (BRAVO, CRUISE, GALILEO, COPERNICUS) the proportion of patients with a duration of macular edema  $< 3$  months was significantly higher: SCORE BRVO  $> 50\%$ , SCORE CRVO 36%, BRAVO 51.5-53.8%, CRUISE 51.5-61.5%<sup>[1, 34]</sup>. Thus, comparison between trials must be performed with caution. Factors to predict patients' response to treatment before the first injection remain to be determined. Results of head-to-head studies, guaranteeing comparable baseline characteristics of patient populations, may provide conclusive results for comparison of the various agents.

## TERMINATION OF THERAPY

According to our recommended scheme, first re-evaluation takes place after the upload of 3 monthly anti-VEGF injections (Figure 1)<sup>[18]</sup>. Recommendation for patients with stable vision and no fluid on OCT is PRN treatment with frequent evaluations; initially monthly which can be further extended when no macular edema re-occurs.



Patients with some improvement in visual acuity but evidence of fluid on OCT are retreated with 3 monthly doses. If the response is less than expected, a change to another anti-VEGF agent or steroid may be considered. In BRVO, additional grid laser treatment can be considered in persistent macular edema.

If no improvement or worsening of BCVA occurs fluorescein angiography should be considered to assess for central ischemia and peripheral ischemia as well as other complications or causes of suboptimal response. Results of angiography serve as a guide for future therapeutic approaches. If there is no chance of visual improvement due to macular ischemia or scarring, intravitreal therapy should be terminated. A switch of agents is not recommended in such conditions. If peripheral ischemia with or without proliferative changes is seen, retinal laser photocoagulation is recommended to prevent patients from secondary glaucoma or intravitreal haemorrhage.

## ROLE OF PERIPHERAL LASER PHOTOCOAGULATION IN ISCHEMIC RVO

With the emerging techniques of wide-field-angiography peripheral ischemia can be examined better than before using the standard 7-field ETDRS-scheme. It is worth investigating the complete periphery to understand RVO better and to address pathophysiological changes which could not be observed until recently. Patients may benefit from targeted laser photocoagulation of non-perfused areas due to less VEGF load in the vitreous. This might lead to a better response to anti-VEGF treatment and/or a reduced number of injections. Evidence is growing for or against this hypothesis and the role of ischemia is in the focus of current discussions.

### Ischemic BRVO

It seems to be useful to treat peripheral non-perfused areas with targeted retinal photocoagulation early in BRVO to reduce the frequency of injections needed<sup>[8]</sup>. In the study 38 patients were enrolled and randomized to two groups. One group received 1,25 mg of intravitreal bevacizumab alone monthly and the other group received adjunctive targeted retinal photocoagulation of peripheral non-perfused areas. The first laser treatment was administered 2 weeks prior to injection. All patients enrolled had an area of non-perfusion of at least 5 disc areas, and a duration of vision loss of no longer than 6 months. Thus all patients presented with rather fresh BRVO and were treated promptly. BCVA significantly improved in the group with additional laser therapy but not in the group with intravitreal treatment alone. Patients needed 2.58 injections of bevacizumab during 6 months compared to those patients with adjunctive targeted laser therapy who needed 1.83 injections. A scientific explanation can be that the destruction of retinal areas expressing VEGF may lead to sustained reduction of the VEGF expression and thereby reduces the frequency of injections.

### Ischemic CRVO

There is evidence that early peripheral laser photocoagulation of non-perfused retinal areas improves visual acuity and leads to less recurrence of macular edema in patients with CRVO<sup>[9]</sup>. 22 patients with CRVO < 8 months, and an area of non-perfusion between 1 and 10 optic disc areas were randomized into two groups. One group received ranibizumab injections only and the other group received additional laser photocoagulation of peripheral retinal areas of non-perfusion. Patients with peripheral non-perfused areas (but without neovascularisations) treated with laser photocoagulation additive to ranibizumab injections showed a better improvement in BCVA

compared to ranibizumab injections alone after 18 months and less recurrence of macular edema on OCT. Rehak *et al* assume that early treatment is important.

Spaide *et al* didn't find a better BCVA in the IVT group with additional laser<sup>[35]</sup>. In comparison to data from Rehak's study, laser photocoagulation was not performed early from the start, but after at least 6 months delay. The delay of the laser therapy may be the reason for a less pronounced effect.

The effect of time of treatment may be observed in long-term data from the RELATE trial<sup>[36]</sup>. In contrary to Tomomatsu's and Rehak's data there is evidence that laser photocoagulation does not reduce macular edema or reduce the frequency of injections if performed after 18 months or more<sup>[36]</sup>. Champochiaro *et al* conducted a randomized, double-masked, controlled clinical trial with 39 patients with CRVO and 42 patients with BRVO with a mean duration of disease of 12.7 to 18.4 months. The core-study investigated the effect of ranibizumab 0.5 mg versus 2.0 mg for macular edema in BRVO and CRVO. Results did not show significant differences. At week 24 patients were re-randomized into the laser plus ranibizumab versus ranibizumab only group. Patients received peripheral laser photocoagulation if they required a ranibizumab injection on two consecutive visits. At the first laser treatment all areas of non-perfused retina were treated. If the patient needed ranibizumab injections again on two consecutive visits, laser photocoagulation was supplemented. There was no significant difference between groups at week 144 in patients with BRVO or CRVO. Champochiaro *et al* could not show any benefit of additional laser after 18 months of ranibizumab injections. The trial investigated patients with macular edema lasting 12 to 18 months who had recurrent or persistent macular edema despite many prior intraocular anti-VEGF or steroid injections. Duration of macular edema was 18 months or more before any additional laser treatment was initiated. The question remains, if without the great delay of laser treatment additional laser could have outreached ranibizumab alone.

In summary, there is good evidence for a supportive effect of targeted retinal laser photocoagulation early in the course of macular edema due to BRVO or CRVO. In later stages laser should not be applied to protect recurrence of macular edema but remains the standard-of-care for significant retinal ischemia to prevent complications.

## COMPARISON OF ANTI-VEGF AGENTS

A comparative, randomised, double-masked and controlled study to assess the efficacy and safety of intravitreal bevacizumab compared with ranibizumab in the treatment of macular edema due to BRVO was performed by Narayanan *et al* (MARVEL Report No. 1)<sup>[37]</sup>. In this prospective, non-inferiority trial, 75 participants with macular edema due to BRVO received intravitreal injections of ranibizumab ( $n = 37$ ) or bevacizumab ( $n = 38$ ). The primary outcome measure was the difference in mean changes in BCVA at 6 months. Secondary outcome measures included mean change in CRT, the proportion of patients improving by >15 letters and the proportion of patients developing neovascularisation. At 6 months, the mean gains in BCVA were +18.1 letters ( $p < 0.0001$ ; 95% CI, +12.8 to +22.6) in the ranibizumab group and +15.6 letters ( $p < 0.0001$ ; 95% CI +12.0 to +20.5) in the bevacizumab group. The difference between the mean visual gains of the treated groups was -2.5 letters (95% CI -8.0 to +5.0;  $p = 0.74$ ). Mean reductions in CRT at 6 months were  $177.1 \pm 122.3$  mm in the ranibizumab group ( $p < 0.0001$ ) and  $201.7 \pm 166.2$  mm in the bevacizumab group ( $p < 0.0001$ ), with no significant difference between the two groups ( $p = 0.48$ ). The mean numbers of

ranibizumab and bevacizumab injections were  $3.2 \pm 1.5$  and  $3.0 \pm 1.4$ , respectively ( $p=0.55$ ). This study demonstrated no difference between the significant gain in visual acuity in eyes with BRVO treated with either bevacizumab or ranibizumab. It also showed PRN to be an effective strategy in maintaining the visual gain in eyes treated with bevacizumab or ranibizumab.

## COMPARISON BETWEEN ANTI-VEGF AND STEROIDS

COMRADE-B and COMRADE-C ([www.clinicaltrials.gov](http://www.clinicaltrials.gov); COMRADE-BNCT01396057; COMRADE-CNCT01396083) are prospective, randomized, controlled head-to-head trials investigating intravitreal ranibizumab versus dexamethasone implant due to macular edema secondary to BRVO and CRVO. Results have been presented but not published yet.

The COMRADE-B is a 6-month phase IIIb multicenter double-masked study<sup>[38]</sup>. Patients were randomized to receive either intravitreal ranibizumab 0.5 mg ( $n = 126$ ) or dexamethasone 0.7 mg implant ( $n = 118$ ). Patients in the intravitreal ranibizumab arm received monthly injections until stable visual acuity for 3 consecutive months, followed by PRN re-treatment. Patients in the dexamethasone arm received an implant at baseline, thereafter sham injections according to intravitreal ranibizumab injection scheme (monthly/PRN). Main outcome measures were mean average change in BCVA from baseline to month 1 through month 6.

Mean average change in BCVA was superior with ranibizumab compared to dexamethasone from baseline to month 1 through month 6 (+14.9 letters vs +10.1 letters;  $p < 0.0001$ ). At month 6, mean BCVA change was significantly higher with ranibizumab vs dexamethasone (+17.3 letters vs +9.2 letters;  $p < 0.0001$ ) and mean central retinal thickness reduction was significantly greater. At month 6, a significantly greater proportion of patients with intravitreal ranibizumab had  $\geq 15$ -letter gain vs dexamethasone (61.1% vs 37.3%;  $p = 0.0002$ ). Ocular adverse events were reported in more dexamethasone recipients than in intravitreal ranibizumab recipients (62.7% vs 48.4%), especially more dexamethasone recipients had elevated IOP (14.4% vs 1.6%). Within the treatment scheme used, COMRADE-B demonstrated superiority of ranibizumab over dexamethasone in patients with macular edema secondary to BRVO over 6 months of treatment.

It is important to see it in the context that the primary endpoint was set at month 6, this is the interval where usually another dose of dexamethasone would be applied.

In the comparative, retrospective study of Kim *et al* the functional and anatomical outcomes of intravitreal bevacizumab (44 eyes; mean injections:  $2.92 \pm 1.38$ ) were compared to those of dexamethasone implant (28 eyes; mean injections:  $1.71 \pm 0.47$ ) for macular edema associated with BRVO<sup>[39]</sup>. Patients received either 1.25 mg intravitreal bevacizumab PRN (monthly follow-up) or 700 mg dexamethasone implant at 6-month intervals PRN and were followed for at least 12 months. Main outcome measures were changes in BCVA and central foveal thickness. The results showed no statistically significant difference of mean change of BCVA between both groups at monthly visits, up to 12 months (all  $p > 0.05$ ). Both groups showed statistically similar improvement of central foveal thickness at monthly visits, up to 5 months (all  $p > 0.05$ ); however, it began to deteriorate after 5 months in the dexamethasone implant group. After a second dexamethasone implant injection at 6 months the central foveal thickness significantly improved, and there was no significant difference of between both groups until 12 months.

Summarising, for macular oedema secondary to BRVO, intravitreal bevacizumab administered PRN monthly and dexamethasone implant injection administered PRN at 6-month intervals, yielded functionally and anatomically comparable outcomes at 12 months.

A drawback of this study is the retrospective character. Furthermore, injection intervals of dexamethasone implant tend to be 4 months in real-life settings. Evidence from RCTs allowing reinjection at 4 months intervals is missing yet. Thus comparison between anti-VEGF and intravitreal steroids remains difficult.

## METAANALYSIS

In the meta-analysis of Regnier *et al* eight RCTs evaluating the efficacy and safety of treatments for macular edema secondary to BRVO were identified and evaluated<sup>[40]</sup>. Inclusion/exclusion criteria for the key variables baseline BCVA and duration of disease were matched in the RCTs evaluating anti-VEGF therapy. Despite matching for baseline (BCVA) and duration of disease, substantial heterogeneity existed between anti-VEGF RCTs. The main limitation of the study was that two clinical trials were not yet published in the peer-reviewed literature and therefore, their quality could not be assessed. This analysis confirms that anti-VEGF monotherapies are more efficacious than laser therapy. A key finding was that the efficacy of grid laser was similar to sham intervention, suggesting that the role of macular laser in the treatment of BRVO should be reappraised.

This analysis confirms the superiority, in terms of letters gained in BCVA, of ranibizumab monotherapy over dexamethasone implant. It also showed that there were no statistical differences between ranibizumab monotherapy and aflibercept.

## CONCLUSIONS/SUMMARY

Current recommendations for treatment of macular edema secondary to BRVO or CRVO favour intravitreal anti-VEGF agents compared to intravitreal steroids. An upload of 3 injections is reasonable to address intravitreal VEGF levels. Prognosis for visual improvement is good and time to treatment is crucial. There is evidence that an early targeted laser photocoagulation of ischemic areas may lead to additional treatment effects, less injections and improved prognosis if administered early after RVO. In the course of the disease patients must be frequently monitored for recurrence of edema to initiate re-treatment and for conversion to ischemic RVO. Ischemia, proliferations and rubeosis iridis must not be treated with intravitreal anti-VEGF alone. Laser treatment of peripheral retina remains the standard-of-care to treat ischemia.

## CONFLICT OF INTERESTS

The authors declare that they do not have conflict of interests.

## REFERENCES

1. Pielon, A., *et al*, Efficacy and safety of intravitreal therapy in macular edema due to branch and central retinal vein occlusion: a systematic review. *PLoS One* 2013. 8(10): p. e78538.
2. Yamada, R., *et al*, Predictive factors for recurrence of macular edema after successful intravitreal bevacizumab therapy in branch retinal vein occlusion. *Jpn J Ophthalmol* 2015. 59(6): p. 389-93.
3. Pielon, A., *et al*, Ranibizumab for Branch Retinal Vein Occlusion Associated Macular Edema Study (RABAMES): six-month results of a prospective randomized clinical trial. *Acta Ophthalmol* 2015. 93(1): p. e29-37.

4. Lardenoye, C.W., *et al*, Photoreceptor function in eyes with macular edema. *Invest Ophthalmol Vis Sci* 2000. 41(12): p. 4048-53.
5. Parodi, M.B., Central vein occlusion and laser treatment. *Arch Ophthalmol* 1995. 113(5): p. 555.
6. Patz, A., Argon laser photocoagulation for macular edema in branch vein occlusion. *Am J Ophthalmol* 1984. 98(3): p. 374-5.
7. McIntosh, R.L., *et al*, Natural history of central retinal vein occlusion: an evidence-based systematic review. *Ophthalmology* 2010. 117(6): p. 1113-1123 e15.
8. Tomomatsu, Y., *et al*, Comparative study of combined bevacizumab/targeted photocoagulation vs bevacizumab alone for macular oedema in ischaemic branch retinal vein occlusions. *Acta Ophthalmol* 2015.
9. Rehak, M., *et al*, Early peripheral laser photocoagulation of non-perfused retina improves vision in patients with central retinal vein occlusion (Results of a proof of concept study). *Graefes Arch Clin Exp Ophthalmol* 2014. 252(5): p. 745-52.
10. Meyer, C.H. and F.G. Holz, Preclinical aspects of anti-VEGF agents for the treatment of wet AMD: ranibizumab and bevacizumab. *Eye (Lond)* 2011. 25(6): p. 661-72.
11. Xu, L., *et al*, Pharmacokinetics of ranibizumab in patients with neovascular age-related macular degeneration: a population approach. *Invest Ophthalmol Vis Sci* 2013. 54(3): p. 1616-24.
12. Ferrara, N., *et al*, Development of ranibizumab, an anti-vascular endothelial growth factor antigen binding fragment, as therapy for neovascular age-related macular degeneration. *Retina* 2006. 26(8): p. 859-70.
13. Holash, J., *et al*, VEGF-Trap: a VEGF blocker with potent antitumor effects. *Proc Natl Acad Sci U S A* 2002. 99(17): p. 11393-8.
14. Brown, D.M., *et al*, Intravitreal aflibercept injection for macular edema secondary to central retinal vein occlusion: 1-year results from the phase 3 COPERNICUS study. *Am J Ophthalmol* 2013. 155(3): p. 429-437 e7.
15. Papadopoulos, N., *et al*, Binding and neutralization of vascular endothelial growth factor (VEGF) and related ligands by VEGF Trap, ranibizumab and bevacizumab. *Angiogenesis* 2012. 15(2): p. 171-85.
16. Stewart, M.W., Aflibercept (VEGF-TRAP): the next anti-VEGF drug. *Inflamm Allergy Drug Targets* 2011. 10(6): p. 497-508.
17. Avery, R.L., *et al*, Systemic pharmacokinetics following intravitreal injections of ranibizumab, bevacizumab or aflibercept in patients with neovascular AMD. *Br J Ophthalmol* 2014. 98(12): p. 1636-41.
18. Berger, A.R., *et al*, Optimal Treatment of Retinal Vein Occlusion: Canadian Expert Consensus. *Ophthalmologica* 2015. 234(1): p. 6-25.
19. Feltgen, N. and A. Pielon, [Retinal vein occlusion: Epidemiology, classification and clinical findings]. *Ophthalmologe* 2015. 112(7): p. 607-18; quiz 619-20.
20. Feltgen, N. and A. Pielon, [Retinal vein occlusion: Therapy of retinal vein occlusion]. *Ophthalmologe* 2015. 112(8): p. 695-704; quiz 705-6.
21. Chin-Yee, D., *et al*, A systematic review of as needed versus treat and extend ranibizumab or bevacizumab treatment regimens for neovascular age-related macular degeneration. *Br J Ophthalmol* 2015.
22. Rayess, N., *et al*, Treatment outcomes after 3 years in neovascular age-related macular degeneration using a treat-and-extend regimen. *Am J Ophthalmol* 2015. 159(1): p. 3-8 e1.
23. Holz, F.G., *et al*, VEGF Trap-Eye for macular oedema secondary to central retinal vein occlusion: 6-month results of the phase III GALILEO study. *Br J Ophthalmol* 2013. 97(3): p. 278-84.
24. Boyer, D., *et al*, Vascular endothelial growth factor Trap-Eye for macular edema secondary to central retinal vein occlusion: six-month results of the phase 3 COPERNICUS study. *Ophthalmology* 2012. 119(5): p. 1024-32.
25. Epstein, D.L., *et al*, Benefit from bevacizumab for macular edema in central retinal vein occlusion: twelve-month results of a prospective, randomized study. *Ophthalmology* 2012. 119(12): p. 2587-91.
26. Campochiaro, P.A., *et al*, Sustained benefits from ranibizumab for macular edema following central retinal vein occlusion: twelve-month outcomes of a phase III study. *Ophthalmology* 2011. 118(10): p. 2041-9.
27. Ip, M.S., *et al*, A randomized trial comparing the efficacy and safety of intravitreal triamcinolone with observation to treat vision loss associated with macular edema secondary to central retinal vein occlusion: the Standard Care vs Corticosteroid for Retinal Vein Occlusion (SCORE) study report 5. *Arch Ophthalmol* 2009. 127(9): p. 1101-14.
28. Chan, C.K., *et al*, SCORE Study report #11: incidences of neovascular events in eyes with retinal vein occlusion. *Ophthalmology* 2011. 118(7): p. 1364-72.
29. Brown, D.M., *et al*, Sustained benefits from ranibizumab for macular edema following branch retinal vein occlusion: 12-month outcomes of a phase III study. *Ophthalmology* 2011. 118(8): p. 1594-602.
30. Campochiaro, P.A., *et al*, Intravitreal aflibercept for macular edema following branch retinal vein occlusion: the 24-week results of the VIBRANT study. *Ophthalmology* 2015. 122(3): p. 538-44.
31. Haller, J.A., *et al*, Dexamethasone intravitreal implant in patients with macular edema related to branch or central retinal vein occlusion twelve-month study results. *Ophthalmology* 2011. 118(12): p. 2453-60.
32. Heier, J.S., *et al*, Ranibizumab for macular edema due to retinal vein occlusions: long-term follow-up in the HORIZON trial. *Ophthalmology* 2012. 119(4): p. 802-9.
33. Campochiaro, P.A., *et al*, Long-term outcomes in patients with retinal vein occlusion treated with ranibizumab: the RETAIN study. *Ophthalmology* 2014. 121(1): p. 209-19.
34. Coscas, G., *et al*, Management of retinal vein occlusion--consensus document. *Ophthalmologica*, 2011. 226(1): p. 4-28.
35. Spaide, R.F., Prospective study of peripheral panretinal photocoagulation of areas of nonperfusion in central retinal vein occlusion. *Retina* 2013. 33(1): p. 56-62.
36. Campochiaro, P.A., *et al*, Scatter Photocoagulation Does Not Reduce Macular Edema or Treatment Burden in Patients with Retinal Vein Occlusion: The RELATE Trial. *Ophthalmology* 2015. 122(7): p. 1426-37.
37. Narayanan, R., *et al*, A randomised, double-masked, controlled study of the efficacy and safety of intravitreal bevacizumab versus ranibizumab in the treatment of macular oedema due to branch retinal vein occlusion: MARVEL Report No. 1. *Br J Ophthalmol* 2015. 99(7): p. 954-9.
38. Hattenbach, L.-O., Efficacy and Safety of 0.5 mg Ranibizumab compared with 0.7 mg dexamethasone intravitreal implant in patients with branch retinal vein occlusion over 6 months: the COMRADE-B study. *Invest Ophthalmol Vis Sci* 2014. 55: p. 1830.
39. Kim, M., *et al*, Comparison of intravitreal bevacizumab and dexamethasone implant for the treatment of macula oedema associated with branch retinal vein occlusion. *Br J Ophthalmol* 2015. 99(9): p. 1271-6.
40. Regnier, S.A., *et al*, Comparative efficacy and safety of approved treatments for macular oedema secondary to branch retinal vein occlusion: a network meta-analysis. *BMJ Open* 2015. 5(6): p. e007527.