

Definition and Classification of Retinal Vein Occlusion

Petr Kolar

Petr Kolar, MD, PhD, Associate Professor of Ophthalmology at Masaryk University, University Eye Clinic of Masaryk University and University Hospital Brno, Jihlavská 20, 625 00 Brno, Czech Republic

Correspondence to: Petr Kolar, MD, PhD, Associate Professor of Ophthalmology at Masaryk University, University Eye Clinic of Masaryk University and University Hospital Brno, Jihlavská 20, 625 00 Brno, Czech Republic

Email: pe.kolar@gmail.com

Telephone: +420 5 3223 3263

Fax: +420 5 3223 3406

Received: November 29, 2015

Revised: April 18, 2016

Accepted: April 20, 2016

Published online: June 28, 2016

ABSTRACT

Retinal vein occlusion is second most common retinal vascular disease after diabetic retinopathy. A main cause of the retinal vein occlusion is arterial disease when arterial stiffness affects neighboring vein. There are three main types of retinal vein occlusion: central retinal vein occlusion, hemicentral retinal vein occlusion and branch retinal vein occlusion. Central retinal vein occlusion and hemicentral retinal vein occlusion can be further divided into non-ischemic and ischemic types. Branch retinal vein occlusion can be further divided into major branch retinal vein occlusion and macular branch retinal vein occlusion based on the location of the occlusion. Retinal vein occlusion is a major cause of vision loss. Of the two main types of retinal vein occlusion, branch retinal vein occlusion, is 4- to 6-times more prevalent than central retinal vein occlusion. A common risk factor for retinal vein occlusion is advancing age, and additional risk factors include systemic conditions such as hypertension, arteriosclerosis, diabetes mellitus, hyperlipidemia, vascular cerebral stroke, blood hyperviscosity and thrombophilia. Ophthalmic risk factors for retinal vein occlusion are ocular hypertension and glaucoma, higher ocular perfusion pressure and changes in the retinal arteries.

Key words: Retinal vein occlusion; Definition; Classification; Fluorescein angiography; Optical coherence tomography

© 2016 The Author. Published by ACT Publishing Group Ltd.

Kolar P. Definition and Classification of Retinal Vein Occlusion. *International Journal of Ophthalmic Research* 2016; 2(2): 124-129 Available from: URL: <http://www.ghrnet.org/index.php/ijor/article/view/1499>

INTRODUCTION

Retinal vein occlusion (RVO) was first described in 1855 by Liebreich and in 1878 by Michel^[1], who indicated that RVO was a complication of systemic vascular status that can be observed on the fundus of the eye. Disease was named as Apoplexia retinae. This type of occlusion was later described as the central retinal vein occlusion (CRVO). Leber, in 1877, and Oeller, in 1896, described branch retinal vein occlusion (BRVO)^[2,3].

There are three main types of retinal vein occlusion: central retinal vein occlusion, hemicentral retinal vein occlusion and branch retinal vein occlusion.

RVO is the second most common retinal vascular disease after diabetic retinopathy. Studies in overall populations showed that its prevalence varies from 5.2 to 16 per 1,000^[4].

RVO is more prevalent in men than women and it is more frequent in older people, over 65 years of age^[4], and BRVO is four times more common than CRVO^[4].

The most recognized risk factors for RVO are age and systemic vascular disorders. In over half of the cases, the age of onset is over 65 years. However, patients under 45 years of age can also develop an RVO^[5]. Systemic diseases such as hypertension, hyperlipidemia and diabetes mellitus are strongly associated with the development of RVO^[6]. Further systemic risk factors are vascular cerebral stroke, blood hyperviscosity and thrombophilia^[6]. Cigarette smoking has also been linked to RVO^[7].

Ophthalmic risk factors for RVO are ocular hypertension and glaucoma, lower ocular perfusion pressure and congenital and

acquired changes in retinal arteries^[8].

The natural course of RVO leads to a decrease in visual acuity if the macula lutea is affected by retinal hemorrhages and macula edema^[8].

DEFINITION OF RETINAL VEIN OCCLUSION

RVO can be defined as a retinal vascular disorder characterized by congestion and dilatation of the retinal veins with subsequent retinal hemorrhages and edema, retinal ischemia including cotton wool spots, retinal exudates and macular edema^[9].

RVO is an occlusion of either the central retinal vein or a branch of the retinal vein, and its pathogenesis is not completely understood. The condition may be because of a combination of three systemic changes known as Virchow's triad (Figure 1), which includes hemodynamic changes (venous stasis), degenerative changes of the vessel wall and blood hypercoagulability^[5,10]. Clinical features and severity vary according to the location of the retinal vein closure. Generally, patients with BRVO have a better prognosis than patients with CRVO.

Until the introduction of anti-VEGF treatment, patients' prognosis for both conditions was poor. Many CRVO patients lose vision as a result of ischemic complications such as secondary neovascular glaucoma and macular edema.

CLASSIFICATION OF RETINAL VEIN OCCLUSION

RVO can be classified into three main types, according to the affected area on the retinal surface: CRVO, HCRVO and BRVO. BRVO is more common than CRVO. In BRVO, a branch of the retinal venous system is occluded, while in CRVO, the occlusion is located in the central retinal vein^[11-16]. BRVO is divided further into major BRVO and macular BRVO. CRVO is divided into ischemic and non-ischemic types^[12,13]. And HCRVO, which involves only one-half of the retinal surface and, similar to CRVO, it is divided into ischemic and non-ischemic types^[17].

According to the ischemic status, CRVO and HCRVO are divided into ischemic and non-ischemic types. Ischemic CRVOs are less common, accounting for one-third of CRVOs, and the other two-thirds are non-ischemic CRVOs^[13,18]. Retinal ischemia in RVO is a strong prognostic factor, and patients whose eyes have large ischemic zones have a worse prognosis than patients whose eyes have small ischemic areas. Non-ischemic RVOs can progress to ischemic forms. This progression is time dependent, with a progression rate of 33% within 3 years^[19]. Neovascular complications may arise in 50% of patients whose eyes have ischemic CRVO in a 4-year period, despite treatment with anti-VEGF^[20]. Raised intraocular pressure and raised erythrocyte sedimentation can be found in CRVO^[7,8,17]. In opposite hypermetropia, arteriosclerosis and hypertension are more common in BRVO^[7,8,17].

CENTRAL RETINAL VEIN OCCLUSION

Clinical findings in patients with CRVO depend on the degree of central retinal vein occlusion, and the degree of venous congestion is also important. A patient with a low degree of venostasis and good visual acuity can be diagnosed, but there are patients with a high degree of venostasis and poor visual acuity. The degree of venostasis correlates well with visual acuity^[21].

Ophthalmoscopic finding in the eye affected with CRVO

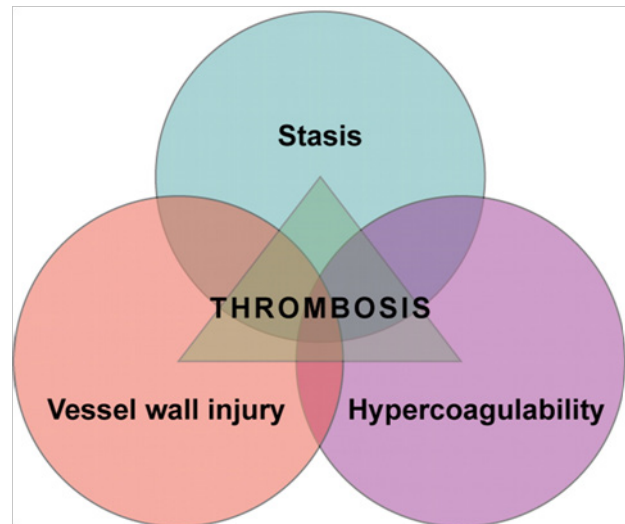


Figure 1 Virchow's triad.

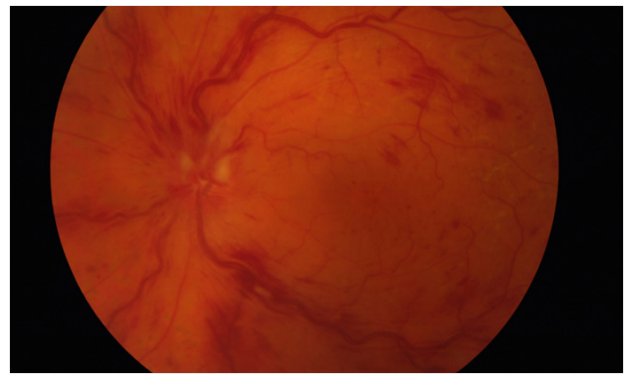


Figure 2 Color fundus image of non-ischemic central retinal vein occlusion, venous dilatation and retinal hemorrhages are present.

includes signs of venous stasis. The venous system is dilated and tortuous, and retinal hemorrhages are present in all four quadrants. Hemorrhages are most often intra-retinal, but pre-retinal and sub-retinal hemorrhages may also be present (Figure 2). Hemorrhages are located predominantly on the posterior pole near the optic disc and macula lutea. In ischemic CRVOs, hemorrhages are spread throughout the retina, and a typical sign is swelling of the optic disc. Hemorrhages usually cover the surface of the optic nerve.

Figure 2 Color fundus image of non-ischemic CRVO (original author photo).

Basic signs of ischemia are cotton wool spots, retinal edema and macular edema. Cotton wool spots have a typical white color and an appearance like a cotton ball. Hard exudates are usually detected on the edges of ischemic zones. They have a white or white-yellow color and they are formed by accumulation of blood lipids.

In the acute phase of CRVO, the degree of ischemia is usually high. This is related to low visual acuity because of macular edema. In the chronic phase of CRVO, visual acuity decreases but not as much as in acute CRVO. However, chronic occlusion is indicated by the presence of neovascularization either on the iris or in the retina. Gonioscopy can detect neovascularization in the iridocorneal angle.

According to the Central Retinal Vein Occlusion Study Group, CRVO is divided into two major forms: non-ischemic and ischemic. Classification of these two types of CRVO is based on fluorescein angiography (FA) finding. Non-ischemic CRVO is characterized by less than 10 disc areas (DA) of ischemia presented on FA, with no retinal neovascularization. The ischemic type of CRVO is the more

advanced type of RVO and it is characterized by either retinal or iris neovascularization, with retinal ischemia greater than 10 DA on FA. CRVOs with a large number of hemorrhages are recommended to be classified as ischemic CRVOs^[19]. Up to 83% of non-ischemic CRVOs with large hemorrhages were later reclassified as ischemic occlusions.

HEMICENTRAL RETINAL VEIN OCCLUSION

In 1980, Hayreh described HCRVO as a separate clinical entity^[22]. Hedemon strated that during embryonic life, two trunks of the central retinal vein exist, and one trunk usually disappears before birth. However, in 20% of subjects, both trunks may persist^[23]. HCRVO involves occlusion of one of the two trunks, as described above. Half of the retinal surface is thus affected by this occlusion.

Another clinical entity that can be interchanged with HCRVO was found. It is hemicentral BRVO. Hemicentral BRVO is occlusion of the major vein branch near the optic disc that may simulate HCRVO^[24]. Pathogenesis of both clinical entities is completely different. HCRVO involves occlusion of one trunk of the central retinal vein, while in hemicentral BRVO, the arterio-venous crossing near the optic disc is occluded^[16].

HCRVO is divided into ischemic and non-ischemic types, similar to CRVO. These two types are distinguished in a manner similar to that of CRVO. Non-ischemic HCRVO appears as ischemic zones that are less than 10 DA on FA, while the ischemic type has ischemia on more than 10 DA of the retinal surface. The ischemic type of HCRVO is less common, representing 19% of cases, while non-ischemic CRVO is present in 81% cases^[23].

HCRVO clinical findings are similar to those of CRVO, but only one-half of the retinal surface is involved. HCRVO usually involves the superior or inferior half of the retina. Retinal hemorrhages, cotton-wool spots, retinal edema and hard exudates can be seen on microscopic examination (Figure 3). Neovascularization on the iris or retinal surface are subsequently detectable. Collaterals are detected between two trunks of central retinal vein.

Figure 3. Color fundus image of non-ischemic HCRVO (with courtesy of <http://retinagallery.com/>).

The effect on visual acuity depends on the status of the macula lutea. Visual acuity is poor in patients with HCRVO, whose eyes have macular edema. The visual field is usually impaired in the corresponding retinal areas.

BRANCH RETINAL VEIN OCCLUSION

BRVO affects branches of the central retinal vein. Hayreh divided BRVO into two groups: major BRVO and macular BRVO^[16].

Major BRVO involves occlusion of 1 of the 4 major retinal vein branches, and it involves all retinal regions drained by this branch^[16]. Macular BRVO arises from occlusion of the macular branch of the retinal vein^[16].

Figure 4. Color fundus image of macular BRVO (with courtesy of <http://retinagallery.com/>).

Figure 5. Color fundus image of major BRVO (original author photo).

BRVO can be diagnosed in the nasal or temporal quadrants, or in the superior or inferior retinal quadrants. Nasally-located BRVOs are usually diagnosed incidentally because they are far away from the macula and they do not affect visual acuity. They may manifest as a vitreous hemorrhage from retinal neovascularization or as secondary neovascular glaucoma that result from neovascularization on the iris surface. Temporally located BRVOs usually affect the

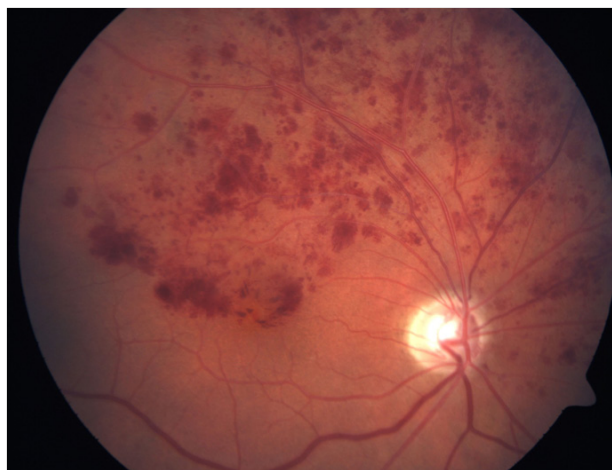

Figure 3 Color fundus image of non-ischemic hemicentral retinal vein occlusion, involvement of upper retinal quadrants.

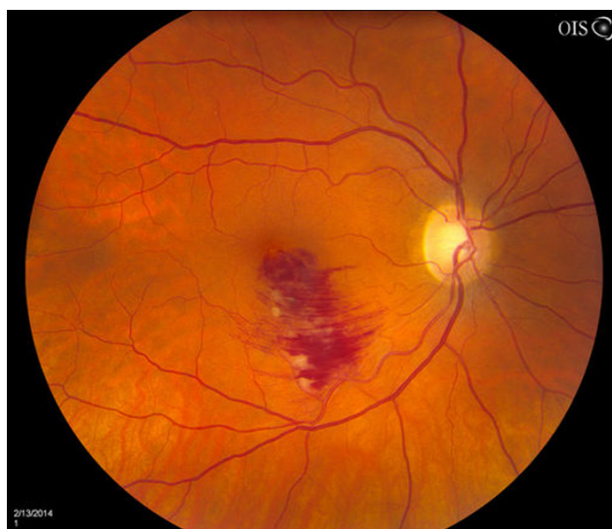

Figure 4 Color fundus image of macular branch retinal vein occlusion, lower part of macula lutea is involved.

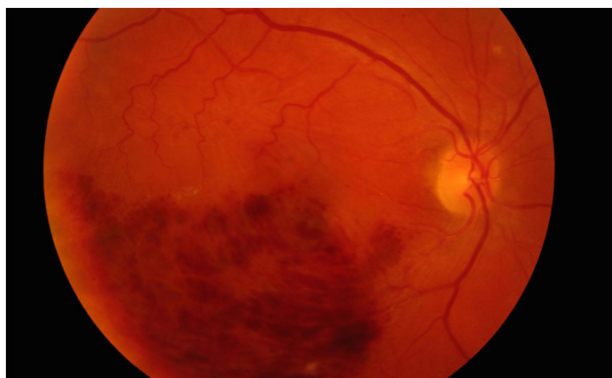


Figure 5 Color fundus image of major BRVO, lower part of retina is involved by edema and hemorrhages.

macula lutea, and they manifest as a decrease in visual acuity. Mainly superotemporally-located BRVOs tend to spread across the macula lutea because of the effect of gravity on the intra-retinal fluid. Some temporal BRVOs may be asymptomatic, similar to nasal BRVOs, if they are located a large distance away in the peripheral retina.

A main characteristic of BRVO is venous dilatation peripherally from the site of occlusion. Occlusion usually occurs on the arterio-venous crossing. Both vessels have a common adventitia and the

retinal artery compresses the retinal vein. An additional characteristic of BRVO is retinal hemorrhage. In severe cases, sub- or pre-retinal hemorrhages may be seen. Retinal edema is also present in affected areas, and if retinal ischemia is present, cotton-wool spots can be detected. Hard exudates can also be detected in the transition to ischemic and non-ischemic retina.

FA can detect vascular abnormalities and ischemic retinal areas, and it can also detect macular edema.

An important imaging method is optical coherence tomography (OCT). OCT is a non-invasive imaging test that uses light waves to take cross-section pictures of the retina. It can detect retinal edema, intra-retinal changes and cystoid remodeling of intra-retinal structures. It can also monitor treatment success.

Patients with BRVO have a good prognosis^[16,25,26], but prognosis depends on several anatomical facts^[9]: (1) localization of the occlusion. Patients with peripherally-located BRVOs have a better prognosis because of lack of macular involvement; (2) diameter of the occluded retinal vein. A larger vessel diameter leads to formation of more collateral circulation, and thereby better normalization of compromised circulation; and (3) degree of venous occlusion. This determines the degree of stasis in the retinal vasculature.

FLUORESCEIN ANGIOGRAPHY

FA is a useful diagnostic tool that can objectively evaluate retinal circulation. To perform FA we used intravenously-applied fluorescein dye. Fluorescein does not leak from physiologically normal vessels, but it does leak from vessels and capillaries affected by RVO leaks. The amount of leakage depends on the severity of the occlusion.

In CRVO, retinal hemorrhages are seen as a block of fluorescence. Places that are less affected by hemorrhages present as either fluorescein leakage or as non-perfusion caused by retinal ischemia (Figures 6, 7 and 8). Based on FA results, CRVO can be divided into non-ischemic and ischemic types. The non-ischemic type has areas of non-perfusion that are smaller than 10 DA in size, while the ischemic type has non-perfusion areas that are greater than 10 DA.

Figure 6 Early FA image in non-ischemic CRVO (original author photo).

Figure 7 Intermediate FA image in non-ischemic CRVO (original author photo).

Figure 8 Late FA image in non-ischemic CRVO (original author photo).

In the ischemic type, CRVOs are identified by retinal neovascularization. On FA, fluorescein leaks intensively in the early phases in ischemic areas. FA distinguishes between retinal collaterals and retinal neovascularization. The retinal collateral does not leak dye, while neovascularization is identified by leaking dye. FA can also detect therapeutic success in CRVO treatment. In successfully-treated CRVO, leakage diminishes.

In HCRVO, the findings are similar to those of CRVO, but only one-half of retinal surface is affected. Similar to CRVO, FA can detect ischemic or non-ischemic type of HCRVO. HCVO seems to be a rare condition.

In BRVO, FA represents an essential diagnostic tool, similar to that for CRVO and HCRVO, if there is any risk of development of macular edema. Similar to CRVO and HCRVO, there are many retinal hemorrhages that block fluorescence. When they disappear retinal blood flow can be much more easily examined. Non-perfused retinal areas can be detected and treated either by laser photocoagulation or anti-VEGF treatment.

Figure 9 Early FA image of major BRVO (original author photo).

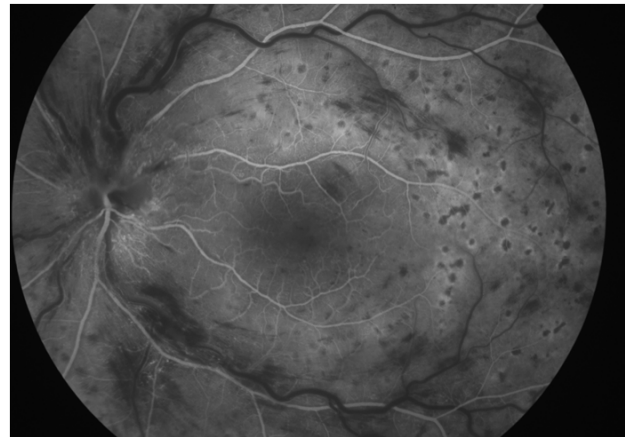


Figure 6 Early FA image in non-ischemic CRVO.

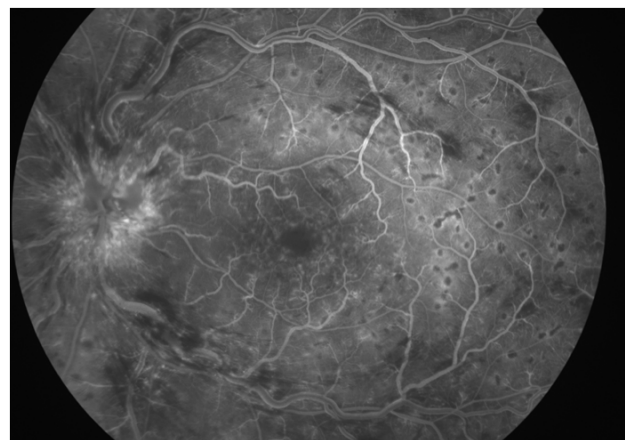


Figure 7 Intermediate FA image in non-ischemic CRVO.

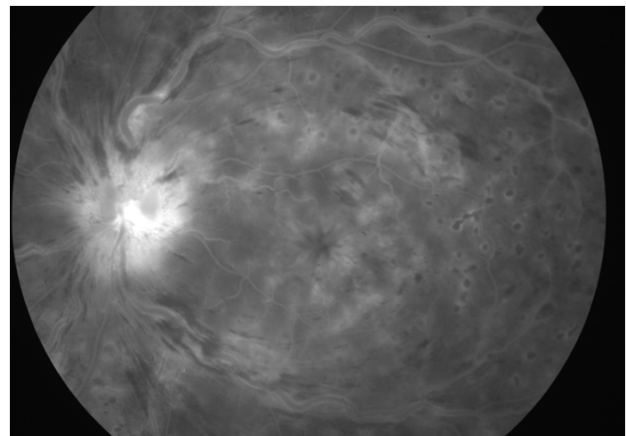


Figure 8 Late FA image in non-ischemic CRVO.

Figure 10 Late FA image of major BRVO (original author photo).

Figure 11 Early FA image of macular BRVO (original author photo).

Figure 12 Late FA image of macular BRVO (original author photo).

OPTICAL COHERENCE TOMOGRAPHY

OCT is a non-invasive imaging test. OCT can easily detect pathology in the retina and choroid on the posterior pole of the eye. This feature can be used to diagnose RVO.

In the acute phases of CRVO and BRVO, retinal edema can be detected if the posterior pole is affected. Macular edema is often combined with macular hemorrhage, and is caused by intra-retinal accumulation of fluid. In more advanced cases, sub-retinal accumulation of fluid can be detected. OCT can efficiently detect successful RVO therapy, which decreases the amount of retinal fluid.

Figure 13 OCT image of diffuse macular edema in CRVO (original author photo).

Although FA and OCT are important diagnostic tools for RVO, some functional tests like electroretinography (ERG), visual acuity,

visual fields, relative afferent pupillary defect (RAPD), color doppler imaging should play important role in diagnostics of RVO. They are of great importance especially for differentiation of ischemic from non-ischemic central retinal vein occlusion^[11].

SUMMARY

RVO is the second most common retinal vascular disease after diabetic retinopathy. The main systemic risk factors are systemic hypertension, hyperlipidemia and diabetes mellitus. Men are more often affected than women. The main ophthalmic risk factor for RVO is glaucoma.

There are three main types of RVO: CRVO, HCRVO and BRVO. CRVO is four times less common than BRVO, but patients with CRVO have a worse prognosis.

CRVO and HCRVO can be further divided into the non-ischemic and ischemic types. Their main difference is the amount of retinal ischemia. The non-ischemic type has less than 10 DA of ischemia, while the ischemic type has more than 10 DA of ischemia. Venous system dilatation, retinal hemorrhage, retinal edema, cotton-wool spots and hard exudates are clinical observations in CRVO and HCRVO.

BRVO can be further divided into major BRVO and macular BRVO, based on the location of the occlusion. Major BRVO affects one of the four major branches of the central retinal vein, and macular BRVO affects one of the macular branches of the central retinal vein. Macular edema is more commonly present in macular BRVO, and patients with an occlusion that is located peripherally have a better prognosis than those with a central occlusion. Diagnostic tools such as FA and OCT assist in the diagnosis and treatment of RVO.

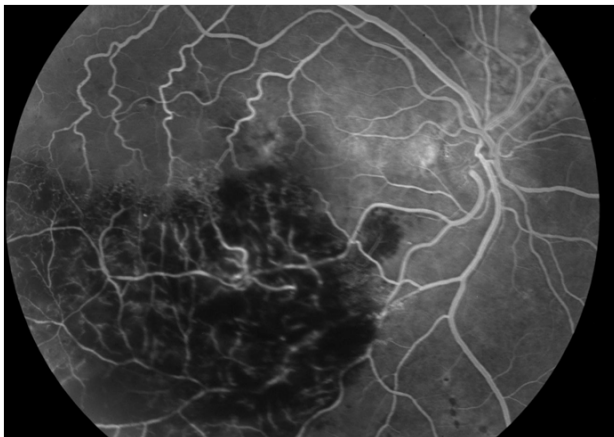


Figure 9 Early FA image of major BRVO.

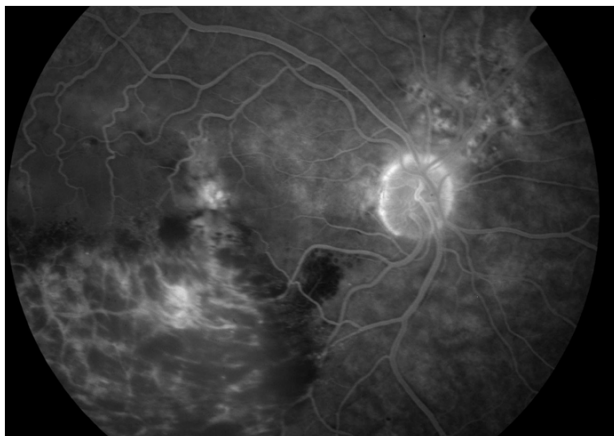


Figure 10 Late FA image of major BRVO.

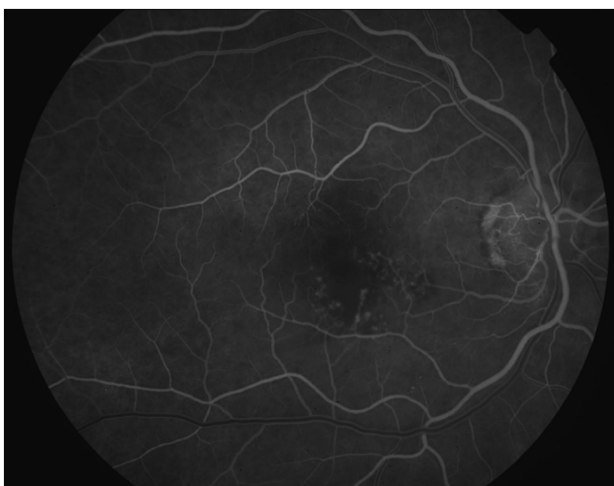

Figure 11 Early FA image of macular BRVO.

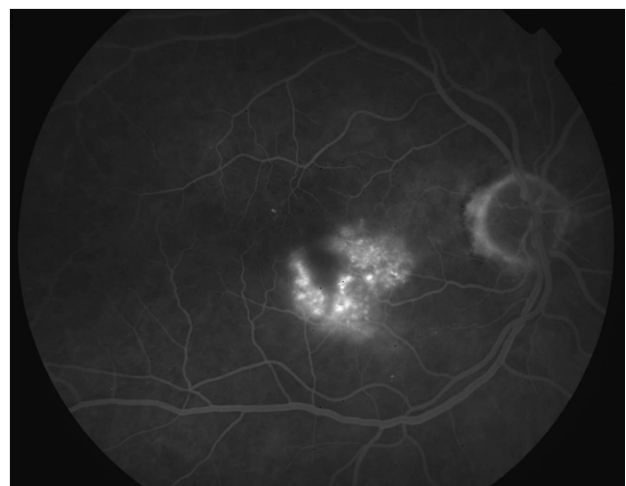

Figure 12 Late FA image of macular BRVO.

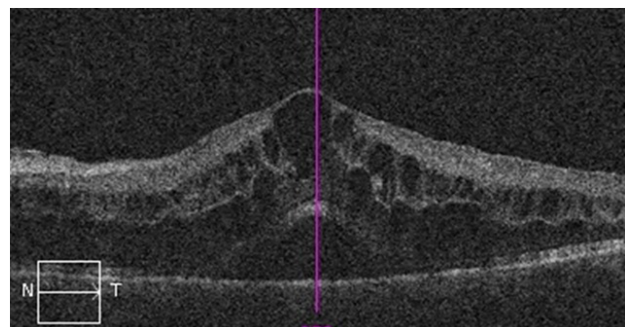


Figure 13 OCT image of diffuse macular edema in CRVO.

COMPETING INTERESTS

The author declares that there is no conflict of interest regarding the publication of this paper.

REFERENCES

- Michel J. Ueber die anatomischen Ursachen von Veranderungendes Augenhintergrundesbeieinigen Allgemeinerkrankungen. *Deutsch Arch Klin Med* 1878; **22**: 339-345.
- Leber T. Die Krankheiten der Netzhaut und des Sehnerven. In: Graefe-Saemisch. Handbuch der Gesamten Augenheilkunde. Leipzig: Verlag von Wilhelm Engelmann; 1877: 551.
- Oeller J. Atlas der Ophthlzaimoscopie. Wiesbaden, Germany: C. Tabs XIII; 1896-1899.
- Rogers S, McIntosh RL, Cheung N, Lim L, Wang JJ, Mitchell P, Kowalski JW, Nguyen H, Wong TY; International Eye Disease Consortium. The prevalence of retinal vein occlusion: pooled data from population studies from the United States, Europe, Asia, and Australia. *Ophthalmology* 2010; **117**: 313-319.
- Zhou JQ, Xu L, Wang S, Wang YX, You QS, Tu Y, Yang H, Jonas JB. The 10-year incidence and risk factors of retinal vein occlusion: The Beijing eye study. *Ophthalmology* 2013; **120**: 803-808.
- Mohamed Q, McIntosh RL, Saw SM, Wong TY. Interventions for central retinal vein occlusion: a evidence-based systematic review. *Ophthalmology* 2007; **114**: 507-519.
- Klein R, Klein BE, Moss SE, Meuer SM. The epidemiology of retinal vein occlusion: the Beaver Dam Eye Study. *Trans Am Ophthalmol Soc* 2000; **98**: 133-141.
- Kolar P. Risk Factors for Central and Branch Retinal Vein Occlusion: A Meta-Analysis of Published Clinical Data. *Journal of Ophthalmology* 2014, Article ID 724780, 5 pages, 2014. doi: 10.1155/2014/724780.
- Coscas G, Loewenstein A, Augustin A, Bandello F, Battaglia Parodi M, Lanzetta P, Monés J, de Smet M, Soubrane G, Staurenghi G. Management of Retinal Vein Occlusion – Consensus Document *Ophthalmologica* 2011; **226**: 4-28
- Rehak J, Rehak M. Branch retinal vein occlusion: pathogenesis, visual prognosis, and treatment modalities. *Curr Eye Res* 2008; **33**: 111-131.
- Hayreh SS. Retinal vein occlusion. *Indian J Ophthalmol* 1994; **42**: 109-132
- Hayreh SS. Classification of central retinal vein occlusion. *Ophthalmology*. 1983 May; **90**(5): 458-474
- Hayreh SS. Differentiation of ischemic from non-ischemic central retinal vein occlusion during the early acute phase. *Graefes Arch Clin Exp Ophthalmol*. 1990; **228**(3): 201-217
- Hayreh SS, Zimmerman B, Podhajsky P. Incidence of various types of retinal vein occlusion and their recurrence and demographic characteristics. *Am J Ophthalmol* 1994; **117**: 429-441.
- Hayreh SS, Zimmerman MB. Fundus changes in branch retinal vein occlusion. *Retina* 2015; **35**: 1216-1227.
- Hayreh SS. Prevalent misconceptions about acute retinal occlusive disorders. *Prog Retin Eye Res* 2005; **24**: 493-519.
- Appiah AP, Trempe CL. Differences in contributory factors among hemi-central, central, and branch retinal vein occlusions. *Ophthalmology* 1989; **96**: 364-366.
- Hayreh SS. Ocular vascular occlusive disorders: Natural history of visual outcome. *Prog Retin Eye Res*. 2014; **0**: 1-25.
- CVOS-Group. Natural history and clinical management of central retinal vein occlusion. The Central Vein Occlusion Study Group. *Arch Ophthalmol* 1997; **115**: 486-491.
- Brown DM, Wykoff CC, Wong TP, Mariani AF, Croft DE, Schuetzle KL et al. Ranibizumab in preproliferative (ischemic) central retinal vein occlusion: the rubeosis anti-VEGF (RAVE) trial. *Retina* 2014; **34**: 1728-1735.
- Feltgen N, Pielen A. Retinaler Venenverschluss. Epidemiologie, Einteilung und klinische Befunde. *Ophthalmologie* 2015; **112**: 607-620.
- Hayreh SS, Hayreh MS. Hemi-central retinal vein occlusion. Pathogenesis, clinical features, and natural history. *Arch Ophthalmol* 1980; **98**: 1600-1609.
- Chopdar A. Hemi-central retinal vein occlusion. Pathogenesis, clinical features, natural history and incidence of dual trunk central retinal vein. *Trans Ophthalmol Soc U K* 1982; **102**: 241-248.
- Hayreh SS, Zimmerman MB. Hemicentral retinal vein occlusion. Natural history of visual outcome. *Retina* 2012; **32**: 68-75.
- Rehak M, Wiedemann P. Retinal vein thrombosis: Pathogenesis and management. *Journal of Thrombosis and Haemostasis* 2010; **8**: 1886-1894.
- Jaulim A, Ahmed B, Khanam T, Chatziralli IP. Branch retinal vein occlusion: epidemiology, pathogenesis, risk factors, clinical features, diagnosis, and complications. An update of the literature. *Retina* 2013; **33**: 901-910.

Peer reviewers: Carolina Arruabarrena, Oftalmología, Hospital "Príncipe de Asturias", Alcalá de Henares. 28805 Madrid, Spain; Petia Kupenova, MD, PhD, Associate Professor, Department of Physiology, Medical University-Sofia, 1 G Sofiiski St, 1431, Sofia, Bulgaria.