

## Clinical Diagnosis of Retinal Vein Occlusion

Daraius Shroff, Abhishek Kothari, Gagan Bhatia, Charu Gupta

Daraius Shroff, Gagan Bhatia, Charu Gupta, Shroff Eye Centre, A 9 Kailash Colony, New Delhi, India

Abhishek Kothari, Agarwal Eye Hospital, Jaipur, India

Correspondence to: Daraius Shroff, Shroff Eye Centre, A 9 Kailash Colony, New Delhi, India.

Email: [daraiuss@gmail.com](mailto:daraiuss@gmail.com)

Received: December 23, 2015

Revised: March 23, 2016

Accepted: March 28, 2016

Published online: June 28, 2016

### ABSTRACT

Retinal vein occlusions are among the commonest of vascular diseases affecting the retina. They may be the presenting sign of systemic disease and complications of retinal vein occlusion are associated with significant visual dysfunction. This article describes signs and symptoms associated with the spectrum of retinal vein occlusions. Clinical diagnosis is invaluable in identification of features of the disease, its complications and to indicate associated risk factors. Besides a description of conventional investigations, recent imaging modalities (Ultra-widefield angiography and OCT angiography) that have shed new light on vein occlusions are also briefly dealt with.

**Key words:** Central retinal vein occlusion; Branch retinal vein occlusion; Macular edema; Neovascular glaucoma; Investigations

© 2016 The Authors. Published by ACT Publishing Group Ltd.

Shroff D, Kothari A, Bhatia G, Gupta C. Clinical Diagnosis of Retinal Vein Occlusion. *International Journal of Ophthalmic Research* 2016; 2(2): 137-142 Available from: URL: <http://www.ghrnet.org/index.php/ijor/article/view/1548>

### INTRODUCTION

Occlusion of the retinal venous system is the second most common retinal vascular disease after diabetic retinopathy<sup>[1]</sup>. Population based studies have estimated the prevalence of central retinal vein

occlusion (CRVO) to be between 0.1 to 0.4%. The cumulative 10-year incidence of branch retinal vein occlusion (BRVO) in the age group above 49 years has been estimated to be 1.2%. The 15-year cumulative incidences of branch retinal vein occlusion and central retinal vein occlusion were 1.8% and 0.5%, respectively, in a large population based study<sup>[2]</sup>.

In the subsequent sections, we focus on the clinical presentation of these occlusions with their appearances during their natural history and alterations seen on investigations.

### CENTRAL RETINAL VEIN OCCLUSION

Central retinal vein occlusion is commonly seen in older individuals, with the prevalence rising sharply over the age of 65 years. The incidence does not vary with sex. Common co-morbidities in individuals with CRVO include hypertension, diabetes, atherosclerotic disease, hematological disorders, vasculitis and autoimmune disorders (in younger individuals). Infective pathologies like HIV, syphilis, are found less frequently. Ocular co-morbidities include glaucoma, retrolubar compression, optic nerve head drusen and crowded discs<sup>[3]</sup>.

Central retinal vein occlusion (CRVO) spans a clinical spectrum from mild alteration in venous flow apparent as an impending vein occlusion to a very severe predominantly occlusive ischemic CRVO. Based on the quantum of ischemia or capillary non-perfusion in the standard ETDRS fields, the Central retinal Vein Occlusion Study (CVOS) divided this spectrum into three major categories<sup>[4]</sup>. Ischemic CRVO (ICRVO) cases had more than 10 disc areas of capillary non-perfusion on fluorescein angiography of the eye, whereas non-ischemic CRVO (NICRVO) had less than this degree of non-perfusion. Between these arbitrary categories were a group of eyes where the amount of non-perfusion could not be reliably ascertained on angiography due to blocked fluorescence from retinal hemorrhages. This category was called indeterminate type.

Given that CRVO is not a static disease and may progress over time, these categories are not watertight and a large percentage (upto 80%) of indeterminate eyes turn out to be of the ICRVO type on follow up. Upto a third of patients having NICRVO at presentation convert to ICRVO patients over a three-year follow-up. Another

classification, proposed by Hayreh *et al* divides CRVO into the milder ‘venous stasis retinopathy’ and the more severe ‘hemorrhagic retinopathy’ group<sup>[5]</sup>. These subgroups are important in the clinical description of the disease, as there are distinct differences in their clinical manifestations and course.

## SYMPTOMS

The most common complaint in patients with CRVO is a sudden painless diminution of vision. It may present as mild, transient obscurations, intermittent blurring and have a stuttering course in impending CRVO or NICRVO. It is usually abrupt and severe in cases with ICRVO. Patients usually have a history of the co-morbid systemic or ocular disease, though up to a third may have no such history and may require special work-up.

## SIGNS<sup>[6-10]</sup>

Visual acuity drop in cases of CRVO may vary from minimal to profound depending upon the severity of block, presence of macular ischemia and macular edema. Visual acuity of 20/400 or less identifies up to 91% of cases with ICRVO. The visual acuity at presentation has great prognostic value. (Table 1)<sup>[4]</sup>.

The pupillary light reflex in CRVO has significant diagnostic and prognostic value. It is non-invasive and objective and provides reliable information even in cases with hazy media and extensive retinal hemorrhages. Presence of relative afferent pupillary defect is a reliable marker for CRVO, with a high degree of sensitivity and specificity. The appearance of RAPD in a case of CRVO is among the earliest indicators of conversion of NICRVO to ICRVO.

The various retinal signs that CRVO presents with include retinal haemorrhages, venous engorgement and tortuosity, cotton wool spots, optic disc edema and macular edema.

Intraretinal hemorrhages in CRVO can be superficial (‘flame shaped’) or deeper retinal (‘blot’), though the former predominate. Depending on the severity of the venous block, there may be few scattered hemorrhages or extensive hemorrhages covering a large part of the fundus (‘splashed ketchup’ appearance). NICRVO presents with mild to moderate number of retinal haemorrhages whereas ICRVO which presents with severe and widespread hemorrhages in all quadrants of the retina. The distribution and the type of haemorrhages may help to clinically differentiate between NICRVO and ICRVO with moderate degree of sensitivity and specificity.

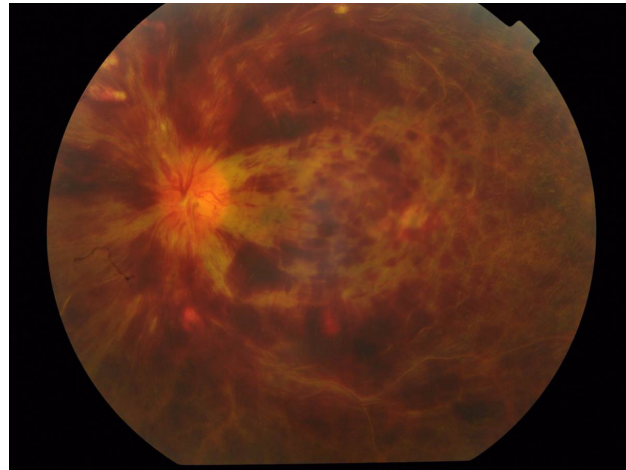Preretinal or sub-internal limiting membrane (ILM) haemorrhages may develop shortly after ICRVO and NICRVO. Hayreh *et al* in his study on fundus changes in CRVO showed higher propensity of sub-ILM and subhyaloid haemorrhages in ICRVO as compared to NICRVO. He also commented on the distribution of the peripheral haemorrhages with haemorrhages in the temporal periphery the first to appear and the last to resolve though no specific reason or explanation for this phenomenon could be elicited in literature<sup>[6]</sup>.

Cotton wool spots, representing microinfarcts of the retinal nerve fiber layer, are more common in ICRVO than in NICRVO. Hayreh *et al* found 40.4 % of ICRVO cases versus 28.8% of NICRVO cases with cotton wool spots within 3 months of onset. They are not pathognomonic of CRVO and are present in a variety of conditions.

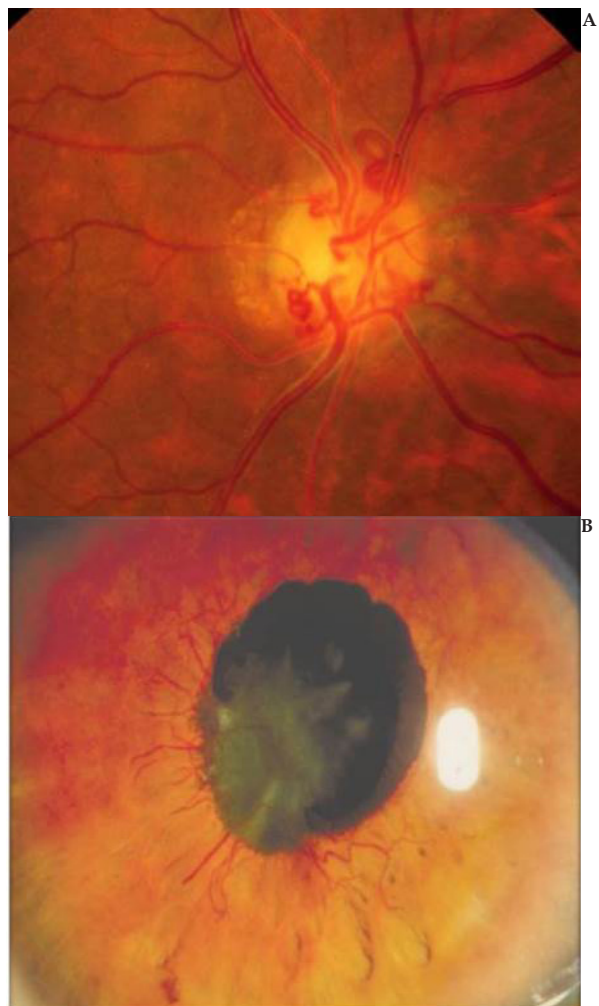Retinal venous engorgement is more marked in ICRVO than in NICRVO. As opposed to irregular dilatation in diabetic retinopathy which causes beading, CRVO presents with uniform dilatation. Retinal perivenous sheathing may be seen in a few cases. Some cases show perivenous sheathing at onset due to retinal phlebitis or

**Table 1** Visual Acuity at presentation is correlated to the final visual acuity in cases with central retinal vein occlusion.

Presenting BCVA	Final BCVA		
	≥ 6/12	6/15-6/60	≤ 6/60
≥ 6/12 (29%)	65 %	25%	10%
6/15-6/60 (43%)	19%	44%	37%
≤ 6/60 (28%)	1%	19%	80%



**Figure 1** Fundus appearance in Ischemic CRVO showing extensive hemorrhages.



**Figure 2** Late complications of CRVO; a. Optociliary shunts, b. Iris Neovascularization.

breakdown of blood retinal barrier due to sudden distention of the lumen on blockage.

Microcystic macular edema is usually more marked in ICRVO than in NICRVO. It may be present at onset or may ensue shortly after the event. There may be subretinal fluid or serous macular retinal detachment (more common in ICRVO), usually obvious on OCT, in the acute stage.

There are several reports of simultaneous development of CRAO with CRVO. Of note is the not infrequent occurrence of cilioretinal artery occlusion along with CRVO. The cilioretinal artery has a luminal pressure much lower than the central retinal artery and is susceptible to compression and closure due to disc edema in CRVO. Optic disc haemorrhages and secondary disc edema are common in either variety of CRVO.

Clinical findings seen in the chronic phase of CRVO include persistent macular edema, epiretinal membranes, sheathed vessels, and optociliary shunts<sup>[11]</sup>. These retinociliary collaterals are more marked in ICRVO and may be present in 34% of eyes with CRVO<sup>[12]</sup>. Optic disc pallor may appear in 38.4% of ICRVO and 2.0% of NICRVO within 1 year of follow up.

The late phase of CRVO may also see the emergence of several complications. Neovascularization is more common in ischemic CRVO<sup>[13-15]</sup>. In the anterior segment, iris neovascularization and angle neovascularization is seen in 20-35% of eyes with CRVO. These may lead to neovascular glaucoma (NVG), which is seen in upto 45% of eyes with ICRVO at the end of three years. NVG is uncommon in eyes with NICRVO, even in the presence of iris neovascularization. The frequent occurrence of NVG in ICRVO eyes has led to the term '100 day glaucoma', due to the time frame of the appearance of this secondary glaucoma after CRVO. The visual acuity of the patient at the time of presentation can indicate a high risk of this complication, with over 30% of patients with vision less than 20/200 developing anterior segment neovascularization.

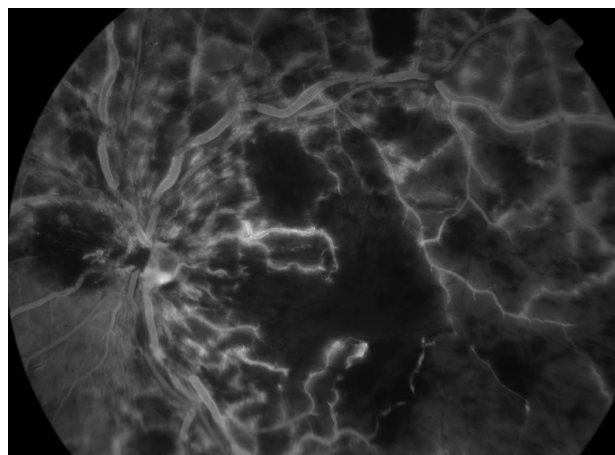
Neovascularization at the disc, and infrequently elsewhere in the fundus, may be seen in CRVO and can cause vitreous hemorrhage and resultant decline in visual acuity. Macular edema is a common complication with upto 80% of these eyes developing some degree of macular edema.

With the above clinical features in mind, the clinical evaluation of a patient with CRVO should always include careful visual acuity examination, pupillary assessment, anterior segment examination with gonioscopy, and biomicroscopic and indirect ophthalmoscopic fundus examination.

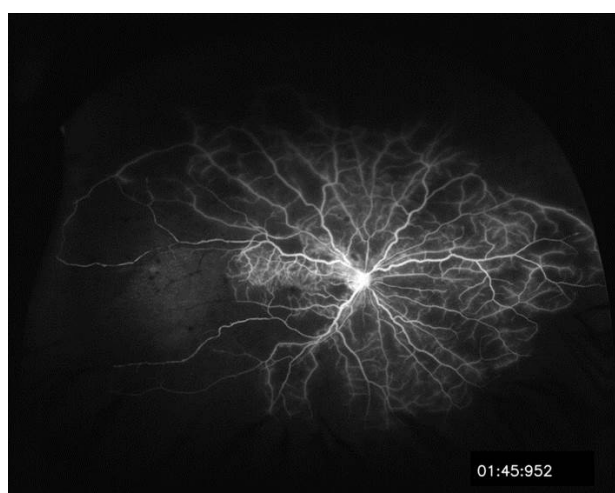
## INVESTIGATIONS

### Fluorescein angiography

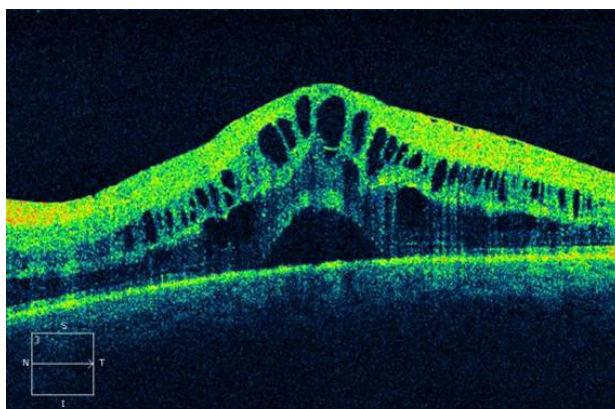
In the acute phase after central retinal vein occlusion, it is difficult to interpret fluorescein angiography due to the presence of superficial retinal hemorrhages that obscure underlying details. At this stage, important information that can be gleaned out of the angiogram includes arteriolar-venous transit time, presence of background diabetic retinopathy, macular leakage or staining and disc staining. Fluorescein angiography helps in the assessment of capillary non-perfusion in later stages. It may be useful in the identification of macular ischemia, conversion of NICRVO to ICRVO and neovascular complications, including iris new vessels. Recent advancements in angiography have enable wide-field imaging almost upto the ora. With this modality, it has been observed that several cases of NICRVO have extensive non-perfusion in the retinal periphery<sup>[16]</sup>. Several cases with non-resolving or recurrent macular edema may have non-perfused areas in the periphery. Whether treatment of these



**Figure 3** Role of Fluorescein Angiography in central retinal vein occlusion- demonstration of capillary non-perfusion and macular ischemia.



**Figure 4** Widefield angiography of CRVO. Although the macular area is perfused large areas of capillary non perfusion are seen especially temporally.



**Figure 5** Optical coherence tomography depicts neurosensory detachment with cystoid macular edema and increased retinal thickness in CRVO.

areas by ablation would have beneficial clinical results remains the subject of current studies.

### Optical coherence tomography

Optical coherence tomography (OCT) has been found to be an extremely useful tool in retinal vascular disorders. In the acute phase, OCT shows inner layer hyper-reflectivity in the areas of retinal hemorrhage. There is expansion or thickening of the retina and

cystoid spaces appear in the inner and outer plexiform layers. There may be subretinal fluid at the fovea in upto 81% of cases<sup>[17]</sup>. In the chronic phase, there may be inner layer loss in eyes with ICRVO. A hyperreflective line located in the outer plexiform layer ('middle limiting membrane') was proposed to be an indicator of ischemia and associated with a poorer visual prognosis<sup>[18]</sup>. OCT is an invaluable tool to quantify macular edema and assess treatment responses.

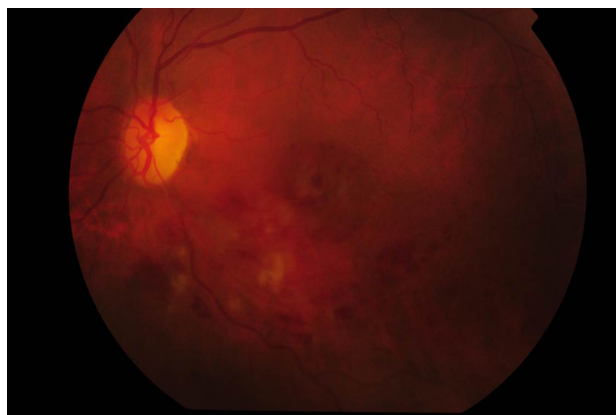**Electroretinography**

The electroretinogram in an eye with CRVO has several notable features. The b-wave amplitude is reduced by 60% or more in most eyes. There is prolongation of the b-wave implicit time. The b/a ratio is reduced and may even be reversed in eyes with ICRVO. The electroretinogram has prognostic significance in CRVO, with grossly reduced b-waves and reversal of b/a ratio portending worse outcomes and neovascular complications.

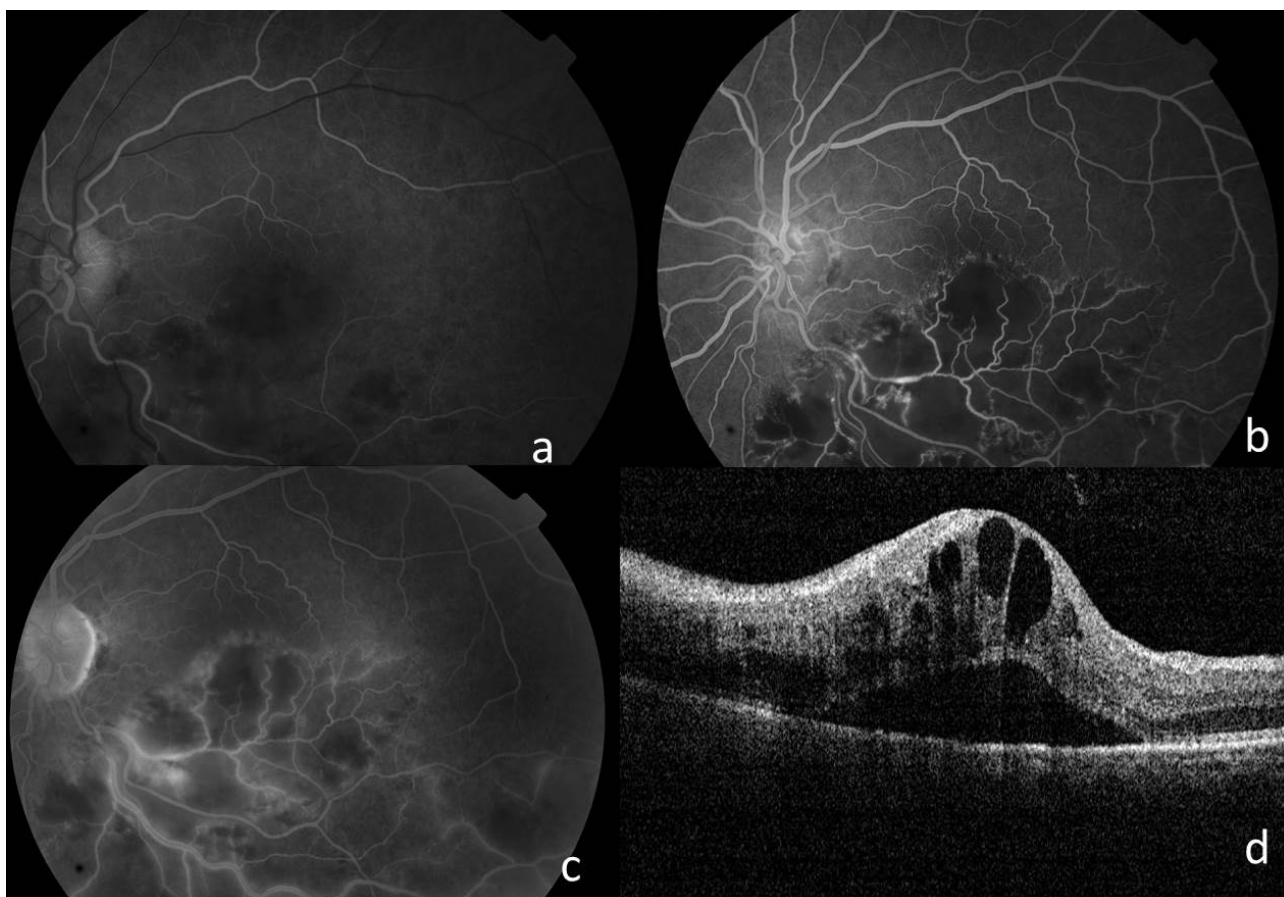
**Branch Retinal Vein Occlusion**

The site of occlusion in branch retinal vein occlusion (BRVO) is invariably at the arteriolo-venous crossing. Arteriosclerosis and arteriolo-venous crossing changes of retinal branch vessels play an important role in the development of BRVO. During recent years a number of studies<sup>[19,20]</sup> have reported that at the site of occlusion in BRVO the retinal arteriole lies anterior to the occluded vein in 93%-100% of cases. The sclerotic retinal arteriole probably compresses the accompanying vein because of a common thickened, adventitial and glial sheath; however, histopathological studies<sup>[20,21]</sup> have so far failed to confirm this view.

Branch retinal vein occlusion may be classified according to the anatomical location of the blockage<sup>[22]</sup>. Major BRVO refers to occlusion of a retinal vein that drains one of the quadrants. BRVO is seen more commonly in the temporal than in the nasal part of the retina, more frequently in the superior than inferior quadrant. The incidence of BRVO is most common in the superotemporal quadrant (58.1-66%), followed by the inferotemporal quadrant (29%), and least common in the nasal quadrants (12.9%). Hemispheric retinal vein occlusion usually involves one of the two trunks of the central retinal vein and results in either superior or inferior half of the retina being affected. Macular BRVO refers to occlusion of a venule within



**Figure 6** Fundus appearance in chronic inferotemporal BRVO shows cotton wool spots, few hemorrhages and formation of collaterals.



**Figure 7** Fluorescein angiography of the inferotemporal BRVO during the early (a) mid (b) and late (c) phases clearly delineated the occlusion along with large areas of capillary non perfusion in the affected sector. Formation of collaterals can also be seen. Optical coherence tomography (d) shows increased retinal thickness due to cystoid macular edema with a neurosensory detachment.

the macula. The superior macular region is involved in 81% of cases and the inferior macular region in 19% of cases. The Branch Vein Occlusion Study (BVOS) divided major BRVO into ischemic or non ischemic depending upon the area of capillary non perfusion on the fluorescein angiogram. Eyes with more than 5 disc areas of non-perfusion were classified as ischemic<sup>[23]</sup>. Unlike in CRVO, this classification has found little relevance in clinical practice.

### Symptoms

Presenting symptoms in BRVO depend on the site and severity of occlusion. Sudden painless loss of vision is the commonest presentation. Decrease in visual acuity (VA) is most commonly due to macular edema which is associated with both major BRVO and macular BRVO. Patients often present with a visual field defect corresponding to the sector of retina involved. Hayreh *et al* found that in both major and macular BRVO, acuity and visual fields improved to a variable degree in the majority of eyes without any treatment<sup>[19]</sup>. Overall, for eyes with initial VA of 20/60 or better, VA improved or remained stable in 75% (95%CI, 63%-86%) for major BRVO and 86% (95%CI, 73%-95%) for macular BRVO. In those with initial VA of 20/70 or worse, VA improved in 69% (95%CI, 56%-80%) for major BRVO and in 53%(95%CI, 27%-79%) for macular BRVO, with median final VA of 20/60 for both BRVO types<sup>[22]</sup>.

Often patients with BRVO are asymptomatic and the occlusion is picked up on a routine retinal examination. Subclinical presentations are usually seen if a tributary vein distal to the macula is blocked or a nasal retinal vein is involved.

Sometimes, patients with BRVO present with floaters from a vitreous hemorrhage if the initial vascular occlusion was asymptomatic and retinal neovascularization has developed.

## SIGNS

### Acute BRVO

Intraretinal haemorrhages corresponding to the sector of retina involved, respecting the horizontal raphe and dilated tortuous veins distal to the occlusion are the pathognomic features of BRVO. These haemorrhages are more extensive and often associated with cotton wool spots in ischemic (non perfused) BRVO and less dense in non ischemic (perfused) BRVO. Marked narrowing of the retinal vein at the arteriovenous crossing just proximal to the haemorrhages, macular edema and hard exudates are some of the other common clinical signs in eyes with BRVO.

### Chronic BRVO

Loss of retinal transparency, collateral formation, microaneurysms, sclerosed veins and telangiectatic vessels in the area of vascular occlusion are characteristic features of a chronic BRVO. Cystoid macular edema with hard exudates and pigmentation at macula may complicate chronic BRVO. Retinal neovascularization, neovascularization of the disc and rarely neovascularization of the angle or iris may also be seen in some patients. Rarely retinal detachment, usually tractional, and neovascular glaucoma maybe the presenting feature in these eyes.

## INVESTIGATIONS

### Fluorescein angiography

Fundus fluorescein angiography (FFA) is a useful investigative modality to diagnose, prognosticate and plan treatment of patients of BRVO. However, in patients with extensive haemorrhages at presentation, FFA is avoided as the blocked fluorescence of the

intraretinal haemorrhages limits the information obtained on FFA and makes interpretation difficult. It is advisable in such cases to obtain FFA only after the intraretinal hemorrhages have cleared significantly from the macula.

In acute BRVO, FFA typically shows delayed filling of the occluded vein with varying degrees of capillary nonperfusion. Blocked fluorescence from intraretinal hemorrhages, dye extravasation in macular edema and later on, microaneurysms, telangiectatic collateral vessels or retinal neovascularization are the other angiographic features. In chronic cases, microvascular changes on FFA may be the only feature<sup>[20]</sup>.

Visualization of peripheral retinal pathology in patients of BRVO by ultra wide-field angiography has recently been applied in the evaluation and management of this condition.

Prasad *et al* evaluated the use of UWFA to study the peripheral angiographic features of branch retinal vein occlusions (BRVO) and hemicentral retinal vein occlusions (HRVO). They suggested that areas of untreated retinal nonperfusion may be the source of production of biochemical mediators that promote neovascularization and macular edema and UWFA may be a powerful tool to identify therapeutic target areas for photocoagulation<sup>[24]</sup>.

Kim *et al* found evidence of retinal vascular pathology on ultra wide-field angiography in a majority of fellow eyes of patients with BRVO<sup>[25]</sup>. They found that visualizing the retinal vasculature in the fellow eye may provide insight into the cause of the vascular occlusion in the affected eye, identify vascular anomalies, and possibly predict future occlusive events in the fellow eye.

### Optical Coherence Tomography

While the clinical picture is diagnostic for vascular occlusions, OCT is useful for non-invasive quantitative monitoring of macular edema and resolution of retinal thickening following treatment. Intraretinal hemorrhages have little effect on the quantitative interpretation of OCT, making this imaging modality useful in acute BRVO when extensive haemorrhages are present.

Some of the morphological findings visible on OCT in acute BRVO include cystoid edema, subretinal fluid accumulation, intraretinal hyperreflectivity from hemorrhages, shadowing from exudates and hemorrhages, and occasionally papilledema. In chronic cases, photoreceptor inner-segment-outer-segment junction abnormalities from long-standing macular ischemia and macular edema or lamellar macular holes may also be seen. Shroff *et al* studied the OCT pattern in recent onset BRVO<sup>[26]</sup>. They noted CME only in 40% of eyes, SRD only in 15% and a combined pattern with both SRD and CME in 45% of eyes. OCT provides an accurate quantification of the amount of macular edema and has been used in place of FA in many treatment trials for BRVO.

## NEW IMAGING MODALITY- OCT ANGIOGRAPHY

Optical Coherence tomography angiography provides a non-invasive way to assess the extent of impaired capillary perfusion in retinal vascular occlusion without injection of contrast dye. Kashani *et al*<sup>[27]</sup> showed 3 novel findings of retinal venous occlusion on OCTA, namely (1) layer specific impairment of blood flow; (2) detection of intraretinal edema associated with hard exudates; (3) impaired blood flow in regions of intraretinal edema. They demonstrated most of the major clinical and fluorescein angiographic features of acute and chronic RVO including impaired capillary perfusion, intraretinal hemorrhage, some forms of macular edema, vascular dilation, and

venous-venous shunting. The most important limitation of OCTA is that it cannot assess “leakage” as in fluorescein angiography. Therefore, it is unlikely that OCTA will completely replace fluorescein angiography.

## COMPARISON OF CLINICAL FEATURES

Long term visual outcome has been shown to be better in patients with BRVO compared to those with CRVO. Visual acuity of more than 20/40 at 3 years was seen in 34% of BRVO versus 12% of CRVO patients<sup>[28,29]</sup>.

Studies by Hayreh<sup>[19]</sup> have shown that neovascularization complication of ischemic CRVO and major BRVO only. Ocular NV is not seen in non-ischemic CRVO or macular BRVO. If an eye with one of the latter diagnoses has ocular NV, the diagnosis is probably incorrect and some other pathology associated carotid artery disease. Macular edema is one of the major complications in all types of RVO. However, it does not involve all eyes with RVO, e.g., mild cases of non-ischemic CRVO, early cases of BRVO or when the BRVO does not involve the macular region.

## COMPETING INTERESTS

The authors declare that there is no conflict of interest regarding the publication of this paper.

## REFERENCES

- 1 Klein R, Klein BE, Moss SE, Meuer SM. The epidemiology of retinal vein occlusion: the Beaver Dam Eye Study. *Trans Am Ophthalmol Soc.* 2000; **98**: 133-141
- 2 Klein R, Moss SE, Meuer SM, Klein BE. The 15-year cumulative incidence of retinal vein occlusion: the Beaver Dam Eye Study. *Arch Ophthalmol.* 2008; **126**: 513-518
- 3 Hayreh SS, Zimmerman B, McCarthy MJ, Podhajsky P. Systemic diseases associated with various types of retinal vein occlusion. *Am J Ophthalmol.* 2001; **131**: 61-77.
- 4 Central Vein Occlusion Study Group. Baseline and early natural history report: the Central Vein Occlusion Study. *Arch Ophthalmol* 1993; **111**: 1087-95
- 5 Hayreh SS. Classification of central retinal vein occlusion. *Ophthalmology.* 1983; **90**: 458-74
- 6 Hayreh SS, Podhajsky PA, Zimmerman MB. Natural history of visual outcome in central retinal vein occlusion. *Ophthalmology.* 2011; **118**: 119-133
- 7 Hayreh SS, Zimmerman MB. Fundus changes in central retinal vein occlusion. *Retina.* 2015; **35(1)**: 29-42
- 8 Foss AJ, Headon MP, Hamilton AM, Lightman S. Transient vessel wall sheathing in acute retinal vein occlusions. *Eye* 1992; **6**: 313-316.
- 9 Paques M, Gaudric A. Perivenular macular whitening during acute central retinal vein occlusion. *Arch Ophthalmol* 2003; **121**: 1488-1491
- 10 Scott IU, Van Veldhuisen PC, Oden NL, *et al.* SCORE Study Investigator Group. SCORE Study report 1: baseline associations between central retinal thickness and visual acuity in patients with retinal vein occlusion. *Ophthalmology* 2009; **116**: 504-512
- 11 McIntosh RL, Rogers SL, Lim L, *et al* Natural history of central retinal vein occlusion: an evidence-based systematic review. *Ophthalmology* 2010; **117**: 1113-1123.
- 12 Giuffrè G, Palumbo C, Randazzo-Papa G. Optociliary veins and central retinal vein occlusion. *Br J Ophthalmol.* 1993; **77**: 774-777
- 13 Chan CK, Ip MS, Vanveldhuisen PC, Oden NL, Scott IU, Tolentino MJ, Blodi BA; SCORE Study Investigator Group. SCORE Study report #11: incidences of neovascular events in eyes with retinal vein occlusion. *Ophthalmology.* 2011; **118**: 1364-1372
- 14 Hayreh SS. Neovascular glaucoma. *Prog Retin Eye Res.* 2007; **26**: 470-485
- 15 McIntosh RL, Rogers SL, Lim L, *et al* Natural history of central retinal vein occlusion: an evidence-based systematic review. *Ophthalmology.* 2010; **117**: 1113-1123
- 16 Spaide RF. Peripheral areas of nonperfusion in treated central retinal vein occlusion as imaged by wide-field fluorescein angiography. *Retina.* 2011; **31**: 829-37.
- 17 Ozdemir H, Karacorlu M, Karacorlu S. Serous macular detachment in central retinal vein occlusion. *Retina.* 2005; **25**: 561-3
- 18 Ko J, Kwon OW, Byeon SH. Optical coherence tomography predicts visual outcome in acute central retinal vein occlusion. *Retina.* 2014; **34**: 1132-41
- 19 Hayreh SS. Retinal Vein Occlusion. *Indian J Ophthalmol* 1994; **42**: 109-132
- 20 Philips S, Fekrat S, Finkelstein D. Retina 4th ed. Elsevier Mosby, 2006: 1349-54
- 21 Parodi MB, Bandello F. Branch retinal vein occlusion: classification and treatment. *Ophthalmologica.* 2009; **223**: 298-305
- 22 Hayreh SS, Zimmerman MB. Branch retinal vein occlusion: natural history of visual outcome. *JAMA Ophthalmol.* 2014; **132**: 13-22.
- 23 Argon laser scatter photocoagulation for prevention of neovascularization and vitreous hemorrhage in branch vein occlusion. A randomized clinical trial. Branch Vein Occlusion Study Group. *Arch Ophthalmol.* 1986; **104**: 34-41
- 24 Prasad PS, Oliver SC, Coffee RE, Hubschman JP, Schwartz SD. Ultra wide-field angiographic characteristics of branch retinal and hemicentral retinal vein occlusion. *Ophthalmology.* 2010; **117**: 780-4
- 25 Kim H, Franco-Cardenas V, Pan C *et al.* Ultra Wide-Field angiographic characteristics of fellow eyes in branch retinal vein occlusion. *Invest Ophthalmol & Vis Sci* 2012; **53**: 2665
- 26 Shroff D, Mehta DK, Arora R, Narula R, Chauhan D. Natural history of macular status in recent-onset branch retinal vein occlusion: an optical coherence tomography study. *Int Ophthalmol.* 2008; **28**: 261-8
- 27 Kashani AH, Lee SY, Moshfeghi A, Durbin MK, Puliafito CA. Optical coherence tomography angiography of retinal venous occlusion. *Retina.* 2015; 2323-31.
- 28 Argon laser photocoagulation for macular edema in branch vein occlusion. The Branch Vein Occlusion Study Group. *Am J Ophthalmol.* 1984; **98**: 271-82
- 29 Evaluation of grid pattern photocoagulation for macular edema in central vein occlusion. The Central Vein Occlusion Study Group M report. *Ophthalmology.* 1995; **102**: 1425-33

**Peer reviewers:** Alparslan SAHIN, Associate Professor, Department of Ophthalmology, Dicle University School of Medicine, 21280, Sur, Diyarbakir, Turkey; Do-Gyun Kim, MD, PhD, Associate Professor, Department of Ophthalmology, Myong-Ji Hospital, 697-24, Hwajung-dong, Deokyang-gu, Goyang-si, Gyeonggi-do, Korea.