

## CASE REPORT

# Cystoid Retinal Degeneration in Chronic Central Serous Chorioretinopathy: A Rare Optical Coherence Tomography Finding

Kemal Tekin, Yasemin Ozdamar Erol, Mehmet Yasin Teke, Merve Inanc, Sadi Onal, Hakan Ozdemir

Kemal Tekin, Merve Inanc, M.D. Ankara Ulucanlar Eye Research Hospital, Ankara, Turkey

Yasemin Ozdamar Erol, Mehmet Yasin Teke, M.D. Assoc Prof., Department of Retinal Diseases, Ankara Ulucanlar Eye Research Hospital, Ankara, Turkey

Sadi Onal, M.D. Bilgi Hospital, Ankara, Turkey

Hakan Ozdemir, Prof., Department of Ophthalmology, Bezmialem University, Istanbul, Turkey

Correspondence to: Kemal Tekin, MD, Ulucanlar Eye Research and Education Hospital, Ankara, 06240, Turkey.

Email: kemal\_htepe@hotmail.com

Telephone: +90 312 312 62 61 Fax: +90 312 312 48 27

Received: September 15, 2015 Revised: October 9, 2015

Accepted: October 12, 2015

Published online: March 28, 2016

**Key words:** Central Serous Chorioretinopathy; Cystoid Retinal Degeneration; Optical Coherence Tomography

Tekin K, Erol YO, Teke MY, Inanc M, Onal S, Ozdemir H. Cystoid Retinal Degeneration in Chronic Central Serous Chorioretinopathy: A Rare Optical Coherence Tomography Finding. *International Journal of Ophthalmic Research* 2016; 2(1): 117-123 Available from: URL: <http://www.ghrnet.org/index.php/ijor/article/view/1578>

## INTRODUCTION

Central serous chorioretinopathy (CSCR) is characterized by serous retinal detachment due to disruption of the pump and barrier function of retinal pigment epithelium (RPE) in addition to choriocapillaries pathology<sup>[1]</sup>. It typically occurs unilaterally in younger men and patients are presented with decreased and distorted vision, metamorphopsia, loss of contrast sensitivity and hypermetropic refractive errors<sup>[2]</sup>. One or more focal leakage has been shown at the level of RPE on the fundus fluorescein angiography (FFA). Most of the cases have a good visual prognosis and disease resolves within 6 months. Chronic CSCR is also known as diffuse retinal pigment epitheliopathy, is commonly seen bilaterally in elderly patients and signs and symptoms are present for more than 6 months<sup>[3]</sup>.

Optical coherence tomography (OCT) is a gold standard technique in the diagnosis and monitoring of CSCR<sup>[4]</sup>. OCT reveals various pathological changes such as serous retinal detachment, pigment epithelial detachment, subretinal deposits, RPE atrophy and brush-border pattern in patients with CSCR. Additionally, cystoid macular edema (CME) and cystoid retinal degeneration (CRD) are very rare OCT findings in eyes with chronic CSCR.

We report posterior cystoid retinal degeneration in two cases of chronic CSCR diagnosed on OCT and its course outcomes.

## CASE PRESENTATION

### Case 1

A 42 year-old man was presented with vision loss and

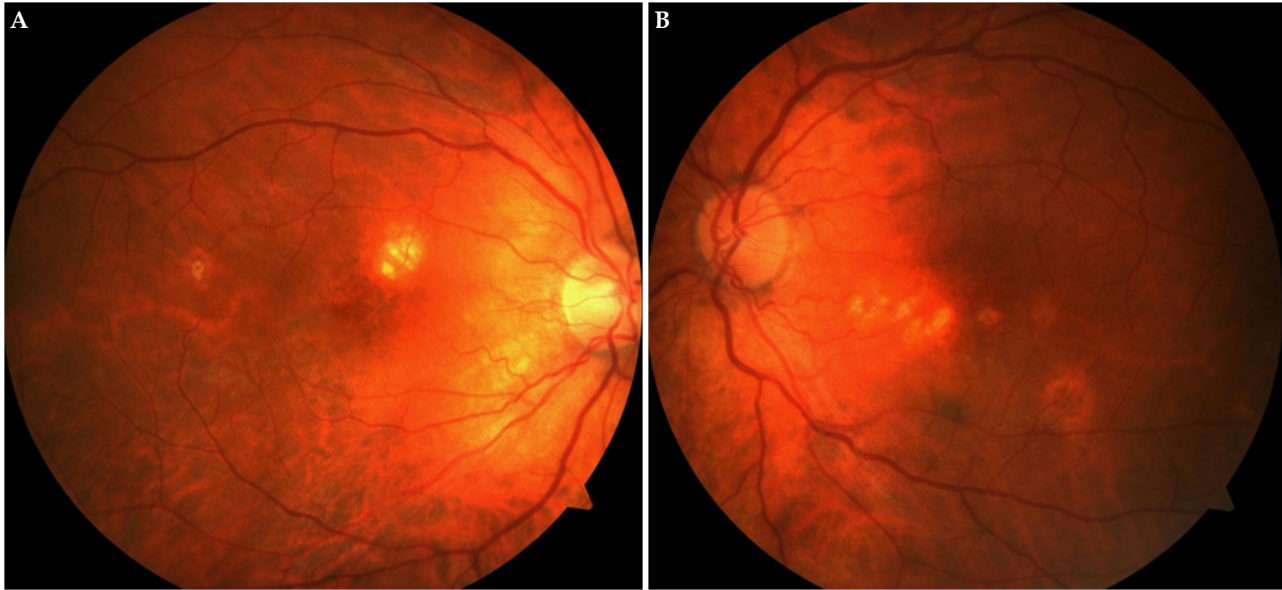
## ABSTRACT

**AIM:** To report cystoid retinal degeneration (CRD) in two cases of chronic central serous chorioretinopathy (CSCR) using optical coherence tomography (OCT).

**METHODS:** Case report. Two patients with chronic CSCR having metamorphopsia and blurred vision for longer than 6 months were evaluated.

**RESULTS:** OCT showed multiple intraretinal cysts in the outer plexiform and the outer nuclear layers of retina, concomitant subretinal fluid with brush-border pattern in 3 eyes of 2 patients. Retinal cystoid changes were located in the fovea in 1 eye and in the extrafoveal area in 2 eyes. Visual acuity was higher than 20/200 in all eyes. At the last examination, visual acuity and cystoid space on OCT images did not change.

**CONCLUSION:** Cystoid retinal degeneration is a rare complication of chronic CSCR and characteristically located in the outer layers of the retina on OCT. Visual prognosis depends on localization of CRD and duration of the disease.



**Figures 1A-1B:** Color fundus photographs of the right and left eye demonstrate pigmentary changes and some atrophic areas throughout the maculas.

metamorphopsia lasting for 7 months in the left eye. The best corrected visual acuity (BCVA) according to Snellen chart was 20/20 in the right eye and 20/50 in the left eye. Intraocular pressures were within the normal limits in both eyes. Anterior segment examinations of both eyes were normal. Dilated fundus examination revealed changes in the pigment epithelium, atrophic regions in the macula of the right eye (Figure 1A) and an atrophic and pigmented area in the neighborhood of the fovea in the left eye (Figure 1B). He had a history of renal transplantation 9 months ago and has been receiving systemic immunosuppressive and corticosteroid therapy since then. Spectral domain OCT of the right eye showed irregularity of the retinal pigment epithelium on the fovea that may be the evidence of previous CSCR episode, while the foveal contour was normal. Additionally, OCT of the right eye demonstrated multiple intraretinal cysts in the area neighboring the fovea and marked RPE atrophy (Figure 2A). On OCT of the left eye, foveal contour was completely disrupted and there were multiple intraretinal cysts in the outer plexiform and the outer nuclear layers, the largest cystoid space located in the fovea. Moreover, concomitant subretinal fluid with brush-border pattern which was compatible with chronic CSCR and CRD was observed on the left eye (Figure 2B). Fundus fluorescein angiography (FFA) could not be performed because of renal transplantation and the patient also refused indocyanine green angiography (ICG) procedure. The findings obtained through history suggested effects of a long term systemic corticosteroid usage and nephrology consultation was performed to find out whether corticosteroid treatment could be discontinued. Since the patient had renal transplantation, he had to continue to take the lowest possible dose without interruption. After 6 months' follow-up, the visual acuity and OCT findings of both eyes did not change. (Figures 2C and D).

#### Case 2:

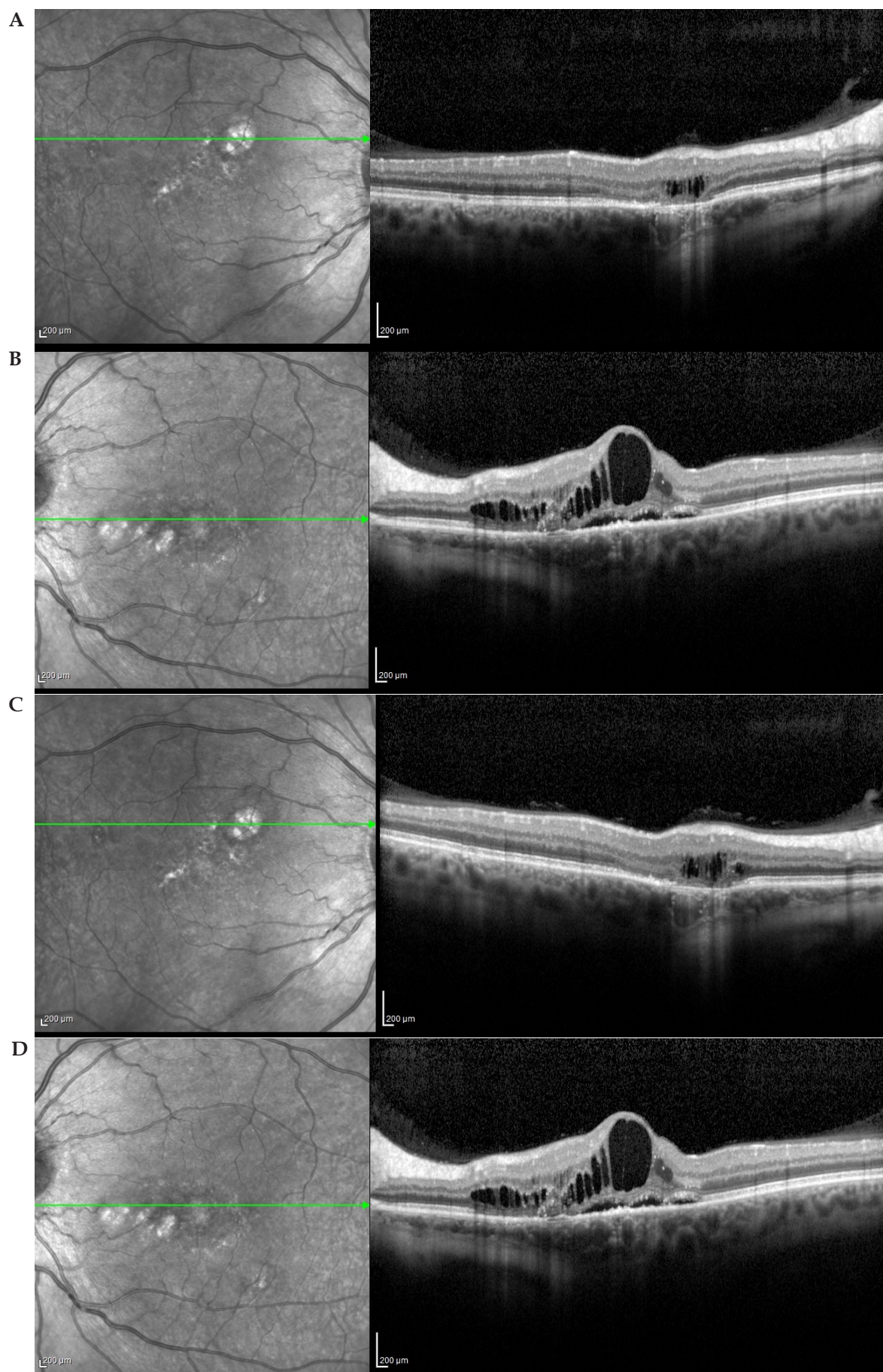
A 61 year-old man who was diagnosed as bilateral CSCR and followed at another clinic for one year was admitted to our clinic with complaints of blurred vision and metamorphopsia. The best corrected visual acuity according to Snellen chart was 20/25 in both eyes. Intraocular pressures and anterior segment examination of both

eyes were normal. Dilated fundus examination revealed changes in the pigment epithelium and atrophic areas in the macula of both eyes (Figures 3A and 3B). The patient did not have history of any systemic disorders and drug administration. Spectral domain OCT showed irregularities of the retinal pigment epithelium, subretinal fluid and brush-border pattern in both eyes, which were compatible with chronic CSCR, and also multiple intraretinal cystoid changes at the outer plexiform and the outer nuclear layers in the papillomacular region of the right eye (Figures 4A and B). On fundus fluorescein angiography, there were numerous leak points without certain sources in the early phase and increased fluorescein leakage of from these points in the late phase in both eyes. Also, no fluorescein leakage was observed in the area of cystoid changes in the right eye (Figures 5A, B, C and D). These findings were compatible with chronic CSCR in both eyes and CRD in the right eye. ICG could not be performed because the patient refused it. Half-dose photodynamic therapy was offered, but he also refused it. After 9 months' follow-up, while the visual acuity and CRD image on OCT did not change, there was a slight decrease in subretinal fluid on OCT of both eyes (Figures 4C and D).

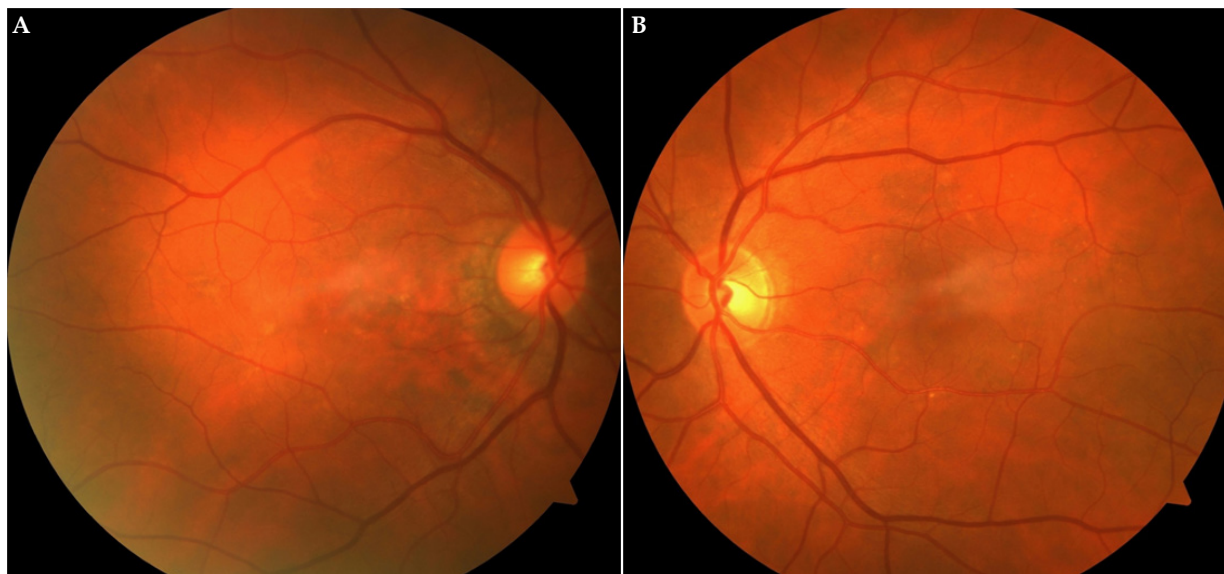
## DISCUSSION

Although the aetiology of CSCR are not clearly understood, the condition has been associated with the use of steroids through virtually any route of administration. Furthermore, type A personality, emotional stress, endogenous hypercortisolism as well as an imbalance between sympathetic and parasympathetic activity have also been suggested as risk factors for CSCR<sup>[4]</sup>. Most cases of acute CSCR resolve spontaneously, but degenerative changes can remain in RPE and the neurosensory retina of the cases with chronic and recurrent macular detachment, resulting in a poor visual outcome in chronic CSCR cases<sup>[3]</sup>. Chronic CSCR is often bilateral and occurs more frequently in elderly patients (>50 years)<sup>[3,4]</sup>. In the first case steroid usage may be associated with CSCR. Although the first patient was younger 50 years old, the age was greater than 50 years old in the second case which was compatible with the literature for chronic CSCR.





**Figures 2A-B-C and D-E:** Optical coherence tomography showing multiple intraretinal cysts in the outer plexiform and the outer nuclear layers in the right eye (A) and left eye (B) on initial visit. Additionally, subretinal fluid with brush-border pattern appearance is seen in the left eye on initial visit (B). Persistent intraretinal cysts is present in the right (C) and left (D) eye after 6 months' follow-up visit.



Figures 3A-3B: Color photographs of the right and left eye demonstrate pigmentary changes and some atrophic areas throughout the maculas.

OCT is considered as a gold standard technique in diagnosing and monitoring of CSCR and it is the most reliable method to demonstrate intraretinal changes<sup>[5-7]</sup>. Serous retinal detachment, pigment epithelial detachment, pigment epithelial tear and subretinal deposits have mostly been shown on OCT of acute CSCR<sup>[8]</sup>. Serous retinal detachment, atrophy and irregularity of RPE, atrophy and irregularities in the IS/OS band formed by outer and inner segments of photoreceptors and brush-border pattern have often been detected in chronic CSCR<sup>[9]</sup>.

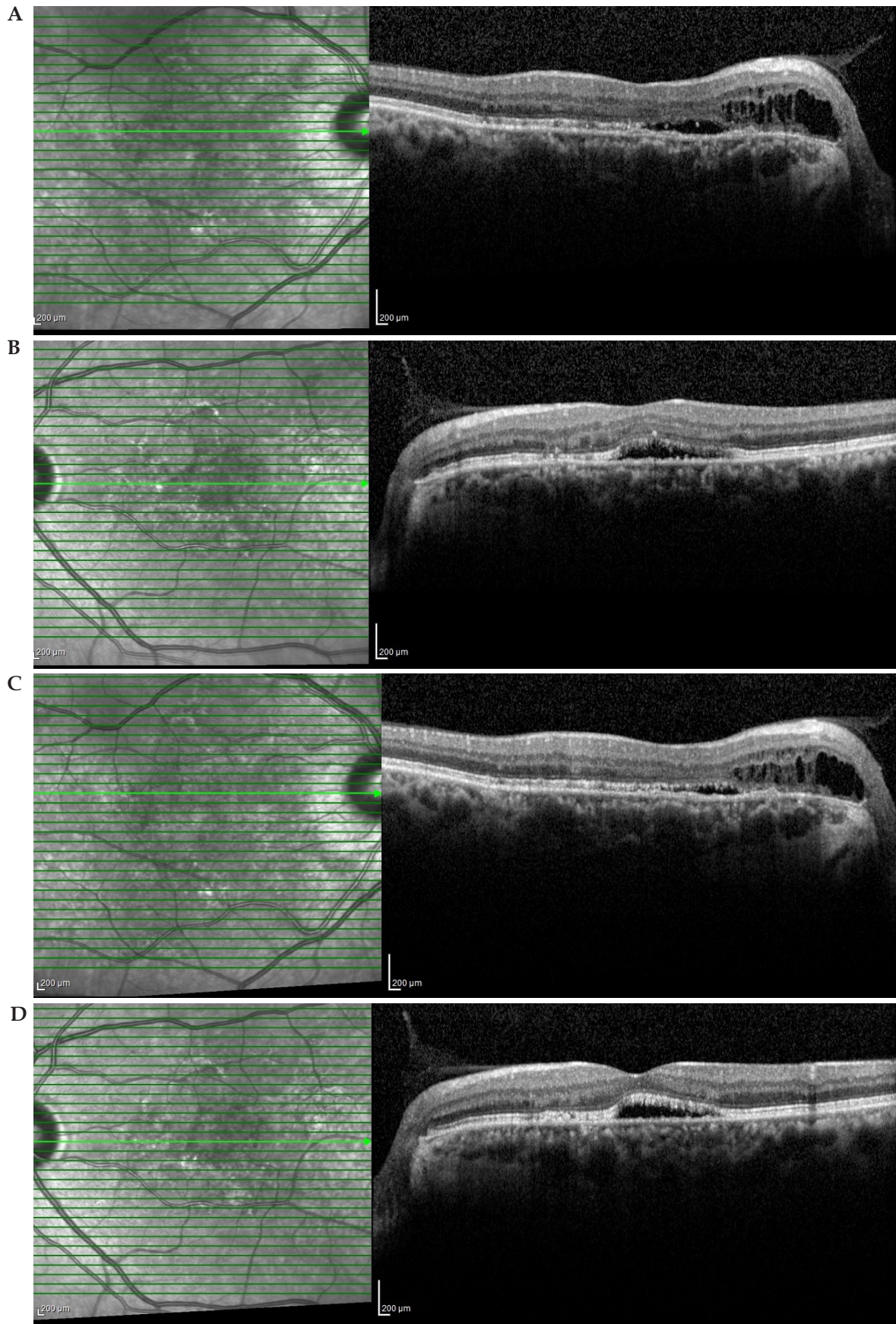
Cystoid retinal degeneration (CRD) is a rare OCT finding having been detected in eyes with chronic CSCR. CRD is a nonspecific term used to describe retinal degeneration with cystic spaces within the retina and may occur in retinal vascular diseases, ocular inflammatory diseases, retinitis pigmentosa, and after anterior segment surgery<sup>[10]</sup>. After resolution of CME, intraretinal cysts may not respond to treatment and may result in different levels of visual impairment<sup>[11]</sup>. There have been several reports regarding CRD and/or cystoid macular degeneration (CMD) in chronic CSCR. The term CMD with chronic CSCR was first mentioned in 2003 by Iida *et al*<sup>[12]</sup>, who described cystoid spaces within the macula on OCT and absence of intraretinal leakage in these areas on FFA in 8 eyes with chronic CSCR. In 2008, Piccolino *et al*<sup>[13]</sup>, found that retinal cysts were mostly located in the papillomacular region in 61.7 % of 34 eyes; therefore, they indicated that the term posterior CRD was more suitable. Also, they showed that cystoid spaces were located primarily in the outer retinal layers on OCT images in their study. In our first case reported here, intraretinal cysts were clearly seen on OCT although FFA could not be performed because of renal transplantation. In case 2, OCT revealed cystic changes in the nasal retina and more RPE leaks areas were seen due to CSCR, no fluorescein leakage was also observed in the area of cystic degeneration on FFA. In both cases, cystoid changes were not evident on clinical examination. OCT revealed that intraretinal cysts were located in the outer nuclear and outer plexiform layers of the retina.

The presence of RPE atrophy and CRD has been associated with a poor visual prognosis in chronic CSCR. In the study by Iida *et al*<sup>[12]</sup>, all patients with central vision of 20/200 or worse had cystoid

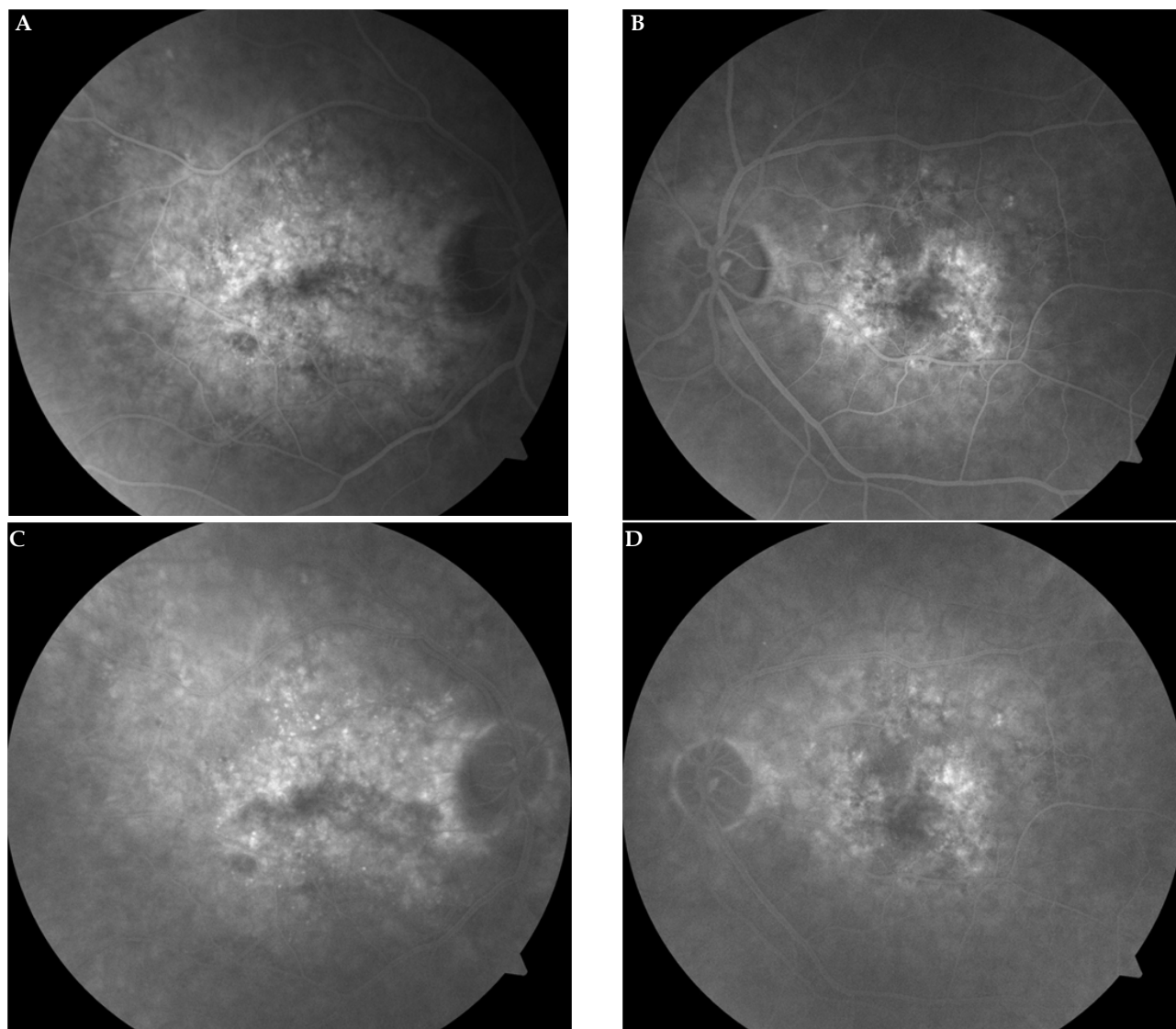
changes within the macula with foveal involvement. Piccolini *et al*<sup>[13]</sup>, showed that visual acuity ranged from 20/20 to 20/400. In 26.4% of the eyes in cases where the cystoid changes spared the foveal center and the visual acuity was 20/40 or better in their study. They found that retinal cysts were largely located in the papillomacular area and involved the fovea in 58.8% of the cases. They pointed out that preserved visual acuity was associated with absence of foveal involvement regarding the retinal cysts. In our cases presented here, visual acuity was higher than 20/200. In the first case, although cystoid degeneration was located on the fovea of the left eye, visual acuity was 20/50 and this preserved vision could be explained by the fact that chronic CSCR in the left eye has not been present for a long time. In the second case, because cystoid degeneration was not located in the foveal area, visual acuity was 20/25 in the right eye, as in the study by Piccolini *et al*<sup>[13]</sup>. In addition, there were no differences in OCT findings of CRD during the follow-up. In fact, posterior cystoid retinal changes did not extend to large cystoid space and/or there was no resolution of the cystoid lesion. Iida *et al*<sup>[12]</sup>, showed that duration of the disease ranged from 3.5 years to 34 years, it can be concluded that cystoid changes do not show progress, not even slowly. To the best of our knowledge, there have been no reports about the course of CRD in chronic CSCR. Piccolini *et al*<sup>[13]</sup>, reported that there was not an association between cystoid retinal changes and RPE atrophy. In the cases presented here, CRD was not detected in each area of RPE atrophy. In other words, CRD was present in some areas of RPE atrophy. Therefore, it can be speculated that there was not a relation between the extent of cystoid retinal changes and the presence of RPE atrophy.

The pathogenesis of intraretinal cysts has not been clearly elucidated. The damage and decompensation of RPE cause diffuse subretinal fluid leakage and this can cause CRD in chronic CSCR cases. Iida *et al*<sup>[12]</sup>, suggested that outer retinal ischemia as a result of chronic retinal detachment in the context of a breakdown of the outer blood-retina barrier appeared to be a contributing factor for the development of CRD in chronic CSCR. However, there have been cases of chronic CSCR with atrophy of the outer retinal layers diagnosed on OCT and having no evidence of intraretinal cystoid





**Figures 4A-B-C-D:** Optical coherence tomography showing irregularities of the retinal pigment epithelium, subretinal fluid and brush-border pattern with multiple intraretinal cystoid changes at the outer plexiform and the outer nuclear layers in the papillomacular region of the right eye (A) and only subretinal fluid with brush-border pattern on the left eye (B) on initial visit. Persistent intraretinal cysts is present and minimally decreased subretinal fluid on the right eye (C) and similarly, decreased minimally subretinal fluid on the left eye (D) after 9 months' follow-up visit.



**Figures 5 A-B-C-D:** Fundus fluorescein angiography reveals numerous leak points without certain sources in early phase and increased fluorescein leakage of from these points in late phase in both eyes. Also, no fluorescein leakage was observed in the area of cystoid changes in the right eye.

changes. This supports the notion that other possible factors are likely to be involved in the development of CMD. Piccolini *et al*<sup>[13]</sup>, reported that the most marked retinal swelling with the largest cystoid cavities tended to occur in areas where the retina adhered to atrophic lesions of the RPE and the choroid, in areas of subretinal fibrosis, or in large laser scars. They added that those same areas were sites of focal leakage from the RPE on fluorescein angiograms taken in the early stages of the disease. They emphasized that these focal chorioretinal adherence areas where fluid from the choroid found a barrier-free path for diffusion into the retina predisposed to cystoid degeneration.

As a conclusion, posterior cystoid retinal degeneration is characterized by cystoid changes in the outer layers of the retina on OCT and it is a rare complication of chronic CSCR. Visual prognosis can be variable in terms of the location of cysts, involvement of the center of the fovea and duration of CSCR. The cystoids spaces may not alter in time; however, a longer follow-up will give more useful information about the course of these cysts.

## COMPETING INTERESTS

The authors declare that there is no conflict of interest regarding the publication of this paper.

## REFERENCES

1. Daruich A, Matet A, Dirani A, Bousquet E, Zhao M, Farman N, Jaissier F, Behar-Cohen F. Central serous chorioretinopathy: Recent findings and new physiopathology hypothesis. *Prog Retin Eye Res* 2015; 15: 33-36.
2. Liew G, Quin G, Gillies M, Fraser-Bell S. Central serous chorioretinopathy: a review of epidemiology and pathophysiology. *Clin Experiment Ophthalmol* 2013; 41: 201-214.
3. Taban M, Boyer DS, Thomas EL, Taban M. Chronic central serous chorioretinopathy: photodynamic therapy. *Am J Ophthalmol* 2004; 137: 1073-1080.
4. Stefaniotou M, Vourda E, Katsanos A, Aspiotis M. Multifocal Central Serous Chorioretinopathy Associated with Steroids in a Patient with Myasthenia Gravis. *Case Rep Ophthalmol* 2013; 4: 1-6.

5. Teke MY, Elgin U, Nalcacioglu-Yuksekkaya P, Sen E, Ozdal P, Ozturk F. Comparison of autofluorescence and optical coherence tomography findings in acute and chronic central serouschorioretinopathy. *Int J Ophthalmol* 2014; 7; 350-354.
6. Talu SD, Talu S. Use of OCT Imaging in the diagnosis and monitoring of Age Related Macular Degeneration - The Recent Advances in Basic Research and Clinical Care. *Published by InTech* 2012: 253-272.
7. Talu S, Balta F, Talu SD, Merticaru A, Talu M. Fourier Domain - Optical Coherence Tomography in diagnosing and monitoring of retinal diseases. *Published by Springer-Verlag GmbH* 2009: 261-266.
8. Yu J, Jiang C, Xu G. Study of subretinal exudation and consequent changes in acute central serous chorioretinopathy by optical coherence tomography. *Am J Ophthalmol* 2014; 158; 752-756.
9. Ferrara D, Mohler KJ, Waheed N, Adhi M, Liu JJ, Grulkowski I, Kraus MF, Bauman C, Hornegger J, Fujimoto JG, Duker JS. En face enhanced-depth swept source optical coherence tomography features of chronic central serous chorioretinopathy. *Ophthalmology* 2014; 121; 719-726.
10. Wallow IHL, Danis RP, Bindley C, Neider M. Cystoid macular degeneration in experimental branch retinal vein occlusion. *Ophthalmology* 1988; 95; 1371-1379.
11. Horii T, Murakami T, Akagi T, Uji A, Ueda-Arakawa N, Nishijima K, Yoshimura N. Optical coherence tomographic reflectivity of cystoid spaces is related to recurrent diabetic macular edema after triamcinolone. *Retina* 2015; 35; 264-271.
12. Iida T, Yannuzzi LA, Spaide RF, Borodoker N, Carvalho CA, Negrao S. Cystoid macular degeneration in chronic central serous chorioretinopathy. *Retina* 2003; 23; 137-138.
13. Piccolino FC, De La Longrais RR, Manea M, Cicinelli S. Posterior cystoid retinal degeneration in central serous chorioretinopathy. *Retina* 2008 ; 28; 1008-1012.

**Peer reviewer:** Ștefan Țălu, The Technical University of Cluj-Napoca, Faculty of Mechanical Engineering, Department of AET, Discipline of Descriptive Geometry and Engineering Graphics, B-dul Muncii Street, no. 103-105, Cluj-Napoca, 400641, Romania; Alparslan SAHIN, Associate Professor, Department of Ophthalmology, Dicle University School of Medicine, 21280, Sur, Diyarbakir, Turkey.