

Laser Photocoagulation in Retinal Vein Occlusion

Ayşe Gul Kocak Altıntaş

Ayşe Gul Kocak Altıntaş, SB Ankara Ulucanlar Eye Education and Research Hospital Ulucanlar Cad. No: 59 06230 Altındag, Ankara, Turkey

Correspondence to: Ayşe Gul Kocak Altıntaş, MD, SB Ankara Ulucanlar Eye Education and Research Hospital Ulucanlar Cad. No: 59 06230 Altındag, Ankara, Turkey.

Email: aysegulkaltintas@hotmail.com

Telephone: +90-312-3126261

Fax: +90-312-3124827

Received: January 23, 2016

Revised: May 5, 2016

Accepted: May 6, 2016

Published online: June 28, 2016

ABSTRACT

Visual acuity is primarily decreased secondary to macular edema, retinal ischemia and complications of neovascularisation in both BRVO and CRVO. Panretinal Laser photocoagulation or Focal photocoagulation is an effecting treatment for neovascularisation and prevention of complications of neovascularisation by ablating ischemic retina in either BRVO or CRVO. But Macular Laser photocoagulation can be use for treatment of non ischaemic macular oedema in only BRVO either alone or combination with other Anti-VEGF or Anti-inflammatory medication.

Key words: Laser; Panretinal photocoagulation; Grid photocoagulation; Neovascularization; Laser-induced chorioretinal venous anastomosis

© 2016 The Author. Published by ACT Publishing Group Ltd.

Altıntaş AGK. Laser Photocoagulation in Retinal Vein Occlusion. *International Journal of Ophthalmic Research* 2016; 2(2): 143-147
Available from: URL: <http://www.ghrnet.org/index.php/ijor/article/view/1623>

IMPORTANCE OF SUB-CLASSIFICATION OF RVO AND COEXISTING FACTORS FOR LASER PHOTOCOAGULATION

Retinal vein occlusion (RVO) is the second most common retinal vascular disease after diabetic retinopathy which is a frequently devastating cause of blindness in mainly in older patients over 60 years of age. Its prevalence changes according to studies in overall populations are from 5.2 to 16 per 1,000^[1-4]. People with end-organ damage caused by diabetes mellitus and hypertension have strongly increased risk for RVO. The majority of individual diagnosed with RVO defined more than one component of the systemic vascular and metabolic disease, such as the presence of Diabetes Mellitus, hyper tension and high serum lipids. Coexisting metabolic diseases are important factors for prognosis and laser treatment response^[1-5].

There are mainly two types of RVO according to occlusion side branch retinal vein occlusion (BRVO) and central retinal vein occlusion (CRVO). In BRVO occlusion is located in the any branch of the retinal vein system, while occlusion located exactly in the central retinal vein in CRVO. Different researches shows that BRVO is 4-6 times more common than CRVO and it has been estimated that there are around 80 new cases of CRVO/million population/year. Although CRVO most commonly affects one eye, in around 10% of patients the disease affects both eyes^[2-7]. Even RVO was first recognized over a century ago, the exact pathogenesis is not completely understood and therefore exact treatment methods not found yet. The condition may be due to a combination of three systemic changes known as Virchow's triad: (1) hemodynamic changes such as venous stasis; (2) degenerative changes of the vessel wall; and (3) blood hypercoagulability^[6,8,9]. According to clinical findings, fundus appearance, Fluorescein angiography and electrophysiological results Hayreh further divided RVO into three types: (1) BRVO is divided further into major BRVO (a) and macular BRVO (b) according to localization; (2) CRVO is divided into ischemic and non-ischemic types due to presence or absence of

perfusion; and (3) hemi-CRVO with involvement of only one half of the retina surface and this type is also divided into ischemic and non-ischemic types like CRVO. The both CRVO and hemi-CRVOs have thrombosis at the level of the lamina cribrosa. The main pathogenic mechanism for development of BRVO is arterial stiffness which causes venous compression in the common arterio-venous adventitial sheath in any part of arterio venous crossing^[8-11]. Type of RVO either CRVO or BRVO, localization of obstruction and macular of peripheral, and ischemic and non-ischemic types are essential factors to perform laser coagulation either for treatments or to prevent complication.

Ischemic and non-ischemic types of CRVO have very different clinical findings, complications, course, prognoses and managements. At the first diagnosed approximately 20% of patients with CRVO have ischaemic type with large areas of retinal non-perfusion and round 8-10% of patients with non-ischaemic CRVO may convert into the ischaemic type during short follow-up, but up to 34% of eyes with nonischemic CRVO converted to ischemic CRVO over a 3-year period if untreated. Visual acuity is primarily decreased due to macular edema and macular or retinal ischemia in both CRVO and also BRVO^[10-14]. Retinal ischaemia may lead to the development of neovascularisation in the retina, iris or anterior chamber angle. Complications of neovascularisation include vitreous haemorrhage and neovascular glaucoma. In at least 23% of eyes developed neovascular glaucoma within 15 months in Ischemic CRVO patients^[4,6,9,10].

Both type of RVO's etiology multifactorial and they have progressive nature, therefore RVO treatment is still a challenge. Currently, no effective treatment has been accepted according to results of large randomized studies. A number of therapies have been assessed in the treatment of RVO for preserving or improvement of Visual Acuity (VA) and ameliorating the severity of complication by either laser photocoagulation, laser-induced chorioretinal venous anastomosis intravitreal steroids and anti-VEGF agents or surgical procedures such as pars plana vitrectomy, arteriovenous sheathotomy, radial optic neurotomy and surgical chorioretinal venous anastomosis. Even with the use of current therapies, some eyes with ischaemic CRVO end up blind and painful and, ultimately, enucleation is necessary^[15-19].

LASER PHOTOCOAGULATION FOR CRVO

Macular (Grid) photocoagulation

Not all people with CRVO will require treatment and macular oedema will resolve in approximately 30% of those cases with non-ischaemic CRVO. In addition, Grid macular laser photocoagulation did not improve VA and was not found to be beneficial to those with macular edema secondary to CRVO. In McIntosh *et al*^[2] review about, 53 studies which providing 3,271 eyes with CRVO for analysis of its natural history and they observed that VA was generally poor at baseline (< 20/40) and decreased further over time. They published that although 6 studies reported an improvement in VA, none of these improvements resulted in VA better than 20/40 in untreated patient. Data from the Standard Care vs Corticosteroid for Retinal Vein Occlusion (SCORE) study also demonstrate limited benefit with median gain of six letters or laser therapy at 12 months^[18-20]. For these patients, antivascular endothelial growth factor (VEGF) therapies and steroids for the management of macular edema could be used.

Panretinal or scatter laser photocoagulation

Due to sufficient perfusion eyes with nonischemic CRVO, do

not develop retinal neovascularisation or neovascular glaucoma unless it combines with DM or ocular ischemic syndrome. These two associated conditions being the sole cause of ocular neovascularisation in eyes with CRVO, therefore it may wrongly be attributed to nonischemic CRVO. So, the main important step in the management of CRVO is to determine whether the CRVO is ischemic or non-ischemic. In non-ischemic types of CRVO subsequent neovascular glaucoma is rare. Therefore panretinal or scatter laser photocoagulation (PRPC) in non-ischemic CRVO is not necessary^[2,3,18,20].

Alterations in arterial and/or venous flow during the course of ischaemic CRVO are shown with colour Doppler imaging. In eyes with ischaemic CRVO reduced blood flow velocity decreased even further after PRPC comparing to the contralateral eyes. Fuijo *et al*^[21] reported that a significant decrease in blood flow velocity in the upper half of the retina after argon laser photocoagulation compared to the other half without treatment. On the other hand, Bertram and coworkers^[22] observed that circulation velocity increases in the areas with laser burns 3-9 months after laser photocoagulation (PC). Similarly Vilser *et al*^[23] showed an increase in retinal blood flow (RBF) after PC but RBF did not reach normal values. According to Arvas *et al*^[24] study by Heidelberg retinal flowmetry (HRF) if the laser burns were not extensive; grade 2 and 3a burns do not damage the internal capillary plexus and this has even further positive effect on blood flow values. They also found that blood flow values were lower in eyes with CRVO than in the eyes of the healthy control group. In addition the blood flow values of retina were found to be significantly lower in the fellow eyes of the CRVO group than in the normal control group. They suggested that their result may be due to bilateral vascular bed insufficiency, which also accounts for the presence of CRVO. In both CRVO and BRVO with vascular bed insufficiency, can lead to fluid leakage from capillaries draining into the obstructed vein which caused in secretion of vascular endothelial growth factor (VEGF) mainly VEGF A and interleukin-6 (IL-6), that leads to neovascularization and oedema. Laser photocoagulation may prevent excessive secretion of these chemical mediators originating from disturb retinal capillary, haemodynamics and tissue damage after vascular occlusion^[6,10,18-20].

In ischemic types of CRVO PRPC decreases the risk of neovascularization of the iris and anterior chamber angle end up with neovascular glaucoma, neovascularization of optic nerve vitreous and haemorrhage below 5%. Wald^[25] suggested that prophylactic scatter photocoagulation in ischaemic CRVO might prevent the risk of anterior segment neovascularization when 75 disc diameters or more of ischaemia are documented. On the other hand according to Mohamed *et al*^[8] review of 17 Randomised clinical Trial results prophylactic PRPC does not prevent angle and iris neovascularization so does not totally eliminate risk of neovascular glaucoma for patient ischemic CRVO, but PRPC resulted in regression of angle and iris neovascularization and reduced progression to neovascular glaucoma (Figure 1: CRVO; Figure 2: non ischaemic CRVO in FFA).

Mitsch *et al*^[26] demonstrated that PRPC leads to a slowly developing but reversible morphometric changes which are detected by spectral domain optical coherence tomography. They reported that this biological change indicates pan-retinal laser therapy cause diffuse, intense but reversible retinal inflammation. According to Ito *et al*^[27] study after both Pattern scan laser (PASCAL) and conventional laser treatments, some inflammatur mediators level such as RANTES (regulated upon activation in normal T cells, expressed secreted) IL-6 (interleukin-6) and MCP-1 (monocyte chemoattractant protein-1), were significantly elevated compared with

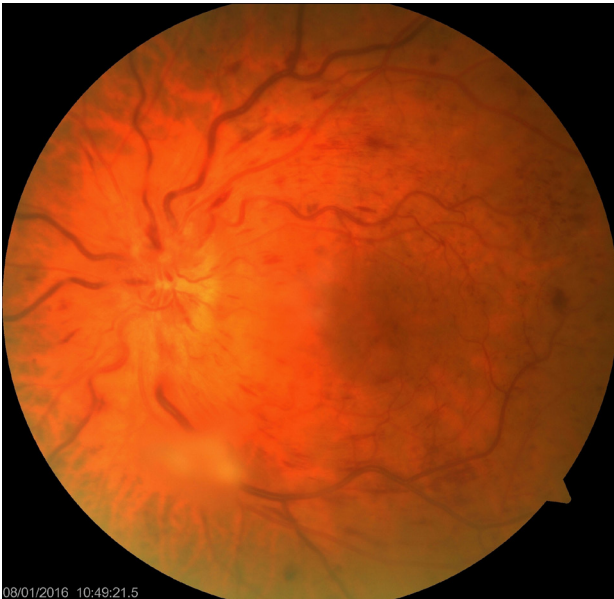


Figure 1 CRVO with intraretinal hemorrhage in each four quadrant without cotton wolle spots and exudates.

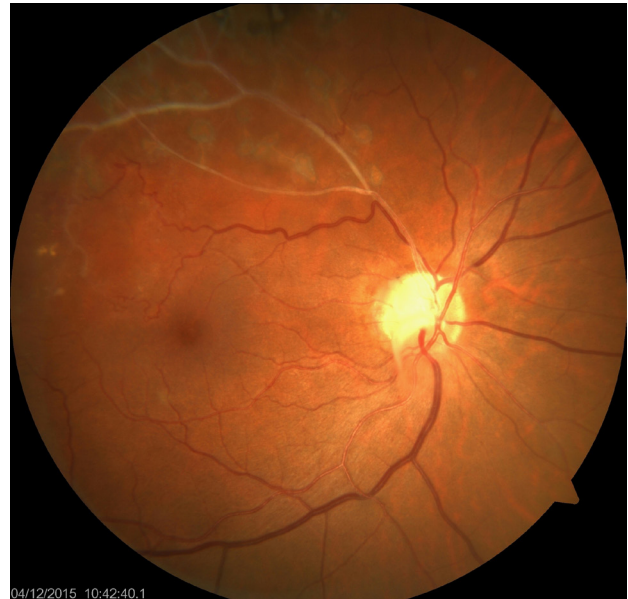

Figure 3 Fundus Photography of BRVO in superior temporal quadrant with prominent vascular occlusion.

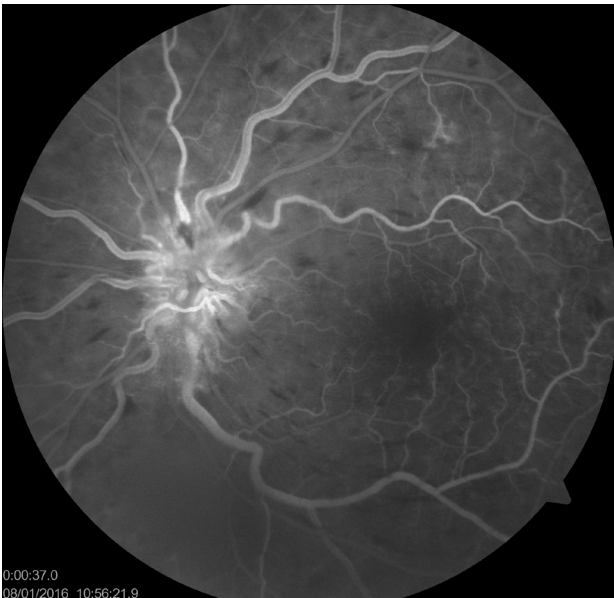


Figure 2 FFA of non ischaemic CRVO with sufficient perfusion without capillary drop out.

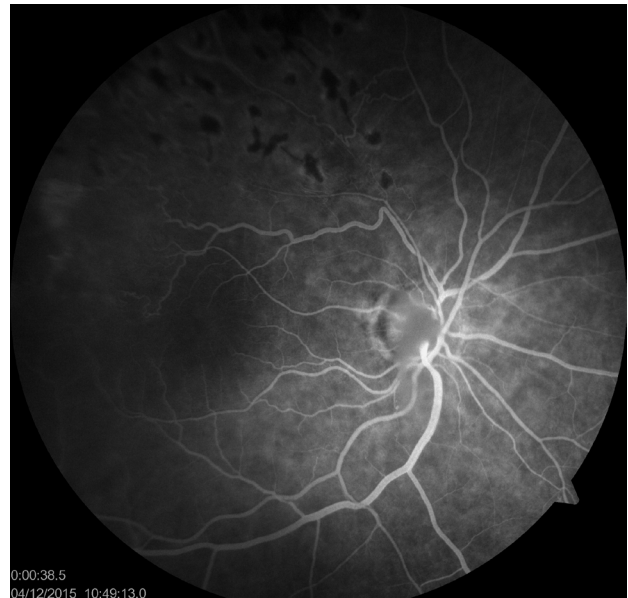

Figure 4 Focal Laser photocoagulation in ischemic peripheral retina in BRVO.

controls. In addition conventional laser treatment, but not PASCAL treatment, resulted in the up-regulation of VEGF. In Ito *et al*^[27] study immunohistochemical analysis showed that PASCAL treatment was associated with lower VEGF and F4/80 expression levels compared with conventional laser treatment. They also suggested that the short pulse duration with the PASCAL induced fewer inflammatory cytokines in the sensory retina compared with the conventional pulse duration which may prevent macular edema after panretinal photocoagulation. Similarly Alasil *et al*^[28] reported that PASCAL has minimized side effects of PRPC. But Chablani *et al*^[29] observed that Laser spots from PASCAL treatment exhibited an increasing elliptical shape toward the retinal periphery which is not uniform shape comparing to that in central retina. This shape difference was indirect evidence of unequal laser energy that reached to the peripheral retina, whereas novel navigated (NAVILAS) laser spots tended to be more uniform all over the retina which indicates equal, uniform and more effective treatment can be performed by NAVILAS. NAVILAS has

also has less pain during shorter treatment duration in comparison with conventional pattern laser. Both PASCAL and NAVILAS are recently developed effective and important for laser treatments on far peripheral retina in CRVO.

LASER PHOTOCOAGULATION FOR BRVO

Macular (Grid) Laser photocoagulation

Visual acuity is primarily decreased secondary to macular edema or retinal ischemia in both BRVO and CRVO. Fortunately macular edema is the most common cause of vision loss in BRVO. If left untreated, patients with BRVO will gain on average only 0.23 lines on the Early Treatment of Diabetic Retinopathy Study (ETDRS) scale after 3 years, VA reaches to only an average level of 20/70, but full recovery of vision is generally not achieved due to persistent edema and resulting structural damage even up to partial or full thickness macular hole. Laser photocoagulation has been, for

many years, the standard therapy for patients with macular edema secondary to branch retinal vein obstruction (BRVO). Data from BVOS testified that at 36 months the proportion of patients gaining at least 10 letters was significantly greater in patients receiving laser therapy than in those receiving no treatment. After the BVOS the gold standard of grid laser photocoagulation implemented for BRVO^[30]. But according to this study, VA improvement differences in between these two groups became apparent only after 12 months during the follow up period, furthermore 12% of patients treated with laser therapy had decreased in VA which is losing at least two letters at two consecutive visits during the study^[30]. But data from the Standard Care vs Corticosteroid for Retinal Vein Occlusion (SCORE) trial also demonstrated limited benefit for laser therapy at 12 months with the median gain of six letters at 12 months. Furthermore, poor vision persists despite photocoagulation treatment in many patients, and its use is not recommended until 3 months after development of BRVO^[18,19,31,32].

Laser photocoagulation had been used for additional treatment in some studies such as in BRAVO study patients not achieving sufficient improvements at month 3 could receive laser therapy, even according to BVOS the benefits of laser therapy are minimal within the first year of treatment thus possibly confounding the results from month 3 onwards^[30-32].

In addition, most studies about Macular edema in BRVO have heterogeneous control groups ranging from sham injection in BRAVO to grid laser photocoagulation in SCORE-BRVO^[19,20]. Donati *et al*^[33] reported that in BRAVO study grid was allowed as rescue therapy, which complicates the indirect comparison results of the studies. In one trial compared grid laser photocoagulation in combination to intravitreal bevacizumab 1.25 mg to bevacizumab alone, and found even better results in the combination group (+20) letters (median 3 injections). Therefore a number of alternative therapies are currently available even more, there are currently several trials registered that compare intravitreal anti- VEGF with macular laser photocoagulation and/ or a combination therapy. Recently published RABAMES study performed to compare standard-of-care grid laser photocoagulation versus intravitreal ranibizumab (IVR) injection versus a combination of both in the treatment of chronic macular oedema persisted more than 3 months secondary to branch retinal vein occlusion^[34]. The six-month results of the study suggest that ranibizumab may be superior to grid laser in improving visual acuity. But Grid has combined with ranibizumab neither enhanced functional and morphological improvement comparing to IVR group, nor did it prevent or prolong recurrence of macular oedema. In IVR groups, Central retinal thickness increased slowly after stopping injections, whereas improvement in visual acuity was sustained, this observation indicating that morphological changes occur prior to functional impairment. Less laser retreatments were required in combination group (2/10) than grid group (7/10) which is an indirect evidence of effectiveness of intravitreal ranibizumab injection in BRVO treatment^[34]. Brighter Study a 24-month, phase IIIB, open-label, randomized, active controlled, three-arm, multicenter study conducted by Barcelona Retina Group which was assessing the efficacy and safety of an individualized, stabilization criteria-driven pro re nata (PRN) dosing regimen with 0.5-mg ranibizumab intravitreal injections applied with or without adjunctive laser treatment versus laser photocoagulation in patients with visual impairment due to macular edema secondary to BRVO up to month 6. Results from this study showed that Ranibizumab with an individualized VA-based regimen, with or without laser, showed statistically significant superior improvement in BCVA compared

with laser alone in patients with BRVO^[35].

Since Laser photocoagulation has a destructive effect on retina it has no therapeutic benefits on ischaemic macular edema. Other new studies will give additional information and help to clarify the roles of the laser and drug therapies in the management of patients with RVO.

Focal Laser photocoagulation

Squirrel *et al*^[36] reported that they compared normal and ischaemic retinal areas following branch retinal vein occlusion with Heidelberg Retinal Flowmeter and observed a significant reduction in blood flow in the ischaemic area. This ischaemic part of retina cause secretion of chemical mediators mainly VEGF similar to CRVO, may leads to neovascularisation. Focal Laser photocoagulation can be used for treatment of neovascularisation. To prevent collateral obstruction Fluorescein angiography guided Focal Laser photocoagulation is recommend. (Figure 3: BRVO Figure 4: Focal Laser photocoagulation peripheral retina) However, laser therapy is necessary for both treatment and prevention of complication of in various ocular disease similar to RVO, it is well known to be associated with various complications, including foveal burns, central visual field defects, exacerbation of macular oedema and acute glaucoma. Therefore patient selection, dosing and application are very important for decirable outcome.

Other treatment modalities with Laser

Even Laser-induced chorioretinal venous anastomosis, had been performed to treat both in nonischemic or ischemic central retinal vein occlusion, it can be associated with severe complications such as, localized preretinal fibrosis, epiretinal membrane cause to Traction Retinal Detachment, either intravitreal, intraretinal and subretinal neovascular membranes occurring at the anastomotic site^[37]. Therefore nowadays it is not as popular as it used to be. Arteriovenous sheathotomy and surgical arteriovenous surgical chorioretinal venous anastomosis were other alternative treatments in RVO.

Although the primary treatment for macular edema due to retinal vein occlusion has changed from observation in CRVO and laserphotocoagulation in BRVO to administration of intravitreal anti-vascular endothelial growth factor (VEGF) or anti-inflammatory agents, photocoagulation is still keeping its importance mainly for treatment of ischemic areas. But still head-to-head trials and research to identify responders for different treatment regime, is needed to help clinicians make the right choices for patient with RVO.

COMPETING INTERESTS

The authors declare that there is no conflict of interest regarding the publication of this paper.

REFERENCES

- 1 SawadaO, Ohji Mev. Retinal Vein Occlusion Survey *Ophthalmol* 2016; **55**: 147-153
- 2 Mc Intosh RL, Rogers SL, Lim L, Cheung N, Wang JJ, Mitchell P, kowalski JW, Nguyen HP, Wong T. Natural History of Central Retinal Vein Occlusion: An Evidence-Based Systematic Review *Ophthalmol*. 2010; **117**: 1113-11123
- 3 O'Mahoney PRA, Wong DT, Ray JG. Retinal vein occlusion and traditional risk factors for atherosclerosis. *Archives of Ophthalmology*. 2008; **126**(5): 692-699
- 4 Wong TY, Scott IU. Clinical practice. Retinal-vein occlusion. *N*

- Engl J Med.* 2010; **363**(22): 2135-2144.
- 5 Parodi MB, Bandello F. Branch retinal vein occlusion: classification and treatment. *Ophthalmologica.* 2009; **223**(5): 298-305
 - 6 Jaulim A, Ahmed B, Khanam T, Chatziralli IP. Branch retinal vein occlusion: epidemiology, pathogenesis, risk factors, clinical features, diagnosis, and complications. An update of the literature. *Retina.* 2013; **33**(5): 901-910
 - 7 Yau JWY, Lee P, Wong TY, Best J, Jenkins A. Retinal vein occlusion: an approach to diagnosis, systemic risk factors and management. *Internal Medicine Journal.* 2008; **38**(12): 904-910.
 - 8 Rehak M, Wiedemann P. Retinal vein thrombosis: pathogenesis and management. *Journal of Thrombosis and Haemostasis.* 2010; **8**(9): 1886-1894.
 - 9 Hayreh SS, Zimmerman MB. Branch retinal vein occlusion: natural history of visual outcome. *JAMA Ophthalmology.* 2014; **132**(1): 13-22.
 - 10 Mohamed Q, McIntosh RL, Saw SM, Wong TY. Interventions for central retinal vein occlusion. An evidence-based systematic review. *Ophthalmology.* 2007; **114**(3): 507-519.
 - 11 Ehlers JP, Fekrat S. Retinal vein occlusion: beyond the acute event. *Survey of Ophthalmology.* 2011; **56**(4): 281-299
 - 12 Stem MS, Talwar N, Comer GM, Stein JD. A longitudinal analysis of risk factors associated with central retinal vein occlusion. *Ophthalmology.* 2013; **120**(2): 362-370.
 - 13 Jaulim A, Ahmed B, Khanam T, Chatziralli IP. Branch retinal vein occlusion: epidemiology, pathogenesis, risk factors, clinical features, diagnosis, and complications. An update of the literature. *Retina.* 2013; **33**(5): 901-910
 - 14 Hayreh SS. Neovascular Glaucoma Prog Retin Eye Res 2007 **26**(5): 470-485
 - 15 Chatziralli IP, Jaulim A, Peponis VG, Mitropoulos PG, Moschos MM. Branch retinal vein occlusion: treatment modalities: an update of the literature. *Seminars in Ophthalmology.* 2014; **29**(2): 85-107.
 - 16 CVOS. Evaluation of grid pattern photocoagulation for macular edema in central vein occlusion. The central vein occlusion study group. *Ophthalmology.* 1995; **102**(10): 1425-1433.
 - 17 Varma R, Wu J, Chong CVOS. Evaluation of grid pattern photocoagulation for macular edema in central vein occlusion. The central vein occlusion study group. *Ophthalmology.* 1995; **102**(10): 1425-1433
 - 18 Blodi BA, Domalpally A, Scott IU, Ip MS, Oden NL, Elledge J, Warren K, Altaweel MM, Kim JE, Van Veldhuisen PC. Standard Care vs Corticosteroid for Retinal Vein Occlusion (SCORE) Study system for evaluation of stereoscopic color fundus photographs and fluorescein angiograms: SCORE Study Report 9. *Arch Ophthalmol* 2010; **128**: 1140-5
 - 19 Ip MS, Scott IU, VanVeldhuisen PC, Oden NL, Blodi BA, Fisher M, Singerman LJ, Tolentino M, Chan CK, Gonzalez VH; SCORE Study Research Group. A randomized trial comparing the efficacy and safety of intravitreal triamcinolone with observation to treat vision loss associated with macular edema secondary to central retinal vein occlusion: the Standard Care vs Corticosteroid for Retinal Vein Occlusion (SCORE) study report *Arch Ophthalmol* 2009; **127**: 1101-14
 - 20 Chan CK, Ip MS, VanVeldhuisen PC, Oden NL, Scott IU, Tolentino MJ, Blodi BA. SCORE Study report #11: incidences of neovascular events in eyes with retinal vein occlusion. *Ophthalmology* 2011; **118**: 1364-1372
 - 21 Fujio N, Feke GT, Goger DG, McMeel JW. Regional retinal blood flow reduction following half fundus photocoagulation treatment. *Br J Ophthalmol.* 1994; **78**: 335-338.
 - 22 Bertram B, Arend O, Moritz A, Wolf S, Remky A. Retinal haemodynamics in diabetic retinopathy before and after laser coagulation. *Klin Monatsbl Augenheilkd.* 1996; **208**(3): 152-156
 - 23 Vilser W, Jutte A, Seewald D, Dietze U, Friedzich R, Konigsdoffer E, Buchner D. Measurements of retinal microcirculation in retinal vessel occlusion before and after treatment. *Graefes Arch Clin Exp Ophthalmol.* 1986; **224**(2): 179-183.
 - 24 Arvas S, Ocakoglu O, Ozkan S. The capillary blood flow in ischaemic type central retinal vein occlusion: the effect of laser photocoagulation. *Acta Ophthalmologica.* 2002; 490-494
 - 25 Wald KJ. The CVOS Group M and N Reports. *Ophthalmology.* 1996; **103**: 352-354
 - 26 Mitsch C, Pemp B, Kriechbaum K, Bolz M, Scholda C, Schmidt-Erfuth U. Retinal morphometry changes measured with spectral domain-optical coherence tomography after pan-retinal photocoagulation in patient with proliferative diabetic retinopathy. *Retina* 2015 Nov 11. [Epub ahead of print]
 - 27 Ito A, Hirano Y, Nozaki M, Ashikari M, Sugitani K, Ogura Y. Short pulse laser induces less inflammatory cytokines in the murine retina after laser photocoagulation. *Ophthalmic Res.* 2015; **53**(2): 65-73
 - 28 Alasil T, Waheed NK. Pan retinal photocoagulation for proliferative diabetic retinopathy. pattern scan laser versus argon laser. *Curr Opin Ophthalmol.* 2014 May; **25**(3): 164-70
 - 29 Chablani J, Mathai A, Rani P, Gupta V, Arevalo JF, Kozaki I. Comparison of conventional pattern and panretinal photocoagulation in proliferative diabetic retinopathy. *Invest Ophthalmol Vis Sci* 2014 May 1; **55**(6): 3432-Vis Sci 2014 May 1; **55**(6): 3432-8
 - 30 BVOS. Argon laser photocoagulation for macular edema in branch vein occlusion. The branch vein occlusion study group. *Am J Ophthalmol.* 1984; **98**(3): 271-282.
 - 31 Thach AB, Yau L, Hoang C, Tuomi L. Time to clinically significant visual acuity gains after ranibizumab treatment for retinal vein occlusion: BRAVO and CRUISE trials. *Ophthalmology.* 2014 May; **121**(5): 1059-66.
 - 32 Varma R, Bressler NM, Suñer I, Lee P, Dolan CM, Ward J, Colman S, Rubio RG; BRAVO and CRUISE Study Groups. Improved vision-related function after ranibizumab for macular edema after retinal vein occlusion: results from the BRAVO and CRUISE trials. *Ophthalmology.* 2012 Oct; **119**(10): 2108-18.
 - 33 Donati S, Barosi P, Bianchi M, Al Oum M, Azzolini C Combined intravitreal bevacizumab and grid laser photocoagulation for macular edema secondary to branch retinal vein occlusion. *Eur J Ophthalmol.* 2012; **22**: 607-614
 - 34 Pielen A, Mirshahi A, Feltgen N, Lorenz K, Korb C, Junker B, Schaefer C, Zwiener I, Hattenbach LO for the RABAMES Study Group Ranibizumab for Branch Retinal Vein Occlusion Associated Macular Edema Study (RABAMES): six-month results of a prospective randomized clinical trial. *Acta Ophthalmologica* 2015 Feb; **93**(1): 29-37
 - 35 Tadayoni R, Waldstein SM, Boscica F, Gerding H, Pearce I, Priglinger S, Wenzel A, Barnes E, Gekkieva M, Pilz S, Monés J; BRIGHTER study group. Individualized Stabilization Criteria-Driven Ranibizumab versus Laser in Branch Retinal Vein Occlusion: Six-Month Results of BRIGHTER. *Ophthalmology.* 2016 Mar 30. doi: 10.1016/j.ophtha.2016.02.030. [Epub ahead of print]
 - 36 Squirrel DM, Watts A, Evans D, Mody C, Talbot JF A prospective evaluation of the Heidelberg retina flowmeter in diagnosing ischaemia following branch retinal vein occlusion: a masked, controlled comparison with fluorescein angiography. *Eye.* 2001; **15**: 261-266.
 - 37 McAllister IL, Douglas JP, Constable IJ, Yu YD. Laser-induced chorioretinal venous anastomosis for nonischemic central retinal vein occlusion: evaluation of the complications and their risk factors. *Am J Ophthalmol.* 1998; **126**(2): 219-229

Peer reviewers: Yong Tao, Department of Ophthalmology, People's Hospital, No.11 Xizhimen South Street, Peking University, Beijing, China; Jia-Kang Wang, Department of Medicine, National Yang Ming University, Department of Ophthalmology, Far Eastern Memorial Hospital, New Taipei City, Taiwan.