

Foveal Pseudoectopia: Report of A Case and Review of the Literature

Emrullah Beyazyildiz, Mehmet Citirik

Emrullah Beyazyildiz, MD, Samsun Research and Training Hospital, Samsun, Turkey

Mehmet Citirik, MD, SB Ankara Ulucanlar Eye Education and Research Hospital, Ankara, Turkey

Correspondence to: Mehmet Citirik, MD, Associated Professor, Ulucanlar Cad. No: 59 06230 Altindag, Ankara, Turkey

Email: mcitirik@hotmail.com

Telephone: +90-312-3126261

Fax: +90-312-3124827

Received: March 3, 2016

Revised: June 3, 2016

Accepted: June 6, 2016

Published online: September 18, 2016

ABSTRACT

A 17-year old woman presented to the ophthalmology department with low visual acuity in the right eye. The best-corrected visual acuity was 1/20 in the right eye and 20/20 in the left. Right fovea was observed in the upper temporal quadrant of posterior pole. Fluorescein angiography (FA) of right eye showed superior to a line drawn horizontally of central fovea through the center of the optic disc. Amblyopia and incyclotropia were observed in right eye. Increased latency (P: 139 ms) and decreased amplitude (A: 6.88 μ v) was detected on Visual Evoked Potentials (VEP) testing for right eye. L-dopa, insulin, and clonidine tests were performed for short stature, and confirmed the diagnosis of growth hormone deficiency. Bagolini and Maddox double rod tests confirmed incyclotropia of the globe. Herein, we presented a case of unilateral idiopathic foveal pseudoectopia associated with incyclotropia and growth hormone deficiency which has not been previously described.

Key words: Foveal ectopia; Amblyopia; Growth hormone deficiency

© 2016 The Authors. Published by ACT Publishing Group Ltd.

Beyazyildiz E, Citirik M. Foveal Pseudoectopia: Report of A Case

and Review of the Literature. *International Journal of Ophthalmic Research* 2016; 2(3): 173-176 Available from: URL: <http://www.ghrnet.org/index.php/ijor/article/view/1629>

INTRODUCTION

The anatomic fovea actually encompasses an area contained just within the optic nerve and the superior and inferior retinal temporal arcades, and extends temporally approximately two disc diameters beyond the central fovea. The central portion of the macula is the fovea, which is 1 disc diameter wide. The center of fovea lies 0.5 mm inferior to a line drawn horizontally through the center of the disc^[1]. Foveal ectopia is a condition in which the fovea is displaced markedly from its normal position^[2]. The etiology of foveal ectopia includes trauma, chorioretinitis, developmental causes, vitreoretinal surgery and retinopathy of prematurity (ROP)^[2].

Pituitary hormonal deficiency most often involves growth hormone (GH) alone^[3]. As in idiopathic hypopituitarism, the defect may be limited to GH, or it can involve deficiencies of several other anterior pituitary hormones. The diagnosis of classic GH deficiency is suspected in cases of profound postnatal growth failure, with heights more than 3 standard deviations below the mean for age and gender^[3].

We described a patient with unilateral idiopathic foveal pseudoectopia associated with incyclotropia and growth hormone deficiency.

CASE REPORT

A 17-year old woman was presented to the ophthalmology department with low visual acuity in the right eye. Her best-corrected visual acuity was 1/20 OD and 20/20 OS. Intraocular pressures were 15 and 14 mmHg applanation in the right and left eyes respectively. Anterior segment examination findings were bilaterally normal. Right fovea was observed superior to a line drawn horizontally of central fovea through the center of the disc (Figure 1). Posterior segment examination of the left eye was normal. Fluorescein Angiography (FA) revealed no pathology for left eye. FA of right eye showed superior

to a line drawn horizontally of central fovea through the center of the optic disc (Figure 2). Limitations in range of motion of one or both eyes were not obtained. Ocular deviation was not detected on the alternate cover test.

Her family history regarding ophthalmologic diseases was unremarkable. Electroretinography (ERG) of both eyes was within normal limits. Increased latency (P: 139 ms) and decreased amplitude (A: 6.88 μ V) was detected on Visual Evoked Potentials (VEP) testing

for right eye (Figure 3). VEP of the left eye was within normal limits (Figure 3). Magnetic Resonance Imaging (MRI) of the brain and visual system was showed no pathology.

Medical evaluation of the patient revealed short stature (body length 133 cm and weight 36 kg). L-dopa, insulin, and clonidine test were performed for the suspected GH deficiency and test results confirmed the diagnosis of GH deficiency. The patient was treated with recombinant somatotropine with 0.3 mg/kg/wk.

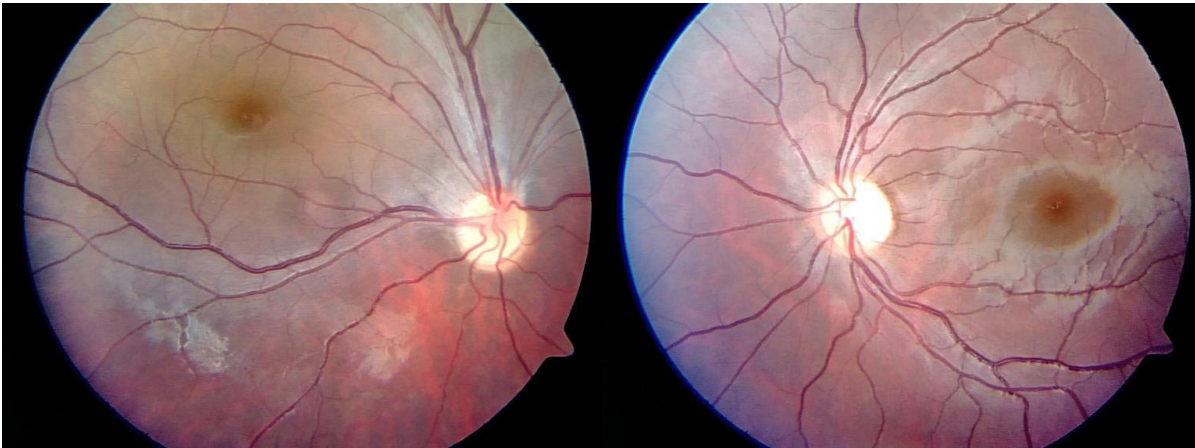


Figure 1 Colored fundus photography of patient.

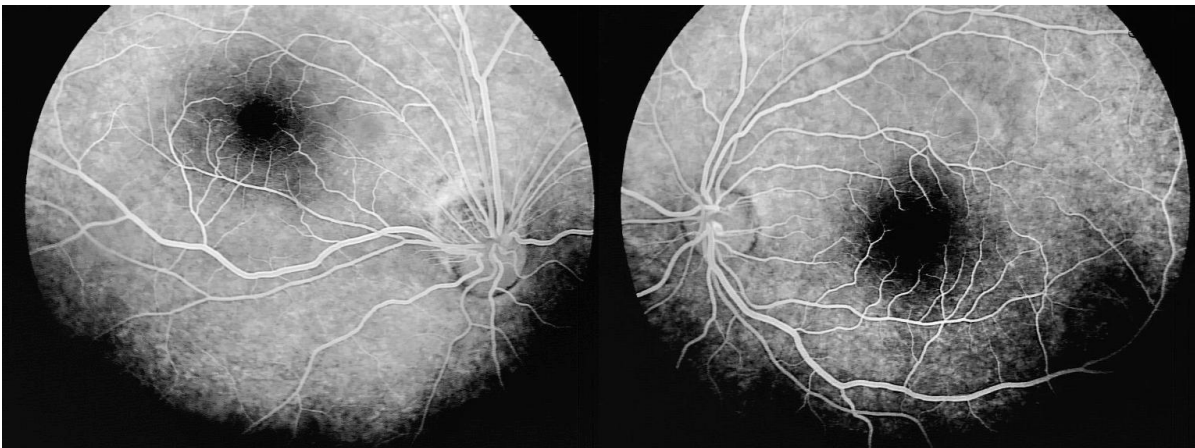


Figure 2 Fluorescein angiography (FA) of patient.

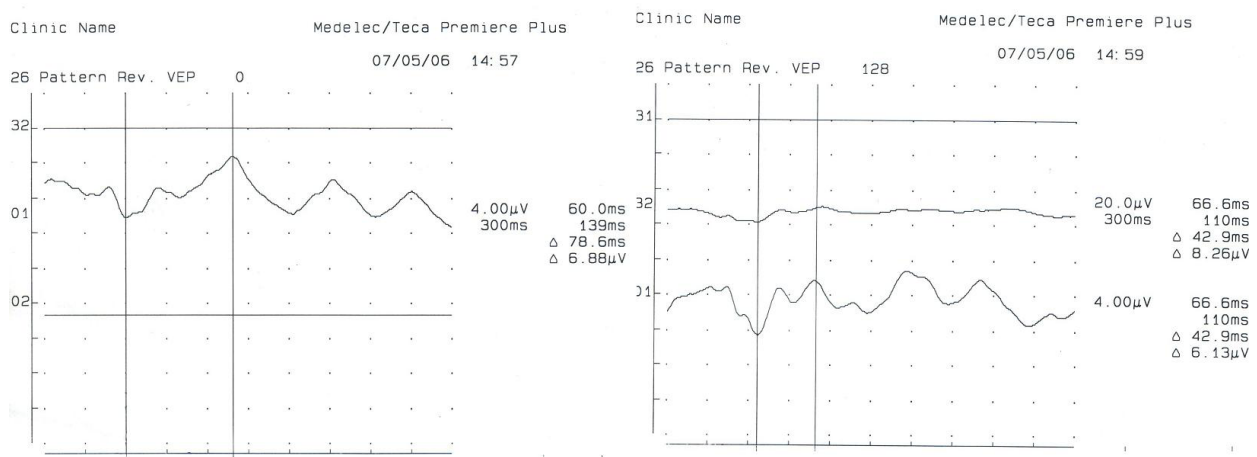


Figure 3 Visual Evoked Potentials (VEP) of patient.

DISCUSSION

In most healthy patients, the foveal center lie temporal to and just inferior to the vertical center of the optic nerve^[1]. The fovea lies 0.5 mm inferior to a line drawn horizontally through the center of the disc. Foveal ectopia occurs in various congenital and acquired conditions, including trauma, chorioretinitis, optic nerve coloboma, retinopathy of prematurity, developmental causes, familial exudative vitreoretinopathy, Norrie's disease, incontinentia pigmenti, and combined hamartoma of the retina and retinal pigment epithelium^[1,2]. In our patient, temporal and superior misalignment of the fovea was seen in her right eye. This was presumably developmental anomaly and may be associated with growth hormone deficiency.

First report associated with foveal displacement was described by Bernhard in 1988^[4]. In this case macula displaced inferolaterally in left eye. There were microcornea and peripheral pigmentation of the retina in left eye of the patient. Adam reported a case with isolated macular heterotropia displaced superolaterally without any other abnormalities^[5]. These cases were presumably congenital and developmental anomalies. Foveal displacement may be associated with intraocular surgeries such as retinal detachment or macular hole surgeries^[6-8]. In a study performed Kawano *et al*^[8] after vitrectomy with ILM peeling for macular hole, fovea of the patients displaced toward the optic disc. Displacement of the macula was also reported in cases with epiretinal membrane and epiretinal membrane peeling surgeries^[9,10]. Thus foveal displacement could be an acquired condition and commonly occurs after retinal surgeries. Strabismus and amblyopia are commonly observed complications of foveal displacement. Nasal displacements of the fovea after retinal surgeries cause esotropia in these patients. Amblyopia is reduced visual acuity as a result of defective central visual processing and could occur in congenital cases^[11]. Since the pattern VEP is generally accepted to be derived from visual cortical responses, any disorder that degrades visual information between the cornea and visual cortex can potentially affect the pattern VEP. The pattern VEP is abnormal in amblyopia^[12]. Especially decreasing in amplitude and increasing in latency may be seen^[13]. In our patient amblyopia were observed and VEP findings were supported this diagnosis.

Most reported cases of foveal ectopia are pseudoexotropia in the literature^[14]. But in our patient, exo or eso deviation was not observed. This condition may be explained by foveal suppression and scotoma. Suppression is a positive inhibitory reflex occurring within the framework of binocular vision; it permits the cortex to ignore visual sensations dispatched from the retina of the nonfixating eye on which are projected the images from the area of conscious regard^[15]. This adaptation eliminates central diplopia. The Bagolini striated lens that described the suppression scotoma gap in one of the streaks presents requires for determining degree of maturity^[15]. In our patient, Bagolini striated glasses was used for testing sensory aspects of fusion. Suppression and foveal scotoma were detected. Any vertical displacement of the fovea with respect to the optic disc beyond the normal ranges indicates that a cyclodeviation of the globe is present. Incyclotorsion is present if the fovea is located above the physiological horizontal line and excyclotorsion is present if the fovea is located below the physiological horizontal line^[16]. If there is abnormal torsion, this situation may be related with overacting superior or inferior oblique muscle present as well. Overacting superior oblique muscle produce intorsion and overacting inferior oblique muscle produce extorsion of the globe^[16]. But in our patient incyclotropia was not associated with oblique muscle defects. This unilateral incyclotropia may be associated with growth hormone

deficiency.

Most patients with hypopituitarism have no demonstrable lesion of the pituitary or hypothalamus. The functional defect is mostly hypothalamic rather than pituitary. The deficiency may involve GH alone or multiple hormones^[17]. A variety of provocative tests have been devised that rapidly increase the level of GH in normal children^[18]. These include a 20-min period of strenuous exercise or administration of L-dopa, insulin, arginine, clonidine, or glucagon. Peak levels of GH below 7 µg/L are compatible with GH deficiency^[18]. In our patient, L-dopa, insulin, and clonidine tests were consistent with GH deficiency. So, the patient was treated with recombinant somatotropine with 0.3 mg/kg/wk.

Bilateral or unilateral optic nerve hypoplasia is often associated with hypopituitarism^[11]. When it is also associated with absence of the septum pellucidum, the condition is known as septo-optic dysplasia^[19]. But macular ectopia associated with growth hormone deficiency has not been described. The condition presented could be co-existence of irrelevant diverse entities. Concomitant presentation of foveal ectopia and isolated growth hormone deficiency in a single patient was described in this study.

Herein, we presented a case of foveal pseudoectopia with incyclotropia and associated with growth hormone deficiency without strabismus which has not been reported previously.

CONFLICT OF INTERESTS

The authors declare that they do not have conflict of interests.

REFERENCES

- 1 Jonas JB, Nguyen NX, Naumann GOH. The retinal nerve fiber layer in normal eyes. *Ophthalmology* 1989; **96**: 627- 632.
- 2 Rados WT, Scholz RO. Pseudostrabismus with heterotopia of the macula. *Am J Ophthalmol* 1958; **45**: 683-91.
- 3 Allen DB, Fost NC: Growth hormone therapy for short stature: Panacea or Pandora's box. *J Pediatr* 1990; **117**: 16-21.
- 4 Bernhard, P. Ein Fall von abnormer Lage der Macula lutea und partielllem Colobom der Chorioidea, *Arch. Augenh.* 1898; **37**: 51-57.
- 5 Adam M. Demonstration, in Transactions of Berlin Ophthalmological Society, *Centralbl. Prak. Augenh.* 1912; **36**: 267.
- 6 Itoh Y, Inoue M, Rii T, Ando Y, Hirakata A. Asymmetrical recovery of cone outer segment tips line and foveal displacement after successful macular hole surgery. *Invest Ophthalmol Vis Sci.* 2014; **55(5)**: 3003-11.
- 7 Lee E, Williamson TH, Hysi P, Shunmugam M, Dogramaci M, Wong R, Laidlaw DA. Macular displacement following rhegmatogenous retinal detachment repair. *Br J Ophthalmol.* 2013 **97(10)**: 1297-302.
- 8 Kawano K, Ito Y, Kondol M, Ishikawa K, Kachi S, Ueono S, Iguchi Y, Terasaki H. Displacement of foveal area toward optic disc after macular hole surgery with internal limiting membrane peeling. *Eye* 2012; **27**: 871-877.
- 9 Lo D, Heussen F, Ho HK, et al. Structural and functional implications of severe foveal dystopia in epiretinal membranes. *Retina* 2012; **32**: 340-348.
- 10 Weinberger D, Stiebel-Kalish H, Priel E, Narala R, Gasperini J, Bertoni B, Na M, Walsch AC, Fawzi AA Digital red-free photography for the evaluation of retinal blood vessel displacement in epiretinal membrane. *Ophthalmology* 1999; **106**: 1380-1383.
- 11 Hillis A, Flynn JT, Hawkins BS. The evolving concept of amblyopia: a challenge to epidemiologists. *Am J Epidemiol* 1983; **118**: 192-205.
- 12 Apkarian P, Spekrijse H: The use of the electroretinogram and visual evoked potentials in ophthalmogenetics. In Desmedt JE.

- Clinical Neurophysiology Updates, vol 3. Visual Evoked Potentials, New York, Elsevier, 1990, pp 169–223.
- 13 Gottlob I, Fendick MG, Guo S, Zubcov AA, Odom JV, Reinecke RD. Visual acuity measurements by swept spatial frequency visual-evoked-cortical potentials (VECPs): Clinical application in children with various visual disorders. *J Pediatr Ophthalmol Strabismus* 1990; **27**: 40-7.
 - 14 Griffin JR. Binocular anomalies: Procedures for vision therapy. Chicago: Professional press, 1976: **15**.
 - 15 Holopigian K, Blake R, Greenwald MJ Clinical suppression and amblyopia. *Invest Ophthalmol Vis Sci* 1988; **29**: 444.
 - 16 Wayne W. Apparent Foveal Displacement in Normal Subjects and in Cyclotropia. *Ophthalmology* 1982; **89(1)**: 58-62
 - 17 Brown RS, Vijayalakshmi B, Hayes E: An apparent cluster of congenital hypopituitarism in central Massachusetts: Magnetic resonance imaging and hormonal studies. *J Clin Endocrinol Metab* 1991; **72**: 10-11.
 - 18 Rose SR, Ross JL, Uriarte M, Barnes KM, Cassoria FG, Cutler GB jr. The advantage of measuring stimulated as compared with spontaneous growth hormone levels in the diagnosis of growth hormone deficiency. *N Engl J Med* 1988; **319**: 201-7.
 - 19 Hellstrom A, Wiklund LM, Svensson E, Albertsson-Wikland K, Stromland K. Optic nerve hypoplasia with isolated tortuosity of the retinal veins: a marker of endocrinopathy. *Arch Ophthalmol.* 1999; **117**: 880-4.

Peer reviewer: Eylem Degirmenci, MD, Associate Professor, Pamukkale University, School of Medicine, Department of Neurology, Pamukkale Universitesi, Tıp Fakultesi Hastanesi, Knıklı/ Denizli/20070/Turke.