

Neodymium YAG Laser Cystotomy for Giant Secondary Iris Cyst

Irfan Ergen, Fatma Gezer Savur, Burak Turgut, Orhan Aydemir

Irfan Ergen, Dışkapı Yıldırım Beyazıt Training and Research Hospital, Eye Diseases Clinic, Ankara, Turkey

Fatma Gezer Savur, Bağcılar Training and Research Hospital, Eye Diseases Clinic, Istanbul, Turkey

Burak Turgut, Orhan Aydemir, Fırat University, School of Medicine, Department of Ophthalmology, Elazığ, Turkey

Correspondence to: Burak Turgut, MD, Associate Professor of Ophthalmology, Fırat University, School of Medicine, Department of Ophthalmology, 23119, Elazığ, Turkey.

Email: drburakturgut@gmail.com

Telephone: +90-424-2388096

Fax: +90-424-2333555

Received: March 12, 2016

Revised: April 13, 2016

Accepted: April 17, 2016

Published online: September 18, 2016

Journal of Ophthalmic Research 2016; 2(2): 177-179 Available from:
URL: <http://www.ghrnet.org/index.php/ijor/article/view/1637>

INTRODUCTION

An iris cyst can develop as primary and secondary. The primary iris cyst is the type without any recognizable cause. Secondary iris cysts may occur due to trauma, ocular surgery and use of eye-drops including miotic and prostaglandin analog^[1,2]. They can cause the closure of visual axis, corneal decompensation, secondary glaucoma or uveitis and complicated cataract^[1,2]. In the management of the iris cysts, it has been used various treatment modalities including iridectomy, excision, diathermic coagulation, laser photocoagulation, the aspiration of cyst's inclusion, cryotherapy and the injection of a sclerosing substrate into the cyst^[1-5]. Here, we report a case with giant secondary iris cyst that was successfully treated with Neodymium YAG laser cystotomy (Nd: YAGLC).

ABSTRACT

We aimed to report a case with giant secondary iris cyst that was successfully treated with Neodymium YAG laser cystotomy (Nd: YAGLC). The case was 79 years old man having the visual loss in his left eye for several months. The visual acuity of his left eye was at the level of finger counting from one meter. The slit-lamp biomicroscopy revealed pseudoaphakia and a giant iris cyst in the chamber of the left eye unless intraocular pressure elevation. After Nd: YAGLC was applied to the cyst, it dramatically shrank and disappeared. At the 6th month following the treatment, there was no recurrence of the cyst. Nd: YAGLC is a safely treatment modality to be able use to effectively treat the giant secondary iris cyst without intraocular penetration.

Key words: Nd: YAG; Laser cystotomy; Giant; Secondary; Iris cyst

© 2016 The Authors. Published by ACT Publishing Group Ltd.

Ergen I, Gezer Savur F, Turgut B, Aydemir O. Neodymium YAG Laser Cystotomy for Giant Secondary Iris Cyst. *International*

CASE REPORT

A 79 years old man admitted to our clinic with complain of the visual loss in his left eye for several months. His systemic medical history was unremarkable. His best corrected visual acuities were 10/10 in the right eye and the level of finger counting from 1 meter in the left eye. His intraocular pressure (IOP) was 14 mmHg in both eyes. The slit-lamp biomicroscopy revealed bilateral pseudophakia and a fluid-filled giant iris cyst with a transparent anterior wall having a 5 × 6 mm in dimensions at clock-hours between four and seven in the chamber of the left eye (Figure 1A). Additionally, ciliary injection was noted in slit-lamp examination of the left eye. The cyst was occupying approximately a quarter of the volume of the anterior chamber and it was reaching to pupillary axis. The anterior wall of the cyst was in contact with corneal endothelium at 6-clock-hour. On fundus examination of both eyes, any pathology was no observed. Nd: YAGLC with a power of 2-2.5 mJ and 20 shots was applied to the anterior wall of the cyst was applied. The eye drops including corticosteroid (loteprednol 3 × 1) and anti-glaucomatous (brimonidine 2 × 1) were topically administered for ten days following the

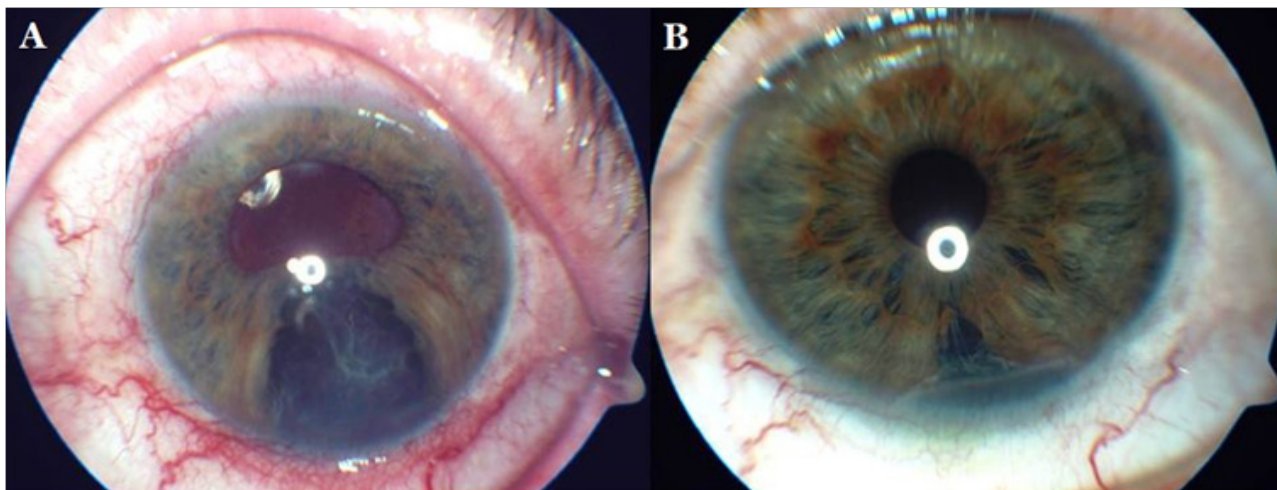


Figure 1 The view of the anterior segment of the patient with iris cyst. At the initial examination (A) and after the laser treatment (B).

treatment. The lesion and ciliary injection were dramatically reduced. At 10th day, his visual acuity was recovered to 1/10 and biomicroscopy revealed the peripheral anterior synechia between 5 and 6 clock-hours (Figure 1B). Significant IOP increasing or anterior chamber inflammatory reaction was no observed following the treatment. In the follow-up examination at 6th month following the treatment, there was no recurrence of iris cyst.

DISCUSSION

The most common cause of secondary iris cyst is ocular trauma and surgery. Secondary cysts have a higher recurrence and complication rate compared to primary cysts. It has been reported that they can occur following various ocular surgeries such as penetrating keratoplasty, refractive surgery, glaucoma surgery and cataract surgery. The pathogenic cause of the iris cyst is the entry of epithelial cells from the ocular surface into the anterior chamber following trauma or surgery and the epithelial proliferation in the anterior chamber.^[1,2]

The choice of the treatment modality for iris cyst depends on the type, location, size of the cyst and whether or not it causes symptoms. The treatment of primary iris cyst is recommended in case of the presence of complications while as prompt treatment of secondary iris cysts is required due to the fact that they lead to more complications such as the closure of visual axis, corneal decompensation, secondary glaucoma or uveitis and complicated cataract.^[1,2] In the presented case, the cyst was in contact with corneal endothelium and had a risk for corneal decompensation. Thus, we decided to apply the laser treatment.

The secondary cysts have usually more severe symptoms compared to primary cysts. Symptoms related secondary cysts are decreased vision due to the involvement of visual axis or corneal decompensation or complicated cataract, pain, redness, photophobia due to secondary glaucoma or uveitis.^[1,2] In our case, we considered that the visual acuity of the eye with the cyst reduced due to pupillary distortion or refractive alteration caused by the anterior chamber invasion of the fluid filled cyst.

In the management of the iris cysts, it has been used various treatment modalities including iridectomy, excision, diathermic coagulation, laser photocoagulation/disruption, the aspiration of cyst contents, cryotherapy and the injection of a sclerosing substrate into the cyst.^[1-6] Intracystic injection of phenol, ethanol, 50% dextrose saline, iodine and low-dose Mitomycin-C has been reported. It has

been considered that these agents might provide the cyst regression/deflation acting, though the permanent damage to epithelial and goblet cells that secrete the cyst fluid or via the flow of the fluid inside cyst in anterior chamber or the sclerosing of the cyst.^[1,2] Although the surgical excision of the iris cyst is the most definitive treatment in the management of all types of cysts, it has a higher complication rate.^[3,4]

However, no anyone is an ideal treatment modality because of their difficulty and complications. Currently, the destruction of the cyst wall with laser has been choice for the treatment of this pathology. An IOP elevation following the laser destruction may occur because of the occlusion of trabecular mesh-work due to viscous content extracted from the cyst.^[5-9] In our case, we did not observe an IOP elevation following the laser procedure.

Argon laser and Nd: YAGLC have been used to perforate the cyst wall in the treatment of the cyst. Although the reports on Nd: YAGLC in the treatment of iris cyst are not large numbers, it has been choiced for the treatment because of its effectivity and safety.^[5-7]

Xiao *et al*^[8] demonstrated that transpupillary Argon laser photocoagulation and Nd: YAGLC in the treatment of iris cyst have a good success rate and no recurrence along a follow-up of two months.

Gül *et al*^[9] also reported that they did not detect the recurrence of the cyst following YAGLC in a case at the follow-up of four months. We also did not observe the recurrence in our case along six months following the treatment.

In conclusion, Nd: YAGLC is a minimal invasive, efficacious and safely treatment method in the treatment of the giant secondary iris cyst because of its lower complication rates, ease of application, efficacy with less energy and shot.

CONFLICT OF INTERESTS

The authors declare that they do not have conflict of interests.

REFERENCES

- 1 Rao A, Gupta V, Bhadange Y, Sharma R, Shields JA. Iris cysts: a review. *Semin Ophthalmol.* 2011; **26**: 11-22.
- 2 Shields JA, Shields CL, Lois N, Mercado G. Iris cysts in children: classification, incidence, and management. The 1998 Torrence A Makley Jr Lecture. *Br J Ophthalmol.* 1999; **83**: 334-338.
- 3 Shin SY, Stark WJ, Haller J, Green WR. Surgical management of recurrent iris stromal cyst. *Am J Ophthalmol.* 2000; **130**: 122-123.
- 4 Haller JA, Stark WJ, Azab A, Thomsen RW, Gottsch JD. Surgical

- management of anteriorchamber epithelial cysts. *Am J Ophthalmol.* 2003; **135**: 309-313.
- 5 Kuchenbecker J, Motschmann M, Schmitz K, Behrens-Baumann W. Laser iridocystotomy for bilateral acute angle-closure glaucoma secondary to iris cysts. *Am J Ophthalmol.* 2000; **129**: 391-393.
- 6 Kathil P, Chin KJ, Ghaznawi N, Finger PT. Transpupillary Nd: YAG laser cystotomy for iris pigment epithelial cysts with secondary progressive angle closure. *Ophthalmic Surg Lasers Imaging.* 2011; **42**: e40-43.
- 7 Duan X, Zhang Y, Wang N. Laser treatment to large iris cyst secondary to trabeculectomy. *Can J Ophthalmol.* 2007; **42**: 316-317.
- 8 Xiao Y, Wang Y, Niu G, Li K. Transpupillary argon laser photocoagulation and Nd-YAG laser cystotomy for peripheral iris pigment epithelium cyst. *Am J Ophthalmol.* 2006; **142**: 691-693.
- 9 Gül A, Yaşar T, Sulhan AK, Batur M. A Non-Invasive Treatment Modality in an Iris Cyst Case: Nd: YAG Laser Cystotomy [Iris Kisti Olan Bir Olguda Non-İnvaziv Bir Tedavi Yöntemi Olarak Nd: YAG Lazer ile Kistotomi]. *Glo-Kat* 2011; **6**: 129-131.

Peer reviewers: Hülya Arpağ Güngel, Professor, Eye Clinic, Istanbul Education and Training Hospital, Kasap İlyas Mah., Orgeneral Nafiz Gürman Cad.P.K.34098, Fatih-İstanbul-Turkey; Muhammed Sahin, Assistant Professor, Dicle University Faculty Of Medicine, Department Ophthalmology, Dicle University Faculty Of Medicine 21280, Diyarbakir/Turkey.