

Macular Hole Retinal Detachment Following Surgical Removal of Myopic Choroidal Neovascularization: A Case Report

Fumihiko Yagi

Fumihiko Yagi, Department of Ophthalmology, Toho University Ohashi Medical Center, Tokyo, Japan

Correspondence to: Fumihiko Yagi, MD, Department of Ophthalmology, Toho University Ohashi Medical Center, 2-17-6 Ohashi, Meguro, Tokyo, 153-8515, Japan.

Email: fyagi@med.toho-u.ac.jp

Telephone: +81-3-3468-1251

Fax: +81-3-3468-2926

Received: July 9, 2016

Revised: July 25, 2016

Accepted: July 26, 2016

Published online: September 18, 2016

ABSTRACT

AIM: To report a case of Japanese woman who developed macular hole retinal detachment (MHRD) following surgical removal of myopic choroidal neovascularization (CNV).

PATIENT: The best-corrected visual acuity (BCVA) was 20/200 with -17.0 diopters in her left eye. She was diagnosed with juxtafoveal CNV and subretinal hemorrhage secondary to myopia. She underwent surgical removal of the CNV. Postoperatively, the CNV was not detected. 2.5 years postoperatively, the BCVA was 20/16. At 6.5 years postoperatively, however the patient presented with worsening vision. The BCVA was 20/220. Funduscopy examination as well as optical coherence tomography (OCT) revealed retinal detachment involving the posterior pole with a macular hole. The patient underwent a vitrectomy without removal of the internal limiting membrane (ILM), and silicone oil tamponade. Finally, Silicone oil was removed. At the latest visit, a flattened macula with a closed macular hole was observed by OCT. The BCVA was 20/100.

CONCLUSION: In this case, the reason for the development of MHRD without vitreous and spontaneous closure of the macular hole without vitreous or removal of the ILM is unknown. A higher index of suspicion of MHRD may be warranted for patients who complain of sudden vision loss after surgical treatment for myopic CNV.

Key words: Macular hole retinal detachment; Myopic choroidal neovascularization; Surgical removal; Vitrectomy; Internal limiting membrane

Yagi F. Macular Hole Retinal Detachment Following Surgical Removal of Myopic Choroidal Neovascularization: A Case Report. *International Journal of Ophthalmic Research* 2016; 2(3): 170-172 Available from: URL: <http://www.ghrnet.org/index.php/ijor/article/view/1782>

INTRODUCTION

High myopia is associated with progressive and excessive elongation of the globe of the eye, which results in various funduscopy changes in the macular area. These changes include localized areas of atrophy of the retinal pigment epithelium and choroid, subretinal hemorrhage, and macular choroidal neovascularization (CNV)^[1,2]. In addition, the development of a macular hole is not an uncommon complication in highly myopic eyes^[3]. In highly myopic eyes with a macular hole associated with a retinal detachment, closure of the hole is difficult to achieve surgery^[4]. For macular CNV in highly myopic eyes, surgical removal of the CNV was also performed until several years ago, but the recent development of photodynamic therapy (PDT) or intravitreal injections of anti-vascular endothelial growth factor (VEGF) has gained popularity as a potential treatment for CNV.

In this report, we present a patient with a macular hole retinal detachment (MHRD) following surgical removal of the CNV.

CASE REPORT

A 53-year-old woman presented with visual impairment in her left eye on October 1, 2002. The best-corrected visual acuity (BCVA) was 20/200 with -17.0 diopters in her left eye (right eye 20/32 × -13.5 diopters). Intraocular pressure was 16 mmHg (right eye = 12 mmHg).

She was diagnosed with juxtafoveal CNV and subretinal hemorrhage secondary to myopia and a posterior subcapsular cataract in her left eye (Figure 1). She underwent surgical removal of the CNV on October 25, 2002. The surgical technique consisted of a standard

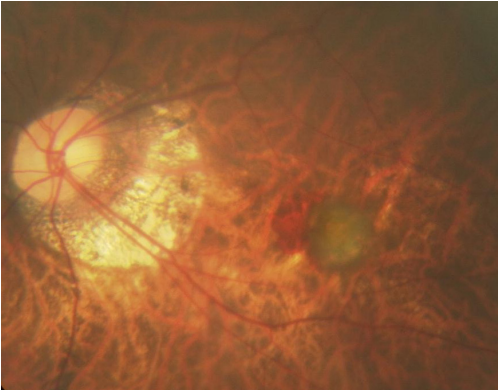


Figure 1 Fundus photography of the left eye before treatment demonstrates a juxtafoveal grayish area of choroidal neovascularization (CNV) with subretinal hemorrhage.

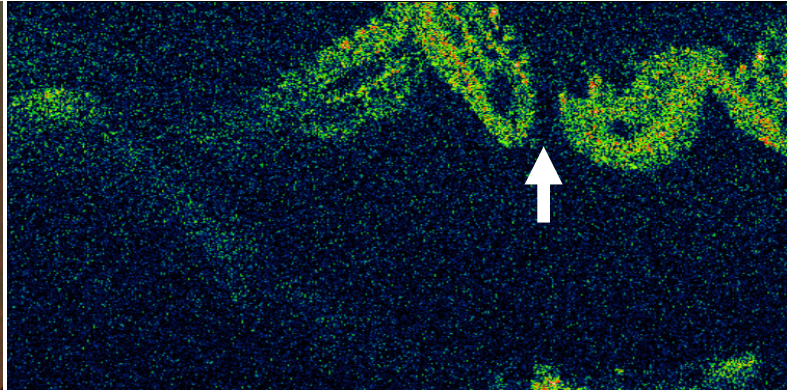


Figure 3 Ocular coherence tomography of the left eye, 6 years and 6 months after the initial treatment, shows retinal detachment with a macular hole (arrow).

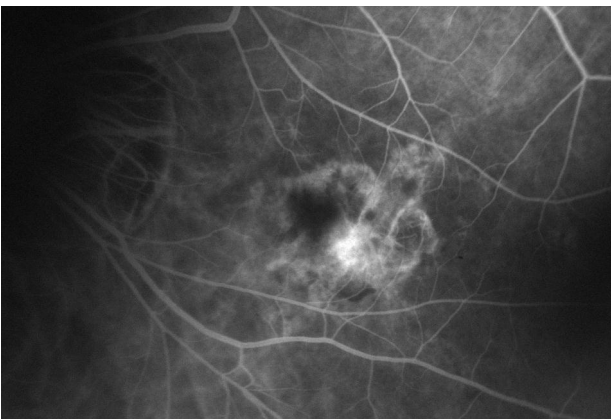


Figure 2 Late-phase fluorescein angiography, 3 months after surgical removal of the area of CNV shows no leakage, but a window defect is observed.

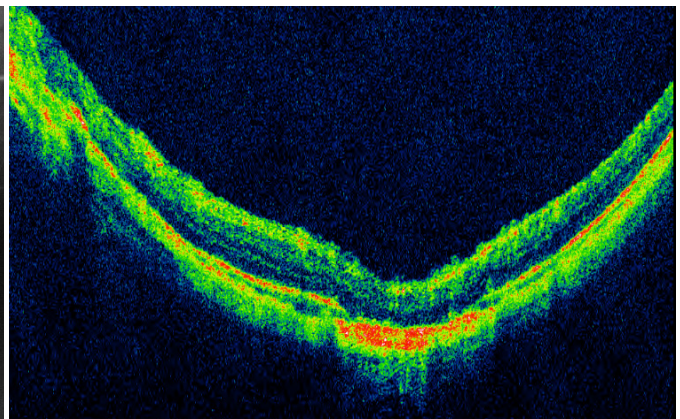


Figure 4 Optical coherence tomography at the final visit shows that the macular hole is closed and the retina is reattached.

three-port pars plana vitrectomy. The cortical vitreous was removed, and the posterior hyaloid membrane was then separated from the retina. An intentional tear was created, and the CNV membrane was removed through the intentional tear using subretinal forceps. The vitreous cavity was then filled with room air. The eye underwent simultaneous cataract surgery with intraocular lens implantation. After surgery, the CNV was not detected by fluorescein angiography (Figure 2). Approximately 2.5 years after surgery, the BCVA in her left eye was 20/16. At approximately 6.5 years after the surgery (April 25, 2009), however the patient presented with worsening vision in her left eye. Her BCVA was 20/220. Funduscopic examination as well as optical coherence tomography (OCT) revealed retinal detachment involving the posterior pole with a macular hole (Figure 3).

The patient underwent a standard three-port pars plana vitrectomy without removal of the internal limiting membrane (ILM), fluid-air exchange, and silicone oil tamponade. During surgery, a peripheral fundus examination was performed with scleral indentation, and no additional peripheral holes were observed except for the intentional tear that was produced at the last surgery. Then, Silicone oil was removed on February 2012. At the latest visit (May 11, 2016), a flattened macula with a closed macular hole was observed by OCT (Figure 4). The BCVA in the left eye was 20/100.

DISCUSSION

The development of MHRD may be a spontaneous process in highly myopic eyes. There are a few reports of the development of MHRD in myopic CNV^[5,6,7], and there is only one report of the development

of MHRD following combined PDT and intravitreal anti-VEGF injection in myopic CNV^[8]. And also there is only one report of the recurrence of MHRD after intravitreal anti-VEGF injection in myopic CNV^[9]. To the best of our knowledge, however, there are no reports on the development of MHRD after surgical removal of myopic CNV.

Chung^[8] reported that MHRD occurred shortly after PDT and repeated intravitreal injections of anti-VEGF. In their case, vitreous incarceration may have been induced at the needle insertion site, causing vitreoretinal traction and leading to the development of a macular hole and subsequent retinal detachment. Vitreous traction combined with scleral and chorioretinal changes is considered to be a causative factor in the formation of a macular hole in highly myopic eyes. In our case, however, vitreous traction was not related to the development of MHRD, because the vitreous had been removed in a previous surgery. Although, the causal relation between the surgical removal of myopic CNV and the development of the MHRD is not clear, the present case demonstrated that MHRD may develop spontaneously, because MHRD in our patient occurred 6.5 years after the surgical removal of myopic CNV.

Ichibe *et al*^[4] reported a 10% anatomic closure rate of macular holes with removal of the ILM. Recent attention has focused on the possibility that tangential vitreous traction plays a role in macular hole formation and subsequent retinal detachment in highly myopic eyes. Again, in the present case, because the vitreous had been removed in the previous surgery, tangential vitreous traction did not seem to have a role in forming the macular hole. Therefore, our observation provides support for the notion that macular hole closure

can occur without removal of the ILM. How closure of the macular hole was achieved without removal of the ILM in the present case, however, is uncertain.

Recently, PDT and intravitreal injections of anti-VEGF have gained popularity as potential treatments for myopic CNV. Myopic CNV is no longer removed surgically, but careful observation is necessary for those who have previously undergone surgical removal of myopic CNV, and received PDT or intravitreal injections of anti-VEGF, due to the possibility of developing MHRD.

In conclusion, although the causal relation between surgical removal of myopic CNV and the development of MHRD is not clear, patients should be informed about this potential complication. A higher index of suspicion for MHRD may be warranted in patients who complain of sudden vision loss after treatment for myopic CNV. Data previously presented at WOC 2014 as a poster, April 2014.

CONFLICT OF INTERESTS

The author declares that there is no conflict of interests regarding the publication of this paper.

REFERENCES

- 1 Steidl SM, Pruet RC. Macular complications associated with posterior staphyloma. *Am J Ophthalmol*, 1997; **123**: 181-187.
- 2 Hotchkiss ML, Fine SL. Pathologic myopia and choroidal neovascularization. *Am J Ophthalmol*, 1981; **91**: 177-183.
- 3 Kobayashi H, Kobayashi K, Okinami S. Macular hole and myopic refraction. *Br J Ophthalmol* 2002; **86**: 1269-1273.
- 4 Ichibe M, Yoshizawa T, Murakami K, Ohta M, Oya Y, Yamamoto S, Funaki S, Funaki H, Ozawa Y, Baba E, Abe H. Surgical management of retinal detachment associated with myopic macular hole: anatomic and functional status of the macula. *Am J Ophthalmol* 2003; **136**: 277-284.
- 5 Baba T, Moriyama M, Nishimuta A, Mochizuki M. Retinal detachment due to retinal break in the macular atrophy of a myopic choroidal neovascularization. *Ophthalmic Surg Lasers Imaging* 2007; **38**: 242-244.
- 6 Shimada N, Ohno-Matsui K, Yoshida T, Futagami S, Tokoro T, Mochizuki M. Development of macular hole and macular retinoschisis in eyes with myopic choroidal neovascularization. *Am J Ophthalmol* 2008; **145**: 155-161.
- 7 Chen ZQ, Lin JJ, Ye PP, Zhang L, Fang XY. Co-existent choroidal neovascular membrane and macular hole in pathologic myopia: a long follow-up clinical outcome and literature review. *International J Ophthalmol* 2013; **6**: 884-887.
- 8 Chung EJ, Koh HJ. Retinal detachment with macular hole following combined photodynamic therapy and intravitreal bevacizumab injection. *Korean J Ophthalmol* 2007; **21**: 185-187.
- 9 Otsuka K, Imai H, Shimoyama T, Nagai T, Honda S, Azumi A. Recurrence of macular hole retinal detachment after intravitreal Ranibizumab injection for the treatment of choroidal neovascularization from the remaining macular hole edge. *Case reports in Ophthalmol* 2012; **3**: 424-427.

Peer reviewer: Hülya Arpağ Güngel, Professor, Eye Clinic, Istanbul Education and Training Hospital, Kasap İlyas Mah, Orgeneral Nafiz Gürman Cad.P.K.34098, Fatih-İstanbul-Turkey.