

Macular Choroidal Thickness Measurement by Enhanced Depth Imaging Optical Coherence Tomography in Type (II) Diabetes Mellitus Patients

Hatem Mohamed Marey, Sameh Mohamed Elgouhary, Ahmed Anwar Gad

Hatem Mohamed Marey, Sameh Mohamed Elgouhary, Department of Ophthalmology, Menoufia University, Egypt
Ahmed Anwar Gad, Embaba Ophthalmic Hospital, Giza, Egypt

Conflict-of-interest statement: The author(s) declare(s) that there is no conflict of interest regarding the publication of this paper.

Correspondence to: Sameh Mohamed Elgouhary, Department of ophthalmology, Menoufia University, Shebin Elkom, Egypt.
Email: sameh_elgouhary@yahoo.com
Telephone: + 2-01005543214

Received: September 20, 2016

Revised: November 23, 2016

Accepted: November 29, 2016

Published online: December 31, 2016

ABSTRACT

AIM: To evaluate the central (macular) choroidal thickness in diabetic patients with type (II) diabetes mellitus (DM) using enhanced depth imaging optical coherence tomography (EDI-OCT).

METHODS: A prospective clinical interventional study included 100 eyes of 100 subjects divided into two groups: Group (A) included 50 eyes of 50 diabetic patients with type (II) DM and Group (B) included 50 eyes of 50 age-matched normal healthy controls with no gender or laterality specification. The central choroidal thickness (CCT) was measured from the posterior edge of RPE to the choroid-scleral junction at 1500 μm intervals up to 3000 μm from the fovea using EDI-OCT in 11 quadrants and regions.

RESULTS: Mean age in group (A) was 42 ± 7 years (range, 26-50 years), and 39 ± 9 years (range, 25-50 years) in group (B). Mean duration of DM was 7.96 ± 3.9 years in group (A). Subfoveal CCT was $291 \pm 42 \mu\text{m}$ in group (A), ($275.31 \pm 31 \mu\text{m}$ for no apparent retinopathy (No DR), $298 \pm 42 \mu\text{m}$ for non-proliferative diabetic retinopathy (NPDR), $309 \pm 58 \mu\text{m}$ for proliferative diabetic retinopathy (PDR), $277 \pm 29 \mu\text{m}$ for diabetic macular edema (DME) absent and $306 \pm 47 \mu\text{m}$ for DME present) while it was $284 \pm 54 \mu\text{m}$ in group (B). There was a statistically significant positive correlation

between CCT and DM duration ($p \leq 0.05$).

CONCLUSION: Choroidal thickness was found to be correlated with the stage of diabetic retinopathy (DR). Progressive thickening of the choroid with the progression of DR and/or the development of DME may reflect the concurrent progression of diabetic choroidopathy.

Key words: Choroidal Thickness; Diabetic Retinopathy; EDI-OCT; type (II) DM

© 2016 The Author(s). Published by ACT Publishing Group Ltd. This is an open access article under the CC BY-NC-ND license (<http://creativecommons.org/licenses/by-nc-nd/4.0/>).

Marey HM, Elgouhary SM, Gad AA. Macular Choroidal Thickness Measurement by Enhanced Depth Imaging Optical Coherence Tomography in Type (II) Diabetes Mellitus Patients. *International Journal of Ophthalmic Research* 2016; 2(4): 180-187 Available from: URL: <http://www.ghrnet.org/index.php/ijor/article/view/1847>

INTRODUCTION

Diabetic retinopathy (DR) is due to breakdown of retinal vasculature integrity and hemodynamic abnormalities^[1]. Doppler flowmetry studies indicated that choroidal blood flow may decrease in early stages of DR, and decrease further in presence of macular edema^[2].

Clinical and histopathologic findings suggest that vascular changes affect the diabetic choroids^[3]. Diabetic retinopathy may cause atrophy of the choriocapillaris endothelium as evidenced by histologic studies^[4]. The choroid, especially the choriocapillaris, provides oxygen and nutrients to the outer retina maintaining the highly metabolically active photoreceptors^[5]. Since there is no retinal vasculature in the fovea, impairment of the choriocapillaris may cause severe functional damage to the retinal tissue in the fovea. Therefore, *in vivo* evaluation of the structural changes in the choroid might be very insightful to determine the pathogenesis macular changes in diabetics. There are few clinical studies on choroidal angiopathy in DM this is because of the difficulty of imaging the choroid *in vivo*^[6]. Spectral-domain optical coherence tomography (SD-OCT) technology improves the scan

resolution; it shows bands corresponding to the retinal anatomical layers and allows seeing small details of photoreceptor layer. Recently, a new approach to improve depth imaging by OCT, termed Enhanced Depth Imaging (EDI), has been shown to be able to reliably image the full-thickness of the choroid. In this fashion, EDI-OCT may represent a useful approach to investigate, *in vivo*, the choroidal changes in diabetic eyes with or without diabetic retinopathy^[7].

Using EDI-OCT, we evaluated the choroidal thickness within the maculae of the eyes of type (II) DM patients.

PATIENTS AND METHODS

This is a prospective clinical interventional study carried out at Embaba Ophthalmic Hospital, Giza, Egypt and the Department of Ophthalmology, Menoufia University, Egypt between August 2014 and August 2015. This study was approved by the clinical research committee of Menoufia University and followed the tenets of the Declaration of Helsinki. The study included 100 eyes of 100 subjects divided into two groups: Group (A) included 50 eyes of 50 diabetic patients with type (II) DM and Group (B) included 50 eyes of 50 age-matched healthy controls with no gender or laterality specification. The participants were recruited from the general ophthalmic clinic; only one eye from each was designated for analysis. Exclusion criteria included participants with medical problems causing diminution of vision other than DM, uncontrolled hypertension, glaucoma, hyperopia of $\geq +3$ diopters, myopia of ≥ -6 D, any macular pathology other than DR, intraocular surgery (except for cataract) and treatment for DR in form of laser or intravitreal injection.

The participants underwent medical history taking including DM duration, visual acuity assessment, intraocular pressure measurement using Goldmann applanation tonometer, slit lamp examination and fundoscopy. Diabetic retinopathy was graded according to the American academy of ophthalmology (AAO) into: No apparent retinopathy (No DR), non-proliferative diabetic retinopathy (NPDR), proliferative diabetic retinopathy (PDR), Diabetic Macular Edema (DME) absent and present.

Choroidal images were performed in the EDI mode of the Spectralis SD-OCT device (Heidelberg Engineering, Dossenheim, Germany, software version 5.6.3.0) that has an acquisition rate of 40,000 A-scans per second. It uses a dual-beam SD-OCT and a confocal scanning laser ophthalmoscope (cSLO) that uses a scanning laser diode with a wavelength of 870 nm and an infrared reference image simultaneously to provide images of ocular structures. It incorporates a real-time eye tracking system. The EDI-OCT scans were captured by a single operator (AA) using the Spectralis EDI mode, a preset software-driven algorithm that places the RPE near the zero-delay line while producing an upright enhanced choroidal image.

The OCT star was used that encounters six consecutive scans in equally spaced angular orientations (30°) in a radial spoke pattern, each centered at the fovea (Figure 1).

The EDI-OCT scans were viewed and measured manually using a special caliper ruler incorporated in the Spectralis software from the outer border of the hyper-reflective line corresponding to the RPE-Bruch's complex to the hyporeflective line or margin corresponding to the chorio-scleral Interface. First the sub-foveal CCT (F) was measured then manual segmentation at 1500 μm intervals up to 3000 μm in each side of the 6 scans. Two circles centered on the fovea were developed; the smaller with 1500 μm radius and the larger with 3000 μm radius. Both, with 2 diagonal lines centered on the fovea, were divided into 9 regions nearly corresponding to the 9 ETDRS regions of the retinal thickness map. (Figures 2, 3 and 4).

Statistical Analysis

Statistical analysis was performed on the IBM SPSS (Statistical Package for Social Sciences) software, version 21.0. The Independent t-test data analysis was employed to test for difference in numerical variables between the two groups, and Chi Square test was used for non-numerical variables. Data were expressed as Mean \pm Standard Deviation. Pearson's correlation was used for correlating both age and duration of DM with CCT. A 95% confidence interval and a 5% level of significance were adopted; therefore, the results with a *P* value ≤ 0.05 were considered significant.

RESULTS

Patients' Data (Table 1)

This study included 100 eyes of 100 subjects divided into two groups with no gender or laterality specification. Group (A) included 50 eyes of 50 diabetic patients with type (II) DM aged from 20 to 50 years old with DM duration of 7.96 ± 3.9 (1-15) years and were subcategorized into: 22 females (44%) and 28 males (56%); 21 right eyes (42%) and 29 left eyes (58%); 16 eyes (32%) with No DR, 28 eyes (56%) with NPDR and 6 eyes (12%) with PDR; 26 eyes (52%) with DME

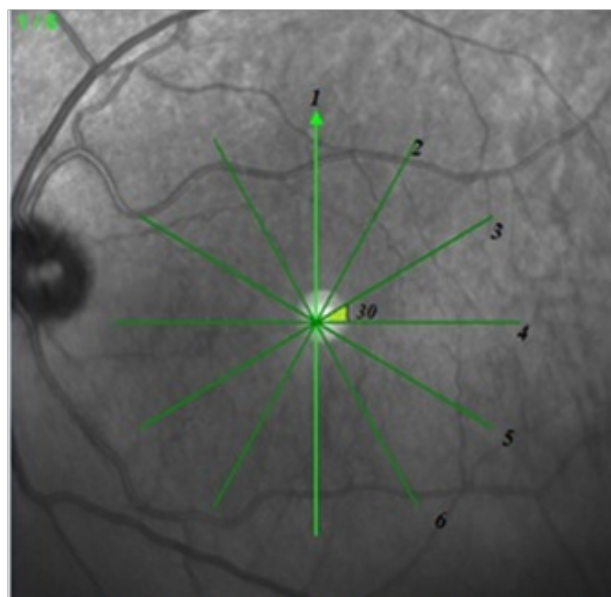


Figure 1 Optical coherence tomography Star, 6 sections, 30° .

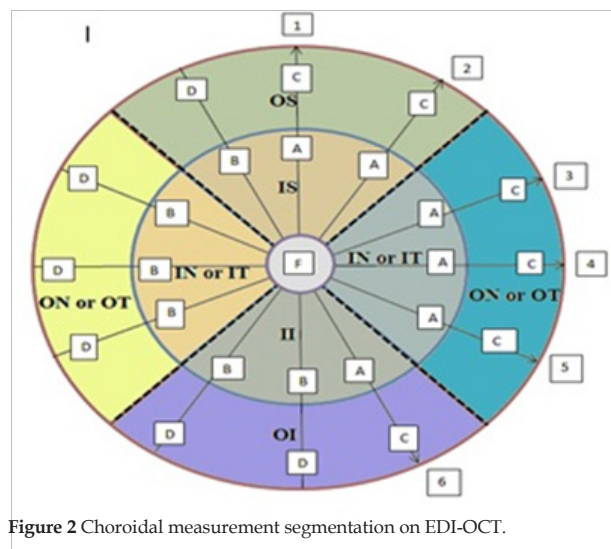


Figure 2 Choroidal measurement segmentation on EDI-OCT.

present and 24 eyes (48%) with DME absent. Group (B) included 50 eyes of 50 age-matched normal healthy controls that were subcategorized into: 20 females (40%) and 30 males (60%); 19 right eyes (38%) and 31 left eyes (62%).

Choroidal Thickness by EDI-OCT (Table 2)

The choroidal thickness was measured in 11 quadrants and regions. The subfoveal CCT was found to be $291 \pm 42 \mu\text{m}$ (range, 225-401 μm) in group (A) and $283 \pm 54 \mu\text{m}$ (range, 166-368 μm) in group (B). There was statistically non-significant difference in the CCT ($P > 0.05$) in all quadrants and regions studied except for the inner nasal (IN) quadrant that showed statistically significant increase in CCT ($P = 0.043$).

When correlating the CCT with the stage of DR in both groups it showed that (Table 3):

- (1) Statistically non-significant difference in CCT between no DR, NPDR and PDR compared to healthy controls ($P > 0.05$).
- (2) Statistically non-significant difference in CCT in group (A) with DME present, $F = 306 \pm 47 \mu\text{m}$ (280-401 μm), was found compared to group (B), $F = 284 \pm 54 \mu\text{m}$ (166-368 μm), in all quadrants and regions studied ($P > 0.05$) except for the nasal (Inner; IN and outer; ON) and outer temporal (OT) there were statistically significant increase ($P < 0.05$, IN = 0.04, ON = 0.26).
- (3) Statistically non-significant difference of CCT in group (A) with DME absent, $F = 277 \pm 29 \mu\text{m}$ (225-326 μm), was found compared to group (B), $F = 284 \pm 54 \mu\text{m}$ (166-368 μm), in all quadrants and regions studied ($P > 0.05$) except for the 3 mm radius fovea cen-

tered circle there was statistically significant decrease in DME absent group ($P = 0.04$).

When correlating the choroidal thickness in different regions of the studied groups in relation to gender it showed that (Table 4)

There was an overall non-significant increase in CCT in group (A) in relation to female gender in all quadrants measured compared to group (B) ($P > 0.05$), and there was an overall non-significant decrease in CCT in group (A) in relation to male gender in all quadrants measured compared to group (B) ($P > 0.05$) except for the nasal quadrants (IN, $P = 0.27$ & ON, $P = 0.54$) in diabetic males that were thicker, but also with no statistical significance.

When correlating the choroidal thickness in different regions of the studied groups in relation to laterality it showed that (Table 5)

There was statistically non-significant increase in CCT in group (A) in relation to right eye side studied as compared to group (B) ($P >$

Table 1 Studied groups' demography.			
	Group (A)	Group (B)	P-value
Age (Mean \pm SD)	42 \pm 7	39 \pm 9	0.16*
Gender			
Males	28(56%)	30(60%)	0.84+
Females	22(44%)	20(40%)	
Laterality			
Right	21(42%)	19(38%)	0.83+
Left	29(58%)	31(62%)	

Group (A) diabetics, Group (B) non diabetics, *T-test, + Chi square test.

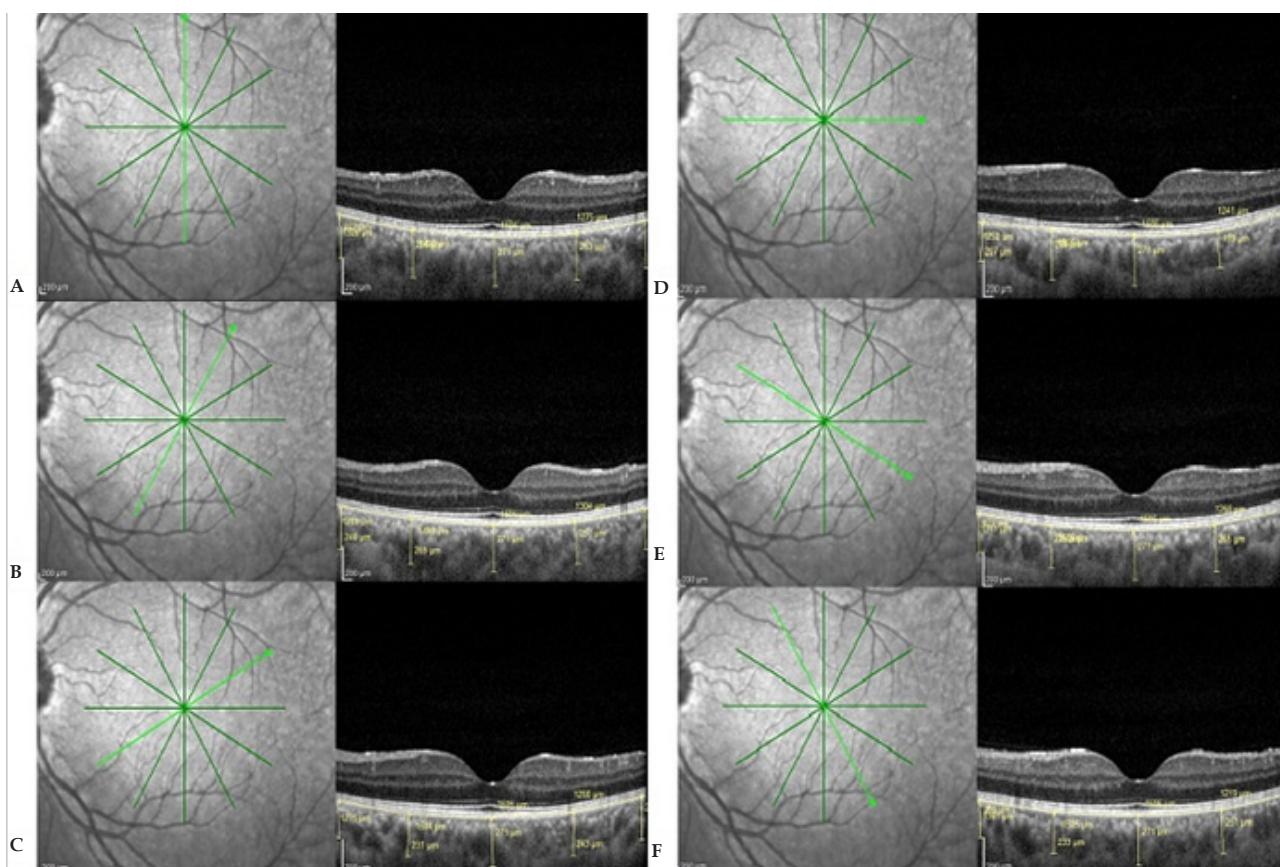


Figure 3 Representative scans for choroidal thickness (CCT) segmentation and measurement; case from group (B). A: Scan (1) from 6.00 to 12.00 O'clock, B: Scan (2) from 7.00 to 1.00 O'clock, C: Scan (2) from 8.00 to 2.00 O'clock, D: Scan (2) from 9.00 to 3.00 O'clock, E: Scan (2) from 10.00 to 4.00 O'clock and F: Scan (2) from 11.00 to 5.00 O'clock; manual segmentation was performed to measure CCT at 1500 μm intervals up to 3000 μm away from the fovea in each side of the 6 scans centered on the fovea.

0.05) except for the inner inferior (II, $P = 0.92$), the outer inferior (OI, $P = 0.78$), the outer nasal (ON, $P = 0.82$), the outer superior (OS, $P = 0.65$), the inner temporal (IT, $P = 0.98$) and the central 3mm ($P = 0.71$) quadrants that were thinner in diabetics, but also with no statistical significance, while there was an overall non-significant increase in CCT in group (A) in relation to left eye side studied as compared to group (B) ($P > 0.05$) except for the outer superior (OS) quadrant that was thinner in diabetics but also with no statistical significance ($P = 0.41$).

When arranging choroidal thickness in ascending order in different quadrants it showed that (Table 6)

Central choroidal thickness was noted to be thinnest nasally, increasing in thickness from the inferior to the temporal to the superior quadrants being thickest subfoveally, this pattern was observed in both groups; (A) and (B).

When correlating age and duration of DM with choroidal thickness in different regions it showed that (Table 7)

Statistically significant positive correlation in all regions and quadrants studied (increase in CCT with increase of diabetic duration) ($P \leq 0.05$).

On correlating the age of group (A) with CCT in different quadrants it showed statistically significant positive correlation (increase in CCT with increase of age) ($P \leq 0.05$) in all regions and quadrants studied except for the Outer Superior (OS) quadrant that showed statistically non-significant positive correlation ($P = 0.61$). On correlating the age of group (B) with CCT in different quadrants it showed statistically significant inverse correlation (decrease in CCT with increase of age) ($P \leq 0.05$) in all regions and quadrants.

Table 2 Mean choroidal thickness in different macular quadrants and regions of the studied groups.

Region	Group	Mean	Std. Deviation	P-value
F	B	283.58	54.08	0.39*
	A	291.92	41.93	
Av II	B	258.98	57.17	0.43*
	A	266.95	41.58	
Av IN	B	243.65	51.78	0.04*
	A	262.87	41.64	
Av OI	B	238.02	52.17	0.73*
	A	241.52	49.38	
Av OS	B	253.52	48.89	0.32*
	A	244.45	42.29	
Av IS	B	260.71	49.87	0.29*
	A	269.58	31.53	
Av OT	B	236.19	44.49	0.45*
	A	243.61	53.26	
Av IT	B	266.56	53.62	0.70*
	A	270.37	45.48	
Av ON	B	213.85	51.51	0.53*
	A	220.15	50.00	
Av 1.5mm	B	262.70	51.22	0.46*
	A	269.33	37.26	
Av 3mm	B	240.86	46.09	0.88*
	A	239.47	43.23	

F: SubFoveal, II: Inner Inferior, IN: Inner Nasal, OI: Outer Inferior, OS: Outer Superior, IS: Inner Superior, OT: Outer Temporal, IT: Inner Temporal, ON: Outer Nasal, 1.5 mm: 1.5 mm Fovea centered circle, 3mm: 3mm Fovea centered circle. *T-test.

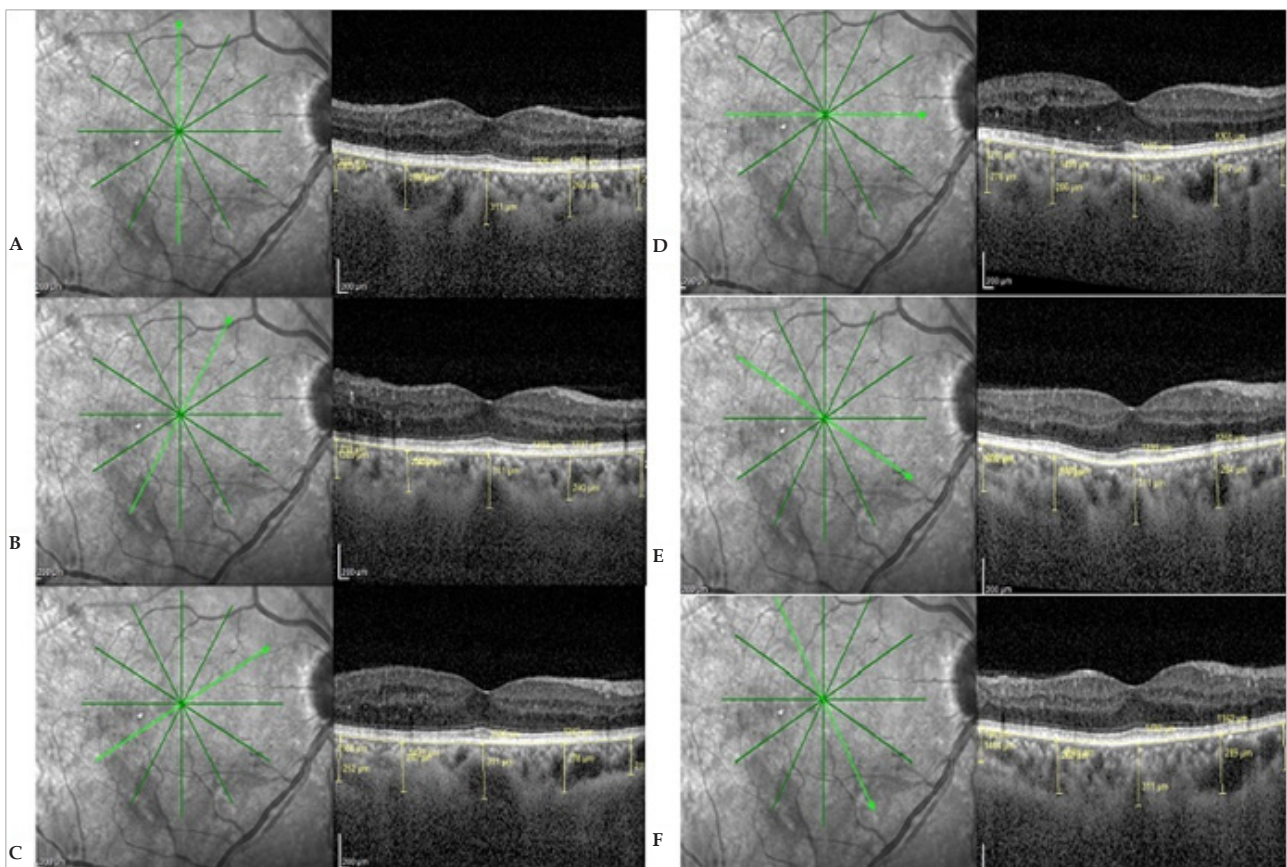


Figure 4 Representative scans for choroidal thickness (CCT) segmentation and measurement; case from group (A). A: Scan (1) from 6.00 to 12.00 O'clock, B: Scan (2) from 7.00 to 1.00 O'clock, C: Scan (2) from 8.00 to 2.00 O'clock, D: Scan (2) from 9.00 to 3.00 O'clock, E: Scan (2) from 10.00 to 4.00 O'clock and F: Scan (2) from 11.00 to 5.00 O'clock; manual segmentation was performed to measure CCT at 1500 μ m intervals up to 3000 μ m away from the fovea in each side of the 6 scans centered on the fovea.

Table 3 P-value regarding choroidal thickness in each stage of DR in group A compared to group B.

Region	P Value of group A versus B				
	NODR	NPDR	PDR	DME absent	DME present
F	0.56*	0.23*	0.28*	0.08*	0.57*
Av II	0.41*	0.21*	0.29*	0.06*	0.41*
Av IN	0.88*	0.02*	0.07*	0.004*	0.90*
Av OI	0.11*	0.37*	0.13*	0.06*	0.08*
Av OS	0.38*	0.31*	0.73*	0.97*	0.08*
Av IS	0.71*	0.45*	0.27*	0.18*	0.84*
Av OT	0.19*	0.28*	0.03*	0.02*	0.21*
Av IT	0.21*	0.31*	0.38*	0.12*	0.22*
Av ON	0.23*	0.18*	0.25*	0.03*	0.19*
Av 1.5mm	0.45*	0.27*	0.27*	0.08*	0.43*
Av 3mm	0.11*	0.72*	0.27*	0.14*	0.04*

NODR: no apparent retinopathy, N: healthy controls, F: SubFoveal, II: Inner Inferior, IN: Inner Nasal, OI: Outer Inferior, OS: Outer Superior, IS: Inner Superior, OT: Outer Temporal, IT: Inner Temporal, ON: Outer Nasal, 1.5 mm: 1.5 mm Fovea centered circle, 3 mm: 3 mm Fovea centered circle. *T-test.

Table 4 Correlating the choroidal thickness in different regions of the studied groups in relation to gender.

Region	Group	Female		Male	
		Mean	P-value	Mean	P-value
F	B	275.60	0.14*	288.90	0.78*
	A	300.05		285.54	
Av II	B	251.78	0.25*	263.78	1.00*
	A	271.00		263.77	
Av IN	B	237.16	0.08*	247.98	0.27*
	A	265.36		260.92	
Av OI	B	234.80	0.65*	240.18	1.00*
	A	243.33		240.11	
Av OS	B	242.63	0.82*	260.79	0.11*
	A	246.29		243.01	
Av IS	B	248.33	0.08*	268.97	0.81*
	A	273.45		266.54	
Av OT	B	227.13	0.21*	242.22	0.81*
	A	248.94		239.42	
Av IT	B	262.05	0.43*	269.57	0.71*
	A	276.61		265.46	
Av ON	B	214.95	0.80*	213.11	0.54*
	A	219.44		220.71	
Av 1.5mm	B	254.99	0.23*	267.84	0.85*
	A	273.79		265.82	
Av 3mm	B	234.90	0.70*	244.83	0.53*
	A	241.02		238.25	

F: SubFoveal, II: Inner Inferior, IN: Inner Nasal, OI: Outer Inferior, OS: Outer Superior, IS: Inner Superior, OT: Outer Temporal, IT: Inner Temporal, ON: Outer Nasal, 1.5 mm: 1.5 mm Fovea centered circle, 3 mm: 3 mm Fovea centered circle. *T-test.

DISCUSSION

Diabetic retinopathy is a well-documented sight threatening complication of DM due to the breakdown of retinal vasculature integrity and hemodynamic abnormalities, and despite the fact that DM affects the choroid, little is known clinically about diabetic choroidopathy, also a structurally and functionally normal choroid is essential for normal retinal functions, hence an abnormal choroidal blood volume and/or flow can result in photoreceptor dysfunction and death^[9].

Table 5 Correlating the choroidal thickness in different regions of the studied groups in relation to laterality.

Region	Right eye			Left eye		
	Group	Mean	P-value	Group	Mean	P-value
F	A	288.43	0.43*	A	294.45	0.60*
	B	277.26		B	287.45	
Av II	A	254.68	0.92*	A	275.84	0.27*
	B	256.16		B	260.71	
Av IN	A	264.49	0.22*	A	261.70	0.12*
	B	247.81		B	241.11	
Av OI	A	234.19	0.78*	A	246.84	0.56*
	B	237.72		B	238.22	
Av OS	A	239.41	0.65*	A	248.10	0.41*
	B	245.63		B	258.37	
Av IS	A	261.38	0.82*	A	275.51	0.23*
	B	258.46		B	262.10	
Av OT	A	241.76	0.70*	A	244.94	0.52*
	B	236.18		B	236.19	
Av IT	A	267.40	0.98*	A	272.52	0.60*
	B	267.89		B	265.74	
Av ON	A	228.56	0.82*	A	214.07	0.41*
	B	231.90		B	202.79	
Av 1.5mm	A	264.02	0.85*	A	273.17	0.43*
	B	261.52		B	263.42	
Av 3mm	A	237.72	0.71*	A	240.73	0.94*
	B	242.59		B	239.80	

F: SubFoveal, II: Inner Inferior, IN: Inner Nasal, OI: Outer Inferior, OS: Outer Superior, IS: Inner Superior, OT: Outer Temporal, IT: Inner Temporal, ON: Outer Nasal, 1.5 mm: 1.5 mm Fovea centered circle, 3 mm: 3 mm Fovea centered circle. *T-test.

Table 6 Choroidal thickness in ascending order in different quadrants.

Ascending Order	Group B (Healthy Controls)	Group A (Diabetics)
1	ON=214 ± 52	ON=220 ± 50
2	OT=236 ± 44	OI=242 ± 49
3	OI=238 ± 52	OS=244 ± 42
4	IN=244 ± 52	OT=244 ± 53
5	OS=254 ± 49	IN=263 ± 42
6	II=259 ± 57	II=267 ± 42
7	IS=261 ± 50	IS=270 ± 32
8	IT=267 ± 53	IT=270 ± 45
9	F=283 ± 54	F=291 ± 42

F: SubFoveal, II: Inner Inferior, IN: Inner Nasal, OI: Outer Inferior, OS: Outer Superior, IS: Inner Superior, OT: Outer Temporal, IT: Inner Temporal, ON: Outer Nasal, 1.5 mm: 1.5 mm Fovea centered circle, 3 mm: 3 mm Fovea centered circle.

Studies using indocyanine green angiography show filling delay or defects, microaneurysms, saccular dilatations in the choriocapillaris and choroidal neovascularization in diabetics^[10].

A limited number of non-invasive imaging techniques available for assessing the choroid, introduction of OCT allows further objective evaluation of DR. The EDI-OCT has provided the advantage of in vivo cross-sectional imaging of the choroid, similar to the retina^[11]. In this study, we reviewed this imaging technique to evaluate the choroidal thickness in diabetic eyes.

One hundred Automatic Real Time (ART) scans per section are often used for good image quality but William *et al*^[8] noted that CCT measurement with 10 A-scans per line in DME is comparable to the standard 100 scans per line, so 10ART frames was adopted in image

capture to reduce patient discomfort and test time.

This study results regarding the subfoveal CCT in healthy controls were similar to Margolis and Spaide^[12] (who used the same EDI-OCT technique) who reported a subfoveal CCT of $287 \pm 76 \mu\text{m}$ in healthy subjects and Copete *et al.*^[13] who reported a subfoveal CCT of $286 \pm 88 \mu\text{m}$ healthy subjects using Swept Source OCT.

In this study, the CCT was noted to be thinnest nasally, then increase in thickness in ascending order from the nasal to the inferior to the temporal to the superior quadrants in a circular manner also it was found to be thickest subfoveally in both groups. This pattern was also noted by previous studies^[10,13-16].

Our results were matched to Kim *et al.*^[10] who found a significant increase in the CCT as DR progressed in severity from moderate-severe NPDR to untreated PDR. The subfoveal choroid in DME-group eyes was significantly thicker than in non-DME eyes.

Similar to our findings, Xu *et al.*^[17] found that patients with DM had a slightly, but statistically significant thicker subfoveal choroids.

Rachel *et al.*^[18] suggested that there was an association between CCT and the progression of DR rather than DME and that the choroid responds to the retinal vascular disease. They found that in PDR, there was a statistically significant increase in CCT ($242.1 \mu\text{m}$) when compared to the mild NPDR group ($217.7 \mu\text{m}$) ($p = 0.03$). DME was associated with a statistically non-significant increase in CCT ($225.4 \mu\text{m}$) compared to eyes without DME ($209.3 \mu\text{m}$) ($p = 0.13$). This may reflect the higher incidence of more severe retinopathy in the eyes with DME that were matched to our results.

The choroidal thickening mechanism in advanced DR is unknown, Savage *et al.*^[19], using a computerized pneumotonometer, investigated pulsatile ocular blood flow as a reflection of choroidal circulation in eyes with DR; compared to healthy controls, choroidal blood flow was found to be increased in severe NPDR and PDR but decreased in treated DR. These findings might reflect an increased production of VEGF or other cytokines mediating choroidal vasodilation and elevation in choroidal blood flow, which subsequently increase the CCT, especially in patients with severe NPDR or PDR. The choroidal blood flow was found to be markedly decreased after laser PRP, possibly due to down regulation of VEGF, also the choroid was found to be significantly thinner after PRP due to decreased blood flow and subsequent ischemic atrophic change^[10].

Interestingly different to our results, Esmaelpour *et al.*^[20] studied the CCT in diabetics using high speed three-dimensional (3D) OCT imaging at 1060 nm. They found a central and inferior thinning in diabetic eyes compared to healthy eyes. Their study gave an overall idea about the effect of DM on CCT, but it used a different mean for choroidal image acquisition.

Different to this study, Querques *et al.*^[9] noted that in diabetic eyes, there was an overall thinning of the choroid on EDI-OCT. A further reduction of CCT was detected in the presence of DME. These data favor the idea that, in diabetic eyes, decreased CCT may lead to tissue hypoxia and consequently increase the level of VEGF resulting in the breakdown of the blood-retinal barrier and the development of macular edema. This contradiction can be explained by different patient profiles as their study included 63 eyes of diabetic patients with no healthy controls and the mean age was 65 ± 9 (48-83) years, elder participants were included unlike our study that may induce bias as the choroids get thinner with age as noted by previous studies^[12,21].

In contrast to our findings, Ünsal *et al.*^[7], using Optovue RTVue 100-2 (Optovue, Fremont, CA, USA), studied 191 eyes, 151 eyes of DM patients (61 NPDR, 90 PDR) and 40 eyes of 20 healthy individuals, they found no statistically significant difference in CCT between normal subjects and the NPDR group. In the PDR group,

Table 7: Correlation between Age and Duration of DM with choroidal thickness in different regions.

Region	Group (A) Age P value	Group (B) Age P value	DM Duration in Group (A) P value
F	0.00*	0.02*	0.00*
Av II	0.00*	0.02*	0.00*
Av IN	0.00*	0.02*	0.00*
Av OI	0.00*	0.00*	0.00*
Av OS	0.06*	0.00*	0.03*
Av IS	0.02*	0.00*	0.02*
Av OT	0.01*	0.04*	0.02*
Av IT	0.00*	0.01*	0.00*
Av ON	0.00*	0.01*	0.01*
Av 1.5mm	0.00*	0.01*	0.00*
Av 3mm	0.00*	0.00*	0.00*

F: SubFoveal, II: Inner Inferior, IN: Inner Nasal, OI: Outer Inferior, OS: Outer Superior, IS: Inner Superior, OT: Outer Temporal, IT: Inner Temporal, ON: Outer Nasal, 1.5 mm: 1.5 mm Fovea centered circle, 3 mm: 3 mm Fovea centered circle. * Pearson Correlation test.

there was statistically significantly decreased in CCT compared to both the healthy and the NPDR. They explained their results depending on previous histologic studies that revealed atrophy and dropout of the choriocapillaris in eyes with DR^[9]. Histologic analysis is an invasive technique with shrinkage of tissue on fixation that is not directly comparable to our EDI-OCT study. This contradiction can be also explained by different mean for image acquisition and different patient profiles as they studied unequal groups 191 eyes, comprising 151 eyes of DM patients and only 40 eyes of 20 healthy individuals, a limited number. Also in their study the PDR group was chosen from those only with a history of pan retinal photocoagulation (PRP) that were excluded from our study. Pan retinal photocoagulation was found to affect the CCT, Kim *et al.*^[10] noted that PRP caused choroidal thinning and atrophy explained, in part, by an intensive systemic control in this group as diabetic patients who had experienced any therapeutic measures, such as PRP, became more aware of the seriousness of the disease and more likely to maintain strict blood sugar control evidenced by low HA1C levels in this group that is conceivable, also the reduction of VEGF following PRP had a significant role in reducing the CCT.

Regatieri *et al.*^[14], using a Cirrus™ HD-OCT(Carl Zeiss Meditec Inc, Dublin, CA), compared CCT in NPDR, PDR, and DME patients with healthy subjects and reported a significant decrease of CCT in the PDR and DME groups, and a non-significant difference in the NPDR group. This contradiction may be due to different patient profiles as their study included unequal groups (49 eyes with diabetes and only 24 age-matched normal subjects) and the PDR group was chosen only from those with a history of PRP also they used a different mean for image acquisition.

In this study on correlating the age of healthy controls with CCT in different quadrants it showed statistically significant inverse correlation (decrease in CCT with increase of age). Differently, in diabetics it showed statistically significant positive correlation (increase in CCT with increase of age); this contradiction between both groups may be due to reported positive effect of DM on CCT.

Margolis and Spaide^[12] studied CCT in healthy subjects noted that the age had a statistically significant inverse correlation with CCT. They noticed that the subfoveal CCT decreased by $15.6 \mu\text{m}$ for each decade of life. Also Spaide^[21] had reported that CCT was decreased with age. With the randomized selection of the patients, we found the mean age was 42 ± 7 (26-50) years for diabetics and 39 ± 9 (25-50) years for healthy controls with no statistically significant difference (p

= 0.16), so the age factor was eliminated.

Our findings were matched to Regatier *et al.*^[14] who studied CCT in 100 eyes divided to two equal groups depended on gender. They found no statistically significant difference in subfoveal CCT according to gender difference.

Limitations of this study were that the low number of the PDR patients [$n = 6$ (12%)] and that some patients have poor fixation leading to problems acquiring good-quality scans, making the accurate measurement of CCT sometimes difficult. Some choroidal scans have a distinct hyporeflective line corresponding to the suprachoroidal space, but often this line can be indistinct, leading to measurement variability or error. The placement of the calipers can also vary depending on the magnification of the scan on the screen.

Correlation between CCT and severity of retinal ischemia by measuring the CCT with EDI-OCT to detect the need for laser treatment is a matter that needs further investigation and assessment through studying the role of anti-VEGF with appropriate number of PDR eyes by an accurate, precise and automated tool for CCT measurement using a well-accepted normative data for age and gender.

To be summarized we found insignificant increase of the choroidal thickness in diabetics compared to non diabetics that increase with deterioration of DR.

CONCLUSION

Choroidal thickness was found to be correlated with the stage of diabetic retinopathy (DR). Progressive thickening of the choroid with the progression of DR and/or the development of DME may reflect the concurrent progression of diabetic choroidopathy.

REFERENCES

- Ciulla TA, Harris A and Ltkany P. Ocular perfusion abnormalities in diabetes. *Acta Ophthalmol Scand.* 2002; 80: 468–477. [PMID: 12390156; <https://www.ncbi.nlm.nih.gov/pubmed/12390156>]
- Nagaoka T, Kitaya N and Sugawara R. Alteration of choroidal circulation in the foveal region in patients with type 2 diabetes. *Br J Ophthalmol.* 2004; 88:1060–1063. [doi:10.1136/bjo.2003.035345; <http://bjo.bmj.com/content/88/8/1060.full>]
- Stela Vujosevic, Ferdinando Martini, Fabiano Cavarzeran, Elisabetta Pilotto and Edoardo Midena. Macular and Peripheral Choroidal thickness in Diabetic Patients. *Retina. The Journal of Retinal and Vitreous Diseases.* 2012; 32:1781-1790. [<http://eyevinci.vhs2.attention.nl/wp-content/uploads/2014/05/Macular-And-Peripapillary-Choroidal-Thickness-in-Diabetic-Patients.pdf>]
- McLeod DS and Luttly GA. High-resolution histologic analysis of the human choroidal vasculature. *Invest Ophthalmol Vis Sci.* 1994; 35:3799–3811. [https://www.google.com.eg/url?sa=t&rc=j&q=&esrc=s&source=web&cd=1&cad=rja&uact=8&ved=0ahUK EwiE24eyy9PQAhXIVxoKHYwMB7gQFggZMAA&url=http%3A%2F%2Fiovs.arvojournals.org%2Fdata%2FJournals%2FIOVS%2F933401%2F3799.pdf&usq=AFQjCNEuZWRTgJlaKRLooxFGjNUgrlJfjg&sig2=hBOIY_2X3e00LYQNVE2hqA&bv=bv.139782543.d.d2s]
- Alm A. Ocular circulation. Hart WM, ed. *Adler's Physiology of the Eye.* 9th ed. St. Louis, MO: CV Mosby, 1992; 198–227. [<https://www.abebooks.com/book-search/title/adler-s-physiology-eye/>]
- Spaide RF, Koizumi H and Pozzoni MC. Enhanced depth imaging spectral-domain optical coherence tomography. *Am J Ophthalmol.* 2008; 146:496–500. PMID: 18639219, [DOI:10.1016/j.ajo.2008.05.032; <https://www.ncbi.nlm.nih.gov/pubmed/18639219>]
- Erkan Ünsal, Kadir Eltutar, Sibel Zirtilog˘lu, Nurhan Dinçer, Sezin Özdog˘ and Erkul, Hülya Güngel. Choroidal thickness in patients with diabetic retinopathy. *Clinical Ophthalmology* 2014;8:637–642. [doi: 10.2147/OPHT.S59395; <https://www.ncbi.nlm.nih.gov/pmc/articles/PMC3971934/>]
- William Best, Ryan Man, Jonathan Edward Noonan, Jing Xie, Sukhpal Singh Sandhu and Ecosse Luc Lamoureux. Choroidal Thickness Measurement with Varying Frame Number in Patients with Diabetic Macular Edema. *Invest Ophthalmol Vis Sci.* April 2014; 55:1750. [<http://iovs.arvojournals.org/article.aspx?articleid=2267020>]
- Giuseppe Querques, Rosangela Lattanzio, Lea Querques, Claudia Del Turco, Raimondo Forte, Luisa Pierro, Eric H. Souied and Francesco Bandello. Enhanced Depth Imaging Optical Coherence Tomography in Type 2 Diabetes. *Invest Ophthalmol Vis Sci.* September 2012; 53(10):6017-6024. [doi:10.1167/iovs.12-9692; <http://iovs.arvojournals.org/article.aspx?articleid=2127059>]
- Kim JT, Lee DH, Joe SG, Kim JG and Yoon YH. Changes in choroidal thickness in relation to the severity of retinopathy and macular edema in type 2 diabetic patients. *Invest Ophthalmol Vis Sci.* 2013; 54(5): 3378–3384. [doi:10.1167/iovs.12-11503]; [<http://iovs.arvojournals.org/article.aspx?articleid=2189369>]
- Jila Noori, Mohammad Razi Esfahani, Fedra Hajizadeh and Mohammad-Mehdi Zaferani. Choroidal mapping; a novel approach for evaluating choroidal thickness and volume. *J Ophthalmic Vis Res.* 2012 Apr; 7(2): 180–185. [PMCID: PMC3520468; <https://www.ncbi.nlm.nih.gov/pmc/articles/PMC3520468/>]
- Margolis R and Spaide RF. A pilot study of enhanced depth imaging optical coherence tomography of the choroid in normal eyes. *Am J Ophthalmol* 2009; 147(5):811-815. doi: 10.1016/j.ajo.2008.12.008. Epub 2009 Feb 20. [<https://www.ncbi.nlm.nih.gov/pubmed/19232559>]
- Sergio Copete, Ignacio Flores-Moreno, Javier A Montero, Jay S Duker, José M Ruiz-Moreno. Direct comparison of spectral-domain and swept-source OCT in the measurement of choroidal thickness in normal eyes. *Br J pOphthalmol* 2014; 98:334-338. doi:10.1136/bjophthalmol-2013-303904 [<http://bjo.bmj.com/content/98/3/334.com>]
- Regatieri CV, Branchini L, Carmody J, Fujimoto JG and Duker JS. Choroidal thickness in patients with diabetic retinopathy analyzed by spectral-domain optical coherence tomography. *Retina.* 2012; 32(3):563–568. [PMID:22374157, PMCID:PMC3393081, DOI:10.1097/IAE.0b013e31822f5678; <https://www.ncbi.nlm.nih.gov/pubmed/22374157>]
- Ikuno Y, Kawaguchi K, Nouchi T and Yasuno Y. Choroidal thickness in healthy Japanese subjects. *Invest Ophthalmol Vis Sci.* 2010; 51: 2173–2176. [doi:10.1167/iovs.09-4383]; <http://iovs.arvojournals.org/article.aspx?articleid=2186229>
- Manjunath V, Taha M, Fujimoto JG and Duker JS. Choroidal thickness in normal eyes measured using Cirrus HD optical coherence tomography. *Am J Ophthalmol.* 2010; 150(3):325–329. [PMID:20591395, PMCID:PMC2926223, DOI:10.1016/j.ajo.2010.04.018; <https://www.ncbi.nlm.nih.gov/pubmed/20591395>]
- Xu JI, Xu L, Du KF, Shao L, Chen CX, Zhou JQ, Wang YX, You QS, Jonas JB and Wei WB. Subfoveal choroidal thickness in diabetes and diabetic retinopathy. *Ophthalmology* 19 May 2013; 3:9. [PMID:23697958, DOI:10.1016/j.ophtha.2013.03.009]; <https://www.ncbi.nlm.nih.gov/pubmed/23697958>
- Rachel Sarah Varughese, Rebecca Rewbury, Andrew Want and Victor Chong. Foveal choroidal thickness in patients with diabetic retinopathy and diabetic macular edema. *Invest Ophthalmol Vis Sci.* April 2014; 55:4431. [<http://iovs.arvojournals.org/article.aspx?articleid=2269944>]
- Savage HI, Hendrix JW and Peterson DC. Differences in pulsatile ocular blood flow among three classifications of diabetic retinopathy. *Invest Ophthalmol Vis Sci.* 2004; 45: 4504–4509. doi:10.1167/iovs.04-0077 [<http://iovs.arvojournals.org/article.aspx?articleid=2163060>]

20. Esmaeelpour M, Povazay B and Hermann B. Mapping choroidal and retinal thickness variation in type 2 diabetes using three-dimensional 1060-nm optical coherence tomography. *Invest Ophthalmol Vis Sci.* 2011; 52:5311–5316. [doi:10.1167/iops.10-6875; <http://iops.arvojournals.org/article.aspx?articleid=2187581>]
21. Spaide RF. Age-related choroidal atrophy. *Am J Ophthalmol.* 2009; 147(5):801–810. PMID:19232561, DOI:10.1016/j.ajo.2008.12.010 [<https://www.ncbi.nlm.nih.gov/pubmed/19232561>]

Peer reviewer: Xavier Valldeperas