

## Macular Findings in Highly Myopic Eyes Using OCT and its Correlation to Refractive State, Axial Length and Visual Acuity

Sameh Mohamed Elgouhary, Abdel Rahman El Sebaey Sarhan, Asmaa Mohamad Ibrahim, Lobna Adel Gamal El Din Abd El Hi

Sameh Mohamed Elgouhary, Abdel Rahman El Sebaey Sarhan, Asmaa Mohamad Ibrahim, Department of Ophthalmology, Menoufia University, Egypt  
Lobna Adel Gamal El Din Abd El Hi, Berket El Saaba Ophthalmic Hospital, Menoufia, Egypt

**Conflict-of-interest statement:** The author(s) declare(s) that there is no conflict of interest regarding the publication of this paper.

**Open-Access:** This article is an open-access article which was selected by an in-house editor and fully peer-reviewed by external reviewers. It is distributed in accordance with the Creative Commons Attribution Non Commercial (CC BY-NC 4.0) license, which permits others to distribute, remix, adapt, build upon this work non-commercially, and license their derivative works on different terms, provided the original work is properly cited and the use is non-commercial. See: <http://creativecommons.org/licenses/by-nc/4.0/>

**Correspondence to:** Sameh Mohamed Elgouhary, Department of Ophthalmology, Menoufia University, Shebin Elkom, Egypt.  
Email: [sameh\\_elgouhary@yahoo.com](mailto:sameh_elgouhary@yahoo.com)  
Telephone: + 201005543214

Received: September 20, 2016  
Revised: November 23, 2016  
Accepted: November 29, 2016  
Published online: June 26, 2017

### ABSTRACT

**AIM:** To detect macular findings in subjects with high axial myopia using spectral domain optical coherence tomography (SD-OCT) and to correlate these findings with refractive state, axial length and visual acuity.

**METHODS:** Observational case study involved 100 eyes of 60 subjects with high axial myopia. Spectral domain-OCT was used to examine all eyes and scans were performed on vertical planes. The presence or absence of macular abnormalities was reported.

**RESULTS:** The findings in the studied 100 eyes were as follows: retinoschisis (6%), epiretinal membrane (6%), foveoschisis (2%),

choroidal neovascular membrane (4%), partial posterior vitreous detachment (4%), macular scar (4%), combined (31%) and normal appearance (43%).

**CONCLUSIONS:** This study concluded that the macula in highly myopic eyes may be normal without any pathologic findings in 43% of cases and it may have one or more pathologic findings in 57% of cases. There is no specific macular finding for a given refractive state or axial length. Macular scar and CNV are associated with the worst visual acuity.

**Key words:** High myopia; OCT; Axial length; Refraction; Visual acuity

© 2017 The Author(s). Published by ACT Publishing Group Ltd. All rights reserved.

Elgouhary SM, El Sebaey Sarhan AR, Ibrahim AM, El Din Abd El Hi LAG. Macular Findings in Highly Myopic Eyes Using OCT and its Correlation to Refractive State, Axial Length and Visual Acuity. *International Journal of Ophthalmic Research* 2017; **3(2)**: 226-230 Available from: URL: <http://www.ghrnet.org/index.php/ijor/article/view/1871>. [DOI: 10.17554/j.issn.2409-5680.2017.03.55]

### INTRODUCTION

Myopia is the most common eye disorder and the complications of high myopia are contributing factor to blindness<sup>[1,2]</sup>.

Although myopia can be easily managed with an appropriate optical correction, it is a risk factor for a number of retinal pathologies and one of the major causes of visual dysfunction, especially in patients with high myopia<sup>[3]</sup>.

Pathologic or high myopia is defined as a refractive error of  $-6.00$  diopters (D) or greater and an axial length exceeding 26 mm<sup>[4]</sup>.

Pathologic myopia is associated with progressive elongation of the globe, which may be accompanied by degenerative changes in the sclera, choroid, Bruch's membrane, retinal pigment epithelium (RPE), and neurosensory retina<sup>[5,6]</sup>.

These findings consist of dehiscence of retinal layers known as retinoschisis, paravascular inner retinal cleavage, cysts and lamellar holes, peripapillary intrachoroidal cavitation, tractional internal

limiting membrane detachment, macular holes (lamellar and full thickness), posterior retinal detachment, and choroidal neovascular membranes<sup>[7]</sup>.

The early stages of myopic retinal changes can easily be underestimated by biomicroscopy, angiography or ultrasonography, and therefore remain undiagnosed<sup>[7]</sup>.

Recently, OCT with its fine cross-sectional imagery of retinal structures has greatly facilitated the evaluation of posterior vitreoretinal anatomy in eyes with high myopia<sup>[7]</sup>.

It can also reveal otherwise undetectable retinal changes in asymptomatic patients. Therefore, it provides information not readily available by conventional imaging techniques or fundus examination<sup>[7]</sup>.

The aim of this study is to detect macular findings in subjects with high axial myopia using spectral domain optical coherence tomography and to correlate these findings with refractive state, axial length and visual acuity.

## PATIENTS AND METHODS

This was an observational case study included 100 eyes of 60 subjects with high axial myopia carried out at the Department of Ophthalmology, Menoufia University, Egypt between August 2015 and August 2016. This study was approved the clinical research committee of the Menoufia University Hospital and it followed the tenets of the Declaration of Helsinki.

### Inclusion criteria

Highly myopic patients with refractive error of -6.00 D or more and axial length exceeding 26 mm were included.

### Exclusion criteria

Opaque media, previous eye surgeries or laser therapy, diabetes, hypertension, retinal vascular diseases, retinal pathologies other than high myopia & history of previous ocular trauma were excluded.

All patients underwent complete ophthalmic examination including; visual acuity (uncorrected & best corrected visual acuity), intraocular pressure measurements using Goldmann applanation tonometer, slit Lamp biomicroscopy, dilated fundus examination by (+ 90 D fundus lens), estimation of the axial length by A-scan ultrasound biometry (Sonomed PacScan 300, Lake Success, NY, USA). The average of five measurements with a standard deviation  $\leq$  0.1 mm was taken as the axial length of the eye.

All patients underwent pupillary dilatation with tropicamide 1%. After pupillary dilatation, we performed multiple OCT scans across the macula. A (6 × 6 mm) area of the macular region centered on the fovea was examined using SD-OCT (Spectralis HRA + OCT; Heidelberg Engineering, Heidelberg, Germany) (Spectralis software version 4.0). Volume scans were centered on the fovea of 25 sections (each with a distance of 200  $\mu$ m). The eye tracking system of the device was used to ensure that the scanning had performed in the correct position. Horizontal scans were avoided to avoid bad scans at area of staphyloma. All scans were taken by one operator (A.I).

## RESULTS

This was an observational case study included 100 eyes of 60 subjects (35 females (58.33%) and 25 males (41.66%)). The mean age was 44.45  $\pm$  10.47 years (range, 20-69 years). All included patients had high myopia with refractive error ranged between -6.00 to -24.00 D (mean, -11.71  $\pm$  4.17 D). The mean axial length was 28.72  $\pm$  2.23 mm (range, 26.3 - 34 mm).

**Table 1** No & % of OCT findings with standard deviation (SD), mean & range of best corrected visual acuity (BCVA), refraction and axial length (AL).

Findings	NO	%	BCVA			Refraction			Axial Length		
			SD	Mean	Range	SD	Mean	Range	SD	Mean	Range
Retinoschisis	6	6.00	0.05	0.27	0.2 : 0.3	1.57	-9.25	-8 : -11.5	0.51	27.22	26.7 : 27.9
Foveoschisis	2	2.00	0.00	0.30	0.3	0.35	-11.25	-11 : -11.5	0.07	28.05	28 : 28.1
ERM	6	6.00	0.10	0.32	0.2 : 0.5	2.99	-11.42	-7.5 : -14.5	1.80	29.23	26.9 : 31
Partial PVD	4	4.00	0.14	0.30	0.2 : 0.5	2.61	-12.50	-10 : -15	1.57	29.25	27.8 : 30.8
CNV	4	4.00	0.12	0.90	0.8 : 1	1.19	-8.25	-7 : -9.5	0.13	27.05	26.9 : 27.2
Macular scar	4	4.00	0.10	0.95	0.8 : 1	0.65	-10.75	-10 : -11.5	0.48	27.50	27 : 28
Combined	31	31.00	0.28	0.72	0.2 : 1	4.19	-15.44	-9 : -24	2.34	30.85	27.1 : 34
Normal Appearance	43	43.00	0.15	0.11	0 : 0.6	4.53	-9.23	-6 : -18	1.28	27.57	26.3 : 32.8

ERM: epiretinal membrane; PVD: partial vitreous detachment; CNV: choroidal neovascularization.

**Table 2** Number of combined findings from total cases as standard deviation (SD), mean & range of best corrected visual acuity (BCVA), refraction and axial length (AL).

Findings	NO	BCVA			Refraction			Axial Length		
		Range	SD	Mean	Range	SD	Mean	Range	SD	Mean
ERM-Retinoschisis	8	0.3 : 0.6	0.12	0.44	-13 : -17.5	1.64	-15.38	27.9 : 32.7	1.75	30.13
ERM-Retinoschisis- lamellar macular hole	2	0.8	0.00	0.80	-14 : -15	0.71	-14.50	32 : 32.4	0.28	32.20
ERM-Retinoschisis-PVD	6	0.2 : 0.8	0.21	0.48	-9 : -24	6.85	-15.08	27.1 : 34	3.01	30.40
ERM-Retinoschisis-Fovioschisis-macular scar	2	1	0.00	1.00	-22 : -22.5	0.35	-22.25	33 : 33.2	0.14	33.10
ERM-Retinoschisis-CNV	4	1	0.00	1.00	-16 : -18.5	1.19	-17.25	32.8 : 33.2	0.17	32.98
ERM-PVD	1	-	-	-	-	-	-	-	-	-
Macular scar-CNV	3	1	0.00	1.00	-10.5 : -15	2.47	-12.17	-27.4 : -30.6	1.79	28.53
Retinoschisis-RD	2	0.6 : 1	0.28	0.80	-9 : -15	4.24	-12.00	27.5 : 30.4	2.05	28.95
ERM-Retinoschisis-CNV-Lamellar macular hole-Fovioschisis	2	1	0.00	1.00	-14.5 : -15.5	0.71	-15.00	32.9 : 33	0.07	32.95
ERM-Retinoschisis-CNV-Fovioschisis	1	-	-	-	-	-	-	-	-	-

ERM: epiretinal membrane; PVD: partial vitreous detachment; CNV: choroidal neovascularization.

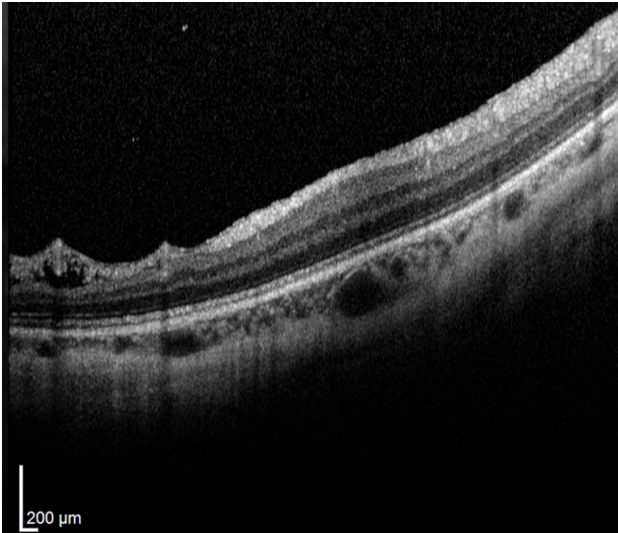


Figure 1 Retinoschisis in right eye of 49 years old patient.

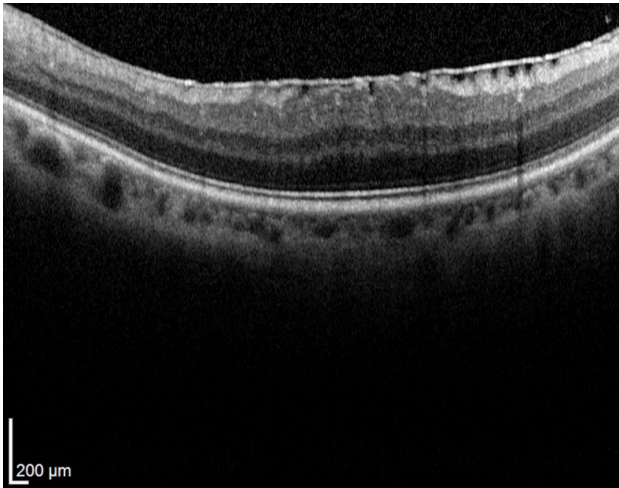


Figure 2 Epiretinal membrane in right eye of 60 years old patient.

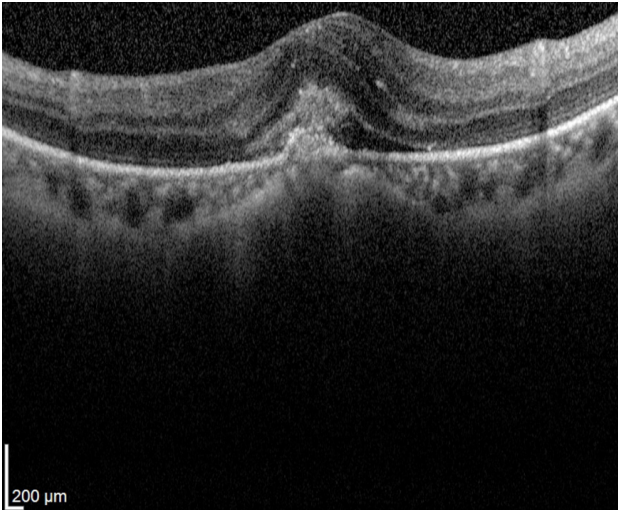


Figure 3 Choroidal neovascular membrane in right eye of 50 years old patient.

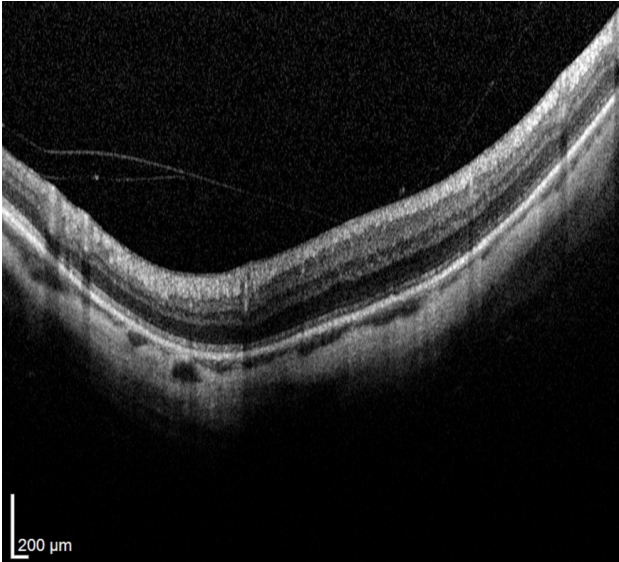


Figure 4 Partial posterior vitreous detachment in left eye of 69 years old patient.

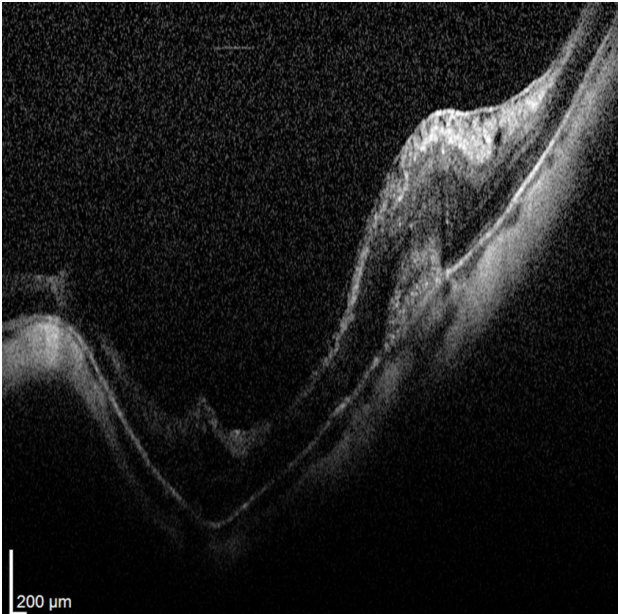


Figure 5 Foveoschisis in left eye of 50 years old patient combined with myopic choroidal neovascular membrane and epiretinal membrane.

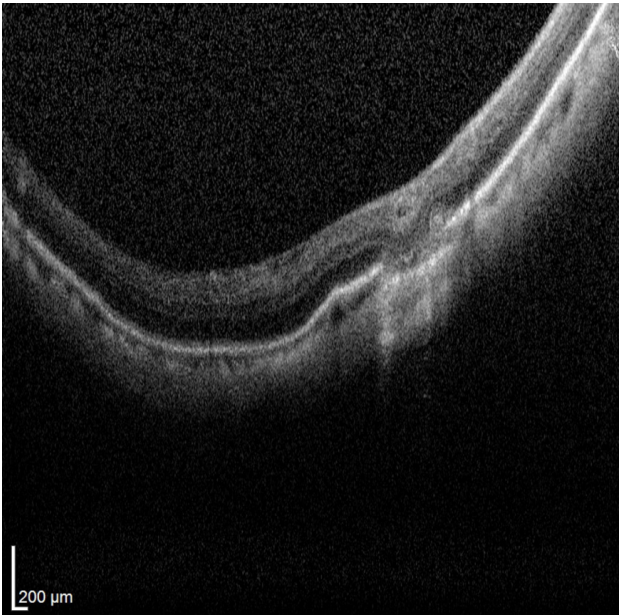
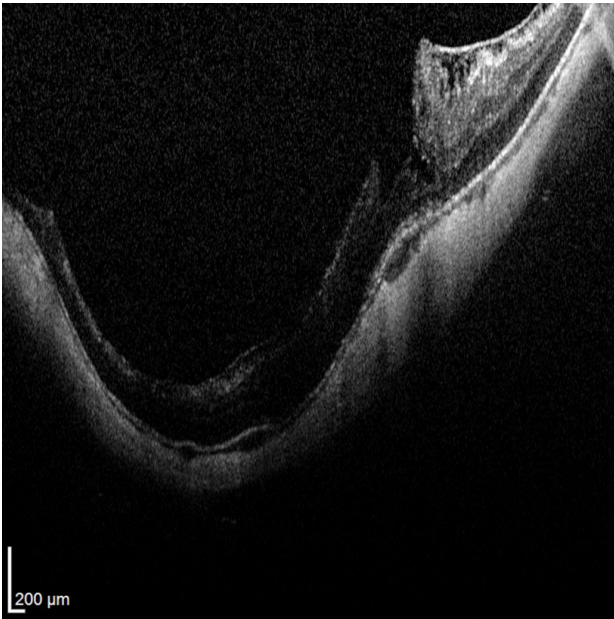
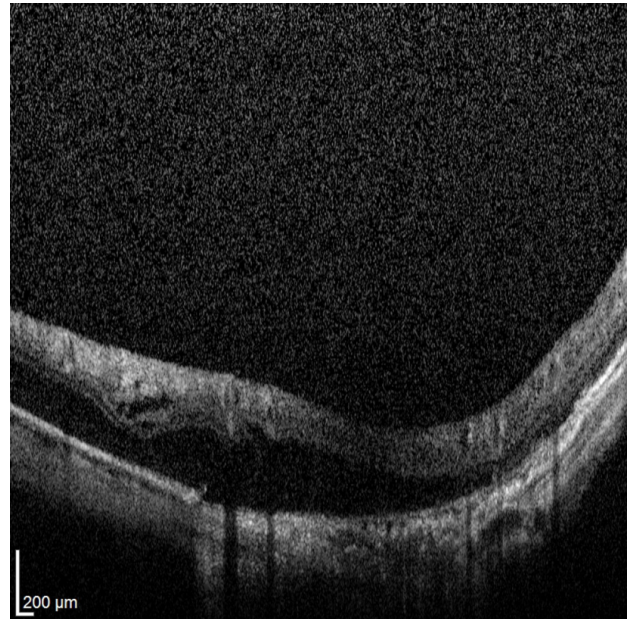


Figure 6 Macular scar in right eye of 48 years old patient.

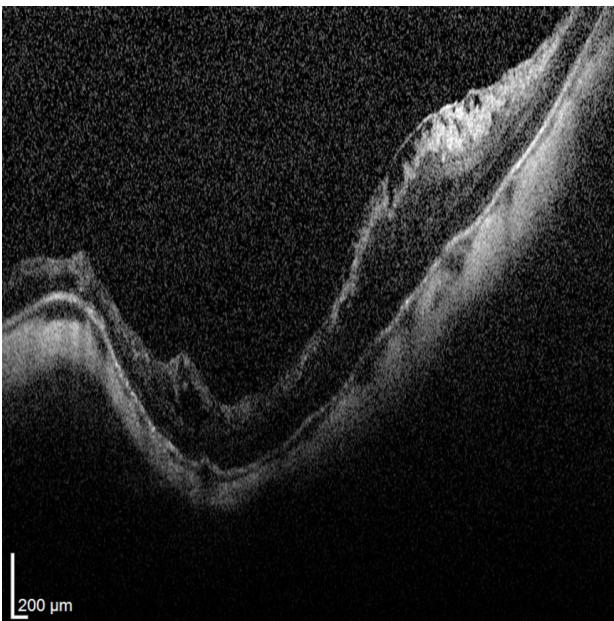




**Figure 7** Lamellar macular hole in left eye of 50 years old patient with retinoschisis and epiretinal membrane.



**Figure 8** Retinal detachment in right eye of 46 years old patient.



**Figure 9** Foveoschisis in left eye of 50 years old patient by SD-OCT combined with retinoschisis and epiretinal membrane.

The reported findings were as follows: myopic macular retinoschisis in 6 eyes (6%) (Figure 1), epiretinal membrane (ERM) in 6 eyes (6%) (Figure 2), myopic choroidal neovascularization (CNV) in 4 eyes (4%) (Figure 3), partial posterior vitreous detachment (PVD) in 4 eyes (4%) (Figure 4), foveoschisis in 2 eyes (2%) (Figure 5), myopic macular scars in 4 eyes (4%) (Figure 6), macular hole in 4 eyes (4%) (Figure 7), retinal detachment in 2 eyes (2%) (Figure 8), combined findings in 31 eyes (31%) (Figure 5, 7, 9) (Table 2) and normal appearance in 43 eyes (43%). Data was tabulated as number of findings and its percentage of total cases as (mean, range and standard deviation) of best corrected visual acuity (BCVA), spherical equivalent of refraction and axial length (AL) (Table 1).

## DISCUSSION

Myopia is characterized by elongation of the axial length (AL). The mechanism is unknown, but several studies have reported that the process of AL elongation is slow and stable, except at the onset of myopia, when the AL has the fastest rate of change<sup>[8]</sup>. Excessive AL elongation leads to various kinds of high-myopia-related complications, such as lacquer crack formation, choroidal neovascularization, and chorioretinal atrophy<sup>[6]</sup>. Some macular diseases, such as macular holes and foveoschisis accompany high myopia and require vitreoretinal surgeries<sup>[9,10]</sup>.

In this study, there was normal macular appearance in 43% of cases. These results were close to the work of Miyake *et al*<sup>[11]</sup> (who reported that 88 eyes out of 182 eyes (48.35%) had normal macular appearance) and the work of Lichtwitz *et al*<sup>[12]</sup> (who reported that 39 out of 87 eyes (44.8%) had normal macular appearance).

Retinoschisis was the most common abnormal macular finding in this study and this is also similar to the work of Miyake *et al*<sup>[11]</sup>.

Close to our results, Gomaa AR and Abouhoussein MA<sup>[13]</sup> (who used SD-OCT Heidelberg Spectralis, Heidelberg Engineering, Heidelberg, Germany and Cirrus HD-OCT Model 4000 - Carl Zeiss Meditec, Inc., Dublin, California, USA) reported a number of macular abnormalities as follows: Macular retinoschisis in 33 eyes, Posterior sensory retinal detachment in two eyes and myopic CNV in 15 eyes. This is close to our results and this may be attributed to the same study population group (Egyptian population).

Viola *et al*<sup>[14]</sup> (who used SD-OCT Heidelberg Spectralis, Heidelberg Engineering, Heidelberg, Germany) reported that foveal subretinal detachment was the most common macular abnormality found in 17 eyes (32.7%) followed by CNV in 13 eyes (25.0%) then extrafoveal schisis in 5 eyes (9.6%) and finally foveoschisis in 2 eyes (3.8%). The difference between our study and Viola *et al* study may be attributed to different population and less number of eyes in Viola *et al* work (52 eyes of 32 patients).

This study demonstrated that there is no specific macular finding for a given refractive state or axial length. Macular scar and CNV are associated with the worst visual acuity.

## REFERENCES

1. Lin HH, Xu L, Wang YX, Wang S, You QS, Jonas JB. Prevalence and progression of myopic retinopathy in Chinese adults: the Beijing Eye Study. *Ophthalmology* 2010; **117**(9): 1763-1768 [DOI: 10.1016/j.ophtha.2010.01.020]. Epub 2010 May 5.
2. Pan CW, Ramamurthy D, Saw SM. Worldwide prevalence and risk factors for myopia. *Ophthalmic Physiol Opt* 2012; **32**(1): 3-16 [DOI: 10.1111/j.1475-1313.2011.00884.x]
3. Song AP, Wu XY, Wang JR, Liu W, Sun Y, Yu T. Measurement of retinal thickness in macular region of high myopic eyes using spectral domain OCT. *Int J Ophthalmol*. 2014; **7**(1): 122-127. [DOI: 10.3980/j.issn.2222-3959.2014.01.23]. eCollection 2014.
4. Curtin BJ. Physiologic vs pathologic myopia: genetics vs environment. *Ophthalmology* 1979; **86**: 681-691. PMID: 397448 [PubMed]
5. Noble KG, Carr RE. Pathologic myopia. *Ophthalmology* 1982; **89**: 1099-100. [PMID: 7177575]
6. Curtin BJ, Karlin DB. Axial length measurements and fundus changes of the myopic eye. *Am. J. Ophthalmol* 1971; **1**: 42-53 [PMID: 5099937]
7. Faghihi H, Hajizadeh F& Riazi-Esfahani M. Optical coherence tomographic findings in highly myopic eyes. *J Ophthalmic Vis Res*. 2010; **5**(2): 110-21. [PMID: 22737340]; [PMCID: PMC3380683]
8. Mutti DO, Hayes JR, Mitchell GL, *et al.* Refractive error, axial length, and relative peripheral refractive error before and after the onset of myopia. *Invest Ophthalmol Vis Sci*. 2007; **48**: 2510-2519. [DOI: 10.1167/iovs.06-0562]
9. Siam A. Macular hole with central retinal detachment in high myopia with posterior staphyloma. *Br J Ophthalmol*. 1969; **53**: 62-63. [PMID: 5775575]; [PMCID: PMC1207098]
10. Takano M, Kishi S. Foveal retinoschisis and retinal detachment in severely myopic eyes with posterior staphyloma. *Am J Ophthalmol*. 1999; **128**: 472-476. [PMID: 10577588]
11. Miyake M, Yamashiro K, Akagi-Kurashige Y, Oishi A, Tsujikawa A, *et al.* (2014) Analysis of Fundus Shape in Highly Myopic Eyes by Using Curvature Maps Constructed from Optical Coherence Tomography. *PLoS ONE* 2014; **9**(9): e107923. [DOI: 10.1371/journal.pone.0107923].
12. VIOLA F, DELL'ARTI L, BENATTI E, *et al.* Choroidal Findings in Dome-Shaped Macula in Highly Myopic Eyes: A Longitudinal Study. *Am J Ophthalmol* 2015; **159**: 44-52. [DOI: 10.1016/j.ajo.2014.09.026] Epub 2014 Sep 22.
13. Gomaa AR, Abouhoussein MA. Optical coherence tomography findings in high myopia. *Egypt Retina J*2013; **1**: 13-7. [DOI: 10.4103/2347-5617.135241]
14. Lichtwitz O, *et al.* Prevalence of macular complications associated with high myopia by multimodal imaging. *J Fr Ophthalmol* 2016. [DOI: 10.1016/j.jfo.2015.11.005]. Epub 2016 Mar 22.

**Peer reviewer:** Muhammed Sahin