

## Non-Therapeutic Laser Retinal Injury

Patrick W. Commiskey<sup>1</sup>, MD; Curtis J. Heisel<sup>1</sup>, BS; Yannis M. Paulus<sup>1,2</sup>, MD, FACS

1 Department of Ophthalmology and Visual Sciences, University of Michigan, Ann Arbor, MI, the United State;

2 Department of Biomedical Engineering, University of Michigan, Ann Arbor, MI, the United State.

**Conflict-of-interest statement:** The author(s) declare(s) that there is no conflict of interest regarding the publication of this paper.

**Open-Access:** This article is an open-access article which was selected by an in-house editor and fully peer-reviewed by external reviewers. It is distributed in accordance with the Creative Commons Attribution Non Commercial (CC BY-NC 4.0) license, which permits others to distribute, remix, adapt, build upon this work non-commercially, and license their derivative works on different terms, provided the original work is properly cited and the use is non-commercial. See: <http://creativecommons.org/licenses/by-nc/4.0/>

**Correspondence to:** Yannis M. Paulus, MD, FACS, University of Michigan Kellogg Eye Center, 1000 Wall Street, Ann Arbor, MI 48105

**Email:** [ypaulus@med.umich.edu](mailto:ypaulus@med.umich.edu)

**Telephone:** +1-734-232-8105

**Fax:** +1-734-936-3815

**Received:** September 23, 2019

**Revised:** October 30, 2019

**Accepted:** November 2, 2019

**Published online:** November 26, 2019

### ABSTRACT

**BACKGROUND:** As lasers have become an increasingly important component of commercial, industrial, military, and medical applications, reported incidents of non-therapeutic laser eye injuries have increased. The retina is particularly vulnerable due to the focusing power and optical transparency of the eye. Continued innovations in laser technology will likely mean that lasers will play an increasingly important and ubiquitous role throughout the world. Critical evaluation should thus be paid to ensure that non-therapeutic injuries are minimized, recognized, and treated appropriately.

**METHODS:** A comprehensive literature review on the PubMed database was conducted to present case reports and case series

representative of the variety of laser eye injuries in different injury circumstances, tissue types, and biological damage mechanisms.

**RESULTS:** A general summary of non-therapeutic laser retina injuries is presented, including information about growth of the industry, increasingly accessible online markets, inconsistent international regulation, laser classifications, laser wavelengths, and laser power, mechanisms of tissue injury, and a demonstration of the variety of settings in which injury may occur. Finally, 68 cases found in the literature are summarized to illustrate the presentations and outcomes of these patients.

**CONCLUSIONS:** As non-therapeutic laser eye injuries increase in frequency, there is a greater need for public health, policy, diagnosis, and treatment of these types of injuries.

**Key words:** Laser; Injury; Retina; Photocoagulation

© 2019 The Author(s). Published by ACT Publishing Group Ltd. All rights reserved.

Commiskey PW, Heisel CJ, Paulus YM. Non-Therapeutic Laser Retinal Injury. *International Journal of Ophthalmic Research* 2019; 5(1): 321-335 Available from: URL: <http://www.ghrnet.org/index.php/ijor/article/view/2743>

### INTRODUCTION

Lasers are increasingly used for medical, industrial, commercial, military, research, and entertainment purposes, spurred by rapid technological development, decreasing size, and decreasing costs. The continued proliferation of laser use<sup>[1]</sup> and their relative ease of unregulated purchase have resulted in concern over the consequences of unintended or malicious laser eye injuries. As they have increased in popularity, so have the incidents of accidental laser use injuries<sup>[2]</sup>. Figure 1 demonstrates a handheld laser pointer that is commercially available online.

In 1997, the United States Food and Drug Administration (FDA) warned that lasers could be “more damaging than staring directly into the sun,” and imposed regulations on laser sales<sup>[3]</sup>. That same year, the British government banned Class III lasers due to retinal damage from direct exposure<sup>[4]</sup>. In 1998, the World Health Organization (WHO) warned of handheld laser pointers that are “too powerful for general use” that pose “an unacceptable risk in the hands of



Figure 1 A 5mW green laser pointer used to point astronomical objects. Photograph is courtesy of Creative Commons.

consumers.<sup>75</sup> In 1999, the *British Journal of Ophthalmology (BJO)* published a review of laser pointers and concluded that “laser pointers, pens or key rings if used appropriately are not an eye hazard, and even if used inappropriately will not cause permanent eye damage.” Up to that point, commercially-available laser pointers had caused only temporary or reversible injury unless used deliberately for harm or stared at for long durations of time<sup>6</sup>. In 2001, there was debate about whether U.S. domestic lasers were compliant with federal standards<sup>7</sup>.

Since then, the growth of the laser industry, proliferation of online marketplace, availability of unregulated overseas lasers, and lack of awareness about laser eye injuries have placed certain patient populations at risk<sup>8</sup>. A 2007 Pediatric Emergency Care literature review noted that nonindustrial laser eye injuries were uncommon; that transient exposure to Class II or Class IIIA does not result in injury, whereas direct, intentional, and prolonged exposure may.<sup>9</sup> A 2013 US study found that among commercially available laser pointers labeled as 1 mW to 5 mW, 90% of green pointers and 44% of red pointers had powers greater than 5 mW, and that harmful levels of additional infrared light were reported to emanate from green handheld lasers<sup>10</sup>. A 2016 review article in *Retina* concluded that “laser eye injury caused by laser pointers/handheld laser devices is possible; however, it can be avoided by proper training and teaching. It may be necessary to restrict sale of laser pointers by imposing a minimum age and educate parents about the inherent danger of laser pointers.” Its authors noted that even at Shiley Eye Institute at the University of California, San Diego (UCSD), 3 of 4 surveyed laser pointers used in lectures had power outputs greater than the standard “safe” level of 5 mW (range from 20 to 160 mW)<sup>11</sup>. A 2016 Spanish Society of Ophthalmology paper concluded that “a laser pointer is never a toy and therefore cannot be left within the reach of children.”<sup>12</sup> There is now general consensus in the ophthalmologic community that unregulated handheld laser pointers carry the potential to cause serious eye injury.

On the other hand, the well-controlled use of therapeutic lasers has contributed significantly to the field of ophthalmology. For example, femtosecond laser can be used to assist cataract surgery. The Diabetic Retinopathy Study (DRS) and the Early Treatment Diabetic Retinopathy Studies (ETDRS) demonstrated the benefit of panretinal and focal photocoagulation retinal laser photocoagulation in diabetic retinopathy. Laser has been the standard of care for diabetic retinopathy for decades<sup>13,14,15</sup>. Neodymium-doped yttrium aluminum garnet (Nd:YAG) laser hyaloidotomy can be used for rapid resolution of premacular subhyaloid hemorrhage<sup>16</sup>. Photodynamic therapy (PDT) utilizes injection of tissues with a contrast agent that is absorptive at specific frequencies, which when targeted initiates ablation of tissue<sup>17</sup>. Photocoagulation can also be used in numerous other conditions, including: retinal vein obstruction, proliferative diabetic retinopathy, retinal tears, and age-related macular degeneration, but can cause reduced night vision, scotoma, macular edema, thinning, and scarring<sup>18</sup>.

The growing use of lasers and increasing cases of non-therapeutic laser injury underscores the importance of understanding the scope and types of non-therapeutic laser eye injuries. This review will evaluate the means and mechanisms of injury in terms of the wavelengths at risk, current policies governing laser regulations, laser principles and specific tissue injuries, imaging modalities for identifying real from imagined laser eye injuries, and cases and types of injuries reported in the literature.

## RISK WAVELENGTHS

Wavelengths between 400 nm and 760 nm are recognized as visible light, whereas wavelengths outside of this range also reach the retina. The eye is designed to focus light on the retina, primarily by the tear film, cornea, and lens. The cornea only transmits photons greater than 295 nm. The lens absorbs almost all wavelengths near 400 nm, including some blue and ultraviolet (UV) light. The lens with age absorbs more UV-A. There are lens filters that block 99% of the UV spectrum from reaching retina<sup>19</sup>. The retina itself has evolved to capture photons efficiently and initiate visual transduction. Overall, the focusing power and anatomical function of the eye means that retinal tissue is particularly susceptible to laser-induced injury<sup>20</sup>.

Typically, handheld laser pointer energy is insufficient to cause injury at the ocular surface. However, greater than 100-fold amplification of irradiance by the ocular media and focusing power of the eye make the retina particularly susceptible to laser eye injury. Anterior segment injuries from handheld lasers are rare, while blink response (average aversion time 0.25 seconds), pupillary constriction and aversion to laser light brightness are usually protective. With greater than 5 mW lasers, the power may be too great for our natural defenses, resulting in severe, permanent damage with vision loss. Minor foveal injury and macular sparing are good prognostic signs for visual recovery<sup>21</sup>.

## LASER AND REGULATION

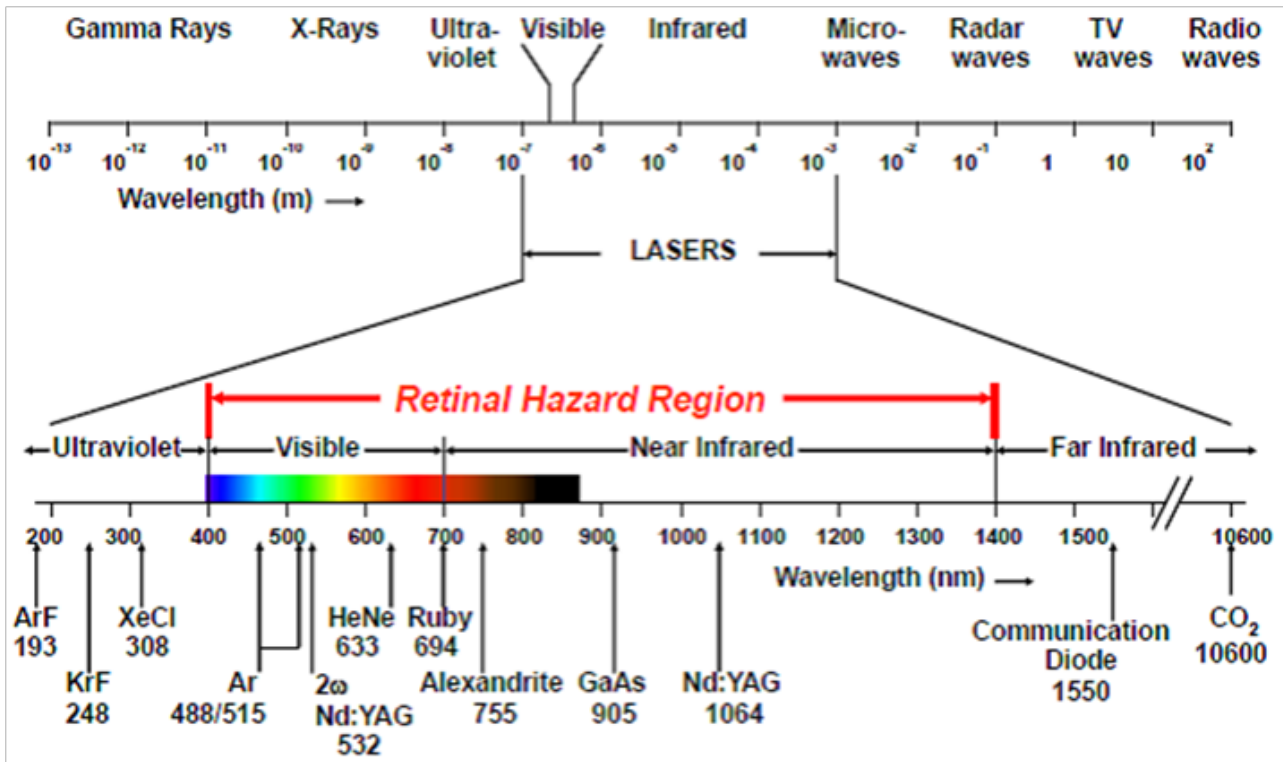
Laser stands for Light Amplification by Stimulated Emission of Radiation. It was first developed in 1960<sup>22</sup>. Lasers are monochromatic, coherent, and non-divergent<sup>23</sup>. A laser is composed of three basic elements: an active medium, a resonant cavity, and an excitation or pumping mechanism. Specific laser properties depend on the stimulated element, molecule, or compound (Figure 2). Examples of commonly used lasers in ophthalmology include: (1) Visible spectrum (400-700 nm): Argon (blue-green and green), Krypton (yellow and red), tunable dye, helium-neon, frequency-doubled Nd:YAG; (2) Infrared: Nd:YAG and carbon dioxide (CO<sub>2</sub>); (3) Ultraviolet (UV): Excimer.

The American National Standards Institute (ANSI)<sup>24</sup> establishes maximum permissible laser radiation exposure an unprotected person may receive without biological consequence as measured by tissue samples and imaging<sup>25,26,27,28,29,30</sup>. They classify lasers by output.

Class I (< 0.4 mW) are used in optical instruments for intrabeam viewing. They do not cause damage even with long-duration retinal exposure.

Class II (< 1 mW) and Class IIIA (1-5 mW) cause retinal damage if viewed greater than 10 s at close range. These lasers rely on our natural aversion to bright lights, which is impaired for instance by altered mentation, malice, or curiosity. Class IIIA was initially thought to be innocuous unless viewed greater than 10s, but some studies in to-be-enucleated eyes have demonstrated histopathologic changes<sup>31</sup>.

Class IIIB and IIIR (5-500 mW) are hazardous and prohibited in



**Figure 2** Representation of a variety of handheld, commercial, and medical laser wavelengths<sup>1, 1</sup>Paulausky, C. Laser Safety: The Eyes Have It! Occupational Health & Safety. August 2, 2014. [https://ohsonline.com/Articles/2014/08/01/Laser-Safety\\_0.aspx](https://ohsonline.com/Articles/2014/08/01/Laser-Safety_0.aspx).

many countries but are readily available online<sup>[32]</sup>.

Class IV (greater than 500 mW) have military applications and can produce extensive ocular damage.

United States laser sales are regulated by the Food and Drug Administration Code of Federal Regulations, which requires compliance for Class I, II, IIA and IIIA devices. Many countries and international Internet sales are unregulated or unenforced<sup>[33]</sup>. For instance, a quick Internet search yields a 6 W laser available for purchase that exceeds the ANSI safety limits by greater than 20,000 times and requires only 10 milliseconds to cause damage, far faster than the blink reflex. In Europe, EN 60825/207/208 provides regulation for safe laser use and necessary protective equipment by limiting exposure respect to energy per unit of beam area with no allowance for diffuse viewing conditions. The American standard, ANSI, which has been adopted by many Asian countries, specifies protective eyewear requirements in terms of optical density (OD) and allows for a nominal hazard zone to be determined by a laser safety officer outside of which diffuse viewing eyewear is allowed. Whereas optical density requirements allow for a diffuse viewing condition, a code that regulates permissible energy density will more specifically protect against direct beam exposures and protects against diffuse exposure that rises above threshold energy limits.

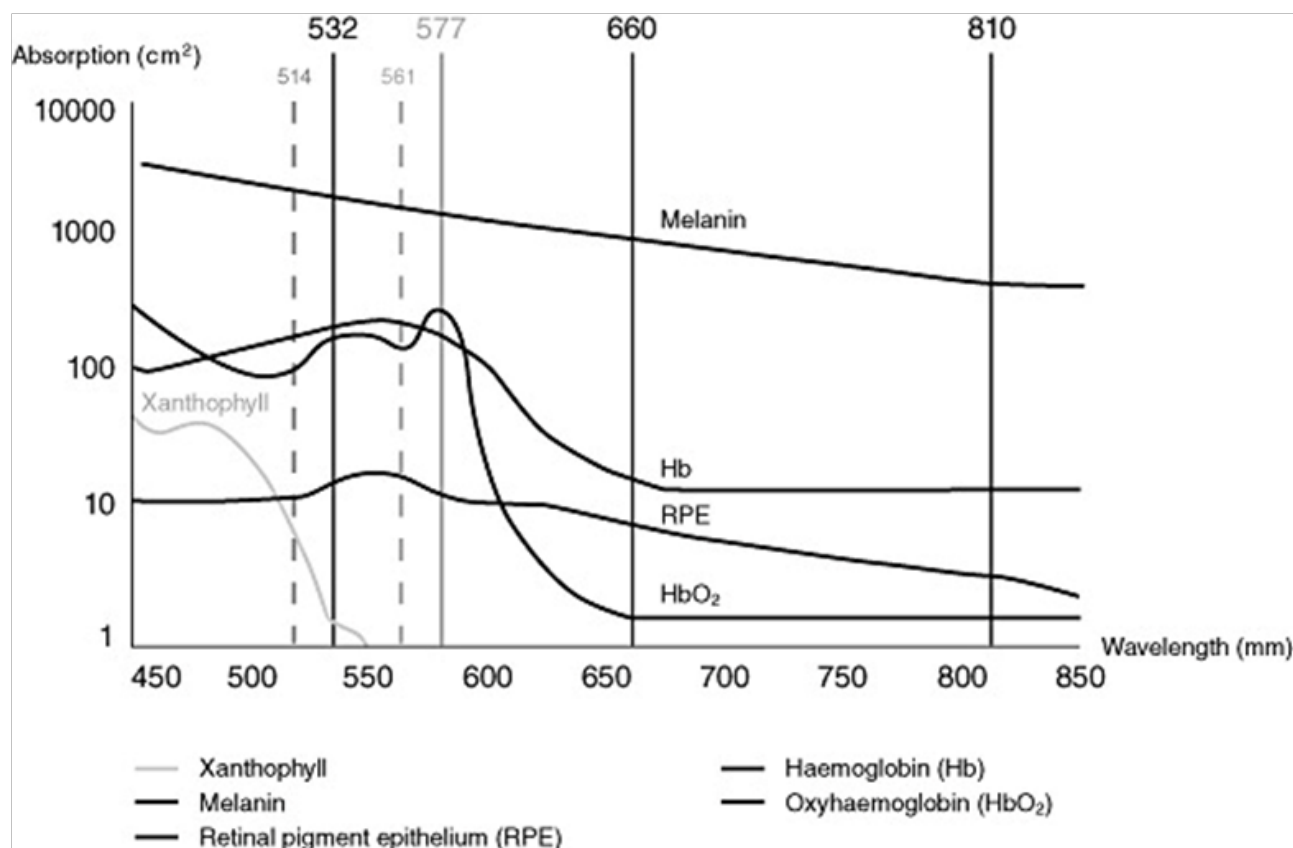
The United Nations 1980 Convention on Certain Conventional Weapons (CCW) Protocol IV, "Protocol on Blinding Laser Weapons," came into force on October 13, 1995, and is the first international agreement regulating the use of lasers as weapons during combat<sup>[161]</sup>. It specifically prohibits the use of blinding laser weapons in warfare that are designed to cause permanent blindness and requires precaution to prevent blindness when non-combat laser systems are employed in combat. The agreement was the first time since the banning of explosive bullets in 1868 that the international community as pre-emptively banned a destructive technology from warfare prior to its widespread implementation on the battlefield<sup>[162]</sup>.

Prior to the ban, however, laser weapons had already been developed that specifically target the eye. For instance, the U.S. developed a shoulder-mounted laser rifle with a beam diameter of 1 m and blinding range of 1 km. China had a similar, tripod-based weapon with a purported blinding range of 2 km to 3 km and the capability to sustain two simultaneous wavelengths at 15 mW for 5 minutes<sup>[159]</sup>. As of January 28, 2018, 108 nations have agreed to the treaty<sup>[160]</sup>.

The U.N. agreement does not limit blinding as an incidental effect of non-intentionally blinding laser systems. The ban also does not remove potentially blinding equipment such as range finders and target illuminators from combat, despite their potential for use as intentionally blinding weapons. This issue was well-framed by British ophthalmologist John Marshall in BMJ in 1997, noting that a wide variety of not-specifically-weapon lasers were still being used as weapons on the battlefield<sup>[163]</sup>. Incidental injuries have also been a problem unaddressed by the agreement, as blinding lasers are still used for a variety of battlefield purposes that include range-finding, target designation, antisensors, and antimaterial systems designed to disable equipment but could be used on humans as well, in violation of the UN agreement<sup>[164-168]</sup>. Currently, there are also laser systems developed for the battlefield that intend to create a temporary glare effect in enemy soldiers, and it is likely that these anti-personnel weapons will continue to be developed<sup>[169]</sup>.

## LASER-TISSUE INTERACTIONS

As light energy reaches the retina, its deposition, penetration and/or absorption depends on wavelength, duration of exposure, and composition of retinal tissues. When energy deposition is too low or dispersion is too high, oxidative photochemical damage occurs via absorption of photons. If deposition is greater than thermal dispersion, and resulting tissue temperature increase is greater or equal to 10°C, photothermal damage occurs. Nonlinear damage can



**Figure 3** Absorption spectrum of several important ocular pigments<sup>1, 1</sup> Lock JH-J, Fong KCS. An update on retinal laser therapy. *Clinical and Experimental Optometry*. 2010;94(1):43-51.

occur via shear stress and cavitation if energy deposition is faster than tissue relaxation. Ultra-short high energy lasers can create very precise locally extreme heat to 10,000°C, causing photodisruptive damage<sup>[34]</sup>. Tissue response to absorbed energy can include photocoagulative, photothermal, and photodynamic injury<sup>[35]</sup>. Injury types are dependent upon power density, total exposure duration, and wavelength of irradiating energy, which are effected by wavelength-dependent properties of the anterior segment and vitreous<sup>[36]</sup>.

Laser light localized to the retina is the most important determining factor for injury. Retinal injury from lasers range from subclinical to full-thickness macular holes with impaired choroidal perfusion<sup>[37]</sup>. Visual loss is greater at the fovea; peripheral injury is less symptomatic. Risk factors that increase injury include large pupil size due to increased transmission, and increased retinal and choroidal pigmentation due to the broad absorption spectrum of photon energy by melanin in the retinal pigment epithelium (RPE)<sup>[38]</sup>.

Injury may occur at different retinal layers based upon duration, wavelength, and power of laser. For instance, green light undergoes less angular spreading than red light, making it more harmful. Green laser light (532 nm) may be additionally harmful due to its wavelength near the peak-sensitivity of dark-adapted eyes<sup>[39]</sup>. Utilizing blue light for macular photocoagulation can result in damage to the inner neurosensory retina.

Tissue composition is also important in determining absorbance and resultant injury within specific layers of the retina<sup>[40]</sup>. (Figure 3) Xanthophyll pigment is concentrated in the macula and has susceptibility to blue light damage due to its peak absorbance. Xanthophyll is abundant in the retinal nerve fiber layer (RNFL), inner plexiform layer (IPL), and outer plexiform layer (OPL), leaving these tissues and the inner retina particularly susceptible<sup>[41]</sup>. Hemoglobin absorbs mostly blue, green and yellow wavelengths. Melanin absorbs

broadly across the visual spectrum. Laser-induced injury pathology has been studied on eyes scheduled for enucleation<sup>[42,43]</sup>, and with animal models<sup>[44,45,46]</sup>.

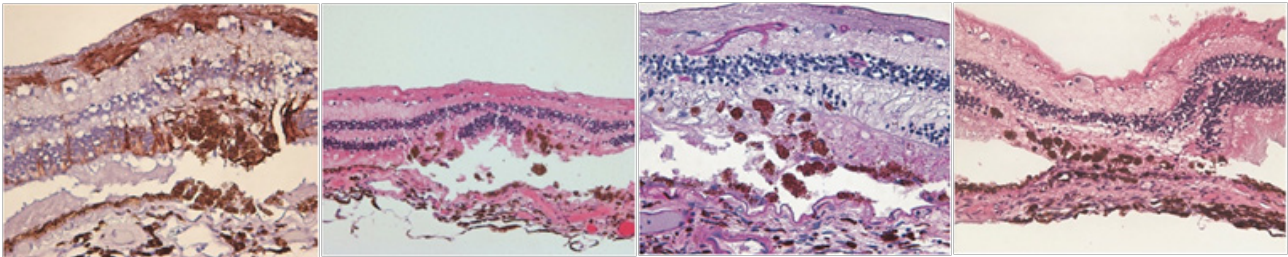
Advanced imaging technology now allows for recognition and study of previously-undetectable light-induced retinal injury and their relationship to wavelength, power, and duration<sup>[47]</sup>. Morgan *et al.* in 2008 demonstrated via adaptive optics scanning laser ophthalmoscope (AOSLO) retinal pigment epithelium (RPE) autofluorescence changes induced by 568-nm light exposure at a power level at or near current laser safety standards<sup>[48]</sup>. Since then, optical coherence tomography (OCT), fluorescein angiography (FA), adaptive optics (AO), and other technologies have emerged that are detecting previously-underappreciated or undetected damage<sup>[49,50]</sup>. This includes sub-RPE choriocapillaris damage<sup>[51]</sup> in subtle<sup>[52]</sup>, early<sup>[53]</sup>, and chronic solar retinopathy<sup>[54,55,56,57]</sup>.

A 2014 paper from Pocock *et al.* in the *Journal of Ophthalmology* evaluated in vivo imaging of photothermal, photochemical, and photomechanical retinal laser injury in cynomolgus monkeys. They identified unique characteristics for each type of tissue injury, and noted that high resolution images are better at detecting laser eye lesions<sup>[58]</sup>.

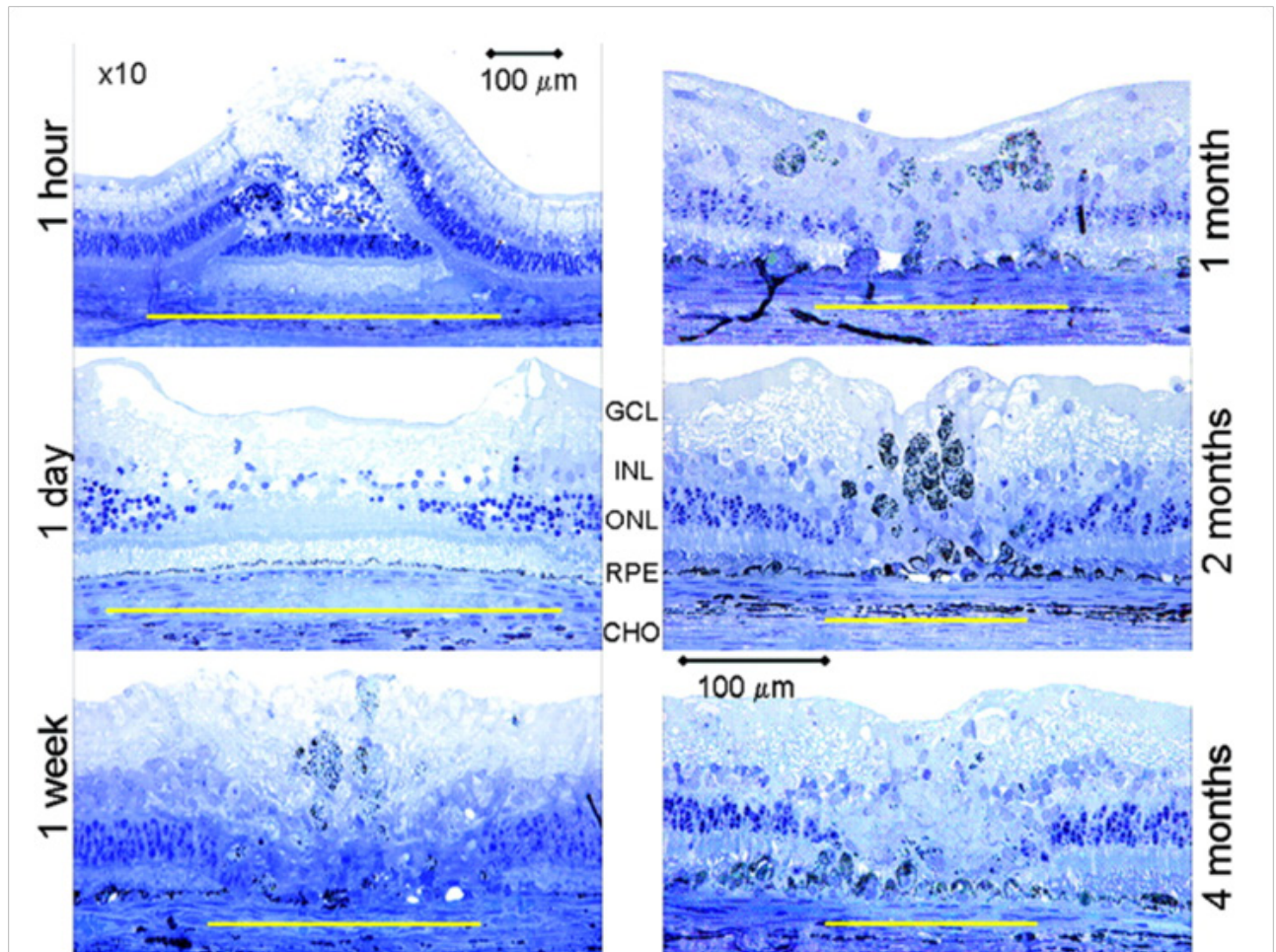
#### Photocoagulation

Argon and krypton wavelengths are primarily absorbed by hemoglobin and melanin, which then increase in temperature resulting in protein denaturation and tissue breakdown. Therapeutic applications of photocoagulative tissue injury include treatment of proliferative diabetic retinopathy, retinal vein occlusion, retinal capillary hemangioma, and choroidal tumors<sup>[59]</sup>.

Photocoagulative therapy is typically performed with continuous 514-532 nm green, 577 nm yellow, or 647 nm red laser with 100-



**Figure 4** Histology of photocoagulation from semi-automated pattern scanning retinal photocoagulation (PASCAL)<sup>†</sup>. <sup>†</sup> Paulus YM, Kaur K, Egbert PR, Blumenkranz MS, Moshfeghi DM. Human histopathology of PASCAL laser burns. *Eye*. 2013 Aug 31;27(8):995–6.



**Figure 5** Paulus *et al.* illustrate rabbit histology of healing retina after 532 nm Nd:YAG photocoagulation laser injury demonstrating a permanent chorioretinal scar in moderate burns<sup>†</sup>. <sup>†</sup> Paulus YM, Jain A, Gariano RF, *et al.* Healing of retinal photocoagulation lesions. *Invest Ophthalmol Vis Sci*. 2008; 49(12):5540–5545.

200 millisecond (ms) pulses, 100-500 micrometer spot size, and 100-750 milliwatt (mW) power. Panretinal photocoagulation has been proven to be effective at halting angiogenesis, but it can cause scarring and decreased peripheral, color, and night vision. Focal and grid laser photocoagulation are effective for treatment of macular edema, but can cause scotoma and scarring. Damage surrounding the treatment area can adversely affect patients. Complications include retinal atrophy, thinning, scotomas, post-laser lesion enlargement, choroidal neovascularization, subretinal fibrosis, and visual field loss<sup>[60]</sup>. Attempts to limit side-effects include adjusting pulse duration, spacing, intensity, and axial localization<sup>[61,62]</sup>.

Modulating wavelength may also minimize certain side-effects. For example, yellow (577 nm) laser for photocoagulation may reduce the risk of Bruch’s membrane rupture as compared to 532 nm green

laser<sup>[63]</sup>.

There is a growing research basis for understanding retinal tissue recovery following certain patterns of laser injury. Following inner-retinal-neuron-sparing selective laser photocoagulation, rabbit retinal neurons exhibit plasticity by changing connectivity to restore anatomy and function<sup>[64]</sup>. The continuity of the photoreceptor layer can also be restored in rabbit and rodent models following selective photocoagulation. RPE coverage restoration takes places within days, followed by the photoreceptor layer weeks to months later<sup>[65,66]</sup>. Photoreceptors filling a lesion likely migrate from adjacent healthy areas<sup>[67,68]</sup>. c-Met facilitates RPE migratory response in response to laser-induced retinal injury<sup>[69]</sup>. (Figures 4 and 5) demonstrate histologic characteristics of semi-automated pattern scanning retinal photocoagulation and Nd:YAG photocoagulation respectively.

### Photothermal

Photothermal damage occurs by transfer of photon energy from light to retinal molecules, provided that the difference between the molecule's energy states is equal to that of the photon. Photothermal damage tends to occur at longer (red-shifted) wavelengths and shorter pulses, and tends to be irreversible when ambient temperature of the retina increases by 10°C. Cells may undergo apoptosis with varying degrees of necrosis up to 68°C, and immediate cell death above 72°C<sup>[70]</sup>. Photothermal absorption occurs especially within melanin (RPE melanosomes and choroid melanocytes), xanthophyll (Müller cells and neurosensory retina), and hemoglobin (retinal and choroidal blood vessels)<sup>[71]</sup>. Photothermal tissue injury is utilized therapeutically in transpupillary thermotherapy (TTT) procedures, which were introduced in 1995<sup>[72]</sup>. TTT has been applied for treatment of choroidal tumors<sup>[73]</sup>, retinoblastoma, choroidal neovascularization<sup>[74]</sup>, and age-related macular degeneration<sup>[75]</sup>.

### Photochemical

Photochemical injury is independent of the energy transfer required for photothermal and photocoagulation. It occurs by generating free radicals from light incident on retinal tissue. It predominates at long exposures of short wavelength (i.e. blue light over time)<sup>[76]</sup>. Energy requirements for photochemical damage have also been described on a continuum with requirements for photothermal damage<sup>[77]</sup>.

Photochemical injury occurs primarily in the outer layers of the central retina principally by short-wavelength exposures. It is by this mechanism that solar retinitis, iatrogenic ophthalmic instrument injury, and blue light-induced age-related macular degeneration (ARMD) are likely to occur. Cell death is via apoptosis. Injury by photochemical injury is classified as follows. Class I damage is via rhodopsin action spectrum mediated by visual pigments with primary lesions in photoreceptors. Action spectrum is heightened with higher frequency, which explains why blue lights are particularly harmful. Class II damage occurs at the RPE<sup>[78]</sup>.

Blue and UV light are more onerous at lower powers because their short wavelength induces greater action spectrum within photoreceptors<sup>[79]</sup>. Michael and Wegener estimated safe exposure times to avoid photochemical injury for different light sources based on American Conference for Governmental and Industrial Hygienists data on the Zeiss operation microscope OPMI VISU 200<sup>[80]</sup>.

In an Agouti rat model, blue light (405nm, 3.2mW/cm<sup>2</sup>) damage applied over 2 hours resulted in photoreceptor apoptotic death, and cellular damage in the outer retina<sup>[81]</sup>. In an early study, low power blue light (441 nm) sustained for 16.7 minutes resulted in nonthermal, photochemical damage to RPE with histological response and hypopigmentation after 48 hours<sup>[82]</sup>. RPE expresses L-type calcium channel  $\alpha 1D$  subunit, vascular endothelial growth factor (VEGF) and basic fibroblast growth factor (bFGF) in response to blue light in vitro<sup>[83]</sup>.

Photoswitches are photochemical pharmaceutical agents modified with an azobenzene derivative which switches between *cis* and *trans* conformations. They have been proposed as potential approaches for vision restoration in retinal degeneration<sup>[84]</sup>. Research is ongoing to develop retinal neurosensory-sparing lasers that modulate RPE transgene expression<sup>[85]</sup>.

### Photodisruption

Photodisruption results from tissue ionization. Short bursts of high power laser pulses create acoustic shock wave and plasma, which disrupts tissue. Despite being referred to as "cold laser," photodisruptive lasers actually create a microenvironment greater

than 10,000°C. They were first used clinically in 1972 for glaucoma. They are now used in minimally invasive surgery i.e. Nd:YAG laser<sup>[86]</sup>. Near-infrared 1030-1064 nm femtosecond lasers that utilize photodisruptive tissue injury are used therapeutically in femtosecond-assisted cataract surgery to add precision and reproducibility. Energy transmitted to the retina and choroid may damage these tissues due to wavelength-absorbing melanosomes in the RPE and pigmented choroid that can cause damage via microbubble formation, shock-wave damage, and cumulative thermal damage<sup>[87]</sup>.

## DISTINGUISHING TRUE FROM FALSE CASES OF LASER EYE INJURY

Interestingly, complaints of accidental laser eye injuries are for more numerous than confirmed instances of retinal injury, with less severe cases more being difficult to diagnose. Symptoms of laser-induced ocular injury include decreased visual acuity, scotoma, photophobia, metamorphopsia, and chromatopsia. Chronic ocular, facial, and head pain are not attributed to laser pointer injury. Redness and irritation are similarly non-attributable. Signs include linear streaking and hypofluorescence on FA, and visible lesion on dilated fundus examination. AOSLO, fluorescein angiography (FA), fundus autofluorescence (FAF), OCT, and infrared (IR) have also been used to characterize lesions<sup>[88]</sup>. Mainster *et al.* present a 5-case series along with series of 6 questions to aid in evaluating real or imagined laser eye injury. The following question and case series can be used to aid in evaluation<sup>[89]</sup>.

1. Are there ocular abnormalities that could have been caused by a known laser-tissue interaction at the time of the reported incident?
2. If so, have those abnormalities been documented by a reliable technique, such as fundus photography, fluorescein angiography, or optical coherence tomography?
3. If so, do findings from ophthalmoscopy and retinal imaging evolve after the incident in a manner consistent with a laser injury?
4. If so, and substantial visual or somatic complaints are present, is there any scientific evidence that the objective ocular findings could cause the reported subjective complaints?
5. If so, and substantial visual complaints are present, is the location of Amsler grid or visual field defects stable and consistent with the location of the retinal abnormalities supposedly responsible for causing them?
6. If the laser source involved in the alleged injury is available or known, is it capable of producing the observed clinical findings under the reported exposure conditions?

### Mainster's example cases:

The article goes through several sample cases of applying the above 6 criteria to an evaluation of alleged laser eye injury.

Case A. 11-year-old girl >10 seconds staring at red laser pointer resulting in painless scotoma. Central foveal pigment mottling and faint hyperfluorescence on evaluation 3 weeks later. Vision returned to 20/25. Yes, likely due to laser injury.

Case B. Middle-age woman momentarily exposed to ordinary laser pointer. 4 years later developed headaches, photophobia, and pains. No pathology on FA or slit lamp other than dry eye. 20/20 OU. Not likely due to laser injury.

Case C. Young male soldier accidentally exposed to q-switched 1064 nm range finder laser pulses resulting in painless decrease in vision. At 24 hours: vitreous hemorrhage overlying 2 foveal retinal holes. At 5 days: "3 prominent chorioretinal lesions with surrounding hyperfluorescence." Visual acuity at 18 months: 20/400. Not due to

laser injury.

Case D. 40-year-old soldier: 3 light pulses in 3 seconds by tank 3 km away. Ocular discomfort lasting 1 hour after mission, relieved by acetaminophen. Visual acuity 20/200 after incident and over next 5 years. 7 years after incident: metamorphopsia. 9 years after incident: 20/20 OD 20/50 OS. Numerous macular 50-100 µm yellow flecks OU. FA: flecks had central hypofluorescence with surrounding hyperfluorescence that faded with time. Not due to laser injury.

Case E. Middle aged man developed chronic headaches, photophobia, blurred vision, and nighttime vision difficulties 5 years after photographing a ship. He surmised that a laser caused the injury. Not due to laser injury.

## DIFFERENT SETTINGS FOR LASER EYE INJURIES

A comprehensive literature review was performed on PubMed using

a variety of search terms related to laser eye injuries, handheld lasers, laser retinopathy, and laser pointer damage. What follows is a sample of cases reports found in the literature that illustrate the variety of presentations and contexts for injury.

### Military

Military and industrial lasers injure an estimated 15 people annually. A 2003 case review series published on military laser retinal injuries included 10 cases from 1984-2000, mostly by 1064 nm q-switched Nd:YAG range finding lasers. No corneal or anterior chamber injuries were reported. No individuals were wearing eye protection. Two received medical discharges as the result of their injuries. Authors suggest that unintentional injuries may be reduced by improving operator safety training and compliance, as well as improving equipment safety design features<sup>[90]</sup>.

Accidental exposure to a hand-held Nd:YAG range finder laser in 2004 resulted in a full thickness foveal hole in a 20-year-old man<sup>[91]</sup>.

**Table 1** Summary of laser-induced retina injury case reports involving military exposures.

Military Cases	Age	Type of Laser	Interval from injury to presentation	Presenting BCVA	Interval from injury to follow-up	Final BCVA	Fundus Findings
Harris (2003)	21	1064nm Q-switched Nd:YAG	Immediate	20/400	12 months	20/40	Vitreous hemorrhage and three focal lesions
	NA	620nm pulse-repetition Nd: YAG pumped dye laser	Immediate	20/unmeasurable	6 months	20/20	Macular hemorrhage
	19	AN/GVS5 laser rangefinder, Q-switched ND:YAG	1 day	20/200	18 months	Count fingers	
	24	6943nm Ruby laser	Immediate	10/400			Subretinal hemorrhage within center of macular involving fovea, vitreous overlying hemorrhage appeared to be detached
	21	AN/GVS-5	24 hours	20/25 OU	4 years	20/200 OD, 20/15 OS	Bilateral macular holes and vitreous hemorrhages
	21	G/VLLD AN-TVQ-2 laser target designator	Immediate	20/50 OD	55 days	20/20	
	29	Laser rangefinder	5w	20/50	15 weeks	20/25	NA
Allen (2004)	20	Nd:YAG laser range finder device	3 months	20/70			Full-thickness macular hole
Shenoy (2015)	27	Blue-green unlabelled laser pointer	1 day	1/60	1 month	1/60	Subhyaloid hemorrhage
	28	Blue-green unlabelled laser pointer	1 week	1/60	Lost to follow-up		Premacular subhyaloid hemorrhage
	28		Immediate	1/60			Full thickness macular hole
Noble (2015)	13	Green laser pointer		20/30	No visible lesion	2 months	20/30

**Table 2** Summary of laser-induced retina injury case reports involving industrial exposures.

Industrial Cases	Age	Type of Laser	Interval from injury to presentation	Presenting BCVA	Interval from injury to follow-up	Final BCVA	Fundus Findings
Zwick (1998)	21	1064nm Nd:YAG laser	Hours	20/50	55 days	20/20	Small macular hemorrhages OU
	21	1064nm Nd:YAG laser	2 days	20/200	139 days	20/15	Small vitreous hemorrhage, retinal injury on fovea
Newman (2000)	24	806nm Titanium-sapphire laser	2 days	6/18	12 weeks	6/6	Full thickness macular hole
Sakaguchi (2000)	24	1064nm Nd:YAG laser	3 days	20/100	1 month	20/100	Full-thickness macular hole
Roider (1999)	25	1064nm Nd:YAG AVIMON Limited LD 900 Range Finder	2 hours	20/100	4 months	20/130	Large, prominent hemorrhage
Kitaguchi (2009)	44	400;800nm Titanium:sapphire laser		20/50	6 months	20/50	Normal
	24	780nm Titanium:sapphire laser	1 day	20/25	1 month	20/20	Normal
Sun (2006)	22	Pulsed Green Laser Light Beam	5 days	0.08 OD	12 months	0.01	Small grayish-yellow lesion with exudation at foveal area
Fujinami (2010)	11	Green laser pointer	8-9 years	1	11-12 years	1	Yellow exudate-like lesion or fibrous tissue surrounded by subretinal hemorrhage
Milani (2011)	25	1064nm Nd:YAG laser	NA	20/60	6 months	20/20 OU	Extended lesion involving foveal area with a deep, central hemorrhage

**Table 3** Summary of laser-induced retina injury case reports involving commercially-available devices.

Commercial Cases	Age	Type of Laser	Interval from injury to presentation	Presenting BCVA	Interval from injury to follow-up	Final BCVA	Fundus Findings
Wyrsh (2010)	15	Green laser pointer	2 weeks	20/50 OD, Count fingers at 3ft OS	4 months	20/32 OD, 20/25 OS	Several tiny round scars in RPE of fovea OD, dense subretinal hemorrhage in macula OS
Ziahosseini (2010)	Teenager	Green diode laser pointer	NA	6/12 OU	2 months	6/6 OU	Bilateral foveal granularity
Xu (2016)	12	Green laser pointer	Shortly after injury	20/20 OD, 20/30 OS	7 months	20/20 OD, 20/30 OS	Pigment clumping with focal RPE atrophy OU
	9	Green laser pointer	4 days	20/50	1 month	20/30	Macular pigment changes
	16	Green laser pointer	Immediate	20/30 OU	2 weeks	20/40 OU	Macular chorioretinal scars and focal RPE atrophy
	12	Red laser pointer	Immediate	20/70	12 months	20/20	RPE atrophy and a choroidal neovascular membrane with subretinal hemorrhage
Hanson (2016)	11	Class III green laser pointer	9 months	6/20 OD, 6/10 OS	34 months	6/15 OD, 6/7.5 OS	Hyper- and hypopigmented scars at foveas OU
Thanos (2015)	44	Red laser pointer	6 months	0.8	NA	NA	Barely visible RPE disturbances within the temporal macula
Raouf (2015)	9	Hand-held laser device	24 hours	6/15	19 months	6/6	Yellow vitelliform-like lesion representing acute laser injury
	11	Laser device could not be obtained	NA	6/7.5 OU	12 months	6/9 OU	Bilateral yellow macular lesions
	8	Hand-held laser device	Several months'	6/12	12 months	6/7.5	Right foveal RPE changes consistent with laser burns
Lim (2014)	13	Green diode laser	4 weeks	20/100	12 months	20/60	Hypopigmented area of RPE centrally, without subretinal hemorrhage
Lee (2014)	10	Class 3B green laser pointer	4 days	20/30	18 months	20/20	Flat, deep diagonal foveal lesion comprised of central pigment clumping surrounded by hypopigmentation and window defect in areas of pigment loss
	9	Red laser pointer	4 days	Counting fingers at 3ft OU	12 months	20/100 OD, 20/70 OS	Bilateral, flat yellow foveal lesions with linear extension and RPE disruption radiating from fovea
	6	Class 3 green laser pointer	Several weeks'	Counting fingers	11 months	20/100	Flat, yellow foveal lesion with radiating streaks of RPE disruption
Alsulaiman (2014)	17	Blue laser beam	1 week	20/40	2 months	20/20	Unremarkable except yellowish-orange discoloration at left foveola representing defect in outer retinal layers
	30	Blue laser beam	2 months	20/70	3 months	20/30	Full-thickness macular hole
	11	Blue laser beam	1 week	20/300	11 weeks	20/160	Full-thickness macular hole
	15	Blue laser beam	2 days	20/400	3 weeks	20/50	Full-thickness macular hole
	18	Blue laser beam	2 months	20/200	3 months	20/40	Full-thickness macular hole
	15	Blue laser beam	5 days	20/300	12 weeks	20/20	Foveal sub-ILM hemorrhage
	22	Blue laser beam	3 days	4/200	6 weeks	20/40	Subhyaloid hemorrhage
	11	Blue laser beam	5 days	4/200	5 months	20/25	Subhyaloid hemorrhage
	18	Blue laser beam	2 hours	4/200	4 weeks	20/25	Subhyaloid hemorrhage
	20	Blue laser beam	6 days	20/100	4 weeks	20/40	Sub-ILM hemorrhage
	17	Blue laser beam	4 hours	5/200	6 weeks	20/15	Subhyaloid hemorrhage
	17	Blue laser beam	1 day	3/200	2 months	20/50	Subhyaloid hemorrhage
	18	Blue laser beam	2 months	20/200	5 months	20/70	ERM with SRF
16	Blue laser beam	4 days	20/70	2 months	20/20	Schisis-like cavity with SRF	



Abdelkader (2016)	20	Class IVb blue handheld laser	2 days	20/400	6 months	20/200	Massive macular edema with a small dot hemorrhage below fovea
Ueda (2011)	13	Class IIIB green laser pointer	1 day	24/20 OD, 24/20 OS	6 months	24/20 OD, 24/20 OS	Hypopigmented spot in fovea
Turaka (2012)	13	Class IIIA green laser pointer		1 day	20/100	20/60	Grey lesion in fovea
Lally (2014)	9	Red laser pointer	4 days	Counting fingers OU	6 months	20/200 OU	yellow-green foveal lesion with asymmetric radial spokes OU
Bhavsar (2015)	18	Red, Green, and Purple laser pointers	3 weeks	20/25 OD, 20/40 OS	8 weeks	20/160 OD, 20/100 OS	Bilateral perifoveal RPE changes
	11	Green laser pointer	1 day	Hand motion	1 month	Counting fingers at 5 feet	deep, yellow foveal lesion and prominent gray-white linear streaks at level of outer retina in superior macula
	14	Unknown laser	5 weeks	20/50 OD, 20/70 OS	9 weeks	20/20 OD, 20/30 OS	Perifoveal RPE changes OD>OS
Sayman (2016)	28	Laser light at a wedding	3 days	3/10	1 year	10/10	Foveal hemorrhage
	9	Laser at a hotel	15 days	Counting fingers	6 months	9/10	Foveal hemorrhage
	24	Laser light at an entertainment venue	1 week	1/10	6 months	3/10	Subretinal foveal hemorrhage
Qi (2017)	26	Nd:YAG laser	5 days	2/20	10 months	3/20	Full-thickness Macular Hole
	21	Nd:YAG laser	Few hours	2/20	38 months	20/20	Full-thickness Macular Hole
	27	Nd:YAG laser	2 months	6/20	9 months	10/20	Full-thickness Macular Hole
	38	Nd:YAG laser	2 months	4/20	5 months	14/20	Full-thickness Macular Hole
	35	Nd:YAG laser	3-4 months	8/20	45 months	20/20	Full-thickness Macular Hole
	20	NA	1 month	Counting fingers	7 months	Counting fingers	Full-thickness Macular Hole
	10	Green handheld laser	1 month	1/20	28 months	16/20	Full-thickness Macular Hole
	13	Blue handheld laser	1 month	8/20	21 months	20/20	Full-thickness Macular Hole
	14	Green handheld laser	10 days	4/20	22 months	16/20	Full-thickness Macular Hole
	32	Blue handheld laser	2 days	6/20	13 months	20/20	Full-thickness Macular Hole
Zhang (2016)	11	Green laser pointer	14 months	20/60	22 months	20/30	Whitish dots in temporal retina, pigmented scar in fovea
	13	Green laser pointer	8 months	20/80	21 months	20/60	Dendritic-shaped lesions
	8	Green laser pointer	6 weeks	20/25	6 months	20/60	Dendritic lesion
	10	Green laser pointer	8 months	20/25	NA	NA	Dendritic lesion
	14	Red laser pointer	1 day	20/80	8 days	20/80	Dendritic foveal lesion
Zhao (2017)	10	Green laser pointer	2 days	10/20	12 months	16/20	Dispersion disorder of foveal reflex
Liang (2017)	29	LED-derived blue laser	4 days	20/40	1 month	20/20	Round red macular lesion

In Oman, three soldiers celebrating a football game developed vision loss after competing in a staring contest with blue-green laser pointers lasting 5-10 seconds<sup>[92]</sup>. A 2015 Military Medicine case study presented case of “visually significant damage to the retina” from brief handheld laser exposure, and warns of dangers from increasing number of military target designating, range finding and radar warning system lasers with high powers<sup>[93]</sup>. These and other military-related laser exposure cases are summarized in (Table 1).

### Industrial

The International Commission on Non-Ionizing Radiation Protection (ICNIRP) has guidelines for human exposure. Laser Maximum Permissible Exposure (MPE) limits are used in international safety standards. They are based on ICNIRP guidelines, and revised periodically to reflect new technology<sup>[94]</sup>. Several case reports since 1998 that describe industrial laser injuries including those involving Nd:YAG and Titanium-sapphire lasers and are summarized in Table 2<sup>[95,96,97,98,99,100,101,102,103,104,105]</sup>.

Welders are at risk for retinal injury<sup>[106]</sup>. In fact, the most frequently reported industrial retinal injuries are from welding arcs and intense lights. However, permanent vision loss from these events are rare. The most frequent attribution for industrial accidents is lack of equipment understanding and failure to follow safety standards<sup>[107]</sup>.

Industrial photoretinitis maculopathy has been described in the following settings: (1) as the result of non-ionizing radiation generated from metal arc inert gas-shielded welding and oxygen lance light<sup>[108]</sup>; (2) despite protective lenses<sup>[109,110]</sup>; (3) in the setting of fluphenazine accumulation in the RPE<sup>[111]</sup> and (4) due to light flash from short-circuited high-tension electrical circuit<sup>[112]</sup>.

Maximal permissible exposure times are often presented in the field of occupational health for different light sources. For instance, Okuno *et al.* presented a study of blue-light hazards from various light sources<sup>[113]</sup>, and a systematic analysis was published specifically on light-based insect traps<sup>[114]</sup>.

### Pilots

Federal Aviation Administration (FAA) reports of pilot-related laser incidents rose from 2,836 in 2010 to 7,442 in 2016<sup>[115]</sup>. A 2015 Canadian article analyzed 58 male and 3 female airline pilots who reported to their clinic due to laser strike while flying between April 2012 and November 2014. All pilots reported immediate ocular irritation or light sensitivity, but there were no signs of damage documented on ophthalmic exam that included visual acuity, color vision, visual fields, intraocular pressure (IOP), slit lamp examination, dilated fundus examination, color fundus photos, and OCT<sup>[116]</sup>. Only 1 confirmed case has been published of permanent retinal injury to a pilot. It occurred from blue laser light while the plane was at an elevation of approximately 396 m. Examination revealed localized photoreceptor disruption on OCT, well-demarcated hypofluorescence on AF, and an identifiable lesion on dilated fundus examination<sup>[117]</sup>. Despite the lack of lasting ocular damage, these incidents can cause glare, flash blindness and irritation that can jeopardize the safety of the flight.

### Commercial

The first commercially available lasers were red (760 nm). Soon, other wavelengths became available to allow for a greater variety of commercial applications. For instance, green lasers are visible in both day and night and good for stargazing and marking far-off targets. Blue and violet lasers reflect a spectrum of colors depending on target properties. Yellow lasers have a gold hue that is desirable for laser

guide star in astronomical adaptive optics<sup>[118]</sup>.

Handheld laser pointers sold in the United States have generally been considered safe due to evidence-based Food and Drug Administration (FDA) regulations. However, the online marketplace is unregulated and has resulted in children using them to pop balloons and accidentally injure their eyes<sup>[119]</sup>. Pointers purchased online are not necessarily readily distinguished by the consumer, or in other cases are marketed to amateur consumers interested in high powered, unregulated lasers<sup>[120]</sup>.

Children are vulnerable particularly to lasers purchased from unregulated marketplaces<sup>[121]</sup>, for instance online, where they can subsequently be used for entertainment<sup>[122]</sup>. These lasers may be unsafe, over the 5mW FDA safety limit, and indistinguishable in appearance from low-powered lasers. They can produce retinal injury with momentary exposure<sup>[123]</sup>. Online marketing of these lasers seem particularly attractive to teenagers as fun gadgets, laser swords, and pranks<sup>[124]</sup>.

A variety of retina-involving cases involving commercially-available handheld lasers are summarized in tables 3 and 4. These include lasers purchased overseas and online, cases from Saudi Arabia, China, Japan, Germany, Saudi Arabia, and USA, and incidents involving children shining lasers in a rear-view mirror, creating their own “laser light shows,” an individual passing out at a bar looking at an LED light, ill-advised dares, and accidents<sup>[125-143]</sup>.

Many of the authors made recommendations or suggestions regarding prevention and recognition of laser eye injuries. These include that the presence of outer retinal streaks suggests repeated self-harm as the cause of injury. There is an interesting assertion that although brief exposures to high-powered industrial lasers may be very painful and result in macular holes, less-powered handheld lasers can cause self-injury specifically due to lack of pain and increased duration of exposure<sup>[144]</sup>. Other authors urge for stricter rules for “uncontrolled and inappropriate use of laser instruments,” and changing the “general misperception that lasers are safe to use for entertainment purposes.”<sup>[145]</sup>

Certain case reports could not be included in our summary table due to lack of access, language, or formatting difficulty. They are presented here. A 2014 case series from the Netherlands describes boys aged 13, 12, and 9 who developed permanent vision loss after playing with unsafe laser pointers. One of the laser pointers was an unlabeled Class IIIB 125 mW, which was purchased while on vacation in Croatia. Another was a Class IIIA purchased during a father’s business trip in China. The other a class IIIB 5-500 mW laser was purchased in Thailand as a gift<sup>[146]</sup>. Phototoxic maculopathy has been described from staring at a quartz infrared heat lamp via photothermal and photochemical mechanisms<sup>[147]</sup>. Tomasso *et al.* published a 2017 paper in *European Journal of Ophthalmology* that first described sub-RPE (choriocapillaris) laser pointer injury via findings OCT in a 13-year-old boy who had stared into the beam of a laser pointer<sup>[148]</sup>. Laser pointers may be used by people with history of self-harm, as in a case report from France in 2016<sup>[149]</sup>.

### Recreational

Pseudophakic retinas with polymethylmethacryl intraocular lenses (IOLs) may be at greater risk due to higher temperature increases and UV retinal irradiances<sup>[150]</sup>. Modern IOLs, however, are mostly made of acrylic and are designed to block numerous blue and harmful wavelengths. Direct sun gazing is likely harmful, and has been shown in rat models to cause neuronal apoptosis and glio-vascular response in the retina that can lead to permanent vision loss<sup>[151]</sup>. UV light is a risk factor for age-related macular degeneration (ARMD)

<sup>[152]</sup>. Solar retinopathy has been reported during prayers<sup>[153]</sup>, observing solar eclipse<sup>[154,155]</sup>, during recreational sun gazing<sup>[156]</sup>, sunbathing and mental disturbance<sup>[157,158]</sup>.

## DISCUSSION

Lasers are becoming an increasingly important component of commercial, industrial, recreational, and medical equipment. While lasers are an indispensable component in the management of diseases of the vitreous and retina and have revolutionized the treatment of many ocular conditions, lasers used for non-therapeutic purposes can cause permanent damage and blindness in the eye. With the proliferation of internet sales and cryptocurrencies which are often poorly regulated, lasers are increasingly being distributed without appropriate safety precautions taken, and people are at increasing risk for injury. The eye is particularly vulnerable to laser injury due to the focusing power of the eye and the optical transparency of the eye. Particularly since the retina is central nervous tissue that does not regenerate, this injury is of critical public health importance, especially since many of the people injured in these cases are young and thus will have to live many years with significant morbidity from these injuries. This also highlights the importance and need for further development of therapies that could treat patients who have suffered from retinal laser injury where none currently exist, particular neuro-protective, neuro-regenerative, and stem cell therapies. Continued innovations in laser technology will likely mean that lasers will play an increasingly important and ubiquitous role throughout the world, and thus critical evaluation should also be paid to ensure that non-therapeutic injuries are minimized.

## ACKNOWLEDGEMENTS

**Funding:** Funding was provided by the generous support of the National Eye Institute 1K08EY027458 (YMP).

## REFERENCES

1. Medical Laser Systems-Global Strategic Business Report. Global Industry Analysts. 2013; (365).
2. Barkana Y, Belkin M. Laser eye injuries. *Surv Ophthalmol.* 2000; 44: 459-478. [PMID: 10906379]; [DOI: 10.1016/s0039-6257(00)00112-0]
3. US Food and Drug Administration. FDA issues warning on misuse of laser pointers. US Department of Health and Human Services (HHS). HHS News. 1997.
4. Abbasi K. UK bans powerful laser pointers. *BMJ.* 1997; 315: 1253. [PMID: 9390047]
5. World Health Organization. 1998 Information Fact Sheet No. 202. Health risks from the use of laser pointers.
6. Marshall J. The safety of laser pointers: myths and realities. *Br J Ophthalmol.* 1998; 82: 1335-8. [PMID: 9924345]; [DOI: 10.1136/bjo.82.11.1335]
7. Lamotte J, Fife J, Lee A, et al. The power output of laser pointers: do they exceed federal standards?. *Optom Vis Sci.* 2001; 78(7): 525-528. [PMID: 11503942]; [DOI: 10.1097/00006324-200107000-00016]
8. US Food and Drug Administration. 2006. Consumer Safety Alert: Internet Sales of Laser Products.
9. Ajudua S, Mello MJ. Shedding Some Light on Laser Pointer Eye Injuries. *Pediatr Emerg Care.* 2007 Sep.; 23(9): 669-72. [PMID: 17876263]; [DOI: 10.1097/PEC.0b013e31814b2dc4]
10. Hadler J, Tobares E, Dowell M. Random testing reveals excessive power in commercial laser pointers. *J Laser Appl.* 2013; 25: 032007. [DOI: 10.2351/1.4798455]
11. Bartsch DU, Muftuoglu IK, Freeman WR. Laser Pointers Revisited. *Retina.* 2016 Sep; 36(9): 1611-3. [PMID: 27533775]; [DOI: 10.1097/IAE.0000000000001253]
12. Alda J, Gómez Sanz F, González Martín-Moro J. Laser pointer maculopathy. A new public health problem?. Vol. 92, *Archivos de la Sociedad Española de Oftalmología (English Edition)*. 2017. [PMID: 27746065]; [DOI: 10.1016/j.oftal.2016.09.001]
13. The Diabetic Retinopathy Study Research Group. Photocoagulation treatment of proliferative diabetic retinopathy: clinical application of Diabetic Retinopathy Study (DRS) findings, DRS Report Number 8. *Ophthalmology.* 1981; 88: 583-600. [PMID: 7196564]
14. Early Treatment Diabetic Retinopathy Study Research Group. Techniques for scatter and local photocoagulation treatment of diabetic retinopathy. Early Treatment Diabetic Retinopathy Study Report Number 3. *Int Ophthalmol Clin.* 1987; 27: 254-264. [PMID: 3692707]; [DOI: 10.1097/00004397-198702740-00005]
15. Aiello L, Ferris F, Bresnick G, Bailey I. Early Treatment Diabetic Retinopathy Study design and baseline patient characteristics. ETDRS report number 7. *Ophthalmology.* 1991 May; 98(5 Suppl): 741-56. [PMID: 2062510]; [DOI: 10.1016/s0161-6420(13)38009-9]
16. Durukan AH, Kerimoglu H, Erdurman C, Demirel A, Karagul S. Long-term results of Nd: YAG laser treatment for premacular subhyaloid haemorrhage owing to Valsalva retinopathy. *Eye (Lond).* 2008; 22: 214-8. [PMID: 16946748]; [DOI: 10.1038/sj.eye.6702574]
17. Niemz MH. Medical Applications of Lasers. In: *Laser-tissue interactions: fundamentals and applications*. 2007. p. 151-248.
18. Luttrull JK, Sramek C, Palanker D, Spink CJ, Musch DC. Long-term safety, high-resolution imaging, and tissue temperature modeling of subvisible diode micropulse photocoagulation for retinovascular macular edema. *Retina.* 2012 Feb; 32(2): 375-86. [PMID: 21971077]; [DOI: 10.1097/IAE.0b013e3182206f6c]
19. Sliney DH. How Light Reaches the Eye and Its Components. *Int J Toxicol.* 2002 Nov; 21(6): 501-9. [PMID: 12537646]; [DOI: 10.1080/10915810290169927]
20. Belkin M. Ophthalmic manifestations of laser-induced eye injuries. *Laser- inflicted eye injuries: epidemiology, prevention, and treatment*. Bellingham SPIE. 1996; 2674: 2-6. [DOI: 10.1117/12.237496]
21. Mainster MA, Stuck BE, Brown J., Jr Assessment of alleged retinal laser injuries. *Arch Ophthalmol.* 2004; 122: 1210-7. [PMID: 15302664]; [DOI: 10.1001/archophpt.122.8.1210]
22. Maiman TH. Stimulated optical radiation in ruby. *Nature.* 1960; 187: 493 [DOI: 10.1038/187493a0]
23. Peyman GA, Raichand M, Zeimer RC. Ocular effects of various laser wavelengths. *Surv Ophthalmol* 1984; 28(5): 391-404. [PMID: 6426070]; [DOI: 10.1016/0039-6257(84)90244-3]
24. American National Standard for safe use of lasers. Orlando, FL: Laser Institute of America; 2014.
25. Denton ML, Foltz MS, Estlack LE, et al. Damage thresholds for exposure to NIR and blue lasers in an in vitro RPE cell system. *Investigative Ophthalmology and Visual Science.* 2006; 47(7): 3065-3073. [PMID: 16799053]; [DOI: 10.1167/iovs.05-1066]
26. Cain CP, Toth CA, DiCarlo CD, et al. Visible retinal lesions from ultrashort laser pulses in the primate eye. *Investigative Ophthalmology and Visual Science.* 1995; 36(5): 879-888. [PMID: 7706036]
27. Lund DJ, Stuck BE, Edsall P. Retinal injury thresholds for blue wavelength lasers. *Health Physics.* 2006; 90(5): 477-484. [PMID: 16607179]; [DOI: 10.1097/01.HP.0000190115.83416.cb]
28. Zuclich JA, Stolarski DJ. Retinal damage induced by red diode laser. *Health Physics.* 2001; 81(1): 8-14. [PMID: 11414628]; [DOI: 10.1097/00004032-200107000-00003]
29. Lund DJ, Edsall P, Stuck BE, Schulmeister K. Variation of laser-induced retinal injury thresholds with retinal irradiated area: 0.1-s duration, 514-nm exposures. *Journal of Biomedical Optics.* 2007;

- 12(2)024023. [PMID: 17477738]; [DOI: 10.1117/1.2714810]
30. Vincelette RL, Rockwell BA, Oliver JW, et al. Trends in retinal damage thresholds from 100-millisecond near-infrared laser radiation exposures: a study at 1,110, 1,130, 1,150, and 1,319 nm. *Lasers in Surgery and Medicine*. 2009; 41(5): 382-390. [PMID: 19533764]; [DOI: 10.1002/lsm.20772]
  31. Robertson DM, Lim TH, Salomao DR, et al.. Laser pointers and the human eye: a clinicopathologic study. *Arch Ophthalmol* 2000; 118: 1686-1691 [PMID: 11115266]; [DOI: 10.1001/archophth.118.12.1686]
  32. Harris MD, Lincoln AE, Amoroso PJ, Stuck B, Sliney D. Laser eye injuries in military occupations. *Aviat Space Environ Med*. 2003; 74: 947-52 [PMID: 14503672]
  33. Center for Devices and Radiological Health. Safety Communications - Risk of Eye and Skin Injuries from Hand-held Laser Pointers: FDA Safety Communication. U S Food and Drug Administration Home Page. [url: <https://www.fda.gov/MedicalDevices/Safety/AlertsandNotices/ucm478707.htm>. Accessed July 18, 2017.]
  34. Glickman RD. Phototoxicity to the Retina: Mechanisms of Damage. *Int J Toxicol*. 2002; 21(6): 473-90. [PMID: 12537644]; [DOI: 10.1080/10915810290169909]
  35. Sacu S, Schmidt-Erfurth U. Principles of laser therapy. In: Singh AD, Damato BE, Pe'er J, Murphree AL, Perry JD. *Clinical Ophthalmic Oncology*. Saunders-Elsevier: Philadelphia, 2007
  36. Clark CD, III, Denton ML, Thomas RJ. Mathematical model that describes the transition from thermal to photochemical damage in retinal pigment epithelial cell culture. *Journal of Biomedical Optics*. 2011; 16(2)020504 [PMID: 2136166]
  37. Allen RD, Brown J, Zwick H, Schuschereba ST, Lund DJ, Stuck BE. Laser-induced macular holes demonstrate impaired choroidal perfusion. *Retina*. 2004 Feb.; 24(1): 92-7. [PMID: 15076949]; [DOI: 10.1097/00006982-200402000-00013]
  38. Barkana Y, Belkin M. Laser eye injuries. *Surv Ophthalmol*. 2000; 44: 459-478 [PMID: 10906379]; [DOI: 10.1016/s0039-6257(00)00112-0]
  39. Robertson DM, McLaren JW, Salomao DR, Link TP. Retinopathy from a green laser pointer: a clinicopathologic study. *Arch Ophthalmol* 2005; 123: 629-33. [PMID: 15883281]; [DOI: 10.1001/archophth.123.5.629]
  40. Singh AD. Ocular phototherapy. *Eye*. 2013 Feb 1; 27(2): 190-8. [PMID: 23238445]; [DOI: 10.1038/eye.2012.258]
  41. Ham WT, Jr, Ruffolo JJ, Jr, Mueller HA, Clarke AM, Moon ME. Histologic analysis of photochemical lesions produced in rhesus retina by short-wave-length light. *Invest Ophthalmol Vis Sci*. 1978; 17(10): 1029-1035 [PMID: 100464]
  42. Robertson DM, H Z, BE S, TP L, RL R, JW M. Retinopathy From a Green Laser Pointer. *Arch Ophthalmol*. American Medical Association; 2005 May 1; 123(5): 629. [PMID: 15883281]; [DOI: 10.1001/archophth.123.5.629]
  43. Paulus YM, Kaur K, Egbert PR, Blumenkranz MS, Moshfeghi DM. Human histopathology of PASCAL laser burns. *Eye*. 2013 Aug 31; 27(8): 995-6. [PMID: 23722723]; [DOI: 10.1038/eye.2013.100]
  44. Allen RD, Brown J, Jr, Zwick H, Schuschereba ST, Lund DJ, Stuck BE. Laser-induced macular holes demonstrate impaired choroidal perfusion. *Retina*. 2004; 24: 92-7 [PMID: 15076949]; [DOI: 10.1097/00006982-200402000-00013]
  45. Ishibashi T, Miller H, Orr G, Sorgente N, Ryan SJ. Morphologic observations on experimental subretinal neovascularization in the monkey. *Invest Ophthalmol Vis Sci*. 1987; 28: 1116-1130 [PMID: 2439474]
  46. Schuschereba ST, Bowman PD, Ferrando RE, et al. Accelerated healing of laser-injured rabbit retina by basic fibroblast growth factor. *Invest Ophthalmol Vis Sci*. 1994; 35: 945-954 [PMID: 8125757]
  47. Pocock GM, Oliver JW, Specht CS, Estep JS, Noojin GD, Schuster K, et al. High-resolution in vivo imaging of regimes of laser damage to the primate retina. *J Ophthalmol*. Hindawi Publishing Corporation; 2014; 2014: 516854. [PMID: 24891943]; [DOI: 10.1155/2014/516854]
  48. Morgan JIW, Hunter JJ, Masella B, Wolfe R, Gray DC, Merigan WH, et al. Light-Induced Retinal Changes Observed with High-Resolution Autofluorescence Imaging of the Retinal Pigment Epithelium. *Investig Ophthalmology Vis Sci*. 2008 Aug 1; 49(8): 3715. [PMID: 18408191]; [DOI: 10.1167/iovs.07-1430]
  49. Borland RG, Brennan DH, Marshall J, et al. The role of fluorescein angiography in the detection of laser-induced damage to the retina: a threshold study for Q-switched, neodymium and ruby lasers. *Exp Eye Res* 1978; 27: 471-93. [PMID: 103737]; [DOI: 10.1016/0014-4835(78)90025-8]
  50. Kitaguchi Y, Fujikado T, Kusaka S, Yamaguchi T, Mihashi T, Tano Y. Imaging of Titanium: Sapphire Laser Retinal Injury by Adaptive Optics Fundus Imaging and Fourier-Domain Optical Coherence Tomography. *Am J Ophthalmol*. 2009 Jul; 148(1): 97-104.e2. [PMID: 19327747]; [DOI: 10.1016/j.ajo.2009.01.019]
  51. Tomasso L, Benatti L, La Spina C, Lattanzio R, Baldin G, Carnevali A, De Vitis LA, Querques L, Bandello F, Querques G. Optical coherence tomography angiography findings in laser maculopathy. *Eur J Ophthalmol*. 2017 Jan 19; 27(1): e13-e15. [PMID: 19327747]; [DOI: 10.1016/j.ajo.2009.01.019]
  52. Kung Y, Wu, T, Sheu S. Subtle solar retinopathy detected by fourier-domain optical coherence tomography. *J Chin Med Assoc*. 2010; 73: 396-398. [PMID: 20688308]; [DOI: 10.1016/S1726-4901(10)70085-X]
  53. Bechmann M, Ehrt O, Thiel MJ, et al. Optical coherence tomography findings in early solar retinopathy. *Br J Ophthalmol*. 2000; 84: 547-548. [PMID: 10847708]; [DOI: 10.1136/bjo.84.5.546b]
  54. Stangos AN, Petropoulos IK, Pournaras JA, Zaninetti M, Borruat FX, Pournaras CJ. Optical coherence tomography and multifocal electroretinogram findings in chronic solar retinopathy. *Am J Ophthalmol*. 2007; 144: 131-134. [PMID: 17601436]; [DOI: 10.1016/j.ajo.2007.03.003]
  55. Kaushik S, Gupta V, Gupta A. Optical coherence tomography findings in solar retinopathy. *Ophthalmic Surg Lasers Imaging*. 2004; 35: 52-55. [PMID: 14750764]
  56. Jorge R, Costa RA, Quirino LS, et al. Optical coherence tomography findings in patients with late solar retinopathy. *Am J Ophthalmol*. 2004; 137: 1139-1142. [PMID: 15183809]; [DOI: 10.1016/j.ajo.2003.12.033]
  57. Gulkilik G, Taskapili M, Kocabora S, et al. Association between visual acuity loss and optical coherence tomography findings in patients with late solar retinopathy. *Retina*. 2009; 29: 257-261. [PMID: 19033886]; [DOI: 10.1097/IAE.0b013e31818a2105]
  58. Pocock GM, Oliver JW, Specht CS, Estep JS, Noojin GD, Schuster K, et al. High-resolution in vivo imaging of regimes of laser damage to the primate retina. *J Ophthalmol*. 2014; 2014: 516854. [PMID: 24891943]; [DOI: 10.1155/2014/516854]
  59. Singh AD. Ocular phototherapy. *Eye*. 2013 Feb 14; 27(2): 190-8. [PMID: 23238445]; [DOI: 10.1038/eye.2012.258]
  60. Sramek C, Leung L-S, Leng T, Brown J, Paulus YM, Schuele G, et al. Improving the therapeutic window of retinal photocoagulation by spatial and temporal modulation of the laser beam. *J Biomed Opt*. 2011; 16(2): 28004. [PMID: 21361711]; [DOI: 10.1117/1.3542045]
  61. Paulus YM. New Frontiers in Selective Retinal Lasers. *Int J Ophthalmic Res*. 2015; 1(1): 1-4. [DOI: 10.17554/j.issn.2409-5680.2015.01.8]
  62. Sramek C, Paulus Y, Nomoto H, Huie P, Brown J, Palanker D. Dynamics of retinal photocoagulation and rupture. *J Biomed Opt*. 2009; 14(3): 34007-034007-13. [PMID: 19566300]; [DOI: 10.1117/1.3130282]
  63. Sramek CK, Leung L-SB, Paulus YM, Palanker D V. Therapeutic

- Window of Retinal Photocoagulation With Green (532-nm) and Yellow (577-nm) Lasers. *Ophthalmic Surgery, Lasers, and Imaging*. 2012 Jul 1; 43(4): 341-7. [PMID: 22589338]; [DOI: 10.3928/15428877-20120426-05]
64. Sher A, Jones BW, Huie P, Paulus YM, Lavinsky D, Leung L-SS, et al. Restoration of Retinal Structure and Function after Selective Photocoagulation. *J Neurosci*. 2013 Apr 17; 33(16): 6800-8 [PMID: 23595739]; [DOI: 10.1523/JNEUROSCI.1044-12.2013]
  65. Paulus YM, Jain A, Gariano RF, Stanzel BV, Marmor M, Blumenkranz MS, Palanker D. Healing of retinal photocoagulation lesions. *Invest Ophthalmol Vis Sci*. 49: 5540-5545. [PMID: 18757510]; [DOI: 10.1167/iovs.08-1928]
  66. Paulus YM, Jain A, Nomoto H, Sramek C, Gariano RF, Andersen D, Schuele G, Leung LS, Leng T, Palanker D Selective retinal therapy with microsecond exposures using a continuous line scanning laser. *Retina*. 2001; 31: 380-388. [PMID: 20930656]; [DOI: 10.1097/IAE.0b013e3181e76da6]
  67. Paulus YM, Jain A, Gariano RF, Stanzel B V., Marmor M, Blumenkranz MS, et al. Healing of retinal photocoagulation lesions. *Investig Ophthalmol Vis Sci*. 2008; 49(12): 5540-5. [PMID: 18757510]; [DOI: 10.1167/iovs.08-1928]
  68. Zwick H, Edsall P, Stuck BE, Wood E, Elliott R, Cheramie R, Hacker H. Laser-induced photoreceptor damage and recovery in the high numerical aperture eye of the garter snake. *Vis Res*. 2008; 48: 486-493. [PMID: 18252238]; [DOI: 10.1016/j.visres.2007.09.012]
  69. Kasaoka M, Ma J, Lashkari K. c-Met modulates RPE migratory response to laser-induced retinal injury. *PLoS One*. 2012; 7: e40771. [PMID: 22808260]; [DOI: 10.1371/journal.pone.0040771]
  70. Sliney DH. Biohazards of ultraviolet, visible and infrared radiation. *J Occup Med*. 1983 Mar.; 25(3): 203-10. [PMID: 6842311]; [DOI: 10.1097/00043764-198303000-00013]
  71. Youssef PN, Sheibani N, Albert DM. Retinal light toxicity. *Eye*. 2010; 25(1): 1-14. [PMID: 21178995]; [DOI: 10.1038/eye.2010.149]
  72. Oosterhuis JA, Journee-de Korver HG, Kakebeeke-Kemme HM, Bleeker JC. Transpupillary thermotherapy in choroidal melanomas. *Arch Ophthalmol*. 1995; 113(3): 315-321. [PMID: 7887845]; [DOI: 10.1001/archophth.1995.01100030071024]
  73. Kociecki J, Biczysko W, Korver HG, Keunen JE, Pecold K. Additional cell damage after transpupillary thermotherapy in choroidal malignant melanoma. *Melanoma Res*. 2001 Oct.; 11(5): 511-5. [PMID: 11595889]; [DOI: 10.1097/00008390-200110000-00011]
  74. Newsom RS, McAlister JC, Saeed M, McHugh JD. Transpupillary thermotherapy (TTT) for the treatment of choroidal neovascularisation. *Br J Ophthalmol*. BMJ Publishing Group; 2001 Feb.; 85(2): 173-8. [PMID: 11159481]; [DOI: 10.1136/bjo.85.2.173]
  75. Mainster MA, Reichel E. Transpupillary thermotherapy for age-related macular degeneration: long-pulse photocoagulation, apoptosis, and heat shock proteins. *Ophthalmic Surg Lasers*. 2000; 31359- 373. [PMID: 11011704]
  76. Youssef PN, Sheibani N, Albert DM. Retinal light toxicity. *Eye*. 2010; 25(1): 1-14. [PMID: 21178995]; [DOI: 10.1038/eye.2010.149]
  77. Clark CD, Denton ML, Thomas RJ. Mathematical model that describes the transition from thermal to photochemical damage in retinal pigment epithelial cell culture. *J Biomed Opt*. 2011 Feb.; 16(2): 20504. [PMID: 21361660]; [DOI: 10.1117/1.3544504]
  78. Wu J, Seregard S, Algreve P V. Photochemical Damage of the Retina. *Surv Ophthalmol*. 2006 Sep.; 51(5): 461-81. [PMID: 16950247]; [DOI: 10.1016/j.survophthal.2006.06.009]
  79. Ham WT, Mueller HA, Ruffolo JJ Jr, Clarke AM. Sensitivity of the retina to radiation damage as a function of wavelength. *Photochem Photobiol*. 1979; 29: 735-743. [PMID: 109869]; [DOI: 10.1111/j.1751-1097.1979.tb07759.x]
  80. Michael R, Wegener A. Estimation of safe exposure time from an ophthalmic operating microscope with regard to ultraviolet radiation and blue-light hazards to the eye. *J Opt Soc Am A. Optical Society of America*; 2004 Aug 30.; 21(8): 1388. [PMID: 15330464]; [DOI: 10.1364/josaa.21.001388]
  81. Schmitz-Valckenberg S, Guo L, Cheung W, Moss SE, Fitzke FW, Cordeiro MF. In vivo imaging of retinal cell apoptosis following acute light exposure. *Ophthalmology*. 2010; 107: 22-29. [PMID: 19499229]; [DOI: 10.1007/s00347-009-1952-y]
  82. Ham WT, Jr, Ruffolo JJ, Jr, Mueller HA, Clarke AM, Moon ME. Histologic analysis of photochemical lesions produced in rhesus retina by short-wave-length light. *Invest Ophthalmol Vis Sci*. 1978; 17(10): 1029-1035. [PMID: 100464]
  83. Li H, Cai S, Gong X, Wu Z, Lyn J, Su G, et al. [The effect of blue light on human retinal pigment epithelium cells  $\alpha$ 1D subunit protein expression and vascular endothelial growth factor and basic fibroblast growth factor secretion in vitro]. *Zhonghua Yan Ke Za Zhi*. 2014 Nov.; 50(11): 814-9. [PMID: 25582206]
  84. Van Gelder RN. Photochemical approaches to vision restoration. *Vision Res*. 2015 Jun.; 111(Pt B): 134-41. [PMID: 25680758]; [DOI: 10.1016/j.visres.2015.02.001]
  85. Lavinsky D, Chalberg TW, Mandel Y, Huie P, Dalal R, Marmor M, et al. Modulation of transgene expression in retinal gene therapy by selective laser treatment. *Invest Ophthalmol Vis Sci*. 2013 Mar 13.; 54(3): 1873-80. [PMID: 23422827]; [DOI: 10.1167/iovs.12-10933]
  86. Peyman GA, Raichand M, Zeimer RC. Ocular effects of various laser wavelengths. *Surv Ophthalmol* 1984; 28(5): 391-404. [PMID: 6426070]; [DOI: 10.1016/0039-6257(84)90244-3]
  87. Wang J, Sramek C, Paulus YM, Lavinsky D, Schuele G, Anderson D, et al. Retinal safety of near-infrared lasers in cataract surgery. *J Biomed Opt*. 2012 Sep 14; 17(9): 950011. [PMID: 23085903]; [DOI: 10.1117/1.JBO.17.9.095001]
  88. Sheyman AT, Nesper PL, Fawzi AA, Jampol LM. Adaptive Optics Imaging in Laser Pointer Maculopathy. *Ophthalmic Surg Lasers Imaging Retina*. 2016 Aug 1; 47(8): 782-5. [PMID: 27548458]; [DOI: 10.3928/23258160-20160808-14]
  89. Mainster MA, Stuck BE, Brown J., Jr Assessment of alleged retinal laser injuries. *Arch Ophthalmol*. 2004; 122: 1210-7. [PMID: 15302664]; [DOI: 10.1001/archophth.122.8.1210]
  90. Harris MD, Lincoln AE, Amoroso PJ, Stuck B, Sliney D. Laser eye injuries in military occupations. *Aviat Space Environ Med*. 2003 Sep.; 74(9): 947-52. [PMID: 14503672]
  91. Allen RD, Brown J, Jr, Zwick H, Schuschereba ST, Lund DJ, Stuck BE. Laser-induced macular holes demonstrate impaired choroidal perfusion. *Retina*. 2004; 24: 92-7. [PMID: 15076949]; [DOI: 10.1097/00006982-200402000-00013]
  92. Shenoy R, Bialasiewicz AA, Bandara A, Isaac R. Retinal Damage from Laser Pointer Misuse - Case Series from the Military Sector in Oman. *Middle East Afr J Ophthalmol*. Medknow Publications; 2015; 22(3): 399-403. [PMID: 26180486]; [DOI: 10.4103/0974-9233.159780]
  93. Noble C, Blice J. Permanent retinal injury from recreational laser pointer. *Mil Med*. 2015 Mar; 180(3): e378-80. [PMID: 25735035]; [DOI: 10.7205/MILMED-D-14-00420]
  94. ICNIRP Publications. International Commission on Non-Ionizing Radiation Protection. <http://www.icnirp.org/en/publications/index.html>. Accessed April 12, 2017.
  95. Zwick H, Stuck BE, Dunlap W, et al. Accidental bilateral q-switched neodymium laser exposure: treatment and recovery of visual function. *SPIE* 1998; 3254: 80-89. [DOI: 10.1117/12.308151]
  96. Gibbons WD, Allen RG. Retinal damage from suprathreshold Q-switch laser exposure. *Health Phys* 1978; 35: 461-469. [PMID: 107148]; [DOI: 10.1097/00004032-197809000-00003]
  97. Newman DK, Flanagan DW. Spontaneous closure of a macular

- hole secondary to an accidental injury. *Br J Ophthalmol* 2000; 84: 1075. [PMID: 11032440]; [DOI: 10.1136/bjo.84.9.1075]
98. Sakaguchi H, Ohji M, Kubota A, et al. Amsler grid examination and optical coherence tomography of a macular hole caused by accidental Nd: YAG injury. *Am J Ophthalmol* 2000; 130: 355-356. [PMID: 11020418]; [DOI: 10.1016/s0002-9394(00)00547-x]
  99. Boldrey EE, Little HL, Flocks M, Vassiliadis A. Retinal injury due to industrial laser burns. *Ophthalmology* 1981; 88: 101-107. [PMID: 7231892]; [DOI: 10.1016/s0161-6420(81)35068-4]
  100. Roeder J, Buesgen P, Hoerauf H, et al. Macular injury by a military range finder. *Retina* 1999; 19: 531-535. [PMID: 10606454]; [DOI: 10.1097/00006982-199911000-00009]
  101. Curtin TL, Boyden DG. Reflected laser beam causing accidental burn of the retina. *Am J Ophthalmol* 1968; 65: 188-189. [PMID: 5636020]; [DOI: 10.1016/0002-9394(68)93585-x]
  102. Kitaguchi Y, Fujikado T, Kusaka S, Yamaguchi T, Mihashi T, Tano Y. Imaging of Titanium: Sapphire Laser Retinal Injury by Adaptive Optics Fundus Imaging and Fourier-Domain Optical Coherence Tomography. *Am J Ophthalmol.* 2009 Jul; 148(1): 97-104.e2. [PMID: 19327747]; [DOI: 10.1016/j.ajo.2009.01.019]
  103. Sun Z, Wen F, Li X, Wu D. Early subfoveal choroidal neovascularization secondary to an accidental stage laser injury. *Graefe's Arch Clin Exp Ophthalmol.* 2006 Jul 6.; 244(7): 888-90. [PMID: 16331483]; [DOI: 10.1007/s00417-005-0169-2]
  104. Fujinami K, Yokoi T, Hiraoka M, Nishina S, Azuma N. Choroidal neovascularization in a child following laser pointer-induced macular injury. *Jpn J Ophthalmol.* 2010 Nov 28.; 54(6): 631-3. [PMID: 21191730]; [DOI: 10.1007/s10384-010-0876-z]
  105. Milani P, Pierro L, Pece A, Marino V, Scialdone A. Retinal photoreceptor focal disruption secondary to accidental Nd: YAG laser exposure. *Int Ophthalmol.* 2011 Oct 15; 31(5): 409-12. [PMID: 22002418]; [DOI: 10.1007/s10792-011-9469-1]
  106. Brittain GP. Retinal burns caused by exposure to MIG-welding arcs: report of two cases. *Br J Ophthalmol.* 1988 Aug.; 72(8): 570-5. [PMID: 3415950]; [DOI: 10.1136/bjo.72.8.570]
  107. Sliney DH. Risks of occupational exposure to optical radiation. *Med Lav.* 2006; 97(2): 215-20. [PMID: 17017352]
  108. Magnavita N. Photoretinitis: an underestimated occupational injury. *Occup Med (Lond).* 2002 Jun.; 52(4): 223-5. [PMID: 12091589]; [DOI: 10.1093/ocmed/52.4.223]
  109. Arend O, Aral H, Reim M, Wenzel M. Welders maculopathy despite using protective lenses. *Retina.* 1996.; 16(3): 257-9. [PMID: 8789868]; [DOI: 10.1097/00006982-199616030-00014]
  110. Cellini M, Profazio V, Fantaguzzi P, Barbaresi E, Longanesi L, Caramazza R. Photic maculopathy by arc welding. A case report. *Int Ophthalmol.* 1987 Jun.; 10(3): 157-9. [PMID: 3596908]; [DOI: 10.1007/bf00139342]
  111. Power WJ, Travers SP, Mooney DJ. Welding arc maculopathy and fluphenazine. *Br J Ophthalmol.* 1991 Jul.; 75(7): 433-5. [PMID: 1854700]; [DOI: 10.1136/bjo.75.7.433]
  112. Gardner TW, Ai E, Chrobak M, Shoch DE. Photic maculopathy secondary to short-circuiting of a high-tension electric current. *Ophthalmology.* 1982 Jul.; 89(7): 865-8. [PMID: 7122058]; [DOI: 10.1016/s0161-6420(82)34712-0]
  113. Okuno T, Saito H, Ojima J. Evaluation of blue-light hazards from various light sources. *Dev Ophthalmol.* 2002.; 35: 104-12. [PMID: 12061267]; [DOI: 10.1159/000060814]
  114. Sliney DH, Gilbert DW, Lyon T, Lyon T. Ultraviolet safety assessments of insect light traps. *J Occup Environ Hyg.* Taylor & Francis; 2016.; 13(6): 413-24. [PMID: 27043058]; [DOI: 10.1080/15459624.2015.1125489]
  115. Laser News, Laws, & Civil Penalties. Federal Aviation Administration. January 13, 2015. <http://www.faa.gov/about/initiatives/lasers/laws/>. Accessed April 15, 2017.
  116. Palakkamanil MM, Fielden MP. Effects of malicious ocular laser exposure in commercial airline pilots. *Can J Ophthalmol / J Can d'Ophthalmologie.* 2015 Dec; 50(6): 429-32. [PMID: 26651301]; [DOI: 10.1016/j.cjco.2015.09.002]
  117. Gosling DB, O'Hagan JB, Quhill FM. Blue laser induced retinal injury in a commercial pilot at 1300 ft. *Aerosp Med Hum Perform* 2016; 87: 69-70. [PMID: 26735237]; [DOI: 10.3357/AMHP.4411.2016]
  118. Shenoy R, Bialasiewicz AA, Bandara A, Isaac R. Retinal Damage from Laser Pointer Misuse - Case Series from the Military Sector in Oman. *Middle East Afr J Ophthalmol.* Medknow Publications; 2015.; 22(3): 399-403. [PMID: 26180486]; [DOI: 10.4103/0974-9233.159780]
  119. Mainster MA, Stuck BE, Brown J Jr. Assessment of alleged retinal laser injuries. *Arch Ophthalmol* 2004; 122: 1210-1217. [PMID: 15302664]; [DOI: 10.1001/archoph.122.8.1210]
  120. styropyro. My Homebuilt 200W LASER BAZOOKA!!!! YouTube. <https://www.youtube.com/watch?v=IzUoe-9bKa0>. Published June 28, 2016. Accessed April 25, 2017.
  121. Wyrsh S, Baenninger PB, Schmid MK. Retinal Injuries from a Handheld Laser Pointer. *N Engl J Med.* Massachusetts Medical Society; 2010 Sep 9.; 363(11): 1089-91. [PMID: 20825327]; [DOI: 10.1056/NEJMc1005818]
  122. Consumer health information: illuminating the hazards of powerful laser products. Silver Spring, MD: Food and Drug Administration, 2009. [url: <https://www.laserpointersafety.com/LPSFiles/files/FDA-illuminating-hazards.pdf>]
  123. Ajudua S, Mello MJ. Shedding some light on laser pointer eye injuries. *Pediatr Emerg Care.* 2007; 23: 669-672. [PMID: 17876263]; [DOI: 10.1097/PEC.0b013e31814b2dc4]
  124. Ziahosseini K, Doris JP, Turner GS. Laser eye injuries: maculopathy from handheld green diode laser pointer. *BMJ* 2010; 340: 1261-1261. [PMID: 20530564]; [DOI: 10.1136/bmj.c2982]
  125. Xu K, Chin EK, Quiram PA, Davies JB, Parke DW 3rd, Almeida DR. Retinal Injury Secondary to Laser Pointers in Pediatric Patients. *Pediatrics.* 2016 Oct; 138(4). [PMID: 27587615]; [DOI: 10.1542/peds.2016-1188]
  126. Hanson JV, Sromicki J, Mangold M, Golling M, Gerth-Kahlert C. Maculopathy following exposure to visible and infrared radiation from a laser pointer: a clinical case study. *Doc Ophthalmol.* 2016 Apr; 132(2): 147-55. [PMID: 26921203]; [DOI: 10.1007/s10633-016-9530-5]
  127. Thanos S, Böhm MR, Meyer zu Hörste M, Schmidt PF. Retinal damage induced by mirror-reflected light from a laser pointer. *BMJ Case Rep.* 2015 Oct 5; 2015 [PMID: 26438673]; [DOI: 10.1136/bcr-2015-210311]
  128. Raoof N, O'Hagan J, Pawlowska N, Quhill F. "Toy" laser macular burns in children: 12-month update. *Eye.* 2016 Mar 27; 30(3): 492-6. [PMID: 26611842]; [DOI: 10.1038/eye.2015.222]
  129. Lim ME, Suelzer J, Moorthy RS, Vemuri G. Thermal macular injury from a 154 mW green laser pointer. *J AAPOS.* 2014 Dec; 18(6): 612-4. [PMID: 25448152]; [DOI: 10.1016/j.jaapos.2014.07.165]
  130. Lee GD, Baumal CR, Lally D, Pitcher JD, Vander J, Duker JS. Retinal injury after inadvertent handheld laser exposure. *Retina.* 2014 Dec; 34(12): 2388-96. [PMID: 25380069]; [DOI: 10.1097/IAE.0000000000000397]
  131. Alsulaiman SM, Alrushood AA, Almasaud J, Alzaaidi S, Alzahrani Y, Arevalo JF, et al. High-Power Handheld Blue Laser-Induced Maculopathy. *Ophthalmology.* 2014 Feb.; 121(2): 566-572.e1. [PMID: 24184164]; [DOI: 10.1016/j.ophtha.2013.09.006]
  132. Petrou P, Kanakis M, Koutsandrea C, Georgalas I, Banerjee PJ. Full-thickness macular hole secondary to high-power handheld blue laser: Natural history and management outcomes. *Am J Ophthalmol.* 2015; 160(5): 1084. [PMID: 26321171]; [DOI: 10.1016/j.ajo.2015.08.004]
  133. Alsulaiman SM, Alrushood AA, Almasaud J, Alkharashi AS, Alzahrani Y, Abboud EB, et al. Full-Thickness Macular Hole Secondary to High-Power Handheld Blue Laser: Natural History and Management Outcomes. *Am J Ophthalmol.* 2015

- Jul.; 160(1): 107-113.e1. [PMID: 24184164]; [DOI: 10.1016/j.optha.2013.09.006]
134. Abdelkader E. Accidental macular injury with class IVb laser outside the medical settings. *Saudi J Ophthalmol Off J Saudi Ophthalmol Soc.* 2016.; 30(4): 253-6. [PMID: 28003786]; [DOI: 10.1016/j.sjopt.2016.10.004]
  135. Ueda T, Kurihara I, Koide R. A case of retinal light damage by green laser pointer (Class 3b). *Jpn J Ophthalmol.* 2011 Jul 2.; 55(4): 428-30. [PMID: 21633809]; [DOI: 10.1007/s10384-011-0031-5]
  136. Turaka K, Bryan JS, Gordon AJ, Reddy R, Kwong HM, Sell CH. Laser pointer induced macular damage: case report and mini review. *Int Ophthalmol.* Springer Netherlands; 2012 Jun 1.; 32(3): 293-7. [PMID: 22466425]; [DOI: 10.1007/s10792-012-9555-z]
  137. Lally DR, Duker JS. Foveal Injury From a Red Laser Pointer. *JAMA Ophthalmol.* 2014 Mar 1.; 132(3): 297. [PMID: 24626822]; [DOI: 10.1001/jamaophthalmol.2014.34]
  138. Bhavsar KV, Wilson D, Margolis R, Judson P, Barbazetto I, Freund KB, Cunningham ET Jr. Multimodal imaging in handheld laser-induced maculopathy. *Am J Ophthalmol.* 2015 Feb; 159(2): 227-31.e2. [PMID: 25448992]; [DOI: 10.1016/j.ajo.2014.10.020]
  139. Sayman Muslubas I, Hocaoglu M, Arf S, Ozdemir H, Karaçorlu M. Macular Burns from Nonmedical Lasers. *Turkish J Ophthalmol.* Galenos Yayinevi; 2016 Jun.; 46(3): 138-43. [PMID: 27800276]; [DOI: 10.4274/tjo.29577]
  140. Qi Y, Wang Y, You Q, Tsai F, Liu W. Surgical treatment and optical coherence tomographic evaluation for accidental laser-induced full-thickness macular holes. *Eye (Lond).* 2017 Mar 10. [PMID: 28282068]; [DOI: 10.1038/eye.2017.41]
  141. Zhang L, Zheng A, Nie H, Bhavsar K V, Xu Y, Sliney DH, et al. Laser-Induced Photocopy Macular Dystrophy. *Ophthalmic Genet.* 2016.; 37(1): 59-67. [PMID: 26927809]; [DOI: 10.3109/13816810.2015.1059458]
  142. Zhao N, Liu L. Long-term changes in optic coherence tomography in a child with laser pointer maculopathy: A case report and mini review. *Photodiagnosis Photodyn Ther.* 2017 Jun 24.; 18: 264-6. [PMID: 28347866]; [DOI: 10.1016/j.pdpdt.2017.03.012]
  143. Liang L, Cui Z, Lu C, Hao Q, Zheng Y. Damage to the macula associated with LED-derived blue laser exposure: A case report. *BMC Ophthalmol.* 2017 Apr 24; 17(1): 49. [PMID: 28438153]; [DOI: 10.1186/s12886-017-0448-9]
  144. Bhavsar KV, Wilson D, Margolis R, Judson P, Barbazetto I, Freund KB, Cunningham ET Jr. Multimodal imaging in handheld laser-induced maculopathy. *Am J Ophthalmol.* 2015 Feb; 159(2): 227-31.e2. [PMID: 25448992]; [DOI: 10.1016/j.ajo.2014.10.020]
  145. Sayman Muslubas I, Hocaoglu M, Arf S, Ozdemir H, Karaçorlu M. Macular Burns from Nonmedical Lasers. *Turkish J Ophthalmol.* Galenos Yayinevi; 2016 Jun.; 46(3): 138-43. [PMID: 27800276]; [DOI: 10.4274/tjo.29577]
  146. Keunen JEE, Delbecq A-LMH, Cruysberg JRMH, van Meurs JC, Gan IM, Berendschot TTJM. Laser pointers are not toys; eye injury with permanent loss of visual acuity. *Ned Tijdschr Geneesk.* 2014.; 158: A7813. [PMID: 25308223]
  147. Zheng X, Xie P, Hu Z, Zhang W, Liang K, Wang X, et al. Phototoxic maculopathy induced by quartz infrared heat lamp. *Medicine (Baltimore).* 2017 Jan.; 96(3): e5830. [PMID: 28099337]; [DOI: 10.1097/MD.0000000000005830]
  148. Tomasso L, Benatti L, La Spina C, Lattanzio R, Baldin G, Carnevali A, De Vitis LA, Querques L, Bandello F, Querques G. Optical coherence tomography angiography findings in laser maculopathy. *Eur J Ophthalmol.* 2017 Jan 19; 27(1): e13-e15. [PMID: 28009410]; [DOI: 10.5301/ejo.5000844]
  149. Combillet F, Saunier V, Rougier MB, Delyfer MN, Korobelnik JF. Multimodal imaging in a case of self-inflicted laser-induced maculopathy. *Eur J Ophthalmol.* 2016 Nov 4; 26(6): e155-e157. [PMID: 27445068]; [DOI: 10.5301/ejo.5000825]
  150. Mainster MA. Solar retinitis, photic maculopathy and the pseudophakic eye. *J Am Intraocul Implant Soc.* 1978 Jul.; 4(3): 84-6. [PMID: 701182]; [DOI: 10.1016/s0146-2776(78)80112-8]
  151. Thanos S, Heiduschka P, Romann I. Exposure to a solar eclipse causes neuronal death in the retina. *Graefes Arch Clin Exp Ophthalmol.* 2001 Oct.; 239(10): 794-800. [PMID: 11760043]; [DOI: 10.1007/s004170100362]
  152. Sui GY, Liu GC, Liu GY, et al. Is sunlight exposure a risk factor for age-related macular degeneration? A systematic review and meta-analysis. *Br J Ophthalmol.* 2013; 97: 389-394. [PMID: 23143904]; [DOI: 10.1136/bjophthalmol-2012-302281]
  153. Mwanza JC, Kayembe DL, Kaimbo DK, Kabasele PM, Ngoy DK. Solar retinopathy acquired after gazing at the sun during prayers. *Bull Soc Belge Ophtalmol.* 2000.; 275: 41-5. [PMID: 10853306]
  154. Agarwal LP, Malik SR. Solar retinitis. *Br J Ophthalmol.* 1959; 43: 366-370. [PMID: 13662561]; [DOI: 10.1136/bjo.43.6.366]
  155. Mehlan J, Linke S, Wagenfeld L, Steinberg J. Einseitige solare Makulopathie nach Sonnenfinsternis. *Klin Monbl Augenheilkd.* (English version) 2016 Apr 7.; 233(6): 749-52. [PMID: 27055491]; [DOI: 10.1055/s-0042-100211]
  156. Moran S, O'Donoghue E. Solar retinopathy secondary to sungazing. *Case Reports.* 2013 Jan 25.; 2013(jan25 1). [PMID: 23355595]; [DOI: 10.1136/bcr-2012-008402]
  157. Ewald RA. Sun gazing associated with the use of LSD. *Ann Ophthalmol.* 1971; 3: 15-17. [PMID: 5163945]
  158. Anaclerio AM, Wicker HS. Self-induced solar retinopathy by patients in a psychiatric hospital. *Am J Ophthalmol.* 1970; 69: 731-736. [PMID: 5441348]; [DOI: 10.1016/0002-9394(70)93412-4]
  159. Seet B, Wong TY. Military laser weapons: current controversies. *Ophthalmic Epidemiol* 2001 Sep; 8(4): 215-26. [PMID: 11471090]; [DOI: 10.1076/opep.8.4.215.1610]
  160. 160 Additional Protocol to the Convention on Prohibitions or Restrictions on the Use of Certain Conventional Weapons which may be deemed to be Excessively Injurious or to have Indiscriminate Effects (Protocol IV, entitled Protocol on Blinding Laser Weapons)". United Nations Treaty Collection. July 30, 1998. [url: [https://treaties.un.org/pages/ViewDetails.aspx?src=TREATY&mtsg\\_no=XXVI-2-a&chapter=26](https://treaties.un.org/pages/ViewDetails.aspx?src=TREATY&mtsg_no=XXVI-2-a&chapter=26)]
  161. 161 Carnahan BM, Robertson M. "The Protocol on "Blinding Laser Weapons": A New Direction for International Humanitarian Law". *The American Journal of International Law.* 90 (3): 484-490. Jul 1996. [DOI: 10.2307/2204074]
  162. Vienna Diplomatic Conference Achieves New Prohibition on Blinding Laser Weapons and Deadlock on Landmines". *International Committee of the Red Cross.* 13 Oct 1995.
  163. Marshall J. Blinding laser weapons: Still available on the battlefield. *BMJ.* 1997 Nov 29; 315(7120): 1392.
  164. Seet B, Wong TY. Military laser weapons: current controversies. *Ophthalmic Epidemiol.* 2001 Sep; 8(4): 215-26. [PMID: 11471090]; [DOI: 10.1076/opep.8.4.215.1610]
  165. Peters A. Blinding laser weapons. *Med Confl Surviv.* 1996 Apr-Jun; 12(2): 107-13. [PMID: 8925488]; [DOI: 10.1080/13623699608409267]
  166. Zwaan J. Blinding laser weapons. *Ophthalmic Surg Lasers.* 1997 Jan; 28(1): 79-80. [PMID: 9031313]
  167. Peters A. Blinding laser weapons. *Med Confl Surviv.* 1996 Apr-Jun; 12(2): 107-13. [PMID: 8925488]; [DOI: 10.1080/13623699608409267]
  168. Gillow JT. Another weapon too far: the anti-personnel laser. *J R Soc Med.* 1995 Jun; 88(6): 347P-349P. [PMID: 7629769]
  169. Gumbel H. Curse and blessing of combat ophthalmology in the 20th and 21st centuries. *Klin Monbl Augenheilkd.* 2009 Aug; 226(8): 624-8. [PMID: 19672807]; [DOI: 10.1055/s-0028-1109473]