

## The Added Value Of SPECT/CT In Dacryoscintigraphy for the Diagnosis of Nasolacrimal Duct Obstruction: Differentiation Between Obstruction Localization And Radiation Contamination

Martin Law, Tze-Chung Chan, Irene Wong, Wai-Han Ma, Francis Go, Wai-Yin Ho, Wendy Lam

Martin Law, Tze-Chung Chan, Irene Wong, Wai-Han Ma, Francis Go, Wai-Yin Ho, Wendy Lam, Department of Radiology, Queen Mary Hospital, 102 Pokfulam Road, Hong Kong  
Correspondence to: Martin Law, Department of Radiology, Queen Mary Hospital, 102 Pokfulam Road, Hong Kong  
Email: lawwm@ha.org.hk  
Telephone: +852-2255-4215 Fax: +852-2255 3872  
Received: November 22, 2015 Revised: January 30, 2016  
Accepted: February 3, 2016  
Published online: March 10, 2016

### ABSTRACT

Epiphora, an abnormal overflow of tears, is commonly caused by tear drainage system anomalies including nasolacrimal duct obstruction. To evaluate the function of the system, dacryoscintigraphy is a commonly available non-invasive method under a nuclear medicine dynamic acquisition. We recommend the use of SPECT/CT after the dynamic acquisition to localize the obstruction site and to differentiate that tear overflow is not due to radiation contamination as sometimes encountered in dacryoscintigraphy. A case is presented to support the use of SPECT/CT in the protocol.

© 2016 ACT. All rights reserved.

**Key words:** SPECT/CT, Dacryoscintigraphy; Nasolacrimal duct obstruction; Localization

Law M, Chan TC, Wong I, Ma WH, Go F, Ho WY, Lam W. The Added Value Of SPECT/CT In Dacryoscintigraphy for the Diagnosis of Nasolacrimal Duct Obstruction: Differentiation Between Obstruction Localization And Radiation Contamination. *International Journal of Radiology* 2015; 3(1): 106-108 Available from: URL: <http://www.ghrnet.org/index.php/ijr/article/view/1025>

### INTRODUCTION

Dacryoscintigraphy is a useful method to assess the patency of nasolacrimal drainage pattern and to evaluate the success of dacryocystorhinostomy treatment to the obstruction<sup>[1-2]</sup>. Although dacryoscintigraphy is regarded as an underutilized and infrequently performed study, experience to enhance the clinical application has always been shared in literature<sup>[3-6]</sup>. Because of the obstruction, small amount of radioactive tracer would sometimes overflow to drain along skull surface and to mask the nasolacrimal duct. Fused images after SPECT/CT imaging can localize the site of obstruction and of radiation contamination due to overflow of radioactive tracer.

### CASE REPORT

A 64 year-old male patient with the history of bilateral epiphora was referred to our department for dacryoscintigraphy imaging. Following instillation of one drop of technetium pertechnetate (<sup>99m</sup>TcO<sub>4</sub> of concentration of 4 MBq/ml) in the inferior fornix of the eyes (outer canthus of both eyes), dynamic imaging with the patient in an erect position was performed (1 minute/frame for 15 minutes) using low energy high resolution collimator mounted onto a single head gamma camera (Siemens Symbia). The dynamic images showed accumulation of the tracer in the lacrimal sacs bilaterally without any progression into the lacrimal ducts for the first 15 minutes (Figure 1), compatible with bilateral lacrimal apparatus obstruction at the sac-duct level.

Delayed imaging at 25 minutes showed similar finding but a track of radioactive tracer images was observed running along the facial skin surface (Figure 2). As this track of the image masked part of the lacrimal duct, the degree of obstruction at the delayed images at the right eye could not be concluded from this serial dynamic scan.

The patient was then placed under SPECT/CT imaging (GE Infinia-4; CT imaging: 120 kVp, 2.5 mA; emission: 140 keV photon peak, 20 sec/frame for 360° acquisition, 3° interval). Fused images of SPECT/CT clearly localized the obstruction site and differentiated

the possibility of radiation contamination by overflow of radiolabeled tracer. The obstructed site would appear along the lacrimal duct and the contamination would appear on the superficial surface of the skull image (Figure 3). Figure 4 shows the bilateral lacrimal apparatus obstruction at the sac-duct level from the fused SPECT/CT image.

### LENS DOSE DUE TO CT COMPONENT OF SPECT/CT

As described in this article, the use of SPECT/CT facility would help differentiate between the true obstruction and radiation contamination. However CT dose to eye lenses is a concern if SPECT/CT is used. We measured the lens dose using a head phantom on which mosfet detectors were placed on both eyes of the head phantom. The same measuring procedures were repeated for various SPECT/CT machines. Average lens doses were measured as 2 mSv per eye for the GE Infinia-4 system, 4 mSv per eye for Siemens T-6 and 64 mSv per eye for GE-D670 system. It is therefore suggested to use SPECT/CT system with low dose CT component to minimize the lens dose.

### CONCLUSION

Dacryoscintigraphy is a simple investigation providing high sensitivity in epiphora detection in patients before and after dacryocystorhinotomy. It is indeed not surprising to observe the overflow of radioactive tracer running along the facial surface to mask the lacrimal duct during the dacryoscintigraphy. SPECT/CT can help localize the obstruction site and radiation contamination area. We suggest that it is firstly to perform dynamic imaging because radioactive tracer can drain along the nasolacrimal duct by gravity while patient is in an erect position. SPECT/CT preferably with low dose CT component has its value to demonstrate the blockage location and importantly to differentiate the actual blockage from possible radiation contamination, the latter of which is sometimes unavoidable in dacryoscintigraphy procedure.

### ACKNOWLEDGEMENT

Part of the article was presented in European Congress of Radiology 2015.

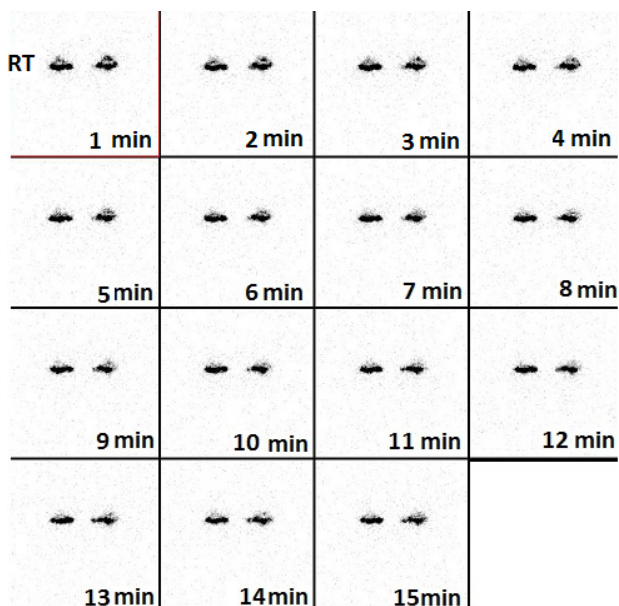


Figure 1 Dynamic scan showing obstruction at both eyes for the first 15 minutes after instillation.

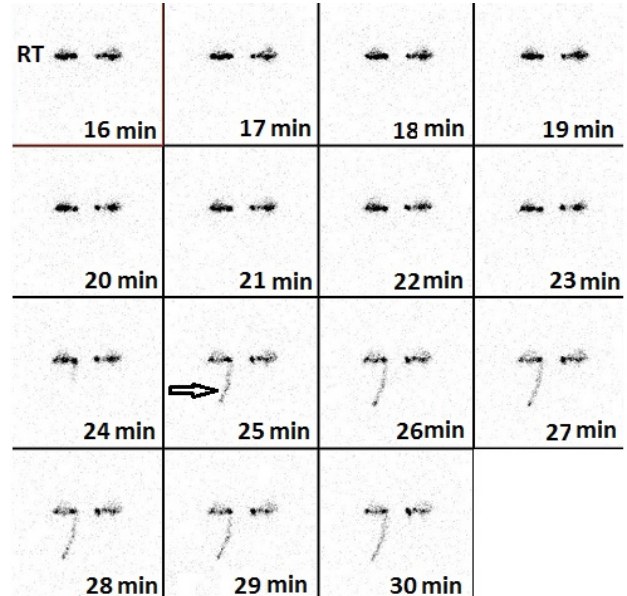


Figure 2 Spillage of radioactive tracer at the right eye at 25 minutes after instillation and the spillage might mask the partial obstruction at the right eye.

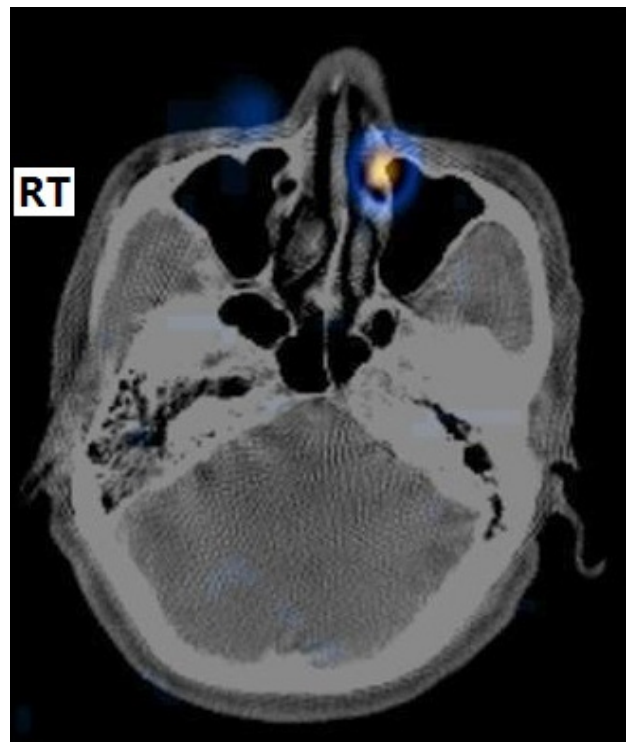
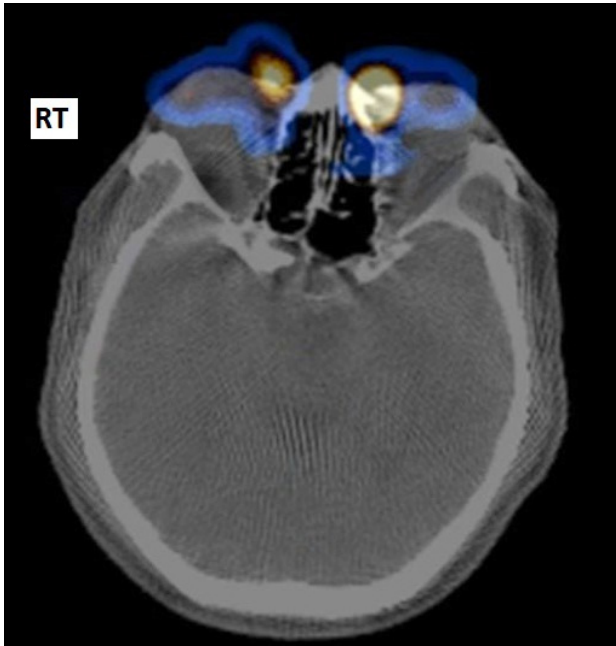

Figure 3 The obstructed site would appear along the lacrimal duct and the contamination would appear on the superficial surface of the skull image on the right eye for the case presented.

### CONFLICT OF INTEREST

All the authors of the manuscript entitled ‘The added value of SPECT/CT in dacryoscintigraphy for the diagnosis of nasolacrimal duct obstruction: differentiation between obstruction localization and radiation contamination’ declare that there is no conflict of interest with regard to equipment, contrast, drug and other materials described in this article.



**Figure 4** Bilateral lacrimal apparatus obstruction at the sac-duct level as observed from the fused SPECT/CT image.

## REFERENCES

- 1 Palaniswamy SS, Subramanyma P. Dacryoscintigraphy: an effective tool in the evaluation of postoperative epiphora. *Nucl Med Comm* 2012; **33**: 262-267.
- 2 Chung YA, Yoo Ie R, Oum JS, Kim SH, Sohn HS, Chung SK. The clinical value of dacryoscintigraphy in the selection of surgical approach for patients with functional lacrimal duct obstruction. *Ann Nucl Med* 2005; **19**: 479-483.
- 3 Brandon D, Maa A. Dacryoscintigraphy: Rediscovering an underutilized test. *J Nucl Med* 2013; **54** (Supplement 2): 1269.
- 4 MacDonald A, Burrell S. Infrequently performed studies in nuclear medicine: Part I. *J Nucl Med Technol* 2008; 132-134.
- 5 Ayati NK, Malekshahi RG, Zakavi SR, Kakhka VRD, Aryana K, Sadeghi R. Systemic absorption of Tc-99m-pertechnetate during dacryoscintigraphy: A note of caution. *Orbit* 2010; **29**: 269-270.
- 6 Kennedy-Beke A, Szabados L, Marna S, Varga J, Galuska L, Kettesy B, Gesztelyi R *et al.* Simultaneous dacryocystography and dacryoscintigraphy using SPECT/CT in the diagnosis of nasolacrimal duct obstruction. *Clin Nucl Med* 2012; **37**: 609-610.