

## Cardiac CT for Assessment of Myocardial Geometry before and after Surgical Repair of Apical Left Ventricular Aneurysm

Valeria Sidjuk, Rainer Röttgen

Valeria Sidjuk, Rainer Röttgen, Charite University Medical Center, Klinik für Strahlenheilkunde, Charite' Campus Virchow, Augustenburger Platz 1, 13353, Berlin, Germany

Correspondence to: Rainer Röttgen, PhD, MD, Radiologisches Zentrum Kurfürstendamm 37, 10719 Berlin, Germany

Email: [rainer\\_roettgen@web.de](mailto:rainer_roettgen@web.de)

Telephone: +49-171-4985101 Fax: +49-30-8821541

Received: December 6, 2015 Revised: January 30, 2016

Accepted: February 3, 2016

Published online: March 7, 2016

### ABSTRACT

**AIM:** To assess left ventricular volumetric, morphologic, and functional changes after surgical restoration of anteroapical left ventricular aneurysm using MSCT.

**MATERIAL AND METHODS:** 35 patients with anteroapical LV aneurysm were assessed by MSCT before and shortly after surgery measuring sphericity index (SI; short-to-long axis ratio), apical concity index (ACI; apical-to-short axis length ratio), apical concity ratio (ACR; ratio of apical area to apical triangle) as well as LV function, thickness and thickening of systolic and diastolic LV basal myocardium and LV end-systolic and end diastolic volumes.

**RESULTS:** After surgical repair there were statistically significant reductions of absolute and indexed LV volumes ( $p < 0.05$ ): LV-EDVI mean  $-33,7 \pm 17$  %, LV-ESVI mean  $-39.05 \pm 20.0$  %. LV-EF increased significantly by 28.88 % ( $p = 0,00$ ). Significant reduction of wall thickness during end-systole ( $p = 0.009$ ) and end-diastole ( $p = 0.034$ ) and significant increase of diastolic SI ( $p < 0.05$ ) were observed as well as a significant decline in systolic ( $p = 0.007$ ) and diastolic ( $p = 0.005$ ) ACI and a significant increase in systolic ( $p = 0.026$ ) and diastolic ( $p = 0.038$ ) ACR.

**CONCLUSIONS:** After surgical LV restoration, MSCT demonstrates significant reduction of LV volume and a reduction of wall thickness leading to improved LV function and a more efficient morphologic LV shape. Postoperative SI increases, probably due to

shortened LV long axis. ACI decline and ACR increase indicate a return toward a more ellipsoid shape after LV repair.

© 2016 ACT. All rights reserved.

**Key words:** Left ventricular aneurysm; MSCT; Aneurysmectomy; Surgical restoration

Sidjuk V, Röttgen R. Cardiac CT for Assessment of Myocardial Geometry before and after Surgical Repair of Apical Left Ventricular Aneurysm. *International Journal of Radiology* 2015; 3(1): 95-101 Available from: URL: <http://www.ghrnet.org/index.php/ijr/article/view/1511>

### INTRODUCTION

Myocardial infarction can lead to scarring of affected myocardial segments with subsequent development of an aneurysm<sup>[1]</sup>. An apical cardiac aneurysm forms in the area of a scar localized at the tip of the heart and is characterized by wall thinning and akinetic or dyskinetic wall motion<sup>[2]</sup>. Enlargement and abnormal configuration of the ventricle results in dilatation of initially unaffected myocardial segments with markedly reduced pump function. Many of these patients will develop cardiac insufficiency<sup>[3,4]</sup>. Traditional treatment with ACE inhibitors<sup>[5]</sup> often turns out to be inadequate in patients with left ventricular (LV) aneurysm. These patients can undergo surgical repair of the ventricle<sup>[6]</sup>. LV reconstruction according to Dor has become the established surgical approach<sup>[7]</sup> and aims at restoring the normal elliptical configuration of the ventricle. This in turn will normalize ventricular volume loading, thereby preventing remodeling and reducing wall tension. The ultimate aim of surgical repair is to restore effective cardiac function<sup>[8]</sup>. Echocardiography and magnetic resonance imaging (MRI) have become the gold standard of cardiac imaging for diagnostic assessment and treatment planning<sup>[9]</sup> while dual-source computed tomography (CT) enables efficient evaluation of cardiac morphology<sup>[10]</sup>.

In the present study, we used dual-source CT to assess the outcome of aneurysm repair and ventricular restoration in terms of function, wall characteristics, and ventricle configuration. We determined and compared the sphericity index (SI), the apical conicity index (ACI), and the apical conicity ratio (ACR) to characterize LV geometry before and after surgical aneurysm repair. The SI describes the ratio of the ventricular short axis to the long axis<sup>[11]</sup> (Figure 1). A normal ellipsoid LV has an SI of approx. 0.5. A dilated LV becomes more spherical and has a higher SI because its short axis becomes longer. The more spherical the ventricle, the higher the SI, with an SI of 1 indicating that the short and long axis are of the same length<sup>[11]</sup>. The ACI is the ratio of the apical axis (diameter of a circle fitted to the apex) to the short axis. A normal ventricle is conical in configuration, and the apical diameter is several times smaller than the short axis, resulting in a rather small ACI. When the apex becomes dilated due to aneurysm, the apical diameter increases as does the ACI<sup>[12]</sup> (Figure 2). The ACR is the ratio of the left ventricular apical area to the idealized apical triangle and should be close to 1 (Figure 3a and b). An LV aneurysm results in a larger apical area and hence a higher ACR<sup>[13]</sup>.

## MATERIAL AND METHODS

### Patient selection

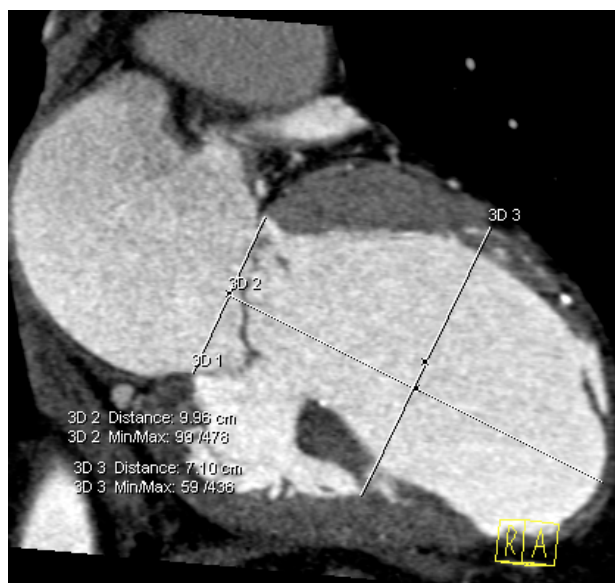Our retrospective analysis is based on data of patients who underwent surgical repair for apical LV aneurysm at the German Heart Center Berlin (GHCB) from June 2006 through July 2009. The patients included had a preoperative CT scan as well as a short-term follow-up CT obtained 3-35 days after surgery (median 7 days). The indication for surgical restoration was established on the basis of clinical data, echocardiography findings, and assessment of cardiac function and aneurysm size by CT.

### MSCT data acquisition and postprocessing

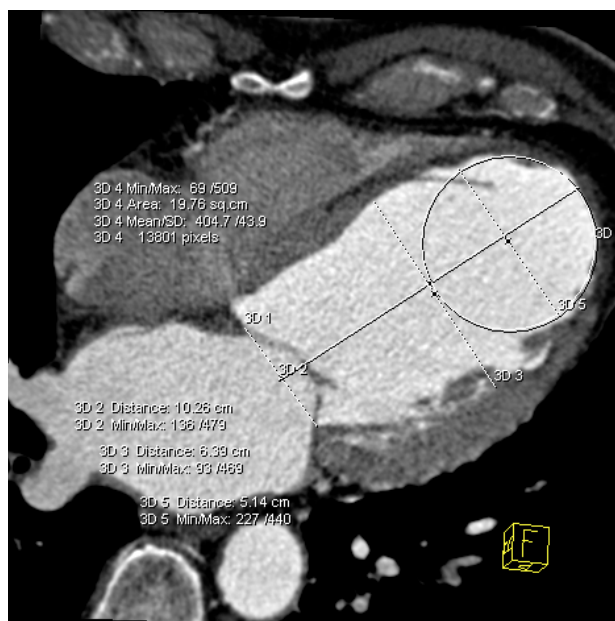
An experienced examiner performed the multislice computed tomography (MSCT) examinations on a dual-source CT scanner (Siemens, Germany). Image acquisition was triggered using bolus tracking performed by means of a dedicated software tool (ROI)<sup>[14]</sup>. Contrast medium arrival was determined in a region of interest (ROI) placed in the aorta following injection of a dose of 100 ml of contrast medium at a rate of 5-6 mL/s. Image acquisition was triggered with a delay of 6 s. The scan duration was 7 to 12 s with breath-hold using retrospective ECG gating. The datasets were reconstructed throughout the cardiac cycle at 10% intervals using a slice thickness of 0.75 mm. Postprocessing and image analysis were performed using a semiautomatic to fully automatic software tool (Syngo Circulation, Siemens Medical Solutions, Forchheim, Germany). Images with poor depiction of the trabecular structure and inadequate delineation of myocardium from the cardiac cavities were excluded from analysis. Images were analyzed using reconstructed two-chamber, four-chamber, and short-axis views.

### Analysis of Datasets

Ventricular assessment and determination of functional parameters were performed in accordance with the guidelines of the Cardiac Imaging Committee of the American Heart Association (AHA)<sup>[15]</sup> using the semiautomatic postprocessing tool Syngo Circulation. This tool allows automatic separation of the cardiac chambers and myocardium with manual correction by the examiner. First, the phases of end-systole (ES) and end-diastole (ED) were identified based on the definition of the smallest and largest ventricular

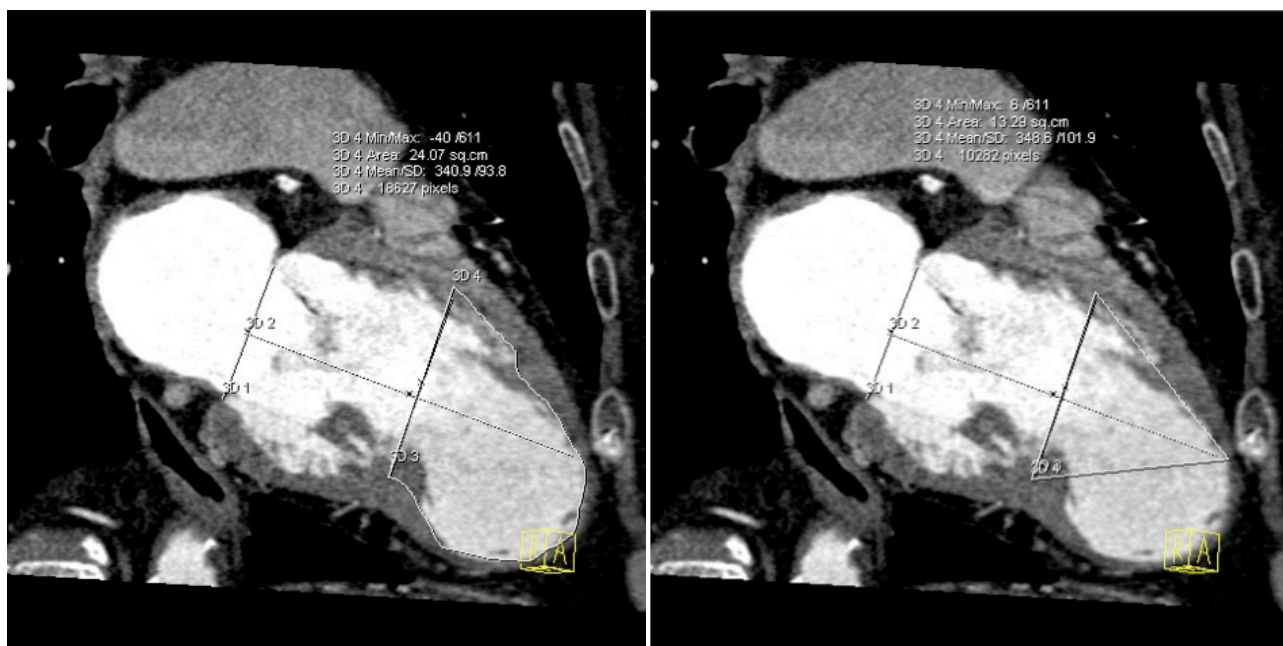


**Figure 1** Calculation of the sphericity index (SI). Example illustrating the method used here for SI determination using the two-chamber view. Measurement of the longitudinal axis from the apex to a line drawn at the level of the mitral valve (LA). The diameter is measured perpendicular to this line in the mid-LA (SA).  $SI = SA/LA$ .

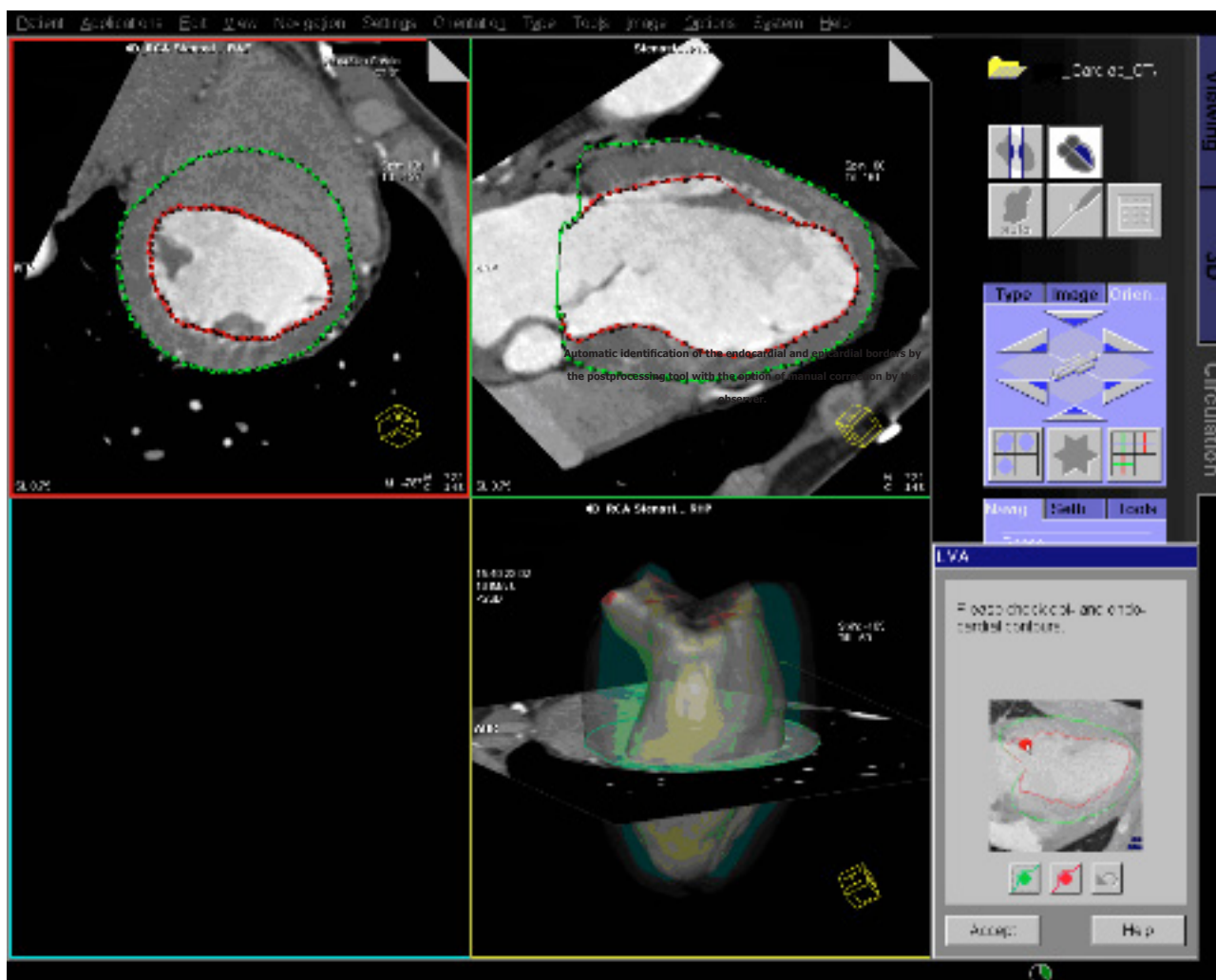


**Figure 2** Calculation of the apical conicity index (ACI) from the four-chamber view. The long axis (LA) and short axis (SA) are drawn. Then a circle is fitted into the apical LV portions within the endocardial borders and its diameter is measured. The ratio of the diameter to the short axis gives the ACI.

volumes. Next, the resulting reconstructions were segmented into 2D slices with automatic drawing of the contours of the endocardium and epicardium and manual correction as needed (Figure 4). The papillary muscles were included in the ventricular volume. After these processing steps, left ventricular end-systolic and end-diastolic volumes (LV-ESV, LV-EDV) could be determined and functional parameters - ejection fraction (EF) and cardiac index (CI) - were derived. For standardized evaluation of the heart, the 17-segment model of the AHA was used<sup>[15]</sup>. Wall thickness and wall thickening could be determined for any point in the 17 segments (Figure 5). For assessment of wall morphology in the basal LV portions, five

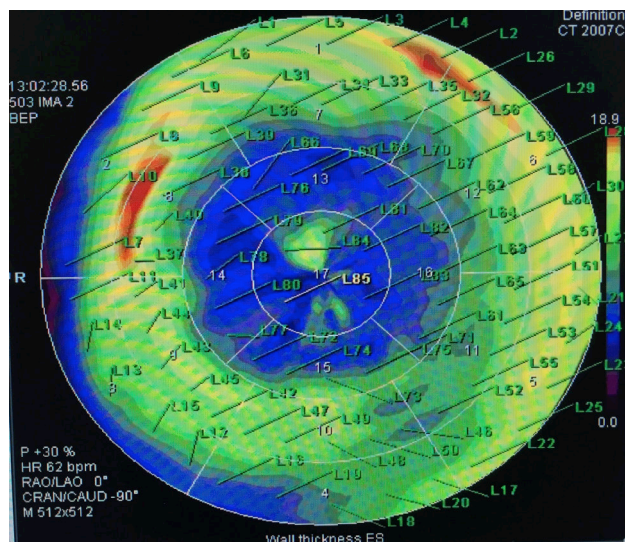


**Figure 3** Calculation of the apical conicity ratio (ACR). Example illustrating the method used here for determining the ACR. Ratio of the true apical area (3a) to the idealized apical triangle (3b).



**Figure 4** Automatic identification of the endocardial and epicardial borders by the postprocessing tool with the option of manual correction by the observer.





**Figure 5** Display of wall thickness using Syngo Circulation. For any one point, the wall thickness is given in mm. The example shows the situation during end-systole (the values are not given in the image).

points were selected from the six basal segments for which end-systolic and end-diastolic wall thickness and wall thickening were determined. The selected points were in one plane in the outer thirds of the segments. The points were selected with a view to accounting for the changing ventricular geometry during the cardiac cycle. With this arrangement, it was ensured that the sites of measurement to be assessed by the Syngo Circulation tool remained within their segments. The values derived in this way were used to calculate mean values for each segment and the cardiac base. Only the values of basal segments 1 to 6 were taken into account, as comparability of the apical segments is limited due to the different geometry following surgical repair. The measured values served to calculate SI, ACI, and ACR.

**Statistical Analysis**

Statistical analysis was performed using SPSS version 19.0 (Chicago, ILL, USA). Significance was assumed at  $p < 0.05$ . Preoperative and postoperative values were compared using the Wilcoxon test for paired samples, and mean values, frequency, and standard deviation (SD) are presented for descriptive characterization of individual segments.

**RESULTS**

The MSCT data of 35 patients (30 men, 5 women) ranging in age from 27 – 87 years (median 62 years) who underwent left ventricular restoration during the study period were included in the analysis.

Analysis of left ventricular volume changes after surgical repair showed a marked decrease in absolute and indexed volumes during both end-systole (LV-ESV, LV-ESVI) and end-diastole (LV-EDV, LV-EDVI); the difference was statistically significant ( $p = 0.000$ ). LV-ESV decreased from a mean of  $228.44 \pm 117.97$  ml/m<sup>2</sup> preoperatively to a mean of  $135.33 \pm 79.89$  ml/m<sup>2</sup> postoperatively, while left-ventricular volume decreased from a median of  $310.44 \pm 122.2$  mL/m<sup>2</sup> during diastole (LV-ESV) to a mean of  $200.94 \pm 83.87$  ml/m<sup>2</sup> (Table 1).

With regard to functional parameters, the average left-ventricular ejection fraction (LV-EF) increased significantly from  $29.64 \pm 11.73$  % before surgery to  $36.75 \pm 14.24$  % after surgery ( $p = 0.000$ ), while

**Table 1** CT-based parameters obtained before and after left ventricular restoration (mean  $\pm$  standard derivation).

Parameter	Preoperative (mean $\pm$ SD)	Postoperative (mean $\pm$ SD)	Change (in %)	p-Value
LV-ESV (ml/m <sup>2</sup> )	228.44 $\pm$ 117.97	135.33 $\pm$ 79.89	-37.6 $\pm$ 21.2	< 0.05
LV-ESVI (ml/m <sup>2</sup> )	115.57 $\pm$ 56.1	68.97 $\pm$ 37.99	-39.1 $\pm$ 20.6	< 0.05
LV-EDV (ml/m <sup>2</sup> )	310.44 $\pm$ 122.2	200.94 $\pm$ 83.87	-32.4 $\pm$ 17.8	< 0.05
LV-EDVI (ml/m <sup>2</sup> )	159.51 $\pm$ 57.12	103.26 $\pm$ 38.87	-33.8 $\pm$ 17.5	< 0.05
LV-EF (%)	29.64 $\pm$ 11.73	36.75 $\pm$ 14.24	48.9 $\pm$ 41.7	< 0.05
SV (ml)	82 $\pm$ 19.44	65.61 $\pm$ 20.32	-17.9 $\pm$ 22.7	< 0.05
Cardiac output (l/min)	5.54 $\pm$ 1.16	5.72 $\pm$ 1.38	5.5 $\pm$ 24.5	0.268
CI (ml/min/m <sup>2</sup> )	2.83 $\pm$ 0.53	2.98 $\pm$ 0.77	6.6 $\pm$ 24.7	0.179
SI systole	0.5 $\pm$ 0.10	0.5 $\pm$ 0.12		> 0.05
SI diastole	0.62 $\pm$ 0.07	0.72 $\pm$ 0.11		< 0.05
ACI systole	0.92 $\pm$ 0.36	0.72 $\pm$ 0.20		0.007
ACI diastole	0.74 $\pm$ 0.15	0.63 $\pm$ 0.18		0.005
ACR systole	1.8 $\pm$ 0.32	1.6 $\pm$ 0.22		0.026
ACR diastole	1.5 $\pm$ 0.14	1.5 $\pm$ 0.19		0.038

**Table 2** Changes in wall thickness and wall thickening of LV basal segments in end-systole (ES) and end-diastole (mean  $\pm$  standard derivation (SD)).

Parameter	Preoperative (mean $\pm$ SD)	Postoperative (mean $\pm$ SD)	Change (in %)	p-Value
Basal wall thickness in ES (mm)	14.11 $\pm$ 1.89	15.26 $\pm$ 2.96	8.2 $\pm$ 15.59	0.009
Basal wall thickness in ED (mm)	11.05 $\pm$ 2.13	11.78 $\pm$ 1.78	39.9 $\pm$ 24.15	0.034
Wall thickening (mm)	4.38 $\pm$ 1.06	4.55 $\pm$ 1.32	8.7 $\pm$ 42.3	0.743

stroke volume (SV) decreased significantly ( $p = 0.000$ ). In contrast, there was no significant change in cardiac output (CO) and cardiac index (CI) (Table 1).

A significant increase in wall thickness was observed in the basal segments of the left ventricle during end-systole ( $14.11 \pm 1.89$  mm vs  $15.26 \pm 2.96$  mm;  $p = 0.009$ ) and end-diastole ( $11.05 \pm 2.13$  mm vs  $11.78 \pm 1.78$  mm;  $p = 0.034$ ), which was interpreted to indicate a postoperative decrease in wall tension. In contrast, there was no statistically significant change in wall thickening during systole ( $p = 0.743$ ) with an average increase of 8.7% (Table 2).

Significant increases in the mean diastolic sphericity index (SI) from  $0.62 \pm 0.07$  to  $0.72 \pm 0.11$  ( $p < 0.05$ ), regardless of the plane, could be attributable to a shortening of the longitudinal axis of the LV after reconstruction. In contrast, mean systolic SI did not change significantly but was nearly constant with  $0.5 \pm 0.1$  preoperatively and  $0.5 \pm 0.12$  postoperatively. The apical conicity index (ACI) was significantly lower after surgery during both systole and diastole ( $0.92 \pm 0.36$  vs  $0.72 \pm 0.20$ ;  $p = 0.007$  and  $0.74 \pm 0.15$  vs  $0.63 \pm 0.18$ ;  $p = 0.005$ ), suggesting a trend toward an ellipsoid configuration of the LV after reconstruction. The mean apical conicity ratio (ACR) also showed a significant decrease during systole ( $1.8 \pm 0.32$  vs  $1.6 \pm 0.22$ ;  $p = 0.026$ ) and during diastole ( $1.5 \pm 0.14$  vs  $1.5 \pm 0.19$ ;  $p = 0.038$ ), which is another indicator of a return to a more elliptical shape of the ventricle (Table 1).

**DISCUSSION**

In our study population, surgical repair of apical left ventricular aneurysm and ventricular reconstruction resulted in significantly lower absolute LV volumes and indexed volumes (volumes normalized to the body surface) compared with preoperative values. This observation is consistent with the results of the RESTORE (Reconstructive Endoventricular Surgery returning Torsion Original

Radius Elliptical shape) study, which was conducted in a large population of 1198 patients<sup>[16]</sup>. As already proposed by Di Donato *et al.*, the observed postoperative volume reduction is largely attributable to aneurysm removal<sup>[17,18]</sup>. The excision of scar tissue reduces the circumference of the left ventricle, resulting in a smaller LV volume and diameter. This in turn lowers wall tension, which – according to Laplace’s law – is directly proportional to ventricular diameter<sup>[19,20]</sup>. Lowering of ventricular volume, one of the most important risk factors for early or late mortality after myocardial infarction<sup>[21,22]</sup>, is associated with a concomitant decrease in wall tension – another desirable effect – which in turn reduces myocardial loading and its oxygen reserve<sup>[16]</sup>.

Basal wall thickness increased significantly during end-systole but most markedly during end-diastole. As, according to Laplace’s model, wall tension is inversely proportionate to wall thickness<sup>[19]</sup>, this means that the postoperative decrease in wall tension was most pronounced in end-diastole. These postoperative changes improve oxygen supply to basal portions of the left ventricle. In line with the improved wall characteristics and better postoperative contractility we observed after surgical repair, Di Donato *et al.*, investigating changes in contraction and relaxation in wall segments unaffected by myocardial infarction, observed a significant decrease in wall motion dysfunction or even intact function after surgical correction<sup>[17]</sup>.

The postoperative improvement of LV function we observed in the form of a significant increase in LV ejection fraction (of nearly 29%) reproduces the results of earlier studies such as that of the RESTORE group, who found nearly identical functional parameters with a preoperative LV-EF of  $29.6 \pm 11.0\%$  and  $39.5 \pm 12.3\%$  postoperatively. The RESTORE group also investigated survival after surgical repair and found an ejection fraction  $< 30\%$  to be an important risk factor for a fatal event<sup>[16]</sup>. In this respect, there was a clear indication for left ventricular reconstruction after LV aneurysm in our study patients. In the CHARM study (The Candesartan in Heart failure: Assessment of Reduction in Mortality and morbidity), which included a study population of 7599, a 10% decrease in EF (in patients with an EF  $< 45\%$ ) was found to be associated with a 39% higher mortality risk<sup>[23]</sup>. The STICH study (surgical treatment of ischemic heart failure) is another example of a study that found a significant increase in ejection fraction after aneurysm repair in patients with an akinetic or dyskinetic ventricle following myocardial infarction and who were investigated with regard to possible advantages of additional ventricular reconstruction versus coronary bypass alone. The investigators of this study also found a significant increase in ejection fraction (average value of 41%) after aneurysm repair. In addition, there was a significant decrease in LV volumes. As expected, the smaller volumes resulted in a decrease in intraventricular pressure<sup>[24]</sup>.

Postoperative changes in left ventricular geometry were reflected in changes in the sphericity index (SI), apical conicity index (ACI), and apical conicity ratio (ACR). While the postoperative SI was nearly unchanged at end-systole, there was a significant increase at end-diastole. These findings are in agreement with the results of Hüther *et al.*, who reported nearly identical changes in SI at end-diastole as in our study, corresponding to a significant SI increase following a reduction of ventricular volume and increased global EF. They also found the EF to be a predictor of survival after ventricular reconstruction for apical dyskinesia or akinesia<sup>[25]</sup>. Although these changes, when the value is  $> 0.5$ , actually indicate a greater abnormality in SI and a more spherical shape<sup>[11]</sup>, it must be borne in mind that we only saw a change at end-diastole, while a constant SI of 0.5 was observed during end-systole, which indicates a normal

ventricular shape<sup>[11]</sup>. These results suggest that determination of SI must be interpreted with caution in patients with LV aneurysm. This is because an aneurysm causes local, apical bulging of the ventricle, while cardiac insufficiency is associated with global ventricular dilatation and results in a spherical ventricle. An aneurysm primarily affects the longitudinal axis of the left ventricle, while the short axis increases less relative to the long axis. That is why the SI remains normal or changes only moderately without becoming abnormal in many patients with LV aneurysm<sup>[12]</sup>. The significant postoperative increase in SI, by definition a change into the abnormal range, is the result of a relatively greater decrease in longitudinal diameter as compared with the transverse diameter after aneurysm repair. Therefore, the SI does not appear to be a suitable parameter for describing the type of ventricular deformation caused by aneurysm and the changes occurring after surgical restoration. Similar conclusions were drawn by Di Donato *et al.*, who, while identifying SI to be a useful parameter for assessing global changes in the myocardial wall, did not find it to be useful for characterizing local changes, as they found no significant differences in SI between healthy subjects and patients with LV aneurysm<sup>[12]</sup>.

A more suitable measure of local changes in cardiac geometry following ventricular dilatation due to LV aneurysm appears to be the apical conicity index (ACI). For instance, when an aneurysm causes apical deformity, the apical diameter approaches the length of the short cardiac axis and the ACI decreases<sup>[12]</sup>, as shown in our study and by Di Donato *et al.*, who reported similar results for patients with apical LV aneurysm as in our study<sup>[12]</sup>. Surgical aneurysm repair with a reduction of LV volume and reconstruction of the normal ellipsoid shape with a conical apex reduces the apical diameter, which is reflected in a decrease in ACI<sup>[24]</sup>. This was seen in our patients, who had significantly decreased ACI values after surgical repair, both during end-systole and end-diastole. This means that the ACI provides a quantitative estimate of the outcome of left ventricular repair in terms of restoration of its normal shape. Restoration of the physiologic configuration of the left ventricle should be the foremost aim of surgical left ventricular restoration as it is crucial for treatment outcome<sup>[26]</sup>. A long-term study has shown that restoration of the normal ventricular shape prevents cardiac death more effectively than a reduction of ventricular volume<sup>[27]</sup>. Another parameter that can be used to characterize the local changes associated with LV aneurysm is the apical conicity ratio (ACR). As outlined in the introduction, the ACR is the ratio of the true apical ventricular area to a triangle approximating the ideal shape of the conical apex. Surgical aneurysm repair with restoration of the elliptical shape of the ventricle aims at reducing the dilated apex and remodeling its normal, conical configuration<sup>[28]</sup>. This repair results in a decrease in the apical area of the left ventricle and hence a lower ACR<sup>[13]</sup>. We found a significant systolic and diastolic decrease in ACR after aneurysm repair, which is consistent with the results of Fan *et al.*<sup>[13]</sup> and indicates that surgery results in a near-normal ventricular shape.

In conclusion, MSCT is a suitable imaging modality for assessing the outcome of LV aneurysm repair and ventricular restoration. Successful repair results in a significant volume reduction and improved LV function and restoration of the normal ellipsoid shape of the ventricle.

## CONCLUSION

MSCT demonstrates significant LV volume reduction after surgical LV aneurysm repair and restoration of the ventricle, which results

in improved cardiac function (LV-EF). The increased wall thickness and volume reduction lowers postoperative wall tension. LV aneurysm surgery contributes to the restoration of normal LV shape and function.

## LIMITATIONS

Our study is limited by the relatively small number of 35 patients investigated. The small number of patients might have biased statistical results. Moreover, our results reflect the situation during the rather short immediate postoperative period of a median of 7 days and provide no information on later changes.

## ACKNOWLEDGEMENT

This study is a retrospective analysis of clinical necessary CT-scans. Both authors have no potential conflicts of interest.

## REFERENCES

- Anversa, P, Olivetti, G, Capasso JM. Cellular basis of ventricular remodeling after myocardial infarction. *Am J Cardiol* 1991; **68(14)**: 7D-16D
- Flaherty GT, O'Neill MN, Daly KM, Folan-Curran J. True aneurysm of the left ventricle: a case report and literature review. *Clin Anat* 2001; **14(5)**: 363-368
- Ertl G, Gaudron P, Eilles C, Kochsiek K. Serial changes in left ventricular size after acute myocardial infarction. *Am J Cardiol* 1991; **68(14)**: 116D-120D
- St John Sutton M, Pfeffer MA, Moye L, Plappert T, Rouleau JL, Lamas G, Rouleo J, Parker JO, Arnold MO, Sussex B, Braunwald E. Cardiovascular death and left ventricular remodeling two years after myocardial infarction: baseline predictors and impact of long-term use of captopril: information from the Survival and Ventricular Enlargement (SAVE) trial. *Circulation* 1997; **96(10)**: 3294-3299
- Pfeffer MA. Left ventricular remodeling after acute myocardial infarction. *Annu Rev Med* 1995; **46**: 455-466
- Eisen HJ. Surgical ventricular reconstruction for heart failure. *N Engl J Med* 2009; **360(17)**: 1781-1784
- Dor V, Saab M, Coste P, Komaszewska M, Montiglio F. Left ventricular aneurysms: a new surgical approach. *Thorac Cardiovasc Surg* 1989; **37(1)**: 11-19
- Shilov VV, Belevitin AB, Prokofev AV, Sidelnikov VO, Shilov PV. Results of surgical remodeling after resection of aneurysm and plasty by Dor-II-Jatene method in patients with post-infarction aneurysms of the left ventricle. *Vestn Khir Im I I Grek* 2009; **168(2)**: 13-17
- Sobkowicz B, Hirnle T, Haran T, Wrabec K, Mielecki T. Usefulness of two-dimensional echocardiography for evaluation of left ventricular aneurysm. Comparison with magnetic resonance imaging and intraoperative evaluation. *Przegl Lek* 2002; **59(8)**: 632-637
- Rist C, Johson TR, Becker A, Leber AW, Huber A, Busch S, Becker CR, Reiser MF, Nikolaou K. Dual-source cardiac CT imaging with improved temporal resolution: Impact on image quality and analysis of left ventricular function. *Radiologe* 2007; **47(4)**: 287-90, 292-294
- Brzezinska B, Loboz-Grudzien K, Sokalski L. Patterns of post-MI left ventricular volume changes - clinical implications. *Kardiol Pol* 2007; **65(10)**: 1190-1198
- Di Donato M, Dabic P, Castelveccchio S, Santambrogio C, Brankovic J, Collarini L, Joussef T, Frigiola A, Buckberg G, Menicanti L. Left ventricular geometry in normal and post-anterior myocardial infarction patients: sphericity index and 'new' conicity index comparisons. *Eur J Cardiothorac Surg* 2006; **29 Suppl 1**: S225-S230
- Fan H, Zheng Z, Feng W, Zhang Y, Jin L, Hu S. Apical conicity ratio: a new index on left ventricular apical geometry after myocardial infarction. *J Thorac Cardiovasc Surg* 2010; **140(6)**: 1402-1407 e1-3
- Mahnken AH, Rauscher A, Klotz E. Quantitative prediction of contrast enhancement from test bolus data in cardiac MSCT. *Eur Radiol* 2007; **17(5)**: 1310-1319
- Cerqueira MD, Weissman NJ, Dilsizian V, Jacobs AK, Kaul S, Laskey WK, Pennell DJ, Rumberger JA, Ryan T, Verani MS. Standardized myocardial segmentation and nomenclature for tomographic imaging of the heart: a statement for healthcare professionals from the Cardiac Imaging Committee of the Council on Clinical Cardiology of the American Heart Association. *Circulation* 2002; **105(4)**: 539-542
- Athanasuleas CL, Buckberg GD, Stanley AW, Siler W, Dor V, DiDonato M, Menicanti L, de Oliveira SA, Beyersdorf F, Kron IL, Suma H, Kouchoukos NT, Moore W, McCarthy PM, Oz MC, Fortan F, Scott ML, Accola KA; RESTORE-Group. Surgical ventricular restoration: the RESTORE Group experience. *Heart Fail Rev* 2004; **9(4)**: 287-297
- Di Donato M, Sabatier M, Toso A, Barletta G, Baroni M, Dor V, Fantini F. Regional myocardial performance of non-ischaemic zones remote from anterior wall left ventricular aneurysm. Effects of aneurysmectomy. *Eur Heart J* 1995; **16(9)**: 1285-1292
- Di Donato M, Sabatier M, Dor V, Toso A, Maioli M, Fantini F. Akinetic versus dyskinetic postinfarction scar: relation to surgical outcome in patients undergoing endoventricular circular patch plasty repair. *J Am Coll Cardiol* 1997; **29(7)**: 1569-1575
- Mirsky I. Left ventricular stresses in the intact human heart. *Biophys J* 1969; **9(2)**: 189-208
- Walker JC, Ratcliffe MB, Zhang P, Wallace AW, Hsu EW, Saloner DA, Guccione JM. Magnetic resonance imaging-based finite element stress analysis after linear repair of left ventricular aneurysm. *J Thorac Cardiovasc Surg* 2008; **135(5)**: 1094-1102, 1102 e1-2
- White HD, Norris RM, Brown MA, Brandt MA, Whitlock RM, Wild CJ. Left ventricular end-systolic volume as the major determinant of survival after recovery from myocardial infarction. *Circulation* 1987; **76(1)**: 44-51
- Migrino RQ, Young JB, Ellis SG, White HD, Lundergan CF, Miller DP, Granger CB, Ross AM, Califf RM, Topol EJ. End-systolic volume index at 90 to 180 minutes into reperfusion therapy for acute myocardial infarction is a strong predictor of early and late mortality. The Global Utilization of Streptokinase and t-PA for Occluded Coronary Arteries (GUSTO)-I Angiographic Investigators. *Circulation* 1997; **96(1)**: 116-121
- Solomon SD, Anavekar N, Skali H, McMurray JJ, Swedberg K, Yusuf S, Granger CB, Michelson EL, Wang D, Pocock S, Pfeffer MA. Influence of ejection fraction on cardiovascular outcomes in a broad spectrum of heart failure patients. *Circulation* 2005; **112(24)**: 3738-3744
- Menicanti L, Di Donato M. Surgical left ventricle reconstruction, pathophysiologic insights, results and expectation from the STICH trial. *Eur J Cardiothorac Surg* 2004; **26(Suppl 1)**: S42-S46; discussion S46-47
- Hüther J, Doenst T, Nitsche S, Thiele H, Mohr FW, Gutberlet M. Cardiac magnetic resonance imaging for the assessment of ventricular function, geometry, and viability before and after surgical ventricular reconstruction. *J Thorac Cardiovasc Surg* 2011; **142(6)**: 1515-1522
- Adhyapak SM, Parachuri VR. Response to heart failure therapy: ventricular volume changes vs. shape changes. *Asian Cardiovasc Thorac Ann*. 2012; **20(2)**: 210-213
- Di Mauro M, Iacò AL, Bencivenga S, Clemente D, Marcon S, Asif Mahmood, Di Saverio MC, Romano S, Gallina S, Penco M,

Calafiore AM. Left ventricular surgical remodelling: is it a matter of shape or volume. *Eur J Cardiothorac Surg* 2014 [Epub ahead of print]

28 Di Donato M, Sabatier M, Dor V, Gensini GF, Toso A, Maioli M,

Stanley AW, Athannasuleas C, Buckberg G. Effects of the Dor procedure on left ventricular dimension and shape and geometric correlates of mitral regurgitation one year after surgery. *J Thorac Cardiovasc Surg* 2001; **121**(1): 91-96