

Occult Pediatric Scaphoid Injuries

Nikolaos K. Sferopoulos

Nikolaos K. Sferopoulos, Department of Pediatric Orthopaedics, "G. Gennimatas" Hospital, Thessaloniki, Greece

Conflict-of-interest statement: The author(s) declare(s) that there is no conflict of interest regarding the publication of this paper.

Open-Access: This article is an open-access article which was selected by an in-house editor and fully peer-reviewed by external reviewers. It is distributed in accordance with the Creative Commons Attribution Non Commercial (CC BY-NC 4.0) license, which permits others to distribute, remix, adapt, build upon this work non-commercially, and license their derivative works on different terms, provided the original work is properly cited and the use is non-commercial. See: <http://creativecommons.org/licenses/by-nc/4.0/>

Correspondence to: Nikolaos K. Sferopoulos, Department of Pediatric Orthopaedics, "G. Gennimatas" Hospital, Thessaloniki, Greece.

Email: sferopoulos@in.gr, sferopoulos@yahoo.com

Telephone: +00302310963270

Fax: +00302310968265

Received: April 26, 2017

Revised: October 22, 2017

Accepted: October 26, 2017

Published online: January 26, 2018

ABSTRACT

Fractures of the scaphoid may not be evident on the initial radiographic examination. They may be diagnosed in a late stage from the radiographic signs of bone healing. The diagnosis and treatment of children presenting with residual pain, swelling and tenderness on palpation in the anatomical snuffbox following either scaphoid injuries or distal forearm fractures after 5, at least, weeks of immobilization represent a true diagnostic dilemma. The use of a limited MRI with fat-suppression may indicate bone bruises of the carpal bones and/or of the scaphoid in these children. Prolonged immobilization and protection, until complete resolution of the clinical symptoms and signs, is the only required treatment.

Key words: Scaphoid injuries; Children; Occult; Bone bruising; Diagnosis; Treatment

© 2018 The Author(s). Published by ACT Publishing Group Ltd. All rights reserved.

Sferopoulos NK. Occult Pediatric Scaphoid Injuries. *International Journal of Radiology* 2018; **5(1)**: 139-143 Available from: URL: <http://www.ghrnet.org/index.php/ijr/article/view/2059>

EDITORIAL

A spherical growth plate circumferentially surrounds the entire ossific centre of each individual carpal bone during development. This growth plate is protective and offers resistance to fracture until sometime in adolescence. Fractures of the carpal scaphoid are rare in children. They are usually incomplete, undisplaced and located in the distal third. Radiographic findings indicative of a scaphoid fracture may be evident 2 to 3 weeks following a wrist injury. Scaphoid, as well as carpal bones lack a periosteal covering. Therefore, a periosteal reaction is not seen at imaging of a healing fracture. Sclerosis and bone resorption are common radiographic findings in the late stage. Diagnosis of scaphoid injuries in children may be easily missed because of their rarity, their unspecific and discrete clinical symptoms and partly because of difficult radiographic diagnostics. Avascular necrosis and nonunion are exceedingly rare in fresh fractures treated in a scaphoid type forearm-thumb cast. Immobilization is mandatory in cases with a clinical, although nonradiological, diagnosis^[1-30].

Clinical examination and standard radiographic evaluation procedures are reliable in the diagnosis of fractures of the scaphoid, in children with wrist injuries who suffer from acute or persistent pain and tenderness on palpation in the anatomical snuffbox, when performed by experienced pediatric orthopaedic surgeons. Occult fractures cannot by definition be diagnosed by conventional radiographs. In clinically suspected scaphoid injuries second-line investigations, including ultrasound, computed tomography (CT), bone scintigraphy and magnetic resonance imaging (MRI), may be used for the differential diagnosis of nonradiographically evident fractures and bone bruises from soft tissue injuries^[31-43].

With the advent of fat-suppression MRI, a new category of injury has been recognized: the bone bruise or contusion. It appears as an area of high intra-osseous signal intensity, representing focal edema and hemorrhage, following a microtrabecular injury of bone marrow without a defined cortical fracture line. Isolated subcortical trabecular fractures can occur in any region of the developing skeleton. Such injuries were rarely detected in the past because they are not visible on conventional radiographs, CT or routine MRI.

Bone bruises remain painful on palpation, whereas occult fractures through the growth plate or metaphysis of the long bones have become asymptomatic after a reasonable period of immobilization in plaster. This may be due to either a reduction in intra-osseous pressure by evacuation of the hematoma from the fractured cortex or to an acceleration of the healing process encouraged by the activated periosteum. A prolonged period of immobilization and restricted use of the involved limb is mandatory during trabecular healing of bone bruises to avoid insufficiency fractures. The bruises as well as their clinical symptoms usually disappear within 12-16 weeks. According to forensic applications and problems pursuant to insurance law, MRI examination is only indicated when conventional radiographs are unremarkable, pain persists for an unusually long period of time and when a relevant therapeutic consequence can be expected from the MRI results^[44-53].

The incidence of bone bruising to the distal radius and wrist or ankle has been well documented in children. The use of a limited MRI, using fat-suppression, to evaluate a potential bone bruising is indicated in children, whose symptoms do not resolve after a sufficient period of immobilization, usually exceeding 5 weeks. In the past, the appearance of a fracture line on plain radiography was needed to diagnose a fracture. Thus, children with bone bruises might have been encouraged to use an injured extremity or to participate in sporting activities after or even before 5 weeks of immobilization^[54,55].

Bone bruising of the scaphoid may exhibit substantial variation in anatomical location and extent. It may also be associated with bone bruising of other carpal bones. It is a benign injury with predictable recovery and is unlikely to result in long-term morbidity in the form of nonunion. An elongated recovery period is mandatory, with appropriate immobilization and restricted use of the involved limb, during trabecular healing to avoid an insufficiency fracture^[56,57].

Children with residual clinical symptoms and signs of radiographically occult scaphoid injury, following 5, at least, weeks of immobilization, are divided in two groups. The former group includes patients that have already been immobilized for a potential scaphoid injury. Scaphoid injuries with residual pain, swelling and tenderness on palpation in the anatomical snuffbox, where

radiographic imaging remains normal and recovery is significantly prolonged, represent a true diagnostic dilemma (Figures 1, 2, 3). The latter group includes patients with distal forearm fractures that were treated conservatively. Residual scaphoid symptoms and signs following the treatment of distal forearm fractures also pose a diagnostic enigma (Figures 4, 5).

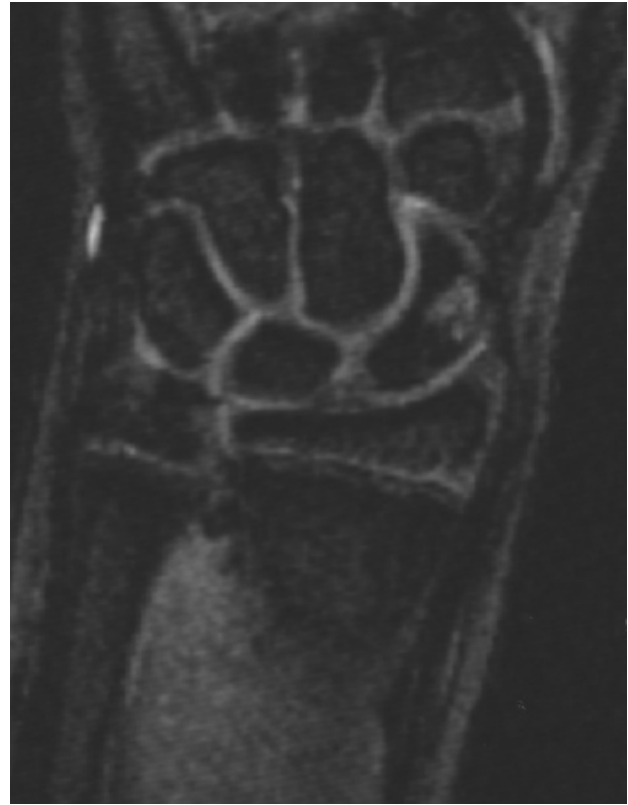

Figure 1 An 11-year-old boy with a radiographically occult scaphoid injury following a fall on an outstretched hand that was immobilized in plaster. A MRI was performed due to residual symptoms, following cast removal, 5 weeks post-injury. FL2D image shows bone bruising through the mid-portion of the left scaphoid.

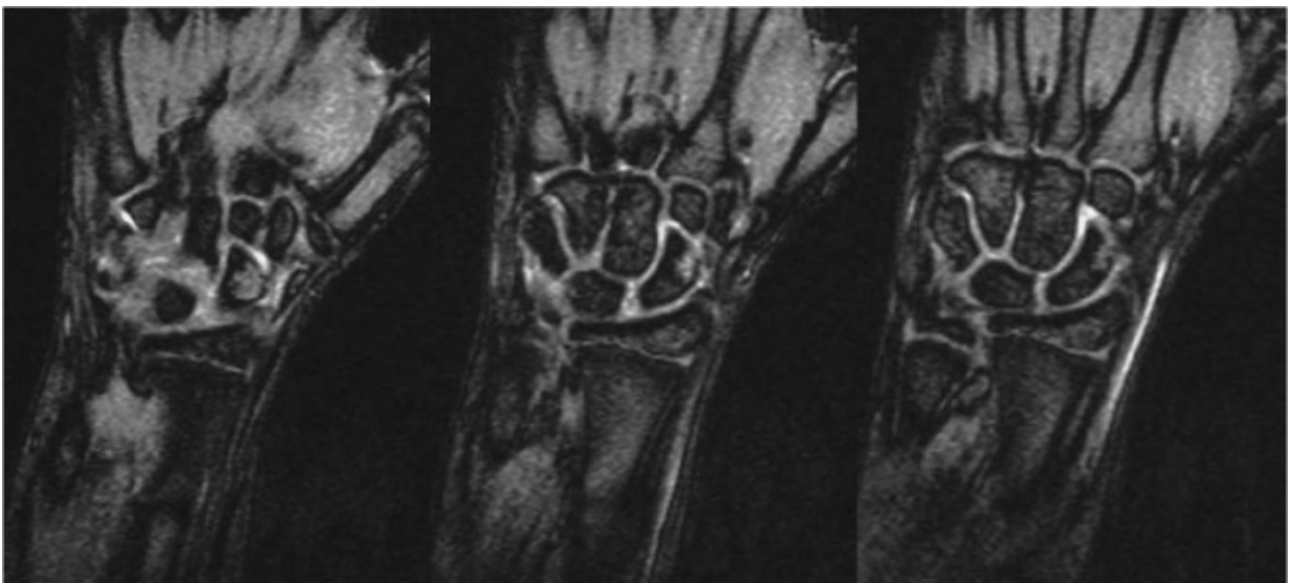


Figure 2 An 11-year-old boy with a radiographically occult scaphoid injury following a fall from his bicycle that was immobilized in plaster. A MRI was performed due to residual symptoms, following cast removal, 5 weeks post-injury. FL2D images showed bone bruising of the distal pole of the left scaphoid and fluid signal around it.

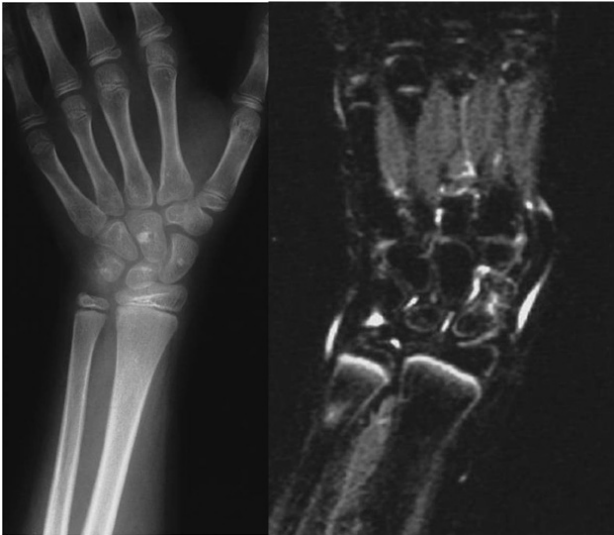

Figure 3 An 8-year-old girl with a radiographically occult scaphoid injury that was immobilized in plaster. A MRI was performed due to residual symptoms, following cast removal, 5 weeks post-injury. Short tau inversion recovery image showed bone bruising of the mid-portion of the scaphoid and fluid signal around most of the carpal bones. Two bone islands on the scaphoid and the capitate were found incidentally on the radiographs.

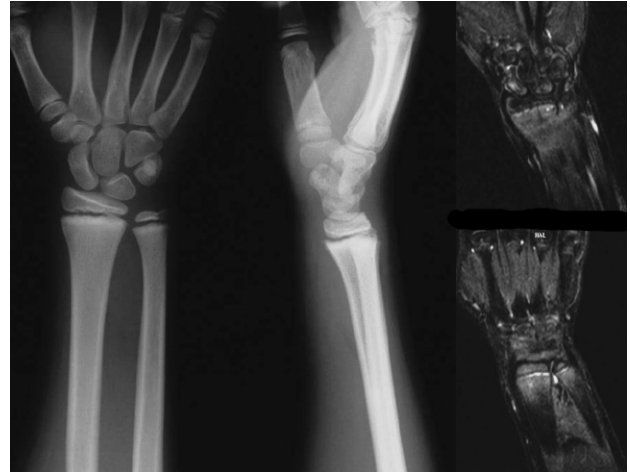

Figure 4 A 13-year-old boy with an undisplaced physal fracture of the distal forearm bones that was treated conservatively. A MRI was performed due to radial-sided wrist pain, following cast removal, 5 weeks post-injury. Short tau inversion recovery images showed bone bruising of the mid-portion of the scaphoid and fluid signal of the distal radioulnar joint.

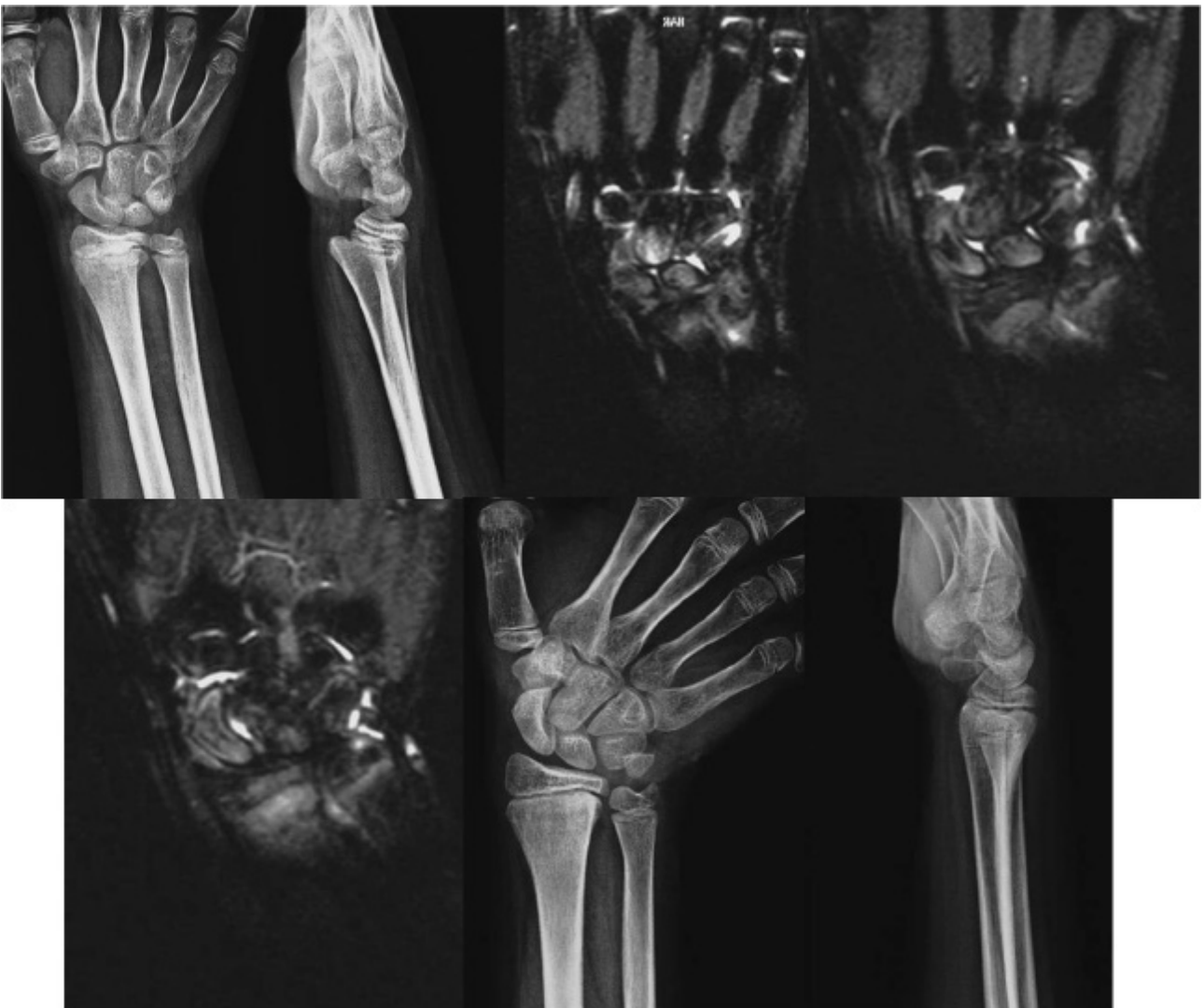

Figure 5 A 12-year-old boy was referred 2 weeks following a football injury (the ball forced the wrist into extension). The fracture was immobilized but reduction was not attempted. A MRI was performed due to radial-sided wrist pain, following cast removal, 5 weeks post-injury. Short tau inversion recovery images showed diffuse bone bruising of the carpal bones, including the scaphoid, with fluid signal between them. Further immobilization and protection was offered for a total period of 3 months post-injury. By that time the patient was symptom-free and radiographs indicated complete remodeling of the displaced fracture of the distal radius.

MRI with fat-suppression may indicate bone bruises of the carpal bones and/or of the scaphoid in both groups of patients. We have also consistently observed fluid collection in the joints of the carpal bones. No long-term morbidity occurred in any of our patients.

It could be argued that bone bruises would heal uneventfully without treatment and that MRI rarely adds information that influences the treatment of such patients and should, therefore, not be considered as a first-line examination. However, the use of a limited MRI with fat-suppression might be considered as a useful second-line investigation to answer or evaluate the cause of residual posttraumatic radial-sided wrist tenderness, justify prolonged immobilization and protection and ensure appropriate treatment of bone bruising of the scaphoid in children.

REFERENCES

- Vahvanen V, Westerlund M. Fracture of the carpal scaphoid in children. A clinical and roentgenological study of 108 cases. *Acta Orthop Scand* 1980; **51(6)**: 909-13. [PMID: 7211295].
- Christodoulou AG, Colton CL. Scaphoid fractures in children. *J Pediatr Orthop* 1986; **6(1)**: 37-9. [PMID: 3941178].
- Nafie S A. Fractures of the carpal bones in children. *Injury* 1987; **18(2)**: 117-9. [PMID: 3508159].
- Gellman H, Caputo RJ, Carter V, Abouafia A, McKay M. Comparison of short and long thumb-spica casts for non-displaced fractures of the carpal scaphoid. *J Bone Joint Surg Am* 1989; **71(3)**: 354-7. [PMID: 2925707].
- Mittal RL, Dargan SK. Occult scaphoid fracture: a diagnostic enigma. *J Orthop Trauma* 1989; **3(4)**: 306-8. [PMID: 2600698].
- Rayan GM. Scaphoid fractures and nonunions. *Am J Orthop (Belle Mead NJ)* 1995; **24(3)**: 227-36. [PMID: 7773666].
- Wulff RN, Schmidt TL. Carpal fractures in children. *J Pediatr Orthop* 1998; **18(4)**: 462-5. [PMID: 9661853].
- Stahl S. Scaphoid fractures in children. *Harefuah*. 2000; **138(10)**: 842-3, 910. [PMID: 10883251].
- D'Arienzo M. Scaphoid fractures in children. *J Hand Surg Br* 2002; **27**: 424-6. [PMID: 12367553].
- García-Mata S. Carpal scaphoid fracture nonunion in children. *J Pediatr Orthop* 2002; **22(4)**: 448-51. [PMID: 12131439].
- Hernandez JA, Swichuk EL, Bathurst JG, Hendrick PE. Scaphoid (navicular) fractures of the wrist in children: attention to the impacted buckle fracture. *Emerg Radiol* 2002; **9(6)**: 305-8. [PMID: 15290539]; [DOI: 10.1007/s10140-002-0244-5].
- Toh S, Miura H, Arai K, Yasumura M, Wada M, Tsubo K. Scaphoid fractures in children: problems and treatment. *J Pediatr Orthop* 2003; **23**: 216-21. [PMID: 12604954].
- Goddard N. Carpal fractures in children. *Clin Orthop Relat Res* 2005; **432**: 73-6. [PMID: 15738806].
- Elhassan BT, Shin AY. Scaphoid fracture in children. *Hand Clin* 2006; **22(1)**: 31-41. [PMID: 16504776]; [DOI: 10.1016/j.hcl.2005.10.004].
- Chloros GD, Themistocleous GS, Weisler ER, Benetos IS, Efstathopoulos DG, Soucacos PN. Pediatric scaphoid nonunion. *J Hand Surg Am* 2007; **32(2)**: 172-6. [PMID: 17275591]; [DOI: 10.1016/j.jhsa.2006.11.007].
- Huckstadt T, Klitscher D, Weltzien A, Müller LP, Rommens PM, Schier F. Pediatric fractures of the carpal scaphoid: a retrospective clinical and radiological study. *J Pediatr Orthop* 2007; **27(4)**: 447-50. [PMID: 17513968]; [DOI: 10.1097/01.bpb.0000271309.05924.80].
- Anz AW, Bushnell BD, Bynum DK, Chloros GD, Wiesler ER. Pediatric scaphoid fractures. *J Am Acad Orthop Surg* 2009; **17(2)**: 77-87. [PMID: 19202121].
- Evenski AJ, Adamczyk MJ, Steiner RP, Morscher MA, Riley PM. Clinically suspected scaphoid fractures in children. *J Pediatr Orthop* 2009; **29(4)**: 352-5. [PMID: 19461376]; [DOI: 10.1097/BPO.0b013e3181a5a667].
- Rhemrev SJ, van Leerdam RH, Ootes D, Beeres FJ, Meylaerts SA. Non-operative treatment of non-displaced scaphoid fractures may be preferred. *Injury* 2009; **40(6)**: 638-41. [PMID: 19324359]; [DOI: 10.1016/j.injury.2008.10.028].
- Dwek JR. The periosteum: what is it, where is it, and what mimics it in its absence? *Skeletal Radiol* 2010; **39(4)**: 319-23. [PMID: 20049593]; [PMCID: PMC2826636]; [DOI: 10.1007/s00256-009-0849-9].
- Gunal I, Altay T. Avascular necrosis of the scaphoid in children treated by splint immobilization: a report of two cases. *J Bone Joint Surg Br* 2011; **93-B**: 847-8. [PMID: 21586789]; [DOI: 10.1302/0301-620X.93B6.26670].
- Gholson JJ, Bae DS, Zurakowski D, Waters PM. Scaphoid fractures in children and adolescents: contemporary injury patterns and factors influencing time to union. *J Bone Joint Surg Am* 2011; **93(13)**: 1210-9. [PMID: 21776574]; [DOI: 10.2106/JBJS.J.01729].
- de Putter CE, van Beeck EF, Looman CW, Toet H, Hovius SE, Selles RW. Trends in wrist fractures in children and adolescents, 1997-2009. *J Hand Surg Am* 2011; **36(11)**: 1810-5.e2. [PMID: 22036281]; [DOI: 10.1016/j.jhsa.2011.08.006].
- Sendher R, Ladd AL. The scaphoid. *Orthop Clin North Am* 2013; **44(1)**: 107-20. [PMID: 23174330]; [DOI: 10.1016/j.jocl.2012.09.003].
- Journeau P. Carpal injuries in children. *Chir Main* 2013; **32 Suppl 1**: S16-28. [PMID: 23746827]; [DOI: 10.1016/j.main.2013.04.009].
- Ahmed I, Ashton F, Tay WK, Porter D. The pediatric fracture of the scaphoid in patients aged 13 years and under: an epidemiological study. *J Pediatr Orthop* 2014; **34(2)**: 150-4. [PMID: 24172664]; [DOI: 10.1097/BPO.0000000000000102].
- Little JT, Kliensky NB, Chaturvedi A, Soral A, Chaturvedi A. Pediatric distal forearm and wrist injury: an imaging review. *Radiographics* 2014; **34(2)**: 472-90. [PMID: 24617692]; [DOI: 10.1148/rg.342135073].
- Gajdobranski D, Zivanović D, Mikov A, Slavković A, Marić D, Marjanović Z, Milankov V. Scaphoid fractures in children. *Srp Arh Celok Lek* 2014; **142(7-8)**: 444-9. [PMID: 25233689].
- Bae DS, Gholson JJ, Zurakowski D, Waters PM. Functional outcomes after treatment of scaphoid fractures in children and adolescents. *J Pediatr Orthop* 2016; **36(1)**: 13-8. [PMID: 25658179]; [DOI: 10.1097/BPO.0000000000000406].
- Eckert K, Tröbs RB, Schweiger B, Liedgens P, Radeloff E, Ackermann O. Diagnostically approach to pediatric carpal fractures: a retrospective analysis. *Z Orthop Unfall* 2016; **154(1)**: 43-9. [PMID: 26468923]; [DOI: 10.1055/s-0035-1558078].
- Naranja RJ Jr, Gregg JR, Dormans JP, Drummond DS, Davidson RS, Hahn M. Pediatric fracture without radiographic abnormality. Description and significance. *Clin Orthop Relat Res* 1997; **342**: 141-6. [PMID: 9308536].
- Cook PA, Yu JS, Wiand W, Cook AJ 2nd, Coleman CR, Cook AJ. Suspected scaphoid fractures in skeletally immature patients: application of MRI. *J Comput Assist Tomogr* 1997; **21(4)**: 511-5. [PMID: 9216753].
- Johnson K J, Haigh S F, Symonds K E. MRI in the management of scaphoid fractures in skeletally immature patients. *Pediatr Radiol* 2000; **30(10)**: 685-8. [PMID: 11075601]; [DOI: 10.1007/s002470000305].
- Gäbler C, Kukla C, Breitensteher MJ, Trattning S, Vécsei V. Diagnosis of occult scaphoid fractures and other wrist injuries. Are repeated clinical examinations and plain radiographs still state of the art? *Langenbecks Arch Surg* 2001; **386(2)**: 150-4. [PMID: 11374049].
- Boutis K, Komar L, Jaramillo D, Babyn P, Alman B, Snyder B, Mandl KD, Schuh S. Sensitivity of a clinical examination to predict need for radiography in children with ankle injuries: a prospective study. *Lancet* 2001 Dec; **358(9299)**: 2118-21. [PMID:

- 11784626]; [DOI: 10.1016/S0140-6736(01)07218-X]
36. Kumar S, O'Connor A, Despois M, Galloway H. Use of early magnetic resonance imaging in the diagnosis of occult scaphoid fractures: the CAST Study (Canberra Area Scaphoid Trial). *N Z Med J* 2005; **118(1209)**: U1296. [PMID: 15711629].
 37. Logters TT, Linhart W, Schubert D, Windolf J, Schadel-Hopfner M. Diagnostic approach for suspected scaphoid fractures in children. *Eur J Trauma Emerg Surg* 2008; **34(2)**: 131-4. [PMID: 26815617]; [DOI: 10.1007/s00068-007-7037-1].
 38. Wilson EB, Beattie TF, Wilkinson AG. Epidemiological review and proposed management of 'scaphoid' injury in children. *Eur J Emerg Med* 2011; **18(1)**: 57-61. [PMID: 20585258]; [DOI: 10.1097/MEJ.0b013e32833c9312].
 39. Fotiadou A, Patel A, Morgan T, Karantanas AH. Wrist injuries in young adults: the diagnostic impact of CT and MRI. *Eur J Radiol* 2011; **77(2)**: 235-9. [PMID: 20554419]; [DOI: 10.1016/j.ejrad.2010.05.011].
 40. Weber DM. Scaphoid fractures in childhood. *Unfallchirurg* 2011; **114(4)**: 285-91. [PMID: 21445650]; [DOI: 10.1007/s00113-011-1963-4].
 41. Foley K, Patel S. Fractures of the scaphoid, capitate and triquetrum in a child: a case report. *J Orthop Surg* 2012; **20(1)**: 103-4. [PMID: 22535822]; [DOI: 10.1177/230949901202000121].
 42. Elvey M, Patel S, Avisar E, White WJ, Sorene E. Defining occult injuries of the distal forearm and wrist in children. *J Child Orthop* 2016; **10(3)**: 227-33. [PMID: 27121641]; [PMCID: PMC4909650]; [DOI: 10.1007/s11832-016-0735-7].
 43. Jørgsholm P, Thomsen N, Besjakov J, Abrahamsson S, Björkman A. MRI shows a high incidence of carpal fractures in children with posttraumatic radial-sided wrist tenderness. *Acta Orthop* 2016 Oct; **87(5)**: 533-7. [PMID: 27436058]; [PMCID: PMC5016915]; [DOI: 10.1080/17453674.2016.1210940].
 44. Lynch TCP, Crues JV 3rd, Morgan FW, Sheehan WE, Harter LP, Ryu R. Bone abnormalities of the knee: prevalence and significance at MR imaging. *Radiology* 1989; **171(3)**: 761-6. [PMID: 2717748]; [DOI: 10.1148/radiology.171.3.2717748].
 45. Meyers SP, Wiener SN. Magnetic resonance imaging features of fractures using the short tau inversion recovery (STIR) sequence: correlation with radiographic findings. *Skeletal Radiol* 1991; **20(7)**: 499-507. [PMID: 1754911].
 46. Ogden JA. Skeletal injury in the child ("Injury to the growth mechanisms"), 3rd ed., New York: Springer; 2000.
 47. Zimmermann R, Rudisch A, Fritz D, Gschwentner M, Arora R. MR imaging for the evaluation of accompanying injuries in cases of distal forearm fractures in children and adolescents. *Handchir Mikrochir Plast Chir* 2007; **39(1)**: 60-7. [PMID: 17402142]; [DOI: 10.1055/s-2007-964926].
 48. Karantanas A, Dailiana Z, Malizos K. The role of MR imaging in scaphoid disorders. *Eur Radiol* 2007; **17(11)**: 2860-71. [PMID: 17351778]; [DOI: 10.1007/s00330-007-0624-z].
 49. Sankar WN, Chen J, Kay RM, Skaggs DL. Incidence of occult fracture in children with acute ankle injuries. *J Pediatr Orthop* 2008; **28(5)**: 500-1. [PMID: 18580361]; [DOI: 10.1097/BPO.0b013e31817b9336].
 50. Boutis K, Narayanan UG, Dong FF, Mackenzie H, Yan H, Chew D, Babyn P. Magnetic resonance imaging of clinically suspected Salter-Harris I fracture of the distal fibula. *Injury* 2010; **41(8)**: 852-6. [PMID: 20494352]; [DOI: 10.1016/j.injury.2010.04.015].
 51. Endele D, Jung C, Bauer G, Mauch F. Value of MRI in diagnosing injuries after ankle sprains in children. *Foot Ankle Int* 2012; **33(12)**: 1063-8. [PMID: 23199854]; [DOI: 10.3113/FAI.2012.1063].
 52. Regauer M, Mutschler W. Occult fractures of extremities in adults and children. Exemplified by foot and ankle injuries. *Unfallchirurg*. 2015; **118(3)**: 213-21. [PMID: 25783689]; [DOI: 10.1007/s00113-014-2689-x].
 53. Sferopoulos NK. Bone bruising of the distal forearm and wrist in children. *Injury* 2009; **40(6)**: 631-7. [PMID: 19394015]; [DOI: 10.1016/j.injury.2009.01.104].
 54. Sferopoulos NK. Residual symptoms of occult pediatric ankle injuries: MRI-diagnosed bone bruising. *British Journal of Medicine & Medical Research* 2014; **4(1)**: 295-303.
 55. Sferopoulos NK. The classification of physeal injuries. *ARC Journal of Orthopedics* 2016; **1(1)**: 23-7.
 56. La Hei N, McFadyen I, Brock M, Field J. Scaphoid bone bruising-probably not the precursor of asymptomatic non-union of the scaphoid. *J Hand Surg Eur Vol* 2007; **32(3)**: 337-40. [PMID: 17335946]; [DOI: 10.1016/J.JHSB.2006.09.018].
 57. Thavarajah D, Syed T, Shah Y, Wetherill M. Does scaphoid bone bruising lead to occult fracture? A prospective study of 50 patients. *Injury* 2011; **42(11)**: 1303-6. [PMID: 21497809]; [DOI: 10.1016/j.injury.2011.02.020].

Peer Reviewer: Abdulrasool Alae