

Percutaneous Transhepatic Biliary Drainage is Effective in Palliative Management of Malignant Obstructive Jaundice

Anuradha Sharma, Rohit Sharma, Puneet Gupta, Rahul Bhan

Anuradha sharma, Department of Radio-diagnosis and Imaging, VMMC and Safdarjung Hospital, New delhi, India

Rohit sharma, Department of Radio-diagnosis and Imaging, GMC, Jammu (J&K), India

Puneet gupta, Department of Radio-diagnosis and Imaging, AS-COMS Hospital, Jammu (J&K), India

Rahul bhan, Department of Surgery, GMC, Jammu (J&K), India

Conflict-of-interest statement: The author(s) declare(s) that there is no conflict of interest regarding the publication of this paper.

Open-Access: This article is an open-access article which was selected by an in-house editor and fully peer-reviewed by external reviewers. It is distributed in accordance with the Creative Commons Attribution Non Commercial (CC BY-NC 4.0) license, which permits others to distribute, remix, adapt, build upon this work non-commercially, and license their derivative works on different terms, provided the original work is properly cited and the use is non-commercial. See: <http://creativecommons.org/licenses/by-nc/4.0/>

Correspondence to: Puneet Gupta, 339/3, Gupta Industries, Jeevan Nagar, Jammu (J&k), India. Pin -180010
Email: puneetgupta619@yahoo.com
Telephone: +91 9622136600

Received: July 25, 2018

Revised: November 28, 2018

Accepted: November 30, 2018

Published online: February 26, 2019

ABSTRACT

Malignant obstructive jaundice is most commonly caused by pancreatic, gall bladder and biliary tract malignant pathologies. Minimally invasive procedures like Percutaneous Transhepatic Biliary Drainage (PTBD) plays an important role in the management of these patients. It is most often used as a palliative procedure, aiming to relieve the symptoms (pruritis, cholangitis etc.) and improve the quality of life, and it also reduces the morbidity associated with the disease, although it is not going to alter the basic disease prognosis. It is a safe & cost effective method of biliary

drainage in obstructive jaundice. Here we discuss the indications, technique, contraindications and complications of the PTBD procedure performed in patients with malignant biliary obstruction. The risk of complications is outweighed by far the advantages achieved by establishment of definitive biliary decompression.

Key words: Percutaneous Transhepatic Biliary Drainage; Obstructive Jaundice; Bile duct; Malignant Biliary obstruction; Interventional radiology

© 2019 The Author(s). Published by ACT Publishing Group Ltd. All rights reserved.

Sharma A, Sharma R, Gupta P, Bhan R. Percutaneous Transhepatic Biliary Drainage is Effective in Palliative Management of Malignant Obstructive Jaundice. *International Journal of Radiology* 2019; 6(1): 212-216 Available from: URL: <http://www.ghrnet.org/index.php/ijr/article/view/2387>

INTRODUCTION

Jaundice is described as yellowish discoloration of skin & sclera of the eyes due to high bilirubin content in the body. It could be due to medical or surgical causes. Surgical reasons are further categorized into benign or malignant causes.

Pancreatic and hepatobiliary malignancies constitute the most common reasons for malignant obstructive jaundice. Other causes include liver metastases and metastatic nodes. For practical purposes, malignant obstructive jaundice is divided into intrahepatic and extrahepatic biliary obstruction. Surgery is the ideal treatment in these patients, but only about 10-15% of these cases are resectable. Rest of the patients have a grim prognosis in terms of survival and quality of life.

Obstructed bile flow causes severe pruritis, malabsorption, occasionally cholangitis, and progressive hepatic failure. Pruritis is usually relieved by the drainage of even a single liver segment^[1].

There are two main options for palliative relief of biliary obstruction: (1) Surgical decompression by using biliary enteric anastomosis; and (2) Non surgical methods, in which an endoprosthesis is placed via transhepatic or transduodenal routes.

Both endoscopic retrograde cholangiopancreatography (ERCP)

and PTBD have well established and effective role of palliation in unresectable cases. ERCP is usually performed in cases of distal common bile duct (CBD) block beyond hilum, whereas PTBD is preferred in cases of proximal biliary obstruction^[2]. Use of both these minimally invasive procedures over surgical bypass has significantly increased in recent times due to higher success rates^[3].

Bismuth-Corlette classification (Table 1) is used worldwide for the classification of hilar cholangiocarcinoma, which is based on the status of primary and secondary confluence.

PTBD is indicated in a number of conditions including palliation of biliary obstruction in patients with unresectable malignant disease, biliary stones (acute suppurative cholangitis with obstruction), conditions where ERCP is not possible (e.g. post surgical anatomy).

PTBD is contraindicated in patients with advanced cirrhosis, coagulopathy, and moderate to massive ascites.

Complications associated with PTBD includes hemobilia (significant in 3%), hemorrhage, hepatic arteriovenous fistula or pseudoaneurysm, bile leak at skin site, contrast reactions and pneumothorax (rare).

MATERIALS AND METHODS

Study period

The prospective study was conducted in post graduate department of radio-diagnosis in association with post graduate department of surgery, in a tertiary care hospital for a period of 12 months.

Inclusion criteria

Patients of malignant obstructive jaundice not amenable to surgical treatment (inoperable), those requiring decompression of bile duct before going for definitive surgery and patients who were not candidates for endoscopic intervention.

Exclusion criteria

Patients with significant ascites, advanced cirrhosis and intractable coagulopathy were excluded from the study.

Material

Ultrasound machine, Chiba needle, guide wire, external drainage catheter, dilators, suture - silk 1 no. Cutting, drain bag, X-ray machine.

Methods

PTBD was performed after proper pre operative preparation.

Technique

Procedure was performed under all aseptic precautions. After giving local anaesthesia (lignocaine 2%), attempt was made to puncture bile duct under ultrasound guidance. Site of puncture was decided after performing ultrasound (Figure 1, 2).

We preferred left sided approach where procedure was performed through sub xiphoid space & left sided duct was punctured (seldinger technique).

An attempt was made to puncture a dilated peripheral bile duct as this limits the risk of injuring a major vessel near the hilum and ensures an adequate number of side holes in the catheter above the obstruction for effective drainage (Figure 3). Puncture needle with guide wire followed by single drain catheter was placed at initial encounter with the patient (Figure 4, 5). X-ray abdomen was taken immediately after injecting water soluble dye through external catheter (Figure 6, 7).

Table 1 Bismuth–Corlette classification for hilar cholangiocarcinoma.

Type	
1	Proximal Common hepatic and biliary duct block: Primary confluence patent
2	Primary confluence blocked, secondary patent
3	Secondary confluence blocked (unilateral)
3a	Right secondary confluence blocked
3b	Left secondary confluence blocked
4	Bilateral secondary confluence blocked

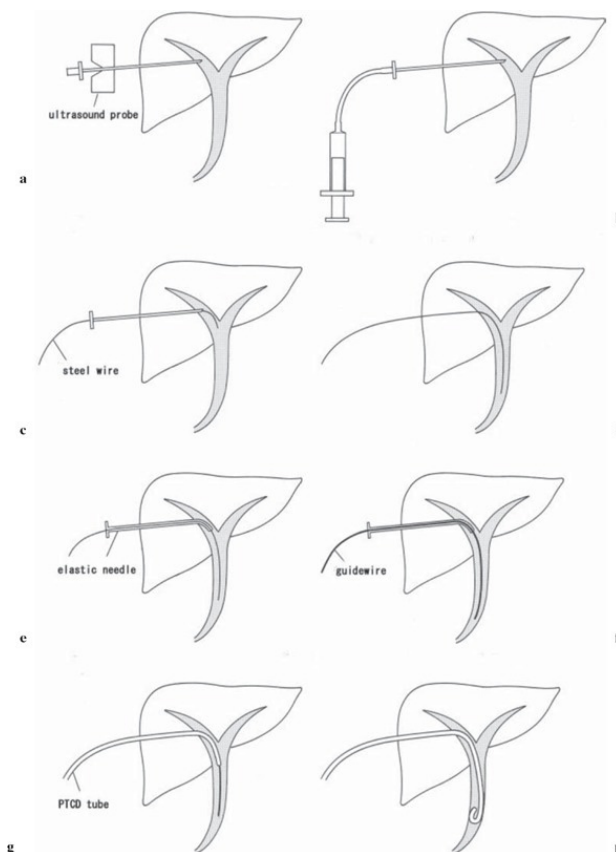


Figure 1 Technique of PTBD.

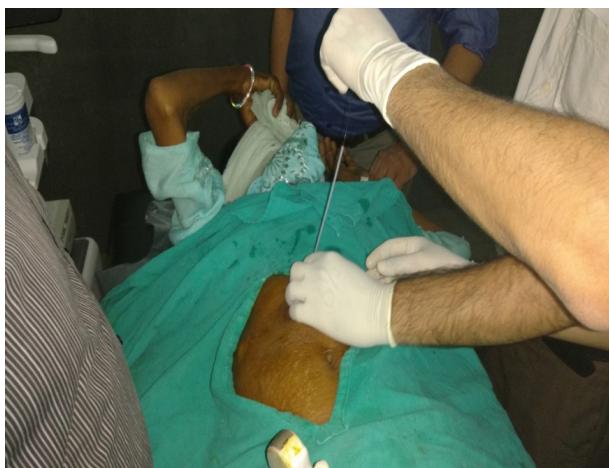

Figure 2 PTBD being performed under USG guidance.

Further interventions were withheld until the serum bilirubin level had stabilized.

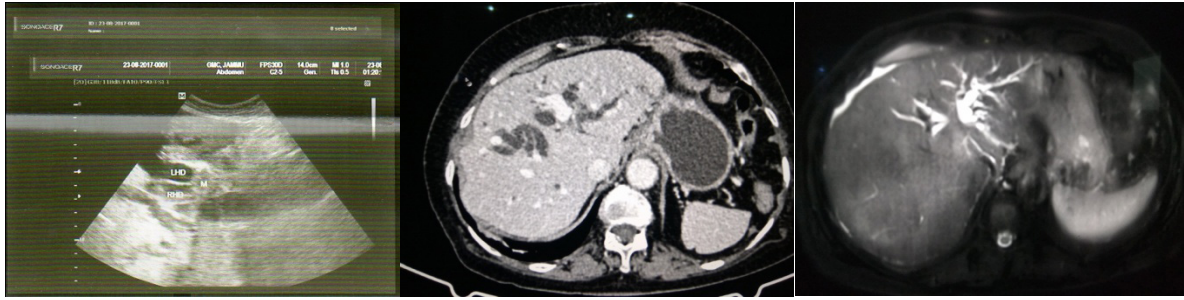

Figure 3 USG, CT and MRCP images showing dilated biliary radicals.

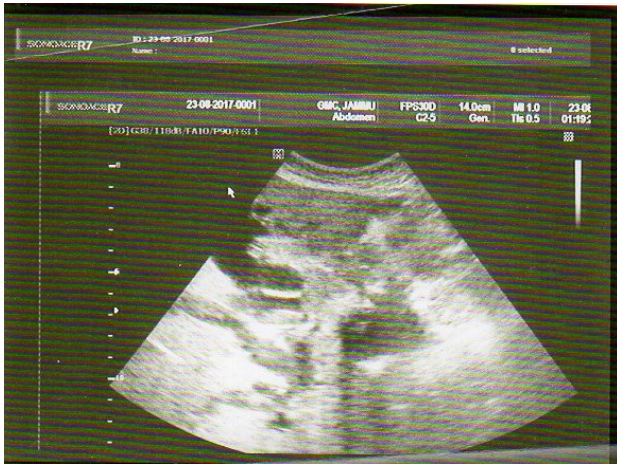


Figure 4 USG showing puncture needle inside biliary radical.

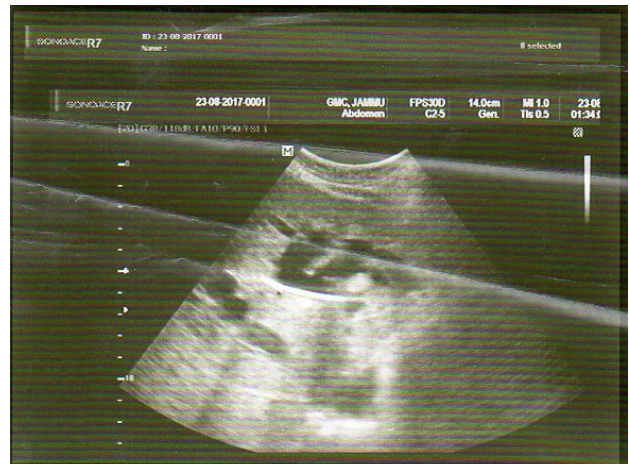

Figure 5 Puncture needle being withdrawn & guidewire being inserted.

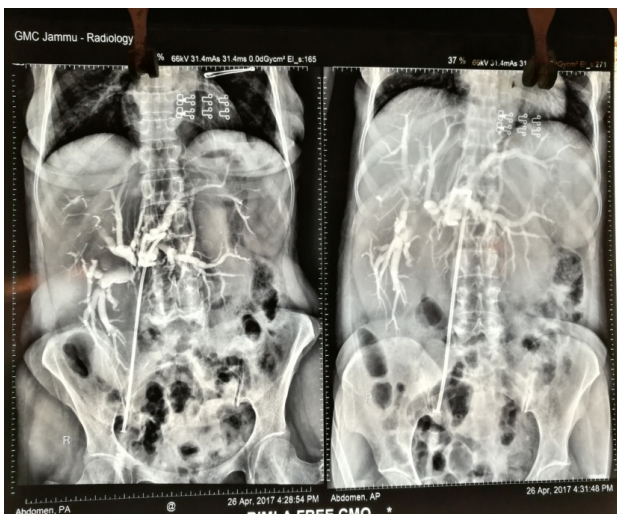


Figure 6 X-ray abdomen taken after injecting water soluble dye through external catheter.

RESULTS

Patients who underwent PTBD were in the age group of 35-80 years. Most of the patients fell in age group of 45-74 years with mean age of 58 years (Table 2) with 22 of them being female & rest male (Table 3).

After taking proper history, clinical examination & required investigations, the diagnosis was established. Most of the patients had carcinoma of gall bladder, with few having cholangiocarcinoma. Some patients with obstructive jaundice had ovarian malignancy, & 1 patient had hepatocellular carcinoma (Table 4).

After checking & correcting the coagulation profile of the patient,

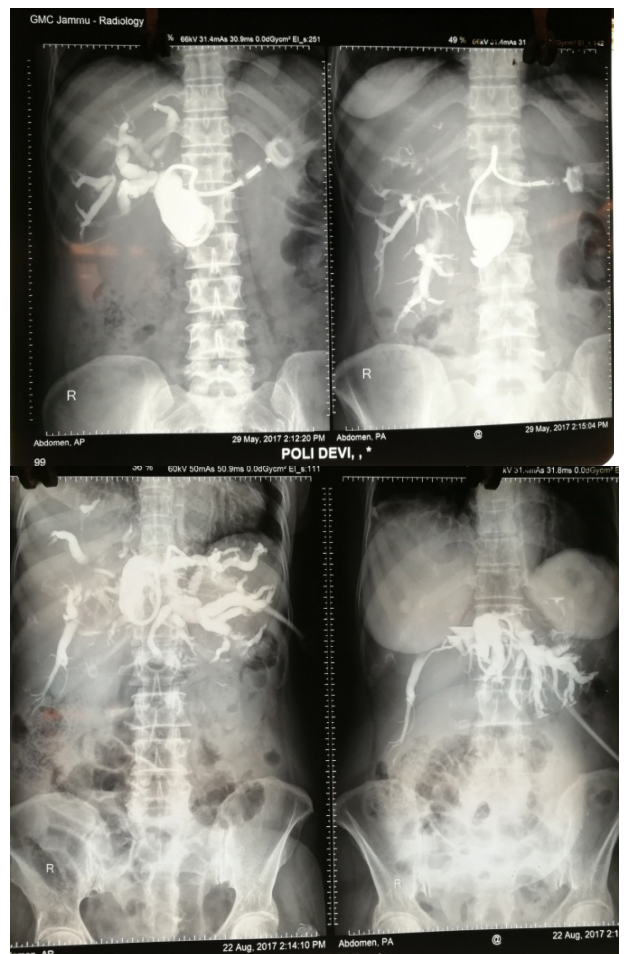


Figure 7 X-ray showing dilated biliary radicals with pig tail in situ.

PTBD was done under ultrasonography. 10 Fr. pig tail catheter was inserted in the most prominent biliary duct & properly fixed with silk suture. This was followed by the X-ray abdomen done for delineating the tract by giving water soluble dye (iohexol) to check for the patency & proper delineation of the biliary tract.

Liver function tests of the patient were done with emphasis on Serum bilirubin (S. Bil.), Serum glutamic oxaloacetic transaminase (S.G.O.T), Serum glutamic pyruvic transaminase (S.G.P.T) & Serum alkaline phosphatase (S. ALP). Patients were asked about the symptoms of pruritus & nausea before & after intervention.

S.Bil.

Mean fall in S.Bil was 4.1mg% with maximum fall being 9mg%. The fall was stastically significant with *p* value being < 0.001 (Table 5).

S.G.O.T.

Patients were found to have fall in the S.G.O.T values with maximum fall being 257 units per litre. Although one patient was found to have raised value after intervention, fall was stastically significant with *p* value of 0.024 (Table 6).

S.G.P.T

The mean value of S.G.P.T before intervention was 79 & after intervention was 75. Although fall was seen in most patients, the fall was not stastically significant with *p* value of 0.204 (Table 7).

S.Alk. Phosphatase

Patients were found to have tremendous fall in ALP with mean fall of 430.6 international units per litre. The fall was stastically significant with *p* value of <0.001 (Table 8).

Pruritus & Nausea

Most of the patients had improvement in both pruritus & nausea. Although a small minority of patients didn't feel significant improvement in the symptoms, the improvement was stastically significant (Table 9, 10).

None of our patients had any immediate post- procedure complication. Dislodgement of pig tail catheter occurred in 2 patients which was managed appropriately.

DISCUSSION

Malignant obstructive jaundice is a common clinical problem and can occur due to variety of causes^[4]. Since, the resectability rate of these malignant tumours is lower than 10%^[5], palliative treatment is highly recommended, in view of the shorter life expectancy^[6]. Interventional radiologist plays an important role in the management of patients with malignant biliary obstruction.

The current treatment options for malignant obstructive jaundice include surgery and percutaneous / endoscopic interventions. At the time of diagnosis, 90% of patients with malignant obstructive jaundice may benefit from palliative treatment only^[7]. The objective of palliation is to relieve jaundice related symptoms and prevent cholangitis^[8].

PTBD is a well-established procedure used for decompression of intrahepatic and extra-hepatic bile ducts. Successful biliary drainage alleviates jaundice, improves liver function, and has a positive impact on quality of life^[9].

In our study, most frequent diagnosis was carcinoma of gall bladder (*n* = 19), followed by cholangiocarcinoma (*n* = 7), with few cases being due to metastasis from other sites. PTBD was done in

Table 2 Age distribution of study patients.

Age (years)	Frequency	Percentage
30-44	3	10
45-59	11	36.7
60-74	13	43.3
≥ 75	3	10
Total	30	100

Mean ± SD (Range) = 58.8 ± 12.3 (35-85).

Table 3 Gender distribution of study patients

Gender	Frequency	Percentage
Male	8	26.7
Female	22	73.3
Total	30	100

Table 4 Distribution of study patients according to diagnosis.

Diagnosis	Frequency	Percentage
Ovarian Carcinoma With Liver Metastasis	3	10
Ca Gall Bladder	19	63.3
Cholangiocarcinoma	7	23.3
Hepatocellular Carcinoma With Metastasis	1	3.3
Total	30	100

Table 5 Showing serum bilirubin before and after PTBD among study patients.

Serum Bilrubin	N	Mean	SD	Min	Max	P-value
Pre PTBD	30	17.6	3.81	10.8	24.3	<0.001*
Post PTBD	30	13.5	2.76	8.3	20	

Table 6 Showing SGOT before and after PTBD among study patients.

SGOT	N	Mean	SD	Min	Max	P-value
Pre PTBD	30	111.1	72.26	46	407	0.024*
Post PTBD	30	88.6	26.61	46	150	

Table 7 Showing SGPT before and after PTBD among study patients.

SGPT	N	Mean	SD	Min	Max	P-value
Pre PTBD	30	79	22.82	40	120	0.204
Post PTBD	30	75.9	18.02	40	100	

Table 8 Showing serum alkaline phosphatase before and after PTBD among study patients.

Serum Alkaline Phosphatase	N	Mean	SD	Min	Max	P-value
Pre PTBD	30	1303.8	311.16	616	1945	<0.001*
Post PTBD	30	873.2	282.2	88	1483	

Table 9 Showing incidence of pruritus before and after PTBD in study patients.

Pruritus	Pre PTBD		Post PTBD		P-value
	No.	%age	No.	%age	
Yes	28	93.3	3	10	<0.001*
No	2	6.7	27	90	
Total	30	100	30	100	

Table 10 Showing incidence of nausea before and after PTBD in study patients

Nausea	Pre PTBD		Post PTBD		P-value
	No.	%age	No.	%age	
Yes	23	76.7	2	6.7	<0.001*
No	7	23.3	28	93.3	
Total	30	100	30	100	

all these patients with 100% success rate. The intervention was done with the aim of providing palliative relief to the patients.

We did left sided puncture in all the patients & it was able to reduce bilirubin levels significantly^[9]. The mean serum bilirubin value fell to 76% of its original value on 1st post procedure day in our study. Mean fall in serum bilirubin was 4.1 mg% on day 1 and the mean fall in serum bilirubin was 227 $\mu\text{mol/l}$ (13.7 mg% after correction) at 1 month follow up^[10,11]. The fall in bilirubin in our study noted on 1st post procedure day was statistically significant also (p value < 0.001).

Acceptable results were found in the value of serum alkaline phosphatase levels which fell to 67% of their original value on 1st post operative day and the mean fall in serum alkaline phosphatase was 430.6 IU/L^[10]. This very high fall may be because of the long course of obstruction that was present in our patients. This fall was also statistically significant (p value < 0.001).

In our study we also observed an improvement in the symptoms of pruritus & nausea. As many as 90% & 93.3% of our patients showed improvement in pruritus & nausea, respectively (Table 8, 9). Some patients also noticed an increase in appetite although this was not recorded in all patients. There was definite improvement in the complaints of itching & nausea by the patients seen in our study.

The mean fall in S.G.P.T levels was 4.9 IU/L in our study while it was 35 IU/L for Shao *et al*^[11]. This low level of fall in our study may be due to the value measured at different times following intervention which was at day 1 in our case & at 1 month in case of Shao *et al*^[11]. Nevertheless, the fall in S.G.P.T levels were not statistically significant (p value 0.204).

In S.G.O.T levels also, the mean fall in levels was 22.5 IU/L. The decline in S.G.O.T was seen in most patients and was statistically significant with p value 0.024.

CONCLUSION

In conclusion, percutaneous management of malignant biliary obstruction is a well-established method of treatment for lesions involving upper end of CBD. It provides effective measure of decompressing the biliary tract with tremendous improvement in the quality of life also. Appropriate pre-procedure planning and complete knowledge of the available techniques, success rates and risk of complications is needed for a successful procedure.

We recommend the procedure for palliative care of such terminally ill patients to relieve the problem of obstructive jaundice as well as for symptomatic relief. The procedure is also cost effective, & is not too demanding with regard to installation of too many expensive equipments.

REFERENCES

- Chandrashekhara SH, Gamanagatti S, Singh A, Bhatnagar A. Current status of percutaneous transhepatic biliary drainage in palliation of malignant obstructive jaundice: A review. *Indian J Palliat Care* 2016; **22**(4): 378-387. [PMID: 27803558]; [DOI: 10.4103/0973-1075.191746].
- Covey AM, Brown KT. Percutaneous transhepatic biliary drainage. *Tech Vasc Interv Radiol* 2008; **11**(1): 14-20. [PMID: 18725138]; [DOI: 10.1053/j.tvir.2008.05.003].
- Van Delden OM, Lameris JS. Percutaneous drainage and stenting for palliation of malignant bile duct obstruction. *Eur Radiol* 2008; **18**(3): 448-456. [PMID: 17960388]; [DOI: 10.1007/s00330-007-0796-6].
- Qureshi WA. Approach to the patient who has suspected acute bacterial cholangitis. *Gastroenterol Clin North Am* 2006; Jun; **35**(2): 409-423. [PMID: 16880073]; [DOI: 10.1016/j.gtc.2006.05.005].
- Bjornsson E, Gustafsson J, Borkman J, Kilander A. Fate of patients with obstructive jaundice. *J Hosp Med* 2008 Mar; **3**(2): 117-123. [PMID: 18438808]; [DOI: 10.1002/jhm.272].
- Brountzos EN, Ptochis N, Panagiotou I, Malagari K, Tzavara C, Kelekis D. A Survival Analysis of Patients with Malignant Biliary Strictures Treated by Percutaneous Metallic Stenting. *Cardiovasc Intervent Radiol* 2007; **30**(1): 66-73. [PMID: 17031733]; [DOI: 10.1007/s00270-005-0379-3].
- Qian X J, Zhai R Y, Dai D K, Yu P, Gao Li. Treatment of malignant biliary obstruction by combined percutaneous transhepatic biliary drainage with local tumor treatment. *World J Gastroenterol*. 2006; **12**(2): 331-335. [DOI: 10.3748/wjg.v12.i2.331].
- Van Delden OM, Lameris JS. Percutaneous drainage and stenting for palliation of malignant bile duct obstruction. *Eur Radiol* 2008; **18**(3): 448-456. [PMID: 17960388]; [DOI: 10.1007/s00330-007-0796-6].
- Gamanagatti S, Singh T, Sharma R, Srivastava DN, Dash NR, Garg PK. Unilobar versus bilobar biliary drainage: effect on quality of life and bilirubin level reduction. *Indian J Palliat Care* 2016; **22**(1): 50-62. [PMID: 26962281]; [PMCID: PMC4768450]; [DOI: 10.4103/0973-1075.173958].
- Aggarwal R, Patel FD, Kapoor R, Kang M, Kumar P, Chander Sharma S. Evaluation of high-dose-rate intraluminal brachytherapy by percutaneous transhepatic biliary drainage in the palliative management of malignant biliary obstruction--a pilot study. *Brachytherapy* 2013; **12**(2): 162-170. [PMID: 23186613]; [DOI: 10.1016/j.brachy.2012.06.002].
- Shao JH, Fang HX, Li GW, He JS, Wang BQ, Sun JH. Percutaneous transhepatic biliary drainage and stenting for malignant obstructive jaundice: A report of two cases. *Exp Ther Med*. 2015; **10**(94): 1503-1506. [PMID: 26622515]; [PMCID: PMC4578101]; [DOI: 10.3892/etm.2015.2701].