

Adult Case of Interhemispheric Cyst Associated With Corpus Callosum Agenesis

Yasushi Shibata, MD, PhD

Yasushi Shibata, Department of Neurosurgery, Mito Medical Center, University of Tsukuba, Mito Kyodo General Hospital, Mito, Ibaraki, 3100015, Japan

Conflict-of-interest statement: The author(s) declare(s) that there is no conflict of interest regarding the publication of this paper.

Open-Access: This article is an open-access article which was selected by an in-house editor and fully peer-reviewed by external reviewers. It is distributed in accordance with the Creative Commons Attribution Non Commercial (CC BY-NC 4.0) license, which permits others to distribute, remix, adapt, build upon this work non-commercially, and license their derivative works on different terms, provided the original work is properly cited and the use is non-commercial. See: <http://creativecommons.org/licenses/by-nc/4.0/>

Correspondence to: Yasushi Shibata, Department of Neurosurgery, Mito Medical Center, University of Tsukuba, Mito Kyodo General Hospital, Miyamachi 3-2-7, Mito, Ibaraki, 3100015, Japan.
Email: yshibata@md.tsukuba.ac.jp
Telephone: +81-29-231-2371
Fax: +81-29-231-5137

Received: September 28, 2018

Revised: December 28, 2018

Accepted: December 30, 2018

Published online: February 26, 2019

ABSTRACT

INTRODUCTION: Most reported cases of interhemispheric cyst associated with corpus callosum agenesis are child. We report adult case of these anomalies who is working in usual social life.

CASE REPORT: Thirty-eight-year-old man visited our hospital complaining with dull headache. Brain Computed Tomography showed interhemispheric cyst, corpus callosum agenesis and large sulcus at right cerebral hemisphere. Magnetic Resonance Imaging showed ectopic gray matter and no communication between cyst and ventricles. Intelligence test revealed generally lower Intelligent Quotient. Brain Magnetic Resonance Angiography was normal.

DISCUSSION: Only a few adult cases of interhemispheric cyst

associated with corpus callosum agenesis has been reported. Radiological findings were resembling with other central nervous system anomalies, such as schizencephaly. Neurologist and neurosurgeon who usually working for adult patients are not familiar with central nervous system anomalies. So adult cases of central nervous system anomalies should be educated and discussed.

Key words: Interhemispheric cyst; Corpus callosum agenesis; Adult

© 2019 The Author(s). Published by ACT Publishing Group Ltd. All rights reserved.

Shibata Y. Adult Case of Interhemispheric Cyst Associated With Corpus Callosum Agenesis. *International Journal of Radiology* 2019; 6(1): 205-207 Available from: URL: <http://www.ghrnet.org/index.php/ijr/article/view/2472>

INTRODUCTION

Most reported cases of interhemispheric cyst associated with corpus callosum agenesis are child. Most of these patients present as mental retardation and epilepsy. We report incidentally found adult case of these anomalies who is working in usual social life. Differential diagnosis from other central nervous system anomalies, such as schizencephaly, may be necessary.

CASE REPORT

Thirty-eight-year-old man visited our hospital complaining with dull headache. His head size has been relatively large, and his height has been relatively short since his childhood. His mental and physical development has been within normal. He does not have any specific past and family history. He graduated a high school and a career college. He has worked as a security staff. He himself noticed that he is not good at both of intellectual and physical activities. His vital signs and neurological examination showed normal. Wechsler Adult Intelligence Scale showed Verbal Intelligent Quotient(IQ) 77, Performance IQ 70, Total IQ 71, these are generally lower than normal.

Brain Computed Tomography (CT, Figure 1) showed ventriculomegaly, interhemispheric cyst, corpus callosum agenesis

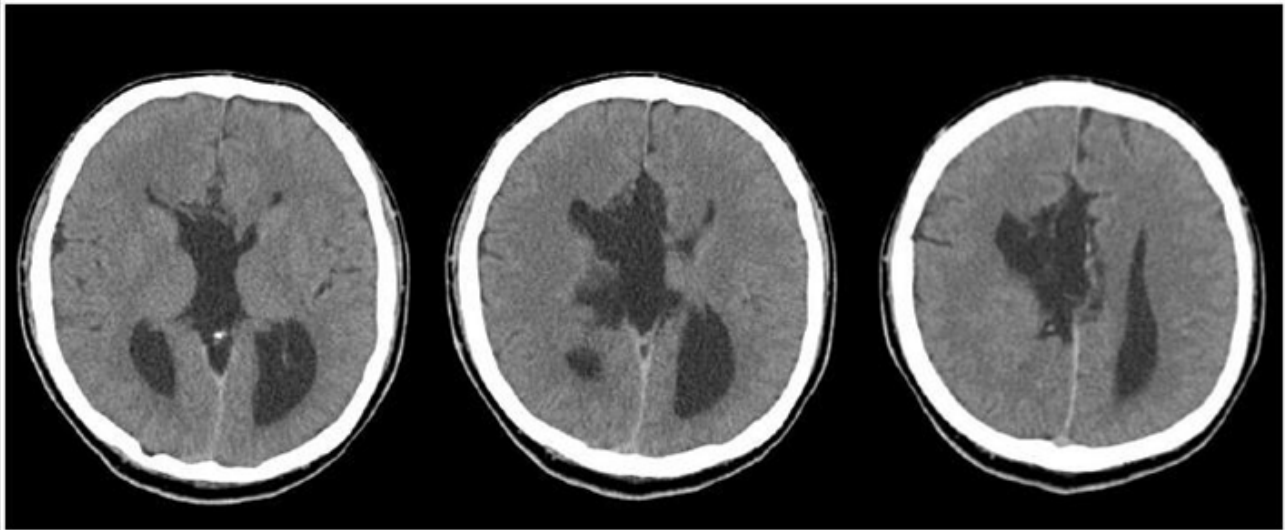


Figure 1 Axial Brain CT.

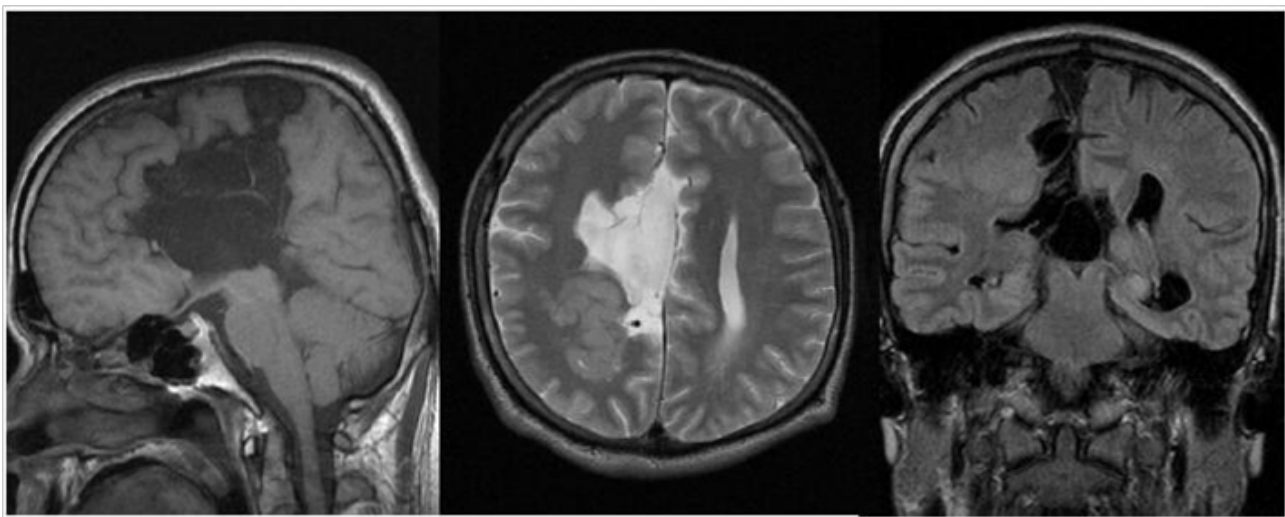


Figure 2 Brain MRI, T1 sagittal(Left), T2 axial(Middle), FLAIR coronal(Right).

and large sulcus at right hemisphere. Falx was normal. Magnetic Resonance Imaging (MRI, Figure 2) showed ectopic gray matter and no communication between cyst and ventricles. Brain Magnetic Resonance Angiography (MRA) and cervical X-p were normal. We diagnosed his nervous system anomaly as interhemispheric cyst associated with corpus callosum agenesis. His headache was diagnosed as tension type headache.

DISCUSSION

The variable symptoms of interhemispheric cyst associated with corpus callosum agenesis are reported, however, most reported patients were children. Only a few adult cases of interhemispheric cyst associated with corpus callosum agenesis has been reported^[1-4]. Zingesser *et al* reported incidentally diagnosed post-traumatic patients as inter-hemispheric arachnoid cyst, however autopsy pathological findings demonstrated cyst wall was formed by astrocytes and glial tissue^[1], so this cyst was neuroepithelial cyst, not arachnoid cyst. Solt *et. al.* reported symptomatic neuroepithelial interhemispheric cyst in 64-year-old man. Frontal headache and paraparesis were improved after cyst opening surgery. Schwartz *et al* reported 57-year-old female, neurologically asymptomatic until she had a seizure during hemodialysis^[3]. This patient expired after craniotomy surgery with

general complications. Surgically removed interhemispheric cyst wall showed ciliated columnar epithelium resembling colloid cysts. Mori reported 54-year-old man with normal psychomotor development complaining dull occipitalgia^[4]. The patient has been followed without surgery. Among these adult case reports, only one case report included MRI findings^[4].

Natural history of interhemispheric cysts associated with corpus callosum agenesis is not clear, because of scanty reported cases. Most reported cases found incidentally, and increased availability of neuroimaging may bring increase of incidentally found these cases. Radiological findings were resembling with other central nervous system anomalies, such as arachnoid cyst, porencephaly, holoprosencephaly, and schizencephaly. Neurologist and neurosurgeon who usually working for adult patients are not familiar with central nervous system anomalies. So adult cases of central nervous system anomalies should be educated and discussed.

REFERENCES

1. Zingesser L, Schechter M, Gonatas N, Levy A, Wisoff H. Agnesis of the Corpus Callosum Associated with an Inter-Hemispheric Arachnoid Cyst. *Br J Radiol* 1964; **37**: 905-909. [PMID: 14238657 DOI: 10.1259/0007-1285-37-444-905]

2. Solt LC, Deck JHN, Baim RS, TerBrugge K. Interhemispheric cyst of neuroepithelial origin in association with partial agenesis of the corpus callosum. *Journal of Neurosurgery* 1980; **52**: 399-403. [PMID: 7359196 DOI: 10.3171/jns.1980.52.3.0399]
3. Schwartz AM, Ghatak NR. Interhemispheric cysts in association with agenesis of the corpus callosum. *Clin Neuropathol* 1990; **9**: 177-180. [PMID: 2225594]
4. Mori K. Giant interhemispheric cysts associated with agenesis of the corpus callosum. *Journal of Neurosurgery* 1992; **76**: 224-230. [PMID: 1730951 DOI: 10.3171/jns.1992.76.2.0224]