

Multiple Biliary Hamartoma Masquerading Polycystic Liver Disease-A Case Report

Sri keerthi. K, Siddharth Srinivasan, Aniket Khadatkhar, JK Banerjee, Mangal Mahajan, Mrunal N Ketkar

Dr. Sri keerthi. K, Resident, Department of Surgery, BHRC, Pune;
Dr. Siddharth Srinivasan, Resident, Department of Surgery, BHRC, Pune;
Dr. Aniket Khadatkhar, Asst Professor (General Surgery) and Fellow in Hepatobiliary surgery, BHRC, Pune;
Dr. JK Banerjee, Professor, Department of GI and Hepatopancreaticobiliary surgery; BHRC, Pune;
Dr. Mangal Mahajan- Professor, Department of Radiodiagnosis, BHRC, Pune;
Dr. Mrunal N Ketkar, Professor and HOD, Department of Surgery, BHRC, Pune.

Conflict-of-interest statement: The author(s) declare(s) that there is no conflict of interest regarding the publication of this paper.

Open-Access: This article is an open-access article which was selected by an in-house editor and fully peer-reviewed by external reviewers. It is distributed in accordance with the Creative Commons Attribution Non Commercial (CC BY-NC 4.0) license, which permits others to distribute, remix, adapt, build upon this work non-commercially, and license their derivative works on different terms, provided the original work is properly cited and the use is non-commercial. See: <http://creativecommons.org/licenses/by-nc/4.0/>

Correspondence to: Dr. Aniket Khadatkhar, Asst Professor (General Surgery) and Fellow in Hepatobiliary surgery, BHRC, Pune.
Email: kskasturi811@gmail.com
Telephone: +9975017057

Received: December 16, 2019
Revised: December 26, 2019
Accepted: December 29, 2019
Published online: March 16, 2020

ABSTRACT

INTRODUCTION: Multiple Biliary Hamartomas are rare and asymptomatic and so are diagnosed less *in vivo*. They are benign malformation of ductal plate of intrahepatic biliary radicals. Patients are usually asymptomatic and the lesions are an incidental radiological finding. They maybe mistaken with liver metastasis, microabscess and other cystic lesions of liver. We report a 45

year old female who had vague right upper quadrant pain on and off for a year. She was diagnosed as extensive multiple biliary hamartomas on CT and MRI of the abdomen. Tumors markers were negative suggesting absence of malignancy. She was managed with symptomatic treatment and is on regular follow up.

Key words: Multiple Biliary Hamartomas; Von Meyenberg complexes (VMC)

© 2020 The Author(s). Published by ACT Publishing Group Ltd. All rights reserved.

Keerthi K, Srinivasan S, Khadatkhar A, Banerjee JK, Mahajan M, Ketkar MN. Multiple Biliary Hamartoma Masquerading Polycystic Liver Disease-A Case Report. *International Journal of Radiology* 2020; 7(1): 234-236 Available from: URL: <http://www.ghrnet.org/index.php/ijr/article/view/2758>

CASE REPORT

We report a 45 year old female patient who presented with vague right upper quadrant pain on and off since one year. There was no history of jaundice, weight loss, loss of appetite or any constitutional symptoms. Family and past history were not contributory. Clinically she had gross hepatomegaly with a liver span measuring 24 cm and nodular surface of liver. There was no ascites. Systemic examination was unremarkable.

Ultrasonography of abdomen revealed gross hepatomegaly with multiple cystic lesions in the liver. Abdominal computed tomography confirmed hepatomegaly and liver being studded with numerous cystic lesions. These lesions showed no enhancement on post-contrast images. No calcification, fat component or central dot sign were seen. Liver was enlarged measuring 24 cm craniocaudally. All the segments of both the lobes were studded with numerous well defined hypodense lesions, varying in sizes from 2 mm to 19 mm in size. The findings were suggestive of biliary hamartomas. On magnetic resonance imaging, few of these cysts showed fluid-fluid level on the T2WI suggesting intracystic bleed/secondary chronic infection. Four solid non-enhancing lesions in segment V, VII, IVA and VII/VIII were also noticed. Largest lesion was seated deep in segment VII/VIII indenting the intrahepatic IVC and abutting the hepatic veins, measuring 39.1 × 38.3 × 43.4 mm (Trans × AP × CC) in size

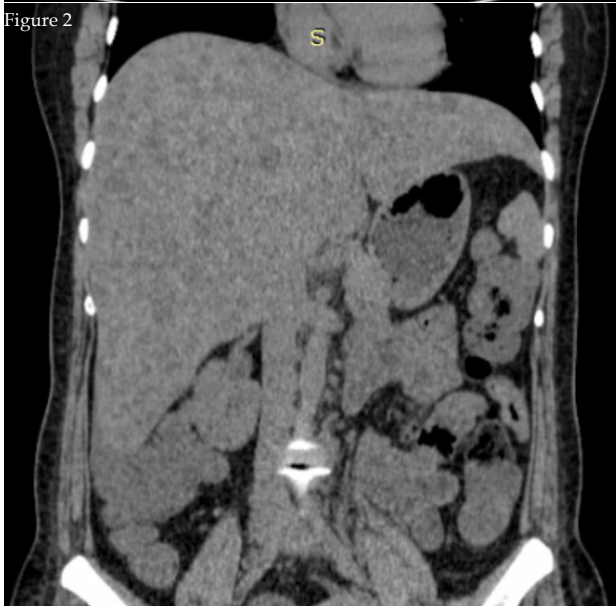
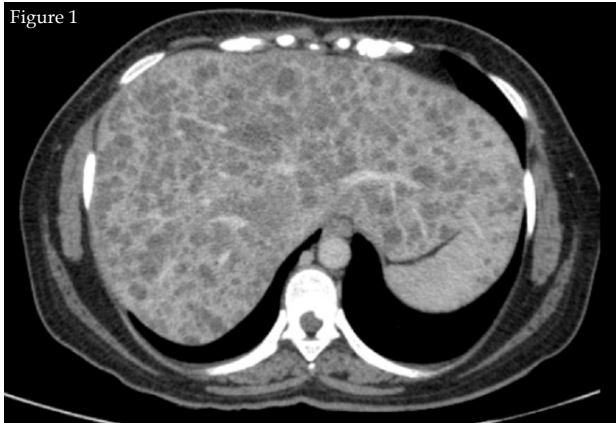

Figure 1 and 2 Showing multiple cystic lesions in liver on CT-scan. These lesions do not show enhancement on post-contrast images. No calcification and fat component seen within it. No central dot sign is seen.

showing cystic degeneration with fluid-fluid levels. These lesions were hypodense on CT and did not show enhancement on arterial, portal, venous and delayed phases. They showed restricted diffusion on MR.

Tumor markers AFP, CEA, CA-125, CA 19-9, Beta HCG were normal. Patient was managed symptomatically and advised regular follow-up.

DISCUSSION

Multiple benign hamartomas were first described by von Meyenberg in 1918, so also known as von Meyenberg complexes (VMC). The prevalence of multiple biliary hamartomas is approximately 3% at autopsy and on imaging it is around 1% because lesions less than 5mm are often difficult to find out on imaging^[1]. It is three times more common in females than in male^[2]. VMCs are benign malformations of ductal plate of intra hepatic bile duct. It can be associated with fibrocystic diseases of the liver, including congenital hepatic fibrosis, autosomal recessive polycystic kidney disease, bile duct atresia, Caroli's disease and mesenchymal hamartomas^[1,3,4,5]. Occasionally patient may present with jaundice due to mass effect. It is known to be associated with autosomal dominant polycystic kidney disease (ADPKD) and polycystic liver disease. There is a rare possibility of malignant transformation of multiple biliary hamartomas into

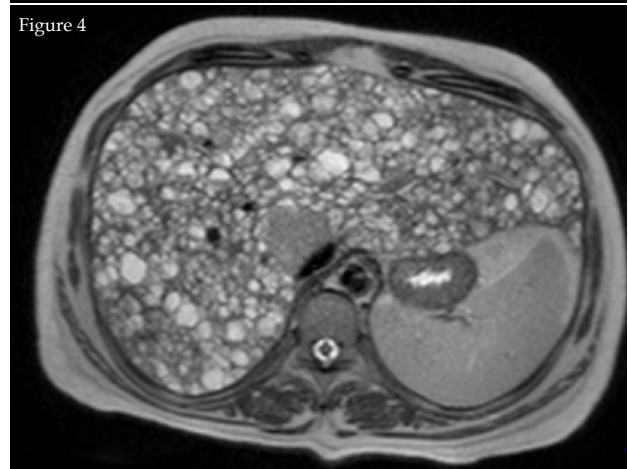
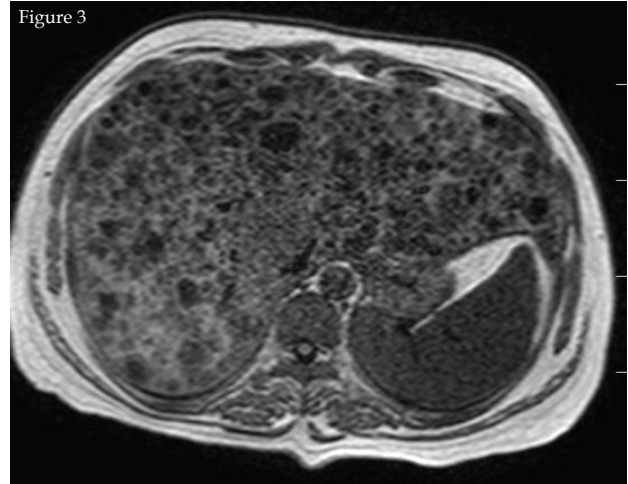


Figure 3 and 4 T1WI and T2WI on axial MRI showing well defined hypointense and hyperintense cysts respectively. Cysts were also indenting the intrahepatic IVC.

hepatocellular carcinoma and cholangiocarcinoma. The malignant transformation is due to the toxic effect of chronic biliary stasis^[6]. The pathogenesis of VMC is interruption of remodeling of the ductal plates during the late phase of embryonic development of intra hepatic bile ducts^[7]. They are well circumscribed, unencapsulated lesions throughout the liver although they may aggregate. On histology they appear as dilated small bile ducts with single layer of cuboidal epithelium with surrounded fibrous stroma. Biliary hamartomas are classified into three classes - class 1- predominantly solid pattern with narrow bile channels, class 2- intermediate pattern, class 3- marked cystic dilatation of bile ducts within the lesions^[7]. Because of different histological pattern, biliary hamartoma may exhibit different echogenicity on ultrasonography. There is association between biliary hamartomas and polycystic liver disease. In a study containing 70 cases done by Melnick, 29 cases had polycystic liver disease co existing with multiple biliary hamartomas. Melnick postulated that bile duct hamartomas arise when embryonic bile ducts fail to involute and polycystic liver disease result from gradual dilatation of hamartomas^[8]. On ultrasonography, biliary hamartomas can be hypo echoic or hyper echoic. CT scans can detect multiple, nodular and irregular cystic liver lesions, smaller than 15 mm. The use of CA 19-9 to diagnose malignant transformation is not routinely indicated because of persistent elevation of this tumor marker has been described in patients with multiple biliary hamartomas without malignancy. On MRI, the biliary hamartomas exhibit hypointensity compared with liver parenchyma on T1-

weighted image, and hyperintensity, but less than that of simple fluid, on T2-weighted image^{9,10,11}. Liver biopsy is not contra indicated and should be done if there is suspicion of malignancy. As evident in studies conducted by Homer, malignant transformation, though rare, is a possibility. Hence, when in doubt, a liver biopsy is warranted¹².

CONCLUSION

Multiple biliary hamartoma is a rare entity. Most of the patients are asymptomatic and are diagnosed incidentally. The radiological appearance of the same can typically mimic polycystic liver disease or metastatic liver disease. Even though subtle differences have been reported in imaging, evaluation in the form of histopathology or tumor markers is warranted to rule out malignancy. These particularly require regular follow-up to watch for malignant transformation and hence deserve emphasis.

REFERENCES

1. Chung EB. Multiple bile-duct hamartomas. *Cancer*. 1970 Aug; **26(2)**: 287-96. [PMID: 4317963]
2. Carla Tohmé-Noun, Dominique Cazals, Roger Noun, Lina Menassa, Dominique Valla & Valérie Vilgrain, Multiple biliary hamartomas: magnetic resonance features with histopathologic correlation. *Eur Radiol*. 2008; **18(3)**: 493-9. [PMID: 17934738]; [DOI: 10.1007/s00330-007-0790-z]
3. Desmet VJ. Ludwig symposium on biliary disorders-Part I. Pathogenesis of ductal plate abnormalities. *Mayo Clin Proc* 1998; **73**: 80-89. [DOI: 10.1016/S0025-6196(11)63624-0]
4. MacSween RNM, Anthony PP, Scheuer PJ, Burt AD, Portman BC. Pathology of the liver, 3rd ed. London: Churchill Livingstone; 1994. p 102, 679.
5. Lee RG. Diagnostic liver pathology. St. Louis: Mosby; 1994. p 408.
6. T. Orii, N. Ohkohchi, K. Sasaki, S. Satomi, M. Watanabe, T. Moriya. Cholangiocarcinoma arising from preexisting biliary hamartoma of liver-report of a case. *Hepato Gastroenterology*, 2003; 33-336 [PMID: 12749215]
7. Lev-Toaff AS, Bach AM, Wechsler RJ, Hilpert PL, Gatalica Z, Rubin R. The radiologic and pathologic spectrum of biliary hamartomas. *AJR Am J Roentgenol*. 1995 Aug; **165(2)**: 309-13. [PMID: 7618546]; [DOI: 10.2214/ajr.165.2.7618546]
8. Melnick PJ. Polycystic liver. Analysis of seventy cases. *AMA Arch Pathol*. 1955 Feb; **59(2)**: 162-72. [PMID: 13227714]
9. Slone HW, Bennett WF, Bova JG. MR findings of multiple biliary hamartomas. *AJR Am J Roentgenol*. 1993 Sep; **161(3)**: 581-3. [PMID: 8352110]; [DOI: 10.2214/ajr.161.3.8352110]
10. Gallego JC, Suarez I, Soler R. Multiple bile duct hamartomas: US, CT, and MR findings. A case report. *Acta Radiol*. 1995 May; **36(3)**: 273-5. [PMID: 7742121]
11. Cheung Y-C, Tan C-F, Wan Y-L, Lui K-W, Tsai C-C. Case report: MRI of multiple biliary hamartomas. *Br J Radiol*. 1997 May; **70(833)**: 527-9. [PMID: 9227236]; [DOI: 10.1259/bjr.70.833.9227236]
12. Homer LW, White HJ, Read AC. Neoplastic transformation of von Meyenburg complexes of the liver. *J Pathol Bacteriol*. 1968 Oct; **96(2)**: 499-502. [PMID: 5698714]; [DOI: 10.1002/path.1700960231]