

## Inaccurate Visual Grading Systems in Neuroradiology: Topic Highlights

Abdulwahab Alahmari<sup>1</sup>

<sup>1</sup> Radiology Specialist, Radiology Department, Al-Namas General Hospital, Ministry of Health, Namas, Saudi Arabia.

**Conflict-of-interest statement:** The author(s) declare(s) that there is no conflict of interest regarding the publication of this paper.

**Open-Access:** This article is an open-access article which was selected by an in-house editor and fully peer-reviewed by external reviewers. It is distributed in accordance with the Creative Commons Attribution Non Commercial (CC BY-NC 4.0) license, which permits others to distribute, remix, adapt, build upon this work non-commercially, and license their derivative works on different terms, provided the original work is properly cited and the use is non-commercial. See: <http://creativecommons.org/licenses/by-nc/4.0/>

**Correspondence to:** Abdulwahab Alahmari, Radiology Department, Al-Namas General Hospital, Ministry of Health, Namas, Saudi Arabia.  
Email: [afaa99@hotmail.co.uk](mailto:afaa99@hotmail.co.uk)  
Telephone: +0000-0002-9959-830

Received: April 14, 2020

Revised: April 28, 2020

Accepted: May 2, 2020

Published online: May 3, 2020

### ABSTRACT

There are many visual grading systems that have been used in neuroradiology like medial temporal lobe atrophy scale, global cortical atrophy scale, posterior atrophy rating scale of parietal atrophy, Fazekas scale, thrombolysis in cerebral infarction scale, etc. All these grading systems do not have any measurable values or grades based on numerate values. Instead, these grading systems depend on a personal opinion and visual estimation. This paper focus on the accuracy, practicality, and usability of these grading systems.

**Key words:** Medial temporal lobe atrophy (MTA); Global cortical atrophy scale; Posterior atrophy rating scale of parietal atrophy; White matter lesion grading system (Fazekas scale); Thrombolysis in cerebral infarction (TICI) scale

© 2020 The Author(s). Published by ACT Publishing Group Ltd. All rights reserved.

Alahmari A. Inaccurate Visual Grading Systems in Neuroradiology: Topic Highlights. *International Journal of Radiology* 2020; 7(1): 242-243 Available from: URL: <http://www.ghrnet.org/index.php/ijr/article/view/2683>

### INTRODUCTION

In neuroradiology, there are many visual grading systems for different neurological illness and conditions. The issue with these grading or scoring systems are depending on the personal estimation and opinion of the Neuroradiologist or Physician in charge. The estimation depends on the physician's experience, number of similar cases that the physician saw before, and the physician's personality. Due to the lack of specific measurable values, inaccurate criteria, broad visual standards, the estimation, and personal opinion could be wrong.

What is mild for someone is moderate for someone else. What is common in one race, age group, gender, or region is rare in another one. What is considered mild in a specific group of people due to abundance, it is considered severe in another group due to rareness.

Many visual grading systems like the MTA grading system which classify Alzheimer disease (AD) effect on hippocampal's parts see (Figures 1 and 2). MTA have been proven to be inaccurate in 1st and 2nd stages<sup>[1]</sup>. The MTA does not use measurable values, but it depends on the estimation which uses words like slightly, mild, moderate, severe, normal dilatation, normal aging, abnormal dilatation, etc. Instead of using measurable values with specific ranges that classify AD patients into a specific category or grade that is 100% accurate, they use uncertain scales which lead to making different medical decisions. The hippocampus can be measured by simple linear measurements from the alveus to the subiculum is the length of the hippocampus and from the temporal horn to the hippocampal gyrus is the hippocampal width. It's easy and it can categorize the patients into any grade by making a specific range for each grade. Another method –which is more difficult– is measuring the hippocampus' volume by a very advanced software then categorize the different volumes measurements into different grades. The values are collected from different patients to come up with a specific range for each grade. The issue with the volume measurements method, is difficult to be applied, need a specialist, and need an advanced software.

Another paper support the previous findings that the MTA grading system is not accurate in grade 1 and 2 similar to Alahmari findings<sup>[2]</sup>. Alahmari applied the MTA on 60 AD patients and the grading system showed that 30 of the 60 AD patient are normal and all of them are in

stages 1 and 2 based on normality analysis. MTA still used by Neurologists, Neuroradiologists, and Psychiatricians worldwide to evaluate AD and MCI patients which is an early stage of AD. Even though, it can't identify AD patients in stage 1 and 2. From a logical point of view, if a grading system can't detect stage 1 and 2 in AD patients (which are early stages of AD), how it can detect the MCI? (which is more earlier than stage 1 and 2 of AD). What is the use of a grading system that can identify AD patients in stage 3 and 4 only which is already known and confirmed as AD patient?

Another visual grading system is the global cortical atrophy scale for neurodegenerative diseases. This grading system uses terms like mild, moderate, and severe ventricle enlargement which is confusing. Ventricle enlargement can be classified based on simple linear measurements into a specific category<sup>[3]</sup>. If a grading system does not use measurable values, it will depend on different personal opinions. A good grading system will make different raters to have the same result.

As well, posterior atrophy rating scale of parietal atrophy for dementia is another case of misleading visual grading systems. This grading system uses terms like mild sulci widening, substantial gyri atrophy, marked widening or atrophy, and knife blade gyral atrophy. How someone can differentiate between a substantial or marked effect?

White matter lesion grading system or Fazekas scale is another grading system that is being used in neuroimaging. Fazekas scale is not being used in the clinical settings due to the use of words like mild, moderate, severe that are not favored by clinicians<sup>[4]</sup>. Even though, its widely used in academia and in publications<sup>[4]</sup>.

The visual grading systems are many, another example is the thrombolysis in cerebral infarction (TICI) scale which classify the perfusion in stroke patients. TICI was found to have a substantial differences in application and definition<sup>[5]</sup>.

All the previous grading systems have been tested in different published papers and they have been proven to be inaccurate, but still many medical professionals use these inaccurate systems to make different medical decisions which is illogical.

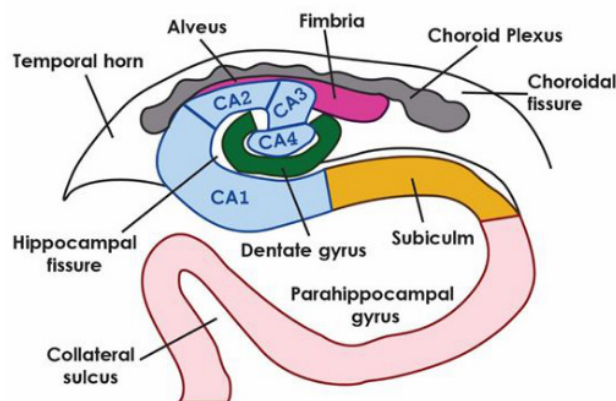
The medical societies like the American College of Radiology must have a role in endorsing or rejecting these systems. Any system that have been proved to be effective, practical, and accurate must be endorse. On the other hand, any system that have been proved to be inaccurate must be warn of using it until the system modified or fixed.

## CONCLUSION

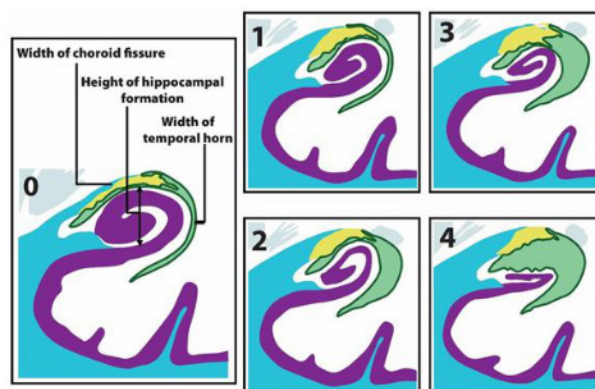
Any grading system should have a measurable values to categorize any disease into a specific category to understand the severity of the condition in any patient which will affect the medical decisions.

## REFERENCES

1. Alahmari AF. Comparison Of Medial Temporal Lobe Measurements On Mri Among Alzheimer'S Geriatric Patients: A Cross-Sectional Study. *PJR*. 2019; **29(1)**. Available from: <http://www.pakjr.com/ojs/index.php/PJR/article/view/1015/728>
2. Varon D, Barker W, Loewenstein D, Greig M, Bohorquez A, Santos I, et al. Visual rating and volumetric measurement of me-



**Figure 1** Hippocampus anatomy illustration (coronal section, illustration, and region of interest (ROI): Hippocampus, temporal horn, parahippocampal gyrus, alveus and subiculum). From the alveus to the subiculum is the length of the hippocampus and from the temporal horn to the hippocampal gyrus (parahippocampal gyrus) is the hippocampal width.



**Figure 2** The medial temporal lobe atrophy (MTA) grading system (coronal section, illustration, and ROI: Hippocampal formation, temporal horn, and choroid fissure). A value of 0 represents normal, stage 1 is characterized by the dilatation of the choroid fissure, stage 2 is characterized by the dilatation of the temporal horn, stage 3 is indicated by hippocampal atrophy, and stage 4 is exemplified by massive atrophy of the hippocampus.

dial temporal atrophy in the Alzheimer's Disease Neuroimaging Initiative (ADNI) cohort: baseline diagnosis and the prediction of MCI outcome. *Int J Geriatr Psychiatry*. 2015; **30(2)**: 192-200. [PMID: 24816477]; [DOI: 10.1002/gps.4126]. Available from: <https://onlinelibrary.wiley.com/doi/abs/10.1002/gps.4126>

3. Alahmari MAF. Common Measurements And Proposed Grading System For Hydrocephalus In Pediatric Patients By Using Ct Scan: A Cross Sectional Study. *PJR*. 2017; **27(4)**. Available from: <http://www.pakjr.com/ojs/index.php/PJR/article/view/742/629>
4. Gaillard F. Fazekas scale for white matter lesions: Radiology Reference Article [Internet]. Radiopaedia Blog RSS. Trend MD; 2014 [cited 2020Apr12]. Available from: <https://radiopaedia.org/articles/fazekas-scale-for-white-matter-lesions.rID:28447>.
5. Fugate JE, Klunder AM, Kallmes DF. What is meant by "TICI"? *Am J Neuroradiol*. 2013; **34(9)**: 1792-7. [PMID: 23578670]; [DOI: 10.3174/ajnr.A3496]. Available from: <http://www.ajnr.org/content/34/9/1792.long>