

Multidetector Computed Tomography in Evaluation of Orbital Injuries in Complex Facial Fractures

Noha Abdelfattah Ahmed Madkour¹

¹ Department of Radiodiagnosis and intervention radiology, Kasr Alainy Hospital, Cairo University, Egypt.

Conflict-of-interest statement: The author(s) declare(s) that there is no conflict of interest regarding the publication of this paper.

Open-Access: This article is an open-access article which was selected by an in-house editor and fully peer-reviewed by external reviewers. It is distributed in accordance with the Creative Commons Attribution Non Commercial (CC BY-NC 4.0) license, which permits others to distribute, remix, adapt, build upon this work non-commercially, and license their derivative works on different terms, provided the original work is properly cited and the use is non-commercial. See: <http://creativecommons.org/licenses/by-nc/4.0/>

Correspondence to: Noha Abdelfattah Ahmed Madkour, Department of Radiodiagnosis and intervention radiology, Kasr Alainy Hospital, Cairo University, Egypt.
Email: dmoahamadkour@kasralainy.edu.eg

Received: August 9, 2021

Revised: September 18, 2021

Accepted: September 22, 2021

Published online: October 1, 2021

ABSTRACT

BACKGROUND: Complex facial fractures were usually associated with orbital fractures. Multidetector computed tomography allows rapid detection of post-traumatic orbital and ocular injuries.

AIM: to evaluate orbital and ocular injuries in complex facial fractures using multidetector computed tomography.

METHODS: This study is a retrospective observational study where 38 male patients with complex facial fractures and orbital injuries due to motor vehicle accident were referred to the Emergency Unit, Radiodiagnosis department, Kasr Alainy Hospital, Cairo University. Multidetector computed tomography of the face was performed to all patients. Multidetector computed tomography and multiplanar images were analyzed for patterns of complex facial fractures and associated orbital and ocular injuries.

STATISTICS: Odds ratios and relative risk were calculated to determine risk of occurrence of orbital and ocular injuries in patients

with complex facial fractures.

RESULTS: the commonest orbital injury in complex facial fractures was periorbital hematoma. Right sided eye injuries (34.2 %) were more common than left ones (31.5%). Extra-ocular intraconal orbital complications (71%) were more common than ocular complications (7%) in patients with complex facial fractures with associated mandibular trauma. The risk of occurrence of ocular injuries in complex facial fractures without mandibular fractures (OR: 2.6, P-value: 0.38) was twice that in complex facial trauma with mandibular fractures.

CONCLUSION: multidetector computed tomography and multiplanar reformatted images were essential in evaluation of orbital complications in complex facial trauma. Orbital and ocular injuries were more common in multiple complex facial fractures than single types.

Key words: Complex facial fractures; Orbital; Multidetector computed tomography; Ocular injuries

© 2021 The Author(s). Published by ACT Publishing Group Ltd. All rights reserved.

Madkour NAA. Multidetector Computed Tomography in Evaluation of Orbital Injuries in Complex Facial Fractures. *International Journal of Radiology* 2021; **8(1)**: 328-331 Available from: URL: <http://www.ghrnet.org/index.php/ijr/article/view/3197>

INTRODUCTION

Complex facial fractures comprise zygomatico-maxillary complex fractures (ZMC), Le Fort fractures and naso-orbito-ethmoidal fractures (NOE) which are considered as a subset of midfacial fractures^[1,2,3,4].

Road traffic accidents were the main mode of injury in complex facial and orbital trauma^[5,6,7]. Multiple complex facial fractures were usually encountered in high accelerating vehicle trauma^[8,9].

Orbital fractures were common association in complex facial trauma^[10,11]. Orbital complications were frequent sequel of complex facial and orbital fractures^[10,12,13].

Multidetector computed tomography (MDCT) allows rapid and accurate early detection of post-traumatic orbital complications and ocular injuries^[14,15,16].

Objective of the study

To evaluate the frequency of orbital and ocular injuries in complex facial fractures using multidetector computed tomography.

PATIENTS AND METHODS

Patients

This study is a retrospective observational cohort study where 38 male patients with complex facial fractures with orbital injuries due to motor vehicle accidents (MVA) were referred to the Emergency Unit of Kasr Alainy Hospital Cairo University during the period from April 2015 to June 2020.

Data Acquisition

Multidetector computed tomography of the face was performed to all patients who were scanned from head vertex to chin in thin-sectioned axial images (1.25 mm) using 16-row multi-slice computed tomography (Somtam Emotion 16; Siemens Healthcare, Erlangen, Germany).

Acquisition parameters were as follows: 16 × 0.6 mm collimation, pitch 0.6, table feed 7.7 mm/s, tube current 325 mA, voltage 125 kV, rotation time 1.00s/HE, field of view 220-290 mm, matrix 512 × 512 with total scan time 11 s.

Multiplanar reformatted (MPR) images of the face were acquired from axial images. MDCT and MPR images were analyzed for complex facial fractures and associated orbital injuries. Images were assessed in bone window with window length (WL) 150, window width (WW) 1500 and in soft tissue window WL 40 and WW 400.

All procedures followed were in accordance with the ethical standards of Code of Ethics of the World Medical Association

(Declaration of Helsinki).

Complex facial fractures were furtherly classified as follows: single complex facial fracture, multiple complex facial fractures, and complex facial fractures with and without mandibular fractures.

MDCT and MPR images were evaluated for orbital injuries that were classified into extra-ocular (periorbital and extra-ocular intraconal orbital complications) and ocular injuries. Inferior rectus muscle herniation was classified according to Gilbard et al into free or hooked or entrapped muscles^[17].

Statistics

Odds ratios (OR) and relative risk (RR) were calculated to determine risk of occurrence of fatty herniation and ocular injuries in patients with different patterns of complex facial fractures. Pearson Chi-square or Fisher's exact test was used to assess the association between categorical variables. A P-value ≤ 0.05 was considered significant. Data were expressed as mean ± standard deviation (SD) using the Statistical Package for Social Science version 16 (SPSS Inc., Chicago, IL, USA).

RESULTS

38 male patients with mean age 32 ± 9.5 SD were enrolled in the current study with complex facial fractures and orbital injuries due to motor vehicle accidents.

In this study, periorbital hematoma and subcutaneous emphysema (Figure 1) were noted nearly in all cases with complex facial fractures. Right sided (34.2 %) orbital complications in complex facial fractures were more common than the left side (31.5%) (Table 1).

Soft tissue herniation through fractured orbital floor was evaluated in coronal sections. Four cases with complex facial fractures sustained hooked inferior rectus muscle herniation (Table 1). The rest of the cases were with free inferior rectus muscle.

Traumatic optic neuropathy was noted in one case with multiple

Table 1 Frequency of orbital injuries in complex facial fractures.

Orbital injuries	Bilateral	Right sided	Left sided
Extra-ocular periorbital injuries			
Periorbital hematoma and edema	13	13	12
Subcutaneous emphysema	12	13	11
Extra-ocular and intraconal orbital injuries			
Fatty herniation	4	12	5
Inferior rectus muscle herniation		3	1
Retrobulbar hematoma			1
Enophthalmos		3	3
Traumatic Optic neuropathy			1
Ocular injuries: rupture globe, lens subluxation and vitreous hemorrhage		3	2

Table 2 Distribution of patterns of orbital wall fractures and ocular injuries in complex facial fractures.

Orbital wall	Number (%)	Ocular injuries (n=5)
Orbital floor only	4 (10.5 %)	
Inferomedial wall only	4 (10.5 %)	1
Orbital floor, lateral wall	4 (10.5 %)	
Inferomedial and lateral walls (3 walls)	18 (47.3 %)	3
Four orbital walls including orbital roof	8 (21 %)	1

Table 3 Odds ratios for ocular injuries in complex facial fractures (n=5).

Facial Fractures	Total cases	Ocular injuries Present/total (%)	Odds ratio (95% Confidence Interval)	Relative risk	P-value*
Single complex fractures	8	1/8 (12.5%)	0.92(0.08,9.6)	0.93	0.7
Multiple complex facial fractures	30	4/30 (13.3%)	1.07(0.1,11.2)	1.06	0.7
Complex facial fractures without mandibular fractures	24	4/24 (16.6%)	2.6(0.26,25.9)	2.33	0.38
Complex facial fractures with mandibular fractures	14	1/14 (7%)	0.38(0.03,3.8)	0.42	0.38

*Fisher's exact test is used.

Table 4 Odds ratios for fatty herniation in complex facial fractures (n=21).

Facial Fractures	Extra-ocular fatty herniation Present/total (%)	Odds ratio (95% Confidence Interval)	Relative risk	P-value
Single complex fractures	2/8 (25 %)	0.19(0.03,1.12)	0.39	0.06*
Multiple complex facial fractures	19/30 (63.3 %)	5.18(0.88,30.2)	2.53	0.06*
Complex facial fractures without mandibular fractures	11/24 (45.8 %)	0.33(0.08,1.38)	1.55	0.12**
Complex facial fractures with mandibular fractures	10/14 (71.4 %)	2.95(0.72,12.1)	0.64	0.12**

*Fisher's exact test is used; **Pearson Chi square test is used.

complex facial fractures with combined Le Fort, NOE and ZMC fractures and was due to indirect compression by retrobulbar hematoma (Figure 2).

Ocular injuries were more common in multiple complex facial fractures with combined three orbital wall fractures (Table 2, 3).

The risk of development of fatty herniation in multiple complex facial fractures was higher than that in single complex facial fractures (OR: 5.1, P-value: 0.06).

In the current study, the risk of occurrence of ocular injuries in complex facial fractures without mandibular trauma was twice that in complex facial fractures associated with mandibular trauma (OR: 2.6, P-value:0.38) (Table 3). While the reverse was noted in extra-ocular complications as in fatty herniation where the risk of occurrence of fatty herniation in complex facial fractures associated with mandibular trauma was twice that in complex facial fractures without mandibular trauma (OR:2.95, P-value:0.12) (Table 4).

Extra-ocular intraconal orbital complications (71%) were more common than ocular complications (7%) in patients with complex facial fractures with mandibular trauma. There was no significant association between fatty herniation and ocular injuries and patterns of complex facial fractures (Table 3, 4).

DISCUSSION

Many trauma studies concerned with perusing the epidemiology of complex facial fractures attributed to MVA exhibited high male prevalence due to socioeconomic factors as noted in the current study [18,19,20].

In the present study, although insignificant association between fatty herniation and ocular injuries and patterns of complex facial fractures, however, the risk of development of fatty herniation and ocular injuries were higher in multiple complex facial fractures than that in single complex types. Also, risk of development of ocular injuries in cases with complex facial fractures without mandibular fractures was higher than that in complex facial fractures associated with mandibular trauma. These results were in accordance with a survey conducted by Zhou et al, who concluded that ocular trauma was more likely to occur in patients with multiple midfacial fractures without mandibular trauma followed by patients with combined midfacial and mandibular fractures^[21]. This could be attributed to different direction of vector of the impact forces.

The current study deduced that combined three orbital wall fractures (combined inferomedial and lateral wall fractures) was the commonest orbital fracture pattern to be associated with ocular injuries in complex facial trauma. In discordance with the current results, Noh et al conducted an analysis for ocular injuries in simple and complex orbital fractures and reported that medial and inferomedial orbital wall fractures sustained consecutively the highest incidence for ocular injuries than other orbital fractures^[22].

The commonest orbital complication in this study was periorbital hematoma which was consistent with results obtained by Eslami et al, who conducted an epidemiological study on ocular injuries in maxillofacial fractures^[23].

In discordance with Foroughia et al, post-traumatic orbital complications were more common in unilateral cases (65.78%) compared to bilateral (34.2%) cases^[24]. In the current study, right eye was more common to be injured than the left eye which was in agreement with results reported by Eslami et al, Muralidhar and Chowdary, Das and Gupta, Puri et al, and in disagreement with Mittal et al, and Zhou et al who deduced reversed results^[18,19,21,23,25,26].

In the present study, the incidence of ocular injuries and globe rupture in complex facial fractures was 13% of cases which

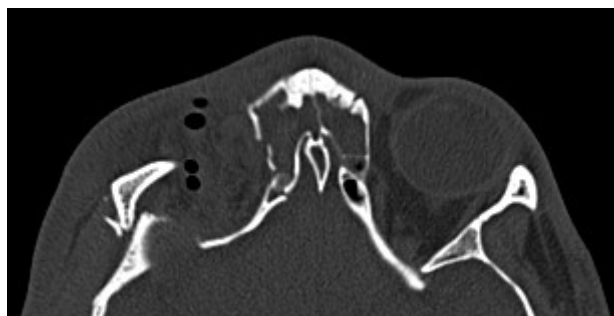


Figure 1 Axial MDCT in a 22-year-old male patient with right Le Fort, ZMC and NOE complex facial fractures. Right extraconal subcutaneous emphysema.

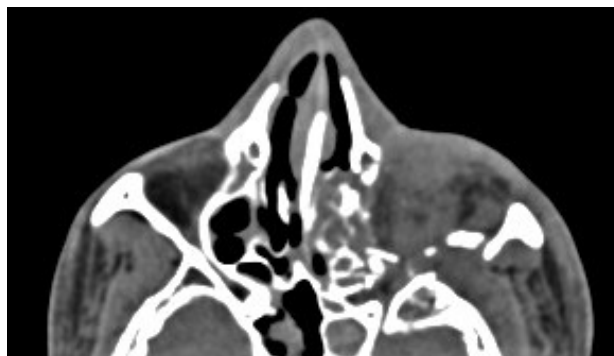


Figure 2 Axial MDCT in a 23-year-old male patient with left Le Fort, ZMC and NOE complex facial fractures. Soft tissue images revealed left preseptal edema and left globe rupture with intraconal superolateral retrobulbar hematoma compressing the left optic nerve.

coincides with results reported by Nagase et al, Al-Qurainy et al, and Osguthorpe, who directed studies for evaluation of ocular injuries in midfacial fractures including complex facial fractures^[27,28,29].

In the current study, all cases with complex facial fractures sustained orbital floor fractures. Orbital floor fractures were associated with the highest incidence of orbital complications^[30,31].

Enophthalmos and orbital emphysema were common association with orbital floor fractures^[1,10,13,32]. Fatty and muscle herniation best evaluated in coronal images were due to herniation of orbital contents through the fractured orbital floor^[1,33].

Retrobulbar hematoma and traumatic optic neuropathy were rare post-traumatic orbital complications in multiple complex facial fractures as noted in the current study^[26,34,35].

Despite retrospective nature of the research. However, this study described different patterns of complex facial fractures and addressed critical complications encountered with post-traumatic orbital injuries.

CONCLUSION

Multidetector computed tomography and MPR images were essential in evaluation of orbital complications in complex facial trauma. Orbital and ocular injuries were more common in multiple complex facial fractures than single types.

REFERENCES

1. Betts AM, O'Brien WT, Davies BW, Youssef OH. A systematic approach to CT evaluation of orbital trauma. *Emergency radiology*. 2014 Oct; **21**(5): 511-31. [PMID: 24756375]; [DOI: 10.1007/s10140-014-1221-5]
2. Doerr TD. Evidence-based facial fracture management. *Facial Plastic Surgery Clinics*. 2015 Aug 1; **23**(3): 335-45. [PMID: 26208771]; [DOI: 10.1016/j.fsc.2015.04.006]

3. Bellamy JL, Munding GS, Reddy SK, Flores JM, Rodriguez ED, Dorafshar AH. Le Fort II fractures are associated with death: a comparison of simple and complex midface fractures. *Journal of Oral and Maxillofacial Surgery*. 2013 Sep 1; **71(9)**: 1556-62. [PMID: 23866783]; [DOI: 10.1016/j.joms.2013.04.007]
4. Dreizin D, Nam AJ, Diaconu SC, Bernstein MP, Bodanapally UK, Munera F. Multidetector CT of midfacial fractures: classification systems, principles of reduction, and common complications. *Radiographics*. 2018 Jan; **38(1)**: 248-74. [PMID: 29320322]; [DOI: 10.1148/rg.2018170074]
5. Carinci F, Zollino I, Arduin L, Brunelli G, Pagliaro F, Cenzi R. Midfacial fractures: A scoring method and validation on 117 patients. *European Journal of Trauma and Emergency Surgery*. 2008 Aug; **34(4)**: 385-90. [PMID: 26815816]; [DOI: 10.1007/s00068-007-7086-5]
6. Kachniarz B, Grant M, Dorafshar AH. Orbital Fractures. In: *Facial Trauma Surgery 2020* Jan 1 (pp. 113-121). Elsevier. [DOI: 10.1016/B978-0-323-49755-8.00017-7]
7. Einy S, Rahman NA, Siman-Tov M, Aizenbud D, Peleg K. Maxillofacial trauma following road accidents and falls. *Journal of Craniofacial Surgery*. 2016 Jun 1; **27(4)**: 857-61. [PMID: 27152572]; [DOI: 10.1097/SCS.0000000000002555]
8. Shelton D. Nasal-orbital-ethmoid fractures. In: Alling CI, Osbon D, editors. *Maxillofacial trauma*. Philadelphia: Lea & Febiger; 1988. p. 363-71.
9. Baril SE, Yoon MK. Naso-orbito-ethmoidal (NOE) fractures: a review. *International ophthalmology clinics*. 2013 Oct 1; **53(4)**: 149-55. [PMID: 24088941]; [DOI: 10.1097/HIO.0b013e31829cf077]
10. Mehta N, Butala P, Bernstein MP. The imaging of maxillofacial trauma and its pertinence to surgical intervention. *Radiologic Clinics*. 2012 Jan 1; **50(1)**: 43-57. [PMID: 22099486]; [DOI: 10.1016/j.rcl.2011.08.005]
11. Holt JE, Holt GR, Blodgett JM. Ocular injuries sustained during blunt facial trauma. *Ophthalmology*. 1983 Jan 1; **90(1)**: 14-8. [PMID: 6828306]; [DOI: 10.1016/s0161-6420(83)34597-8]
12. Poon A, McCluskey PJ, Hill DA. Eye injuries in patients with major trauma. *Journal of Trauma and Acute Care Surgery*. 1999 Mar 1; **46(3)**: 494-9. [PMID: 10088858]; [DOI: 10.1097/00005373-199903000-00027]
13. Patil SG, Kotwal IA, Joshi U, Allurkar S, Thakur N, Aftab A. Ophthalmological evaluation by a maxillofacial surgeon and an ophthalmologist in assessing the damage to the orbital contents in midfacial fractures: a prospective study. *Journal of maxillofacial and oral surgery*. 2016 Sep; **15(3)**: 328-35. [PMID: 27752202]; [DOI: 10.1007/s12663-015-0844-8]
14. Dobrovăț B, Popescu R, Nemtoi A, Ladunca O, Haba D. Orbital trauma: from anatomy to imaging patterns: A pictorial review. *Romanian Neurosurgery*. 2011 Dec 15: 525-32.
15. Agarwal A, Kumar N, Sharma N. 2D and 3D CT scan-A diagnostic adjunct or necessity in maxillofacial trauma. *Indian Journal of Dentistry*. 2012 Oct 1; **3(4)**: 185-9. [DOI: 10.1016/j.ijd.2012.03.016]
16. Caranci F, Cicala D, Cappabianca S, Briganti F, Brunese L, Fonio P. Orbital fractures: role of imaging. In: *Seminars in Ultrasound, CT and MRI 2012* Oct 1 (Vol. 33, No. 5, pp. 385-391). WB Saunders. [PMID: 22964404]; [DOI: 10.1053/j.sult.2012.06.007]
17. Gilbard SM. Management of orbital blowout fractures: the prognostic significance of computed tomography. *Advances in ophthalmic plastic and reconstructive surgery*. 1987 Jan 1; **6**: 269-80. [PMID: 3455209]
18. Muralidhar P, Chowdary NL. Ocular manifestations in road traffic accidents: a study done at a medical college hospital in South India. *Interna J Contem Med Res*. 2016; **3(8)**: 2337-3239.
19. Das D, Gupta S. Epidemiology and pattern of motorcycle accident related ocular injuries in a rural tertiary care hospital in Eastern India. *Indian Journal of Clinical and Experimental Ophthalmology*. 2016 Oct; **2(4)**: 341-4. [DOI: 10.18231/2395-1451.2016.0014]
20. Ababneh LT, Mohidat H, Abdelnabi H, Kana'an MF, Tashtush NA, El-Mulki OS, Aleshawi AJ. Hospital-Based Ocular Trauma: Factors, Treatment, And Impact Outcome. *Clinical Ophthalmology (Auckland, NZ)*. 2019; **13**: 2119. [PMID: 31802841]; [DOI: 10.2147/OPHT.S223379]
21. Zhou HH, Liu Q, Yang RT, Li Z, Li ZB. Ocular trauma in patients with maxillofacial fractures. *Journal of Craniofacial Surgery*. 2014 Mar 1; **25(2)**: 519-23. [PMID: 24561369]; [DOI: 10.1097/SCS.0000000000000683]
22. Noh H, Chung JK, Woo KI, Kim YD. Occurrence of ocular injury and orbital fracture in orbital blunt trauma patients at tertiary care center emergency room. *Graefe's archive for clinical and experimental ophthalmology*. 2021 Jan; **259(1)**: 165-71. [PMID: 32514771]; [DOI: 10.1007/s00417-020-04786-6]
23. Eslami F, Zandi M, Seif Rabiei MA, Bigonah N, Sharifi S. Epidemiologic study of ocular injuries in patients with maxillofacial fracture in Hamadan. *Avicenna J Dent Res*. 2018; **10(1)**: 16-21. [DOI: 10.34172/ajdr.2018.04]
24. Foroughi R, Faghani F, Gharib S, Khafri S. Traumatic ophthalmic injuries ophthalmic injuries in mid-facial trauma: A decade long survey. *Journal of Craniomaxillofacial Research*. 2015: 128-32.
25. Puri S, Ralra N, Kumar P, Kapoor G, Kandhari S. Profile of ocular trauma in a tertiary care centre. *IOSP J. Dent. Med. Sci*. 2016; **15**: 122-8. [DOI: 10.9790/0853-150508122128]
26. Mittal G, Singh N, Suvarana S, Mittal SR. A prospective study on ophthalmic injuries related to maxillofacial trauma in Indian population. *National journal of maxillofacial surgery*. 2012 Jul; **3(2)**: 152. [PMID: 23833490]; [DOI: 10.4103/0975-5950.111370]
27. Nagase DY, Courtemanche DJ, Peters DA. Facial fractures-association with ocular injuries: a 13-year review of one practice in a tertiary care centre. *Canadian Journal of Plastic Surgery*. 2006 Aug; **14(3)**: 167-71. [PMID: 19554110]; [DOI: 10.1177/229255030601400303]
28. Al-Ourainy IA, Dutton GN, Stassen LF, Moos KF, El-Attar A. The characteristics of midfacial fractures and the association with ocular injury: a prospective study. *British journal of oral and maxillofacial surgery*. 1991 Oct 1; **29(5)**: 291-301. [PMID: 1742258]; [DOI: 10.1016/0266-4356(91)90114-k]
29. Osguthorpe JD. Orbital wall fractures: evaluation and management. *Otolaryngology-Head and Neck Surgery*. 1991 Nov; **105(5)**: 702-7. [PMID: 1754254]; [DOI: 10.1177/019459989110500511]
30. Tupits A, Neimane L. Use of Computed Tomography in Orbital Trauma Diagnostic: Literature Review. *medicine & pharmacy*. 2017.
31. Janakarajah N, Sukumaran K. Orbital floor fractures and their treatment. *Australian and New Zealand journal of ophthalmology*. 1985 Feb; **13(1)**: 75-80. [PMID: 3893471]; [DOI: 10.1111/j.1442-9071.1985.tb00404.x]
32. Jha KN, Rajalakshmi AR. Evaluation and management of orbital trauma. *Journal of Clinical Ophthalmology and Research*. 2018 May 1; **6(2)**: 77. [DOI: 10.4103/jcor.jcor_115_17]
33. Fraioli RE, Branstetter IV BF, Deleyiannis FW. Facial fractures: beyond le fort. *Otolaryngologic Clinics of North America*. 2008 Feb 1; **41(1)**: 51-76. [PMID: 18261526]; [DOI: 10.1016/j.otc.2007.10.003]
34. Rajkumar GC, Ashwin DP, Singh R, Prashanth R, Rudresh KB. Ocular injuries associated with midface fractures: A 5 year survey. *Journal of maxillofacial and oral surgery*. 2015 Dec; **14(4)**: 925-9. [PMID: 26604465]; [DOI: 10.1007/s12663-015-0778-1]
35. Jindwani K, Singh K, Paharia YK. Epidemiological Study of Ocular Injuries with Midface Fractures in a Government Medical College of Central India. *Journal of Advanced Medical and Dental Sciences Research*. 2019 Apr 1; **7(4)**: 88-93. [DOI: 10.21276/jamdsr]