

Fetal Dose From Emergency CT Examination: Fetal Simulation and Dose Measurements

Christine Lo, Martin Law, Francis Cho, Dominic Pang, Patricia Cheng, Lawrance Yip, Wendy Lam

Christine Lo, Martin Law, Francis Cho, Dominic Pang, Patricia Cheng, Lawrance Yip, Wendy Lam, Department of Radiology, Queen Mary Hospital, Hong Kong, 102 Pokfulam Road, Hong Kong
Correspondence to: Martin Law, Department of Radiology, Queen Mary Hospital, Hong Kong, 102 Pokfulam Road, Hong Kong
Email: lawwm@ha.org.hk
Telephone: +852-2255 4215 Fax: +852- 2255-3872
Received: November 3, 2014 Revised: December 16, 2014
Accepted: December 19, 2014
Published online: December 31, 2014

© 2014 ACT. All rights reserved.

Key words: Emergency CT for pregnant patients; Fetal simulation and dose measurements; Childhood cancer induction

Lo C, Law M, Cho F, Pang D, Cheng P, Yip L, Lam W. Fetal Dose From Emergency CT Examination: Fetal Simulation and Dose Measurements. *International Journal of Radiology* 2014; 1(1): 4-6
Available from: URL: <http://www.ghrnet.org/index.php/ijr/article/view/909>

ABSTRACT

AIM: To experimentally simulate a late stage fetus, to measure fetal irradiation dose and to estimate associated childhood cancer risk resulting from an emergency thorax-abdominopelvic CT imaging for a pregnant patient with suspected aortic dissection.

METHODS: To simulate the fetal body, a physics CTDI cylindrical phantom was placed onto the abdomen of a standard female humanoid phantom. Layers of beeswax were used to make the phantom maternal dimension similar to that of the pregnant patient. A 10 cm pencil chamber was used to measure the dose at each quadrant location and at the center of the CTDI phantom and the fetal dose was obtained by averaging these measured doses. Stochastic effect of childhood cancer risk induction (0.4% per 10 mGy irradiation) was estimated to provide a reference value to monitor the growth of the newborn child.

RESULTS: The fetal dose was measured as 20 mGy for a single acquisition according to the patient scanning protocol. Since the patient had both pre- and post-contrast CT acquisition, the total fetal dose was therefore 40 mGy. The lifetime risk of developing childhood cancer was estimated as 1.6%.

CONCLUSION: By using readily available equipment in a radiology department, fetal simulation and then dose measurements can be efficiently performed with the moulding technique. Results obtained are useful as reference value to monitor the growth of the newborn.

INTRODUCTION

Pregnant patients may experience non-obstetrical emergencies over the course of pregnancy, and CT remains essential in the emergent setting for pregnant population^[1]. For pregnant women undergoing abdominopelvic CT, the concern of consequent cancer risk is particularly relevant because the fetus, with a greater sensitivity to radiation than the mother, is also directly exposed to radiation^[1-3].

Most published estimates of fetal dose from radiological examinations have relied on Monte Carlo computation^[3] or on measurements with thermoluminescent dosimeters for specific clinical application^[4] that requires special facility and expertise^[5]. We report a simple fetal simulation technique to perform fetal dose measurements for a clinical case of a 38 year old previously healthy pregnant woman who was referred to our institution at 36 weeks gestation for acute chest pain. Investigations were immediately performed to ascertain the cause of the patient's pain. Troponin I was increased to 1.12. ECG showed T-wave inversion in leads III and avF. Urgent bedside echocardiogram showed suspected aortic dissection. CT imaging was requested to confirm the echocardiogram findings and to delineate the extent of dissection. Referring clinicians would then decide their therapeutic decision, whether to treat with medical or surgical means, based on the level of dissection from the CT findings. General knowledge of risks and benefits due to the radiation dose delivered to the fetus was informed to the patient. Fetal dose from a single acquisition abdominopelvic CT study has been reported

to have an average of 25 mGy^[1]. An urgent CT scan of thorax-abdominopelvis was then performed and a Type A aortic dissection extending from the dilated aortic root down to the bifurcation was verified. The patient underwent emergency Caesarean section, Bentall operation and ascending aortic interposition graft repair. The child was delivered successfully with normal Apgar scores and the mother was recovered uneventfully. The child has been growing well with normal parameters. Retrospective fetal irradiation dose was measured with the use of phantom and estimated associated risks were estimated as information to the mother and as reference to monitor the growth of the newborn child.

METHOD

A standard reference female humanoid of weight 70 kg (The Phantom Laboratory, New York, USA) was used as the mother in this retrospective measurement study. To simulate a fetus of gestational age of 36 weeks, we used a cylindrical phantom (a CTDI head phantom commonly used for CT quality control work) of weight about 3 kg to mimic the fetal body. The CTDI cylinder was then embedded onto the humanoid abdominal region to closely match with the patient's maternal parameters. Layers of tissue-equivalent beeswax (available from most radiation oncology department moulding laboratory) were moulded around the humanoid abdominal region to simulate the maternal dimensions (Figure 1). The finished dimensions were: maternal curvature 42 cm, maternal anteroposterior thickness 34 cm, total maternal weight 79 kg, all of which were comparable to reported late stage gestation dimensions^[6].

The simulated fetal body had a series of holes of length 10 cm with each hole located at each quadrant position and at the center of the CTDI phantom. A calibrated 10 cm pencil chamber was then inserted into each hole for dose measurement using the patient irradiation CT protocol. By averaging the doses measured at these five positions, the average irradiated dose to the simulated fetal body was obtained.

Figure 2 shows the patient CT scout image (Toshiba Aquilion 320 rows CT, Otawara, Japan). CT parameters were 120 kVp, automatic mA with manually adjusted tube current within the fetal region^[7]. The same CT beam parameters were used to irradiate the simulated pregnant humanoid. For exposure to a newborn, the lifetime attributable risk of childhood cancer induction was estimated with 0.4% per 10 mGy irradiation to the fetus^[8].

RESULTS

The pregnant patient had undergone 2 identical thorax-abdominopelvis CT sets, namely pre-contrast CT scan for intramural hematoma and post-contrast CT for dissection. Figure 3 shows the image of the post-contrast CT examination, demonstrating the extensive dissection flap from dilated aortic root down to the bifurcation and the direct CT exposure to the fetus. The average dose delivered to the fetus was measured as 20 mGy for a single thorax-abdominopelvic CT acquisition. Therefore, the total irradiation CT dose to the fetus was 40 mGy because pre- and post-contrast scans were used.

The lifetime attributable risk of childhood cancer induction was estimated as 1.6% due to the CT irradiation.

DISCUSSION

Osei and Darko recently presented a multi-national study in that average fetal absorbed doses for pelvis and abdomen under

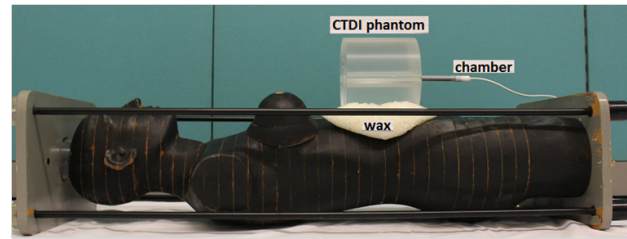


Figure 1 Diagram showing equipment used to simulate the fetus and to measure the fetal dose. The CTDI phantom was used to simulate the fetus with the 10 cm pencil chamber inserted into the CTDI phantom to measure the irradiation dose. Layers of beeswax were then pasted onto the humanoid abdominal region to simulate the maternal curvature.

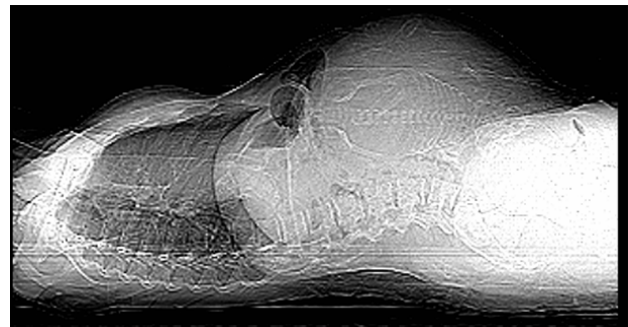


Figure 2 Scout image of the pregnant patient indicating the CT scanning range. The same CT scanning parameters and scanning range were used for humanoid irradiation.

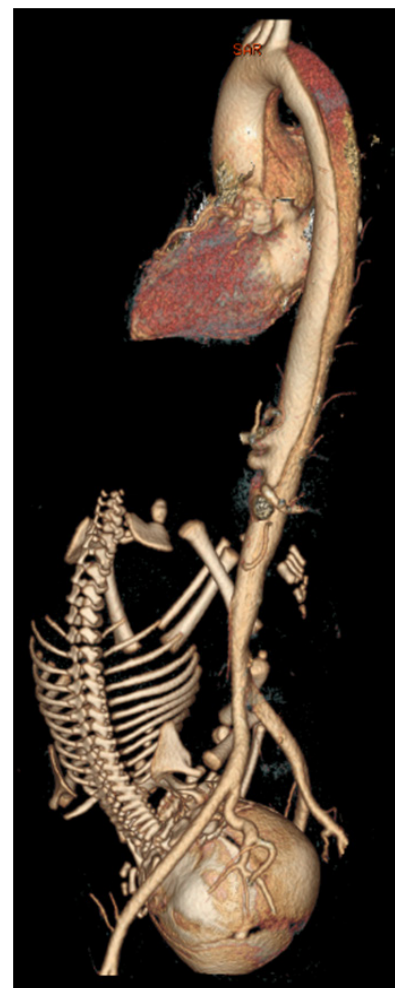


Figure 3 CT image of the pregnant patient shows that dissection flap was observed from the dilated aortic root down to the bifurcation. The proximal part was close to the aortic valve. The fetus was directly exposed.

CT irradiation were 10.6 mGy (range: 1.3-17 mGy) and 2 mGy (range: 1.0-3.7 mGy) respectively without details in gestational age^[9]. Goldberg-Stein *et al* retrospectively analyzed data from a 7-years database and identified 86 pregnant patients from 180,000 abdominopelvic examinations^[2]. Based on each identified pregnant patient CT parameters, the authors used Monte Carlo technique applied to a mathematical phantom which was not specifically designed for pregnant woman in order to calculate the fetal absorbed dose. Nevertheless, it was reported an average fetal dose of 24.8 mGy (range: 6.7-56 mGy) for those identified pregnant patients who had undergone a single acquisition abdominopelvis CT examination. Lazarus *et al* also reported a mean fetal dose of 17 mGy (range: 8-44 mGy) from a review of 10 years database^[10]. Our result of 20 mGy per thorax-abdominopelvis CT acquisition was in good accord with multi-national survey and with large database reviews for abdominopelvic CT scan. It should be noted that our dose measurement referred to thorax-abdominopelvic region that would result in a slight increase in fetal absorbed dose when compared with that from an abdominopelvic scan due to increase in internal scatter dose from the thorax region irradiation.

The fetal irradiated dose of 40 mGy, as resulted from the emergency CT to diagnose the patient's aortic dissection, was measured to be well below the safety limit of 100 mGy. Lethal effects will be very infrequent for doses under 100 mGy and birth malformation fetal exposure well below 100 mGy is not expected^[11]. Therefore, we would not expect any birth defects to the newborn. Stochastic effect of childhood cancer risk induction (0.4% per 10 mGy irradiation) was the main concern^[8]. Exposure of 40 mGy increases the lifetime risk of developing cancer to the newborn child by 1.6%. In other words, there is a better than 98% likelihood that the child will be unaffected by the irradiation. The cancer risk is low of the order <2% for emergency CT scan through thorax-abdominopelvis region, indicating that such high dose examination may be performed on pregnant patients who have medically necessary indication. The radiologist performing the emergency CT must be aware of any prior radiological examinations in the abdominopelvis region to the pregnant patient in order to have an updated risk and benefit consideration.

CONCLUSION

By using readily available equipment in a radiology department, fetal simulation and then dose measurements can be efficiently performed with moulding technique. Such simulation and measurement are efficient in simulating various clinical applications. In the future, fetal dose can be prepared as a look-up table according to gestational age and for common maternal dimensions as a preparedness to cope with the increasing trend of emergency presentations in the pregnant patient population^[10]. One also has to consider if the mother has had any high dose radiological examinations prior to the emergency CT to provide an update in risk and benefit analysis as information to the pregnant patient.

ACKNOWLEDGMENTS

The authors would like to thank the Department of Clinical Oncology of Queen Mary Hospital, Hong Kong, for the use of the humanoid phantom and laboratory facilities.

CONFLICT OF INTERESTS

All the authors of the manuscript entitled 'Fetal dose from emergency CT examination: fetal simulation and dose measurements' declare that there is no conflict of interest with regard to equipment, contrast, drug and other materials described in the study.

REFERENCES

- 1 Sadro CT, Dubinsky TJ. CT in pregnancy: risks and benefits. *Appl Radiol* 2013; **October**: 6-16
- 2 Goldberg-Stein S, Liu B, Hahn PF, Lee SI. Body CT during pregnancy: Utilization trends, examination indications, and fetal radiation doses. *AJR Am J Roentgenol* 2011; **196**: 146-151
- 3 Goldberg-Stein SA, Liu B, Hahn PF, Lee SI. Radiation dose management: Part 2, estimating fetal radiation risk from CT during pregnancy. *AJR Am J Roentgenol* 2012; **198**: W352-W356
- 4 Doshi SK, Negus IS, Oduko JM. Fetal radiation dose from CT pulmonary angiography in late pregnancy: a phantom study. *Br J Radiol* 2008; **81**: 653-658
- 5 Feng ST, Law WWM, Huang B, et al. Radiation dose and cancer risk from pediatric CT examinations on 64-slice CT: a phantom study. *Eur J Radiol* 2010; **76**: 19-23
- 6 Osei EK, Faulkner K. Fetal position and size data for dose estimation. *Br J Radiol* 1999;**72**:363-370
- 7 Westerman BR. Radiation dose from Toshiba CT scanners. *Pediatr Radiol* 2002; **32**: 735-737
- 8 ACR-SPR Practice Guideline for Imaging Pregnant or Potentially Pregnant Adolescents and Women with Ionizing Radiation (revised 2013, resolution 48). <http://www.acr.org/~media/9E2ED55531FC4B4FA53EF3B6D3B25DF8.pdf> (accessed on 03-Nov-2014 15:00 hr)
- 9 Osei EK, Darko J. Foetal radiation dose and risk from diagnostic radiology procedures: a multinational study. ISRN Radiol 2013, Article ID 318425. <http://dx.doi.org/10.5402/2013/318425> (accessed on 3-Nov-2014 15:15 hr)
- 10 Lazarus E, DeBenedictis C, North D, Spencer PK, Mayo-Smith WW. Utilization of imaging in pregnant patients: 10-year Review of 5270 Examinations in 3285 Patients 1997-2006. *Radiology* 2009; **251**: 517-524
- 11 ICRP. The 2007 recommendations of the International Commission on Radiological Protection. *Ann ICRP* 2007; **2-4**: 1-332 [ICRP publication 103]

Peer reviewers: Bing Wang, MD, PhD, Team Leader, Senior Researcher, National Institute of Radiological Sciences, Anagawa 4-9-1, Inage-ku, Chiba 263-8555, Japan; Xin Liu, PhD, School of Medical Instrument & Food Engineering, University of Shanghai for Science and Technology, 516 Jun Gong Road, Shanghai, 200093, China.