

Activation of Matrix Metalloproteinase 2(MMP-2) in Breast Cancer Progression

Hrishikesh Sil, Shuvojit Moulik, Indrani Singha, Shyam S Mandal, Jaydip Biswas, Amitava Chatterjee

Hrishikesh Sil, Shuvojit Moulik, Indrani Singha, Amitava Chatterjee, Department of Receptor Biology & Tumor Metastasis, Chittaranjan National Cancer Institute, 37, S.P. Mukherjee road, Kolkata, 700026, India

Shyam S Mandal, Medical Records Unit, Chittaranjan National Cancer Institute, 37, S.P. Mukherjee Road, Kolkata, 700026, India

Jaydip Biswas, Head, Department of Surgery, Director, Chittaranjan National Cancer Institute, 37, S.P. Mukherjee Road, Kolkata, 700026, India

Correspondence to: Amitava Chatterjee, Ph.D, Emeritus Scientist, Ramakrishna Mission Vivekananda University, (IRDM), Kolkata, 700103, West Bengal, India

Email: amitavachatterjee24@gmail.com

Telephone: +91-33-9830128320

Received: October 13, 2014 Revised: January 24, 2015

Accepted: January 28, 2015

Published online: February 18, 2015

© 2015 ACT. All rights reserved.

Key words: Breast cancer; MMP-2; MT1-MMP; TIMP-2; EMPRIN; ER; PR; Her-2

Sil H, Moulik S, Singha I, Mandal SS, Biswas J, Chatterjee A. Activation of Matrix Metalloproteinase 2(MMP-2) in Breast Cancer Progression. *Journal of Tumor* 2015; 3(1): 292-304 Available from: URL: <http://www.ghrnet.org/index.php/JT/article/view/1036>

INTRODUCTION

Breast cancer, a clinically and pathologically heterogeneous disease is the most frequent malignancy and the leading cause of cancer related death worldwide. The aggressiveness of a tumor is primarily dependent on its ability to invade adjacent tissue. Proteolytic degradation of the basement membrane and extra cellular matrix is the central aspect of physiologic and pathologic tissue remodeling process such as neovascularization, wound healing and malignant growth involving proteolytic enzymes^[1]. Matrix metalloproteinase-2 (MMP-2/gelatinase A/72-kDa type IV collagenase) is a member of zinc-dependent endopeptidase that degrade matrix proteins, among other type IV collagens in basement membranes^[2,3,4]. The expression of MMP-2 is strongly associated with the progression of malignancy of several types of carcinoma^[5,6,7,8,9]. Primary melanoma^[10] lung carcinoma^[11], ovarian carcinoma^[12] and brain neoplasms^[13], the expression of the immunoreactive protein for MMP-2 was associated with a poor prognosis. In several studies, MMP-2 was expressed in breast carcinoma^[14,15,16] and detected most commonly in breast carcinoma cells.

Presence of active MMP-2 species in the culture media of the carcinoma tissues^[17,18] indicate the presence of proMMP-2 activator(s). In fact, MT1-MMP mRNA expression was reported in breast carcinoma^[19,20]. Immunohistochemical studies of breast tumors have indicated possible prognostic value of MMP-2 suggesting that this protease may be useful as marker for early breast cancer (BC) detection, disease classification/prognostication for treatment monitoring. Aberrant expression of *HER2* oncogene are related to disease progression and increased invasive capacity in breast

ABSTRACT

AIMS: The present study aimed to detect expression and activation of MMP-2 as well as the involvement of MMP2 in cancer progression in 81 malignant breast tumor and adjacent normal tissues of different stages of the disease.

METHODS: Methods used were gelatin zymography, western blot, RT-PCR, Immuno histochemistry and ELISA.

RESULTS: Pro-MMP-2 was highly expressed in node positive tumors and adjacent normal breast tissue. The mature forms of MMP-2 (68kD and 64kD) were observed mostly in T2–T4 stages. We also observed down regulation of TIMP-2 and translocation of NFκB in stage-III cases, which suggest their possible role as key regulators of MMP-2 activation in Her-2 positive breast cancer. However MMP-2 activation was not correlated with ER and PR expression.

CONCLUSIONS: Appreciable induction of MT-1-MMP and EMPRIN and translocation of NFκB in tumors compared to adjacent normal breast tissue suggested their possible involvement in activation of pro-MMP-2 in late stage of cancer (TNM stage-III) tumors. Evaluation of MMP-2 expression and activity may add valuable information in detection and treatment of the disease.

cancer^[21-24] at least in part, to the up-regulation of MMP-2 and MMP-9 expression and proteolytic activity^[24-30].

The aim of our present study was to investigate the expression and activity of MMP-2 in malignant and adjacent normal breast tissues from breast cancer patients of different clinical stages and also to correlate our data with clinical parameters.

MATERIALS AND METHODS

Patients

The present study involving 81 breast cancer patients among the women, who were referred to Chittaranjan National Cancer Institute, Kolkata, India because of clinical breast lump, suspicious mammographic finding or breast symptoms between 2008 and 2010 (Table 1 shows clinicopathological data of patients in brief). Stage was assessed by using the TNM classification. The mean age of the patients was 59.2 years (median 56.8 years; range, 23.3-91.6 years). The mean follow up time was 55.0 months (median 57.5 months; range, 1.2-115.1 months).

Collection of tissue samples

Tissues from tumor and respective normal breast tissues of the same patient were collected from the operation theater during surgery. Tissues were stored at -80°C and used for the further experiments.

Materials

Minimum Essential Medium (MEM), fetal bovine serum (FBS). Protease Inhibitor Cocktail Tablets (complete, mini, EDTA-free) were purchased from Roche, Germany. Gelatin Sepharose 4B beads was purchased from GE Healthcare Bio-Sciences AB, Uppsala, Sweden.

Table 1 Clinicopathological data of patients.

Characteristics	n (%)
No of patients	81(100)
Age (y)	
Mean (range)	57.3(23.1-77.6)
Tumor Size	
T1	5 (6.17)
T2	21 (25.92)
T3	28 (34.5)
T4	27 (33.3)
Lymph Node Status	
Negative	7 (8.6)
Positive	74 (91.3)
Stage	
II	25 (30.8)
III	56 (69.13)
Unknown	1 (1.23)
Histological Type	
Ductal	74 (91.3)
Lobular	7 (8.64)
Histological Grade	
I	5 (6.17)
II	24 (29.6)
III	52 (64.19)
Estrogen Receptor Status	
Positive	41 (50.61)
Negative	40 (49.38)
Progesteron Receptor Status	
Positive	41 (50.61)
Negative	40 (49.38)
Her-2 Status	
Positive	35 (43.2)
Negative	46 (56.79)
Menopausal Status	
Pre menopausal	54 (66.6)
Post Menopausal	27 (33.3)

All primary antibodies (Anti-MMP-2, anti-TIMP-2, anti-MT1-MMP, anti-EMPRIN, anti-NFκB and, anti-β-tubulin) antibodies were purchased from Santa Cruz, USA. Biotinylated secondary antibodies, SuperSignal West Femto Maximum Sensitivity Substrate were purchased from Thermo Scientific, Rockford, USA. Avidin-biotinylated peroxidase complex reagent (vectastain Rabbit ABC kit) was purchased from vector laboratories, Burlingame, CA). DAB substrate and stable peroxidase substrate buffer were purchased from Pierce Biotechnology, USA. Primers were synthesized by Operon, Germany. Trizol Reagent was purchased from invitrogen, Retroscript (RT-PCR Kit) was purchased from Ambion, USA. Protease Inhibitor Cocktail Tablets (complete, mini, EDTA-free) were purchased from Roche, Germany. DAB substrate and stable peroxidase substrate buffer were purchased from Pierce Biotechnology, USA. Primers were synthesized by Operon, Germany. USA. Immobilon-P Membrane, (PVDF), was purchased from Millipore, USA.

Methods

Cell culture: HT-1080 (human fibrosarcoma cell line) was obtained from National Centre for Cell Sciences (NCCS), Pune, India. and were grown and maintained in MEM containing 10% FBS in a 5 % CO₂ incubator at 37°C and culture supernatant was used as markers for MMP-9 in zymographic analysis.

Gelatin Zymography

Tissues were collected, homogenized, extracted with tissue extraction buffer (Tris: 50 mM, NaCl: 150mM, NP40: 1%, protease inhibitor cocktail and pH adjusted to 7.5). Equal amount of protein (100 µg each) was taken. The gelatinases were separated from tissue extract using Gelatin Sepharose 4B beads shaking for 2 hours at 4°C. The beads were washed ×3 with Tris-buffered saline with (0.02%) Tween-20 (TBST) and suspended in 50 µl of 1× sample buffer (0.075 gm Tris, 0.2 gm SDS in 10 ml water, pH 6.8) for 30 mins at 37°C. The extract was then subjected to zymography on 7.5% SDS-PAGE (sodium dodecyl sulfate polyacrylamide gel electrophoresis) co-polymerized with 0.1% gelatin. Gel was washed in 2.5% Triton-X-100 for 30 mins to remove SDS and was then incubated overnight in reaction buffer (50 mM Tris-HCl pH 7, 4.5 mM CaCl₂, 0.2 M NaCl). After incubation, the gel was stained with 0.5% Coomassie Blue in 30% methanol and 10% glacial acetic acid. The bands were visualized by destaining the gel with 30% methanol and 10% glacial acetic acid.

Semi- quantitative RT-PCR: Both normal and respective tumor tissues were collected, homogenized in 1ml of Trizol reagent per 50µg of tissue using a power homogenizer. Homogenized samples were incubated for 5 minutes at room temperature (RT). Then 0.2 ml of chloroform was added to each sample, vigorously shaken for 15 seconds and incubated at RT for 2-3 minutes. Centrifuged at 12,000×g for 15 minutes at 4°C. Aqueous phase was isolated and mixed with 0.5 mL of isopropyl alcohol, incubated for 10 minutes at RT, centrifuged at 12,000×g for 10 minutes at 4°C. Supernatant removed and RNA pellet was washed with 75% ethanol and air dried and dissolved in RNase free water. 2 steps RT-PCR (Retroscript, Ambion, USA) was done with equal amounts of total RNA, using specific primers for PCR (MMP-9 and TIMP-1). 20 µl of each PCR products were run on a 2.5 % agarose gel and bands visualized under UV. Glyceraldehyde phosphate dehydrogenase (GAPDH) primers were used as control to normalize for mRNA integrity and equal loading. The primer sequences and PCR cycles/conditions for each primer are tabulated below.

Primer sequences, PCR cycles and conditions: HMMP-

Immunohistochemistry: The sections were de-parafinized in xylene, re-hydrated in EtOH, and washed twice with distilled water. For better antigen retrieval, the samples were boiled three times for 5 minutes in a microwave in citrate buffer (10 mM, pH-6). Endogenous per-oxidases were blocked by 5% hydrogen peroxidase treatment for 5 minutes. The samples were washed with PBS (pH-7.2) and incubated in 2% normal bovine serum for 35 minutes to prevent nonspecific antigen binding followed by incubation with The primary antibody for MMP-2 (2C1), at a working dilution of 1:500 for overnight at 4°C. Before applying the secondary antibody, the samples were washed twice with PBS. The slides were then incubated with the biotinylated secondary antibody followed by a wash and a 50 minutes incubation in an avidin-biotinylated peroxidase complex reagent. Expressions were visualized with a 5-minute diaminobenzidin tetrahydrochloride treatment. The slides were counterstained with Mayer’s hematoxylin, dehydrated and mounted with DePex. A routinely processed breast cancer section without the primary antibody served as negative control at each staining series. Control sections stained as expected.

Statistical Analyses: The statistical analyses were carried out by using the Epi Info(TM) software of the centers for disease Control and Prevention (CDC, USA) for windows 9.0 programme. Test of proportion and corresponding Z values as well as p values had been calculated. The associations between MMP-2 expression and clinicopathological parameters were tested. The univariate analyses were performed using Kaplan-Meier’s log rank analysis, and the independent prognostic value of variables were further examined with Cox’s regression analysis. Probability values of ≤ 0.05 were considered significant in the analyses (Table 3). Multivariate analysis was carried out to correlate the markers with clinicopathological parameters including age, menopausal status, lymph node involvement, status of ER, PR, Her-2/neu and stage of the disease (Table 4). Odds ratio (OR) was calculated to assess the associations. Values of the parameters were expressed as Mean \pm S.E., p values less than 0.05 were considered statistically significant.

RESULTS

MMP-2 gelatinolytic activity was up regulated in tumors of TNM stage II and III compared to adjacent normal breast tissue

Most of the node positive tumors (95%), a few node negative tumors (40%) of both clinical stage-II and III showed increased pro-MMP-2 activity (Figure 1a and 1b). Significant correlation was found in high-MMP-2 activity and nodal involvement (relative risk: 19.33, $p=0.03$). Adjacent normal breast tissues were with less MMP-2 activity. The active mature form of MMP-2 (68 kD and 64KD) was appeared only in invasive cancer tissues.

Advanced stage of breast cancer is associated with upregulation of MMP-2 mRNA and protein expression

MMP-2 m-RNA expression was increased in stage-III tumors as compared to adjacent normal tissues. However tumors of DCIS (ductal carcinoma in-situ) and T2 stage did not show any appreciable difference in MMP-2 m-RNA expression (Figure 2). pro-MMP-2 production was increased in few tumors of both DCIS and T2 stage. Appreciable increased expression of pro-MMP-2 was found In T4 stage (stage III), where tumor invaded the skin (Figure 3). Over expression of MMP-2 in tumors was confirmed

Table 4 Result for multivariate logistic regression.

Category (variable)	MMP-2	
	Relative risk	CL (95%) *P
Stage-II		
Nodal involvement	19.33 (1.79, 468.5)	0.03
ER status	0.46 (0.05,4.63)	0.89
PR status	0.96 (0.92,425.06)	0.40
Her-2 status	0.86 (0.07, 55.5)	0.66
Stage-III		
Nodal involvement	11.24 (1.53, 73.3)	0.04
ER status	6.72 (1.86, 52.03)	0.77
PR status	0.98 (0.94, 10.25)	0.40
Her-2 status	1.97(1.15, 8.19)	0.039

Table 3 Gelatinase expression and statistically significant clinicopathological variables of breast cancer patients in univariate analysis.

Variable	MMP-2		(*P)	O.R
	Normal (%)	Tumor (%)		
Stage-II				
Lymph Node Status				
Node positive	4 (20%)	19 (95%)	P=0.0046	2.59 (1.03, 20.40)
Node negative	3 (60%)	2 (40%)		
Estrogen Receptor Status				
ER positive	2 (16.6%)	6 (50%)	P=0.55	4.67 (1.25, 6.64)
ER negative	1(6.6%)	14 (93.3%)		
Progesteron Receptor Status				
PR positive	2 (13.3%)	14 (93.3%)	P=0.24	0.88 (0.13, 5.79)
PR negative	4 (40%)	3 (93.3%)		
Her-2 Status				
Her-2 positive	1 (20%)	15 (93.3%)	P=0.91	0.64 (0.6, 7.49)
Her-2negative	4 (40%)	3 (30%)		
Stage-III				
Lymph Node Status				
Node positive	2 (3.7%)	54 (100%)	P=0.04	2.07 (1.23, 8.11)
Node negative	1 (50%)	1 (50%)		
Estrogen Receptor Status				
ER positive	1 (3.4%)	12 (41.3%)	P=0.51	0.83 (7.17, 1.89)
ER negative	1 (3.7%)	27 (100%)		
Progesteron Receptor Status				
PR positive	2 (7.6%)	12 (46.1%)	P=0.47	0.20 (0.11, 13.13)
PR negative	2 (6.6%)	21(70%)		
Her-2 Status				
Her-2 positive	1(5.8%)	17 (100%)	P=0.058	1.12 (1.02, 17.57)
Her-2 negative	2 (5.12%)	38 (97.4%)		

by Immunohistochemical staining, MMP-2 was found in tumor cells and also in stromal cells (Figure 4). The expression of MMP-2 was homogeneous, cytoplasmically diffused and occasionally membranous as seen by intense staining in parts of membrane.

Relation of MMP-2 expression and activity with Estrogen receptors(ER)

Both ER positive and negative tumors of stage-II and stage-III showed High MMP-2 expression and activity. Approximately 52% of ER negative tumors and 50% of ER positive tumors were MMP-2 positive in stage-II and in cases of stage-III, 48.2% ER negative tumors and 41% of ER positive tumors were MMP-2 positive. However ER expression and MMP-2 activity were not significantly correlated for both stages.

Relation of MMP-2 expression and activity with Progesterone receptors (PR)

Our data clearly showed positive correlation of MMP-2 production and presence of progesterone receptors in stage II tumors. Both PR positive (93%) and negative tumors (30%) and in stage III tumors both PR negative tumors (70%) and PR positive tumors (46%) showed MMP-2 expression and activity. However no correlation was found within PR positive expression and MMP-2 activity in stage-III tumors.

Relation of MMP-2 expression and activity with Her-2 expression

MMP-2 was highly expressed in all HER-2 positive, stage-II tumors (90%) (relative risk: 1.94, $p=0.03$) and 55% of HER-2 positive, stage-III tumors (relative risk: 2.27, $p=0.04$). MMP-2 production was significantly correlated with HER-2 over expression. However in HER-2 negative tumors, MMP 2 production was less (30%).

Status of TIMP-2 in both TNM stage-II and III of breast cancer

The gene expression of TIMP-2 has been analyzed by representative semi quantitative RT-PCR. In both Stages II and III, no appreciable difference of TIMP-2 m-RNA in tumor tissues were found as compared to adjacent normal tissues (Figure 5a).

The expression pattern of TIMP-2 in both adjacent normal breast tissues and tumor tissues has been analyzed by representative ELISA (Figure 5b). In most of the cases, downregulation in TIMP-2 expression were found in tumor tissues compared to adjacent normal tissues.

Breast cancer progression is associated with upregulation of MT1-MMP,EMPRIN and VEGF

MT1-MMP m-RNA expression was analyzed in both tumor and normal breast tissues by RT-PCR where, transcriptional difference of MT1-MMP was found in tumors compared to adjacent normal breast tissue (Figure 6a). Our representative western blots showed that, MT1-MMP (Figure 6b), EMPRIN (Figure 7) and VEGF (Figure 8) expression were appreciably increased in tumors than adjacent normal breast tissue in both stage-II and III tumors compared to adjacent normal tissue.

Relation of MMP-2 expression with age and menopausal status

Age and menopausal status have a great influence in the development of breast cancer and expression of MMP-2 can also vary with respective to the age of the patients. In our representative zymographic study, for both the stages, MMP-2 gelatinolytic activity were appreciably higher with subsequent activation of MMP-2 in tumors in the age group of 35-60 years and pre-menopausal patients

compared to post menopausal indicating higher malignancy of the disease in patients of this specific age group (Figure 9).

DISCUSSION

We investigated the expression and activity of MMP-2, as well as it's relation to known prognostic parameters like estrogen receptors (ER), progesterone receptors(PR), and HER-2 in a prospective series of breast cancer patients from different stages of the disease. Expression of MMP-2 and MMP-9 in breast cancer are partly related to expression of HER2^[31].

The most pronounced difference in MMP-2 expression was seen in zymographic analysis. We found different gelatinolytic bands of activated MMP-2 in tumors. Gelatinolytic activity corresponding to one of the two activated forms of MMP-2 (i.e., the 68-kDa and 64kDa form) were more frequently observed in tumor than the precursor form and were more intense than that corresponding to pro gelatinase A (72 kDa). Our findings are in agreement with other studies suggesting that the activation of MMP-2 (gelatinase A) is a more common event in human breast carcinoma^[32,33]. In accordance with our current study, E.A Garbett (2000)^[34] found decreased latent MMP-2 expression and activity in non metastatic breast cancer. As the cancer progressed from DCIS to T4stage, there was a tendency towards an increment of the mRNA, protein expression and gelatinolytic activity of MMP-2 which becomes higher with subsequent activation of this protease. In several in situ hybridization studies, MMP-2 mRNA was identified mainly in stromal cells, although some has been detected in carcinoma cells^[35,36]. In immunohistochemical study For both stageII and III, MMP-2 over expression was found in tumor cells. Stromal fibroblasts secrete MMPs, which are stored and activated in carcinoma cells^[37]. In line with our study, some previous findings also suggest that, MMP-2 protein expressed mainly in the carcinoma cells^[38-42]. The comparable levels of pro MMP-2, between adjacent normal and malignant tissues in the current study, may be due to the fact that although MMP-2 is localized in the tumor stroma, its expression tends to be more focal. Garbett E A *et al* (2000)^[34] showed increased expression of TIMP-2 in invasive breast cancer and Ree A.H *et al* (1997) correlated increased amount of TIMP-1 and TIMP-2 with distant metastasis^[43].

In breast cancer, overexpression of HER-2/neu occurs either through changes in amplification and/or through messenger RNA (mRNA) overexpression. Studies indicate that in breast cancer, Positive stromal MMP-2 expression was associated with HER2 overexpression^[44] and down regulation of HER-2 is associated with decreased tumor invasiveness^[45]. HER-2/neu oncogene has been shown to inhibit the expression of the MMP inhibitor RECK to promote cell invasion in NIH/3T3 cells^[46]. In a previous study, Menha Swellam *et al* 2007 has also confirmed that, positive MMP-2, MMP-2/TIMP-2, HER-2/neu overexpression, higher tumor grade, late clinical stages and positive lymph nodes status were significantly associated with relapse^[47]. In this present study, positive MMP-2 expression was related to HER-2 over expression in cases of TNM stage-III appreciating previous observations.

Studies have confirmed the relationship between steroid hormones and increased gelatinase activity as well^[48-50]. Grieu F *et al* 2004^[51] have shown that, the MMP-2 genotype was associated with poor survival in patients with ER negative breast tumors, progesterone inhibits MMP-2 expression in a variety of tissues^[52-54]. In our present study, no significant association with MMP-2 and estrogen receptor (ER) and progesterone receptor (PR) expression was found.

Menopausal status is an important factor to decide prognosis

and can be divided into regular, pre and post menopausal status depending upon exposure of menstrual cycle. Studies reveal that higher gelatinase level is correlated with regular and pre menopausal patients of breast cancer than post menopausal patients^[55]. In our present study level of MMP-2 was higher in regular and pre menopausal patient group. Currently, the nodal status is the strongest prognostic factor in breast cancer. Li *et al* (2004)^[56], have reported that the co-expression of MMP-2 and MMP-9 has significant prognostic value in node-negative patients, for predicting relapse-free survival. However, the association of MMP-2 expression with lymph node involvement in patients of both stage-II and III was observed in our study.

MT-MMPs are a subfamily of MMPs that contain a transmembrane domain and therefore are inserted in the outer side of the plasma membrane^[57]. Because MMP-2 is secreted from cells in an inactive form (zymogen), activation of this proenzyme is necessary for its biological function. This activation appears to be mediated at least in part by MT1-MMP on the cell surface^[58]. Recently, the expression of MT1-MMP in various human cancer tissues has been associated with pro-MMP-2 activation^[59-61]. We observed increased expression of MT1-MMP in tumors.

Extracellular matrix metalloproteinase inducer (EMMPRIN) (also known as CD 147) is a 58 kDa glycoprotein was designated as tumor collagenase stimulating factor (TCSF) because of its ability to stimulate collagenase-1 (MMP-1) synthesis by tumor stromal fibroblast cells^[62]. Subsequent studies further demonstrated that EMMPRIN also induced fibroblast synthesis of MMP-2, MMP-3, as well as the membrane-type 1 MMP (MT1-MMP) and MT2-MMP that function as endogenous activators for MMP-2^[63-65]. In our present study, increased expression of EMMPRIN was also observed in tumors.

VEGF was observed across a range of tumor types and has been widely correlated with tumor development and/or poor prognosis^[66-69]. VEGF protein content is also increased in invasive

breast cancer and this overexpression has prognostic significance in patients for both relapse-free and overall survival^[70]. In patients with human epidermal growth factor receptor (HER)-2 overexpressing tumours, a higher VEGF content was demonstrated, confirming that VEGF is a downstream target of HER-2 activation^[71]. Studies reveal that over expression of VEGF significantly correlated with MMP-2 expression and activity in breast cancer^[72]. In our present study, enhanced expression of VEGF in tumors indicates its correlation with enhanced MMP-2 expression.

Previously we observed that cultivation of human breast cancer cells, MCF-7, in serum free medium in presence of fibronectin, upregulates the activity of MMP-2 and MMP-9. Blocking of $\alpha 5\beta 1$ integrin with anti- $\alpha 5$ monoclonal antibody inhibits the fibronectin-induced MMP activation response appreciably. Our study strongly indicated $\alpha 5\beta 1$ mediated signalling events in activation of MMP-2 and MMP-9 and phosphorylation of FAK and PI-3 kinase and the nuclear translocation of ERK and NF- κ B and possible participation of FAK/PI-3K/ERK signalling in the regulation of MMP-2 activity^[73].

As our previous studies indicated the role of integrin $\alpha 5\beta 1$ mediated signaling pathways in activation of MMP-2 in breast cancer cell line MCF-7, proteolytic activation mechanism of MMP-2 in breast tumors (stage-III) may be dependent to integrin $\alpha 5\beta 1$ -fibronectin system mediated signaling pathways leading to activation of pro-MMP-2 and increased invasiveness of breast cancer cells. Our findings may have potential applications in understanding as well as management of breast cancer.

ACKNOWLEDGMENTS

The authors wish to acknowledge Department of Science and Technology(DST), Government of India for financial support of this project(DST No: SR/SO/HS-123/2008) and Director, Chittaranjan National Cancer Institute (CNCI) for giving infrastructural support to this work.

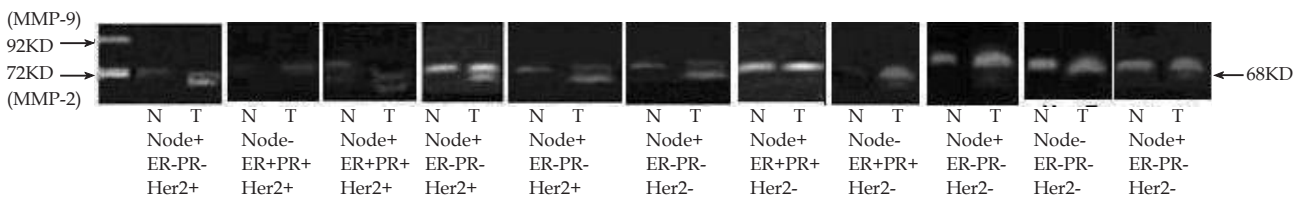


Figure 1A Gelatinolytic activity of MMP-2 in TNM stage-II patients: 100 ug of tissue extract from tumor samples(lane-T) and respective adjacent normal breast tissues(lane-N) was taken. The gelatinases were enriched and zymograms were developed. Marker lane is MMP-9 (92 kDa) / MMP-2 (72 KDa) (SFCM of HT-1080 cells grown for 24 hours).

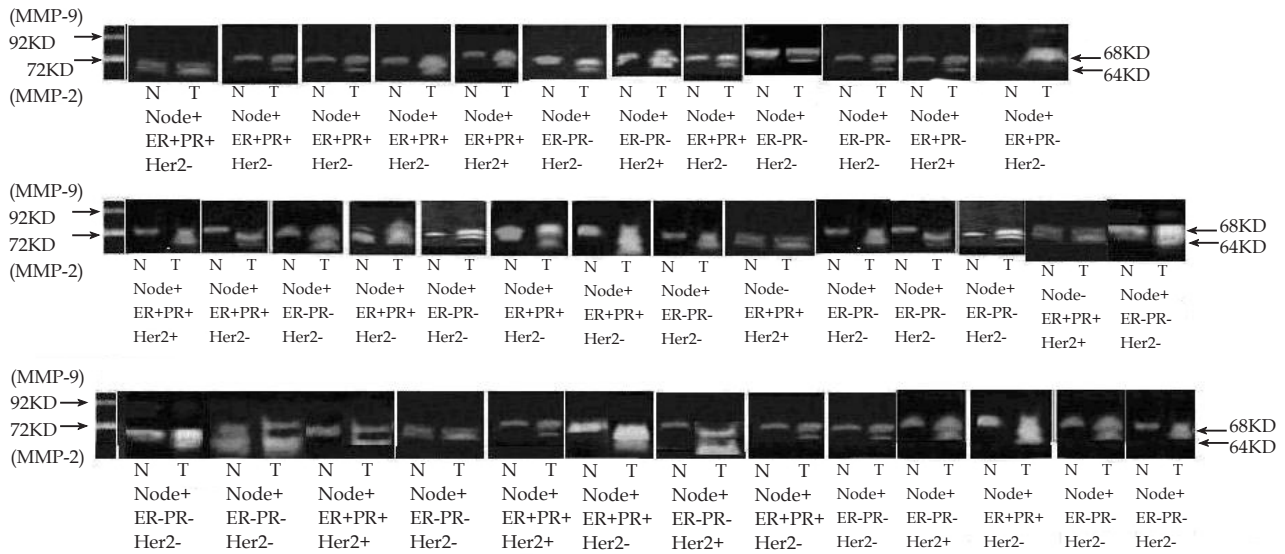


Figure 1B Gelatinolytic activity of MMP-2 in TNM stage-III patients: Equal amount of protein (100µg each) from stage III samples were taken. Zymograms were developed following standard method described in method section. Marker lane is MMP-9 (92 kDa) / MMP-2 (72 kDa) (SFCM of HT-1080 cells grown for 24 hours).




Figure 2 Expression of MMP-2 mRNA in both tumor and adjacent normal tissues by semi-quantitative RT-PCR: RT-PCR of cancer and corresponding normal tissue were done following standard method . The accompanying graph represents the comparative densitometric/quantitative analysis of the band intensities using image J Launcher (version 1.4.3.67).

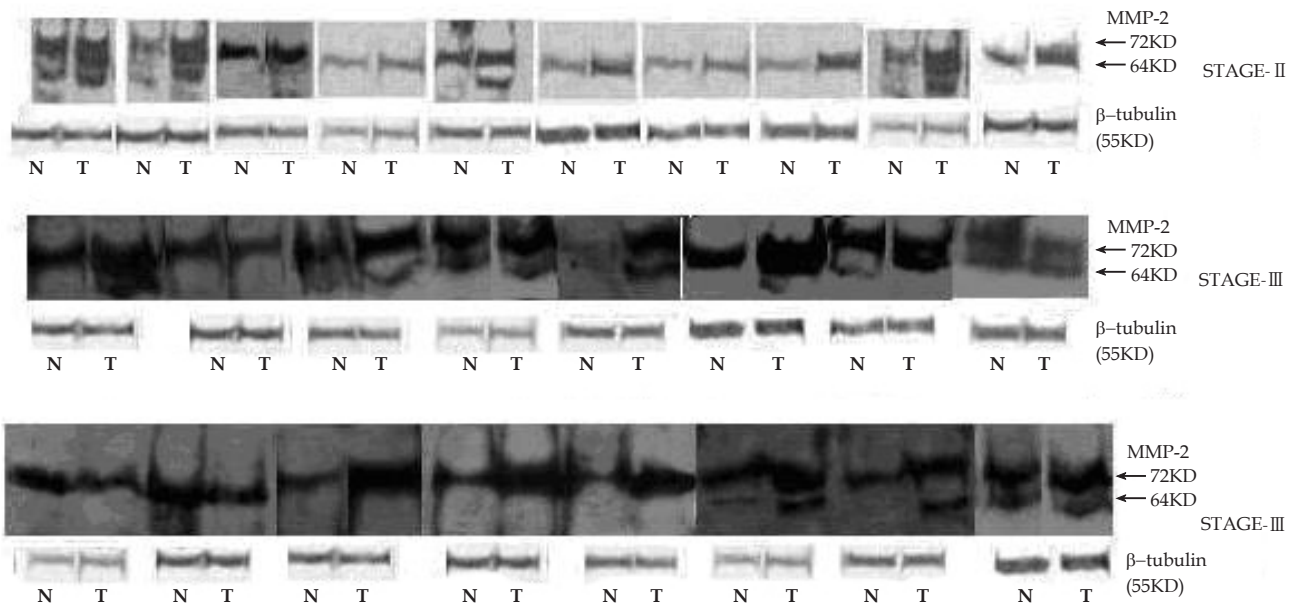


Figure 3 Expression of MMP-2 in both tumor and adjacent normal tissues by immunoblot: Immunoblot of tumors and corresponding normal tissue extracts (50 ug) were developed following procedure described. Bands were visualized using super signal femto as substrate. The accompanying graph represents the comparative densitometric/quantitative analysis of the band intensities using image J Launcher (version 1.4.3.67).

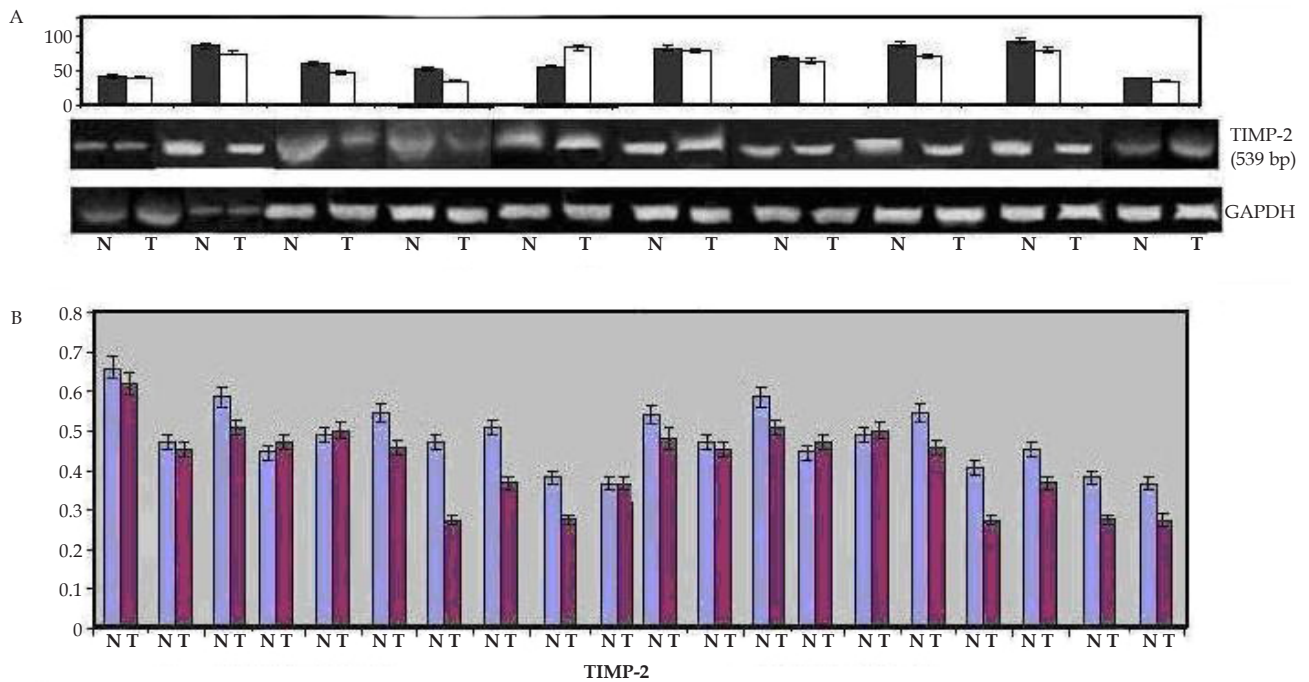


Figure 5 A: Expression of TIMP-2 mRNA in both tumor and adjacent normal tissues by semi-quantitative RT-PCR: TIMP-2 RT-PCR of both adjacent normal (lane-N) and respective tumor tissues (lane-T) were done following methods section. The accompanying graph represents the comparative densitometric/quantitative analysis of the band intensities using image J Launcher (version 1.4.3.67). B: Expression of TIMP-2 in both tumor and adjacent normal tissues by ELISA: Comparative ELISA of cancer and corresponding normal tissue extracts were developed following methods section. The accompanying graph represents the comparative densitometric/quantitative analysis of the band intensities using image J Launcher (version 1.4.3.67).

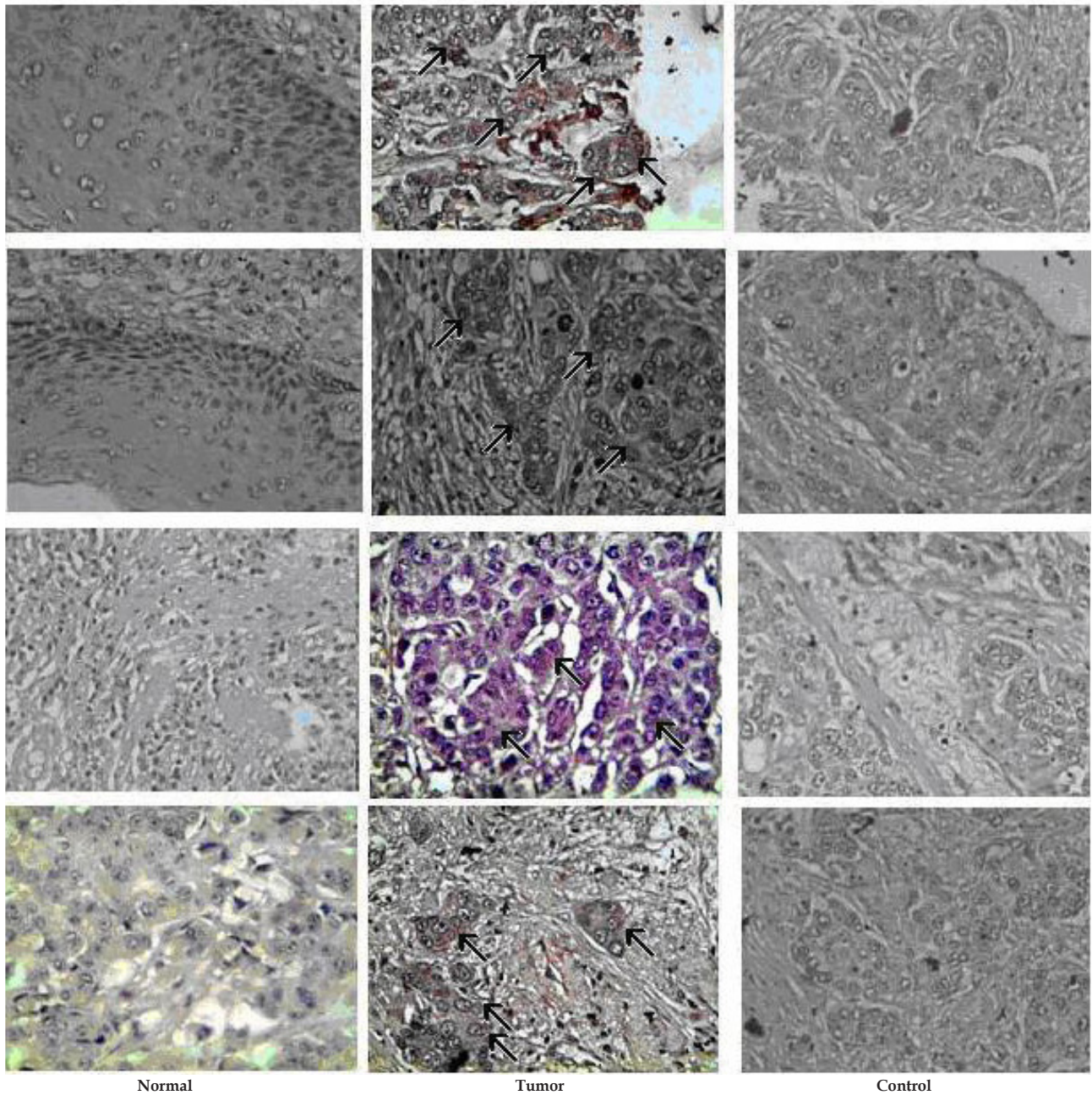


Figure 4 Expression of MMP-2 in both tumor and adjacent normal tissues by immunohistochemistry: Immunohistochemistry of both normal and tumor samples were done following methods section. The slides were counterstained with Mayer's hematoxylin, dehydrated and mounted with DePex. A routinely processed breast cancer section without the primary antibody served as negative control at each staining series. Arrows indicate detection of MMP-2 in cytoplasmic area of tumor cells identified pathologically by intense staining.

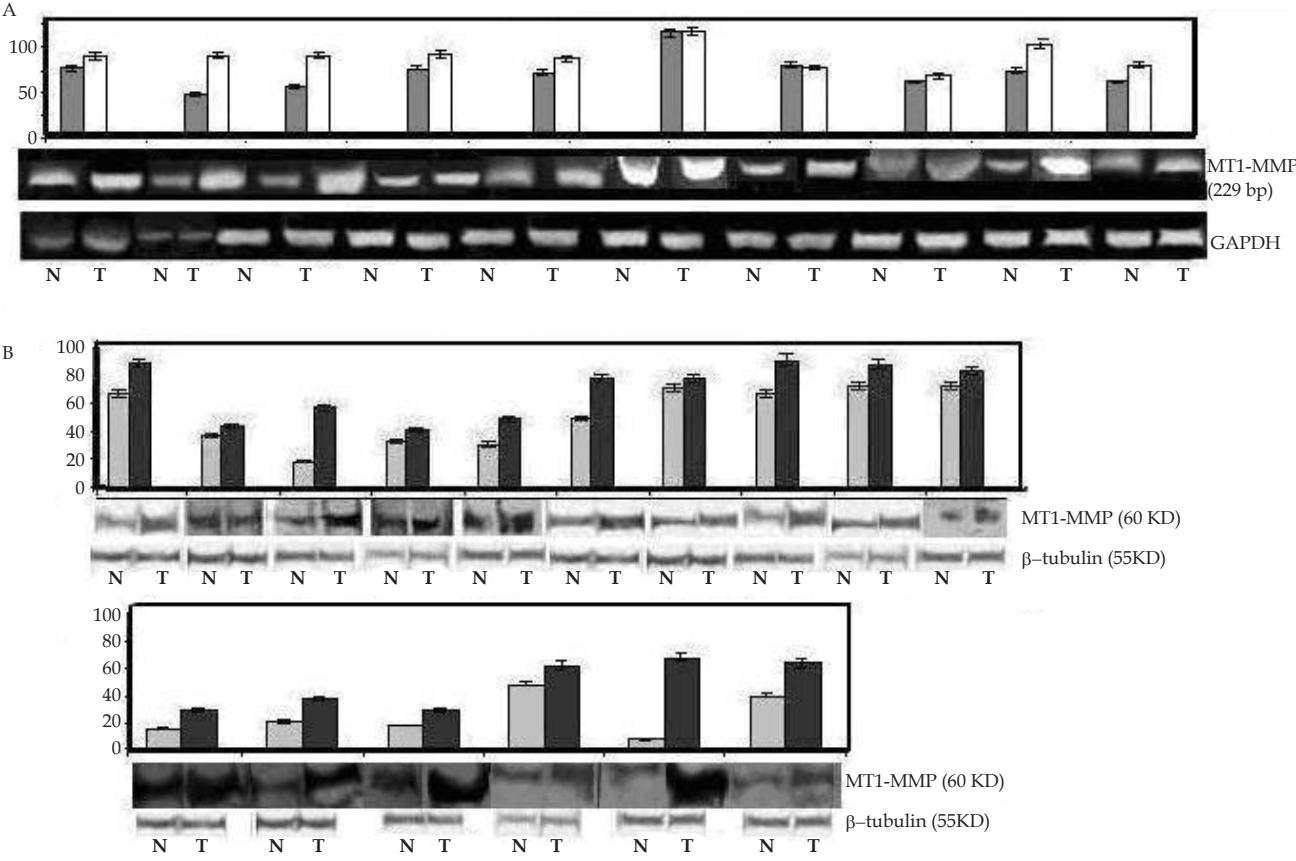


Figure 6 A: Expression of MT1-MMP mRNA in both tumor and adjacent normal tissues by semi-quantitative RT-PCR: MT1-MMP mRNA was measured by RT-PCR of both adjacent normal (lane-N) and respective tumor tissues (lane-T) samples as described in methods. The accompanying graph represents the comparative densitometric/quantitative analysis of the band intensities using image J Launcher (version 1.4.3.67). B: Expression of MT1-MMP in both tumor and adjacent normal tissues by immunoblot: Immunoblot of both cancer and corresponding normal tissue extract were developed. Bands were visualized using super signal femto as substrate. The accompanying graph represents the comparative densitometric/quantitative analysis of the band intensities using image J Launcher (version 1.4.3.67).

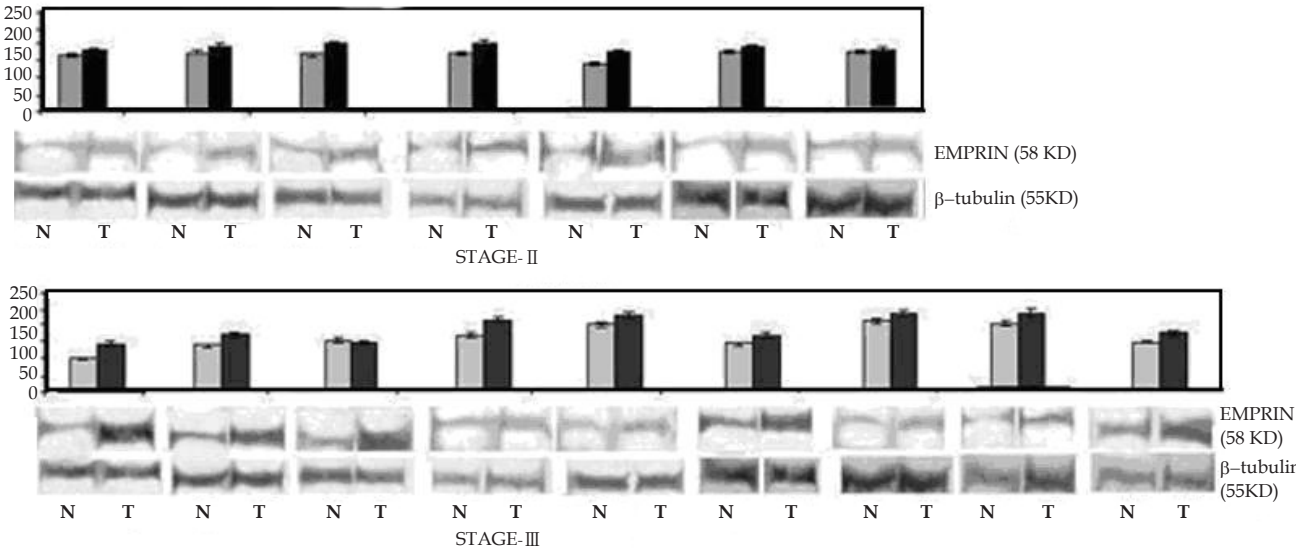


Figure 7 Expression of EMPRIN in both tumor and adjacent normal tissues by immunoblot: Immunoblots of cancer and corresponding normal tissue extracts were developed. Bands were visualized using super signal femto as substrate. The accompanying graph represents the comparative densitometric/quantitative analysis of the band intensities using image J Launcher (version 1.4.3.67).

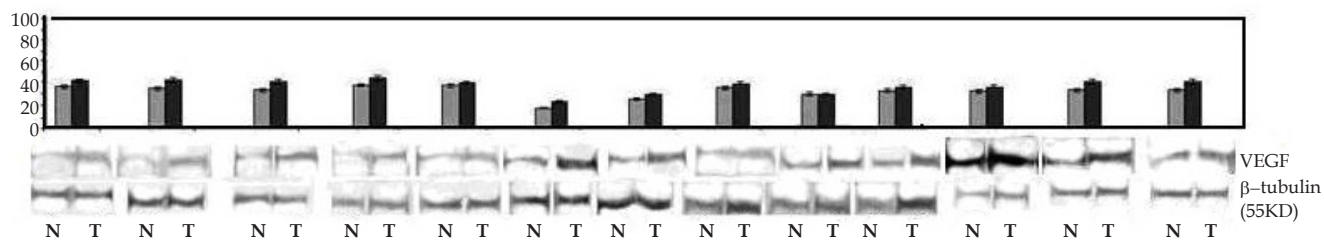


Figure 8 Expression of VEGF in both tumor and adjacent normal tissues by immunoblot: Immunoblots of cancer and corresponding normal tissue extracts were developed following method described.. The accompanying graph represents the comparative densitometric/quantitative analysis of the band intensities using image J Launcher (version 1.4.3.67).

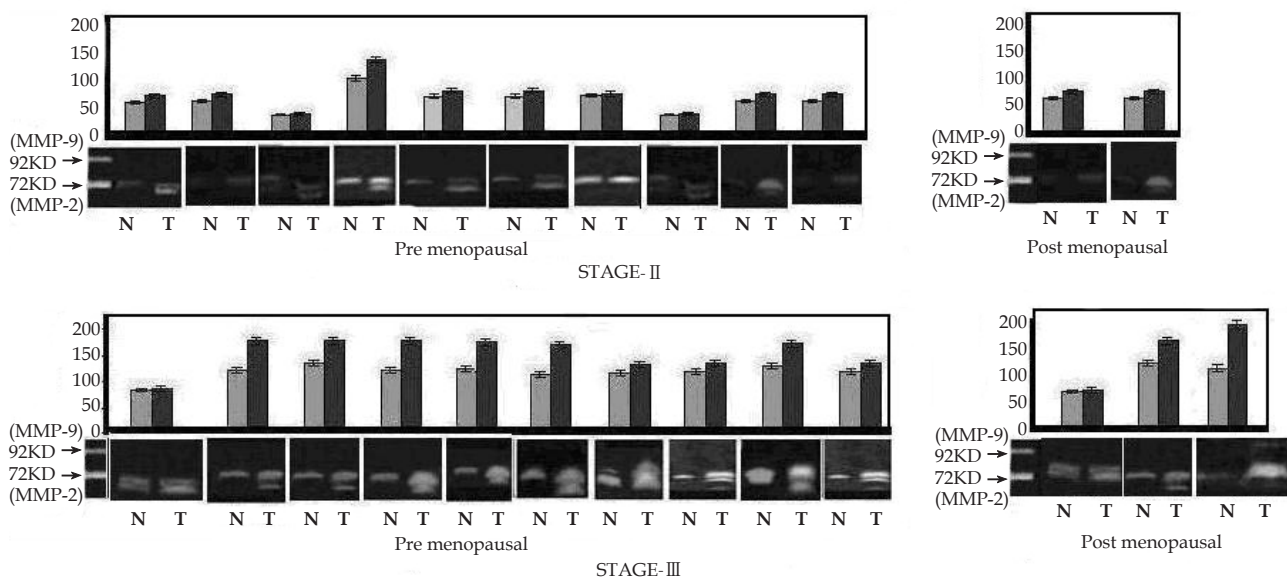


Figure 9 Gelatinolytic activity of MMP-2 by zymographic analysis from patients of TNM stage-II and III in relation to menopausal status: Zymogram of tissue samples of tumor (lane-T) and respective adjacent normal breast tissues(lane-N) of the same patients were developed as described in methods. Marker lane is MMP-9 (92 kDa) / MMP-2 (72 KDa) (SFCM of HT-1080 cells grown for 24 hours). The accompanying graph represents the comparative densitometric/quantitative analysis of the band intensities using image J Launcher (version 1.4.3.67).

CONFLICT OF INTERESTS

There are no conflicts of interest with regard to the present study.

REFERENCES

- 1 Chambers AF, Matrisian LM. Changingviews of the role of matrix Metalloproteinases in metastasis. *J Natl Cancer Inst* 1997; **89**: 1260-1270
- 2 Liotta LA, Stetler-StevensonWG. Metalloproteinases and cancer invasion. *Semin Cancer Biol* 1990; **1**: 99-106
- 3 Liotta LA, Wewer U, Rao NC, Schiffmann E, Stracke M, Guirguis R, Thorgeirsson U, Muschel R, Sobel M. Biochemical mechanisms of tumor invasion and metastases. *Prog Clin Biol Res* 1998; **256**: 3–16
- 4 Curran S, Murray GI. Matrix metalloproteinases in tumour invasion and metastasis. *J Pathol* 1999; **189**: 300-308
- 5 Levy AT, Cioce V, Sobel ME, Garbisa S, Grigioni WF, Liotta LA, Stetler-Stevenson WG. Increased expression of the 72 kDa type IV collagenase in human colonic adenocarcinoma. *Cancer Res* 1991; **51**: 439-444
- 6 D’Errico A, Garbisa S, Liotta LA, Castronovo R, Stetler-Stevenson W, Grigioni WF. Augmentation of type IV collagenase and laminin receptors immunoreactivity associated with human breast, colon and

- gastric carcinoma progression. *Mod Pathol* 1991; **4**: 239-246
- 7 Ellenrieder V, Alber B, Lacher U, Hendlr SF, Menke A, Boeck W, Wagner M, Wilda M, Friess H, Buchler M, Adler G, Gress TM. Role of MT-MMPs and MMP-2 in pancreatic cancer progression. *Int J Cancer* 2000; **85**: 14-20
- 8 Giannelli G, Bergamini C, Marinosci F, Fransvea E, Quaranta M, Lupo L, Schiraldi O, Antonaci S .Clinical role of MMP-2/TIMP-2 imbalance in hepatocellular carcinoma. *Int J Cancer* 2002; **97**: 425-431
- 9 Sakata K, Shigemasa K, Nagai N, Ohama K. Expression of matrix metalloproteinases (MMP-2, MMP-9, MT1-MMP) and their inhibitors (TIMP-1, TIMP-2) in common epithelial tumors of the ovary. *Int J Oncol* 2000; **17**: 673-681
- 10 Vaisanen A, Kallioinen M, Taskinen PJ, Turpeenniemi-Hujanen T. Prognostic value of MMP-2 immunoreactive protein (72 kD type IV collagenase) in primary skin melanoma. *J Pathol* 1998; **186**: 51-58
- 11 Kodate M, Kasai T, Hashimoto H, Yasumoto K, Iwata Y, Manabe H. Expression of MMP (gelatinase) in T1 adenocarcinoma of the lung. *Pathol Int* 1997; **47**: 461-469
- 12 Davidson B, Goldgerg I, Gotlieb WH, Kopolovic J, Ben-Baruch G, Nesland JM, Berner A, Bryne M, Reich R. High levels of MMP-2, MMP-9, MT1-MMP and TIMP-2 mRNA correlate with poor survival in ovarian carcinoma. *Clin Exp Metastasis* 1999; **17**: 799-808

- 13 Ja a linoja J, Herva R, Korpela M, Hoyhtya M. Turpeenniemi-Hujanen T. Matrix metalloproteinase-2 (MMP-2) immunoreactive protein is associated with poor grade and survival in brain neoplasms. *J Neuro oncol* 2000; **46**: 81-90
- 14 Monteagudo C, Merino MJ, San-Juan J, Liotta LA, Stetler-Stevenson WG. Immunohistochemical distribution of type IV collagenase in normal, benign, and malignant breast tissue. *Am J Pathol* 1990; **136**: 585-592
- 15 Tryggvason K, Ho"yhtya M, Pyke C. Type IV collagenase in invasive tumors. *Breast Cancer Res Treat* 1993; **24**: 209-218
- 16 Iwata H, Kobayashi S, Iwase H, Masaoka A, Fujimoto N, Okada Y. Production of matrix metalloproteinases and tissue inhibitors of metalloproteinases in human breast carcinomas. *Jpn J Cancer Res* 1996; **87**: 602-611
- 17 Daidone MG, Silvestrini R, D'Errico A, Di Fronzo G, Benini E, Mancini WAM, Garbisa S, Liotta LA, Grigioni WF. Laminin receptors, collagenase IV and prognosis in node-negative breast cancers. *Int J Cancer* 1991; **48**: 529-532
- 18 Ho"yhtya M, Fridman R, Komarck D, Porter-Jordan K, Stetler-Stevenson WG, Liotta LA, Liang CM. Immunohistochemical localization of matrix metalloproteinase-2 and its specific inhibitor TIMP-2 in neoplastic tissue with monoclonal antibodies. *Int J Cancer* 1994; **54**: 500-505
- 19 Nagase H, Okada Y. Proteinases and matrix degradation. Textbook of Rheumatology. 5th Ed Philadelphia: W. B. Saunders Company; 1997: 323-341
- 20 Strongin AY, Manner B.L, Grant GA Goldberg G I. Plasma membrane dependentactivationof 72 kDa type IV collagenaseis prevented by complex formationwithTIMP-2. *J Biol Chem* 1993; **268**: 14033-14013999.
- 21 Strongin AY, Collier I, Bannikov G, Manner B L, Grant G A, and Goldberg G I. Mechanismof cell surface activation of 72 kDa type-IV collagenase. *J Biol Chem* 1995; **270**: 5331-5338
- 22 Okada Y, Morodomi T, Enghild J. J, Suzuki K, Yasui A, Nakanishi I, Salvesen G, Nagase H. Matrix metalloproteinase 2 from human rheumatoid synovial fibroblasts: purification and activation of the precursor and enzymic prop erties. *Eur J Biochem* 1990; **194**: 721-730
- 23 Sato H, Takino T, Okada Y, Cao J, Shinagawa A, Yamamoto E, and Seiki M A Matrix metalloproteinase expressed on the surface of invasive tumor cells. *Nature (Lond)* 1994; **370**: 61-65
- 24 Corcoran M L, Hewitt R E, Kleiner D E Jr, Stetler- Stevenson W J. MMP-2: expression, activation and inhibition. *Enzyme Prot* 1996; **49**: 7-19
- 25 Nomura H, Sato H, Seiki M, Mai M, and Okada Y. Expression of membrane-type matrix metalloproteinase in human gastric carcinoma. *Cancer Res*1995; **55**: 3263-3266
- 26 Ueno H, Nakamura H, Inoue M, Imai K, Noguchi M, Sato H, Seiki M, and Okada Y. Expression and tissue localization of membrane types 1, 2, and 3 matrix metalloproteinases in human invasive breast carcinomas. *Cancer Res* 1997; **57**: 2055-2060
- 27 Brown P D, Bloxidge R E, Anderson E, and Howell A. Expression of activated gelatinase in human invasive breast carcinoma. *Clin. Exp. Metastasis* 1993; **11**: 183-189
- 28 Devies B, Miles D V, Happerfield L C, Naylar M S, Bobrow L, Rubens R D and Balkwill F R. Activity of type IV collagenases in benign and malignant breast disease. *Br. J. Cancer* 1993; **67**: 1126-31
- 29 Okada A, Bellocq J P, Rouyer N, Chenard M P, Rio M C, and Chambon P. Membrane-type matrix metalloproteinase (MT-MMP) gene is expressed in stromal cells of human colon, breast, and head and neck carcinomas. *Proc. Nail. Acad. Sci* 1995; **92**: 2730-2734
- 30 Polette M, Nawrocki B, Gilles C, Sato H, Seiki M, Toumier J M, Birembaut P. MT-MMP expression and localization in human lung and breast cancers. *Virchows Arch* 1996; **428**: 29-35
- 31 Pellikainen JM, Ropponen KM, Kataja VV, Kellokoski JK, Eskelinen MJ, kosma VM. Expression of matrix metalloproteinase 2 and 9 in breast cancer with a special reference to activator protein, Her-2 and prognosis. *Clin Cancer Res* 2004; **10**: 7621-7628
- 32 Salmon DJ, Clark GM, Wrong SG, Levin WJ, Ullrich A, McGuire WL. Human breast cancer: correlation of relapse and survival with amplification of Her-2/neuoncogene, *Science* 1987 ;**235**: 177-182
- 33 Gershenwald JE, Sumner W, Calderone T, et al. Dominant-negative transcription factor AP-2 augments SB-2 melanoma tumor growth in vivo. *Oncogene* 2001; **20**: 3363-3375
- 34 Garbett EA, Reed MWR, Stephenson TJ, Brown NJ. Proteolysis in human breast cancer. *J. Clin. Pathol: Mol Pathol* 2000; **53** :99-106
- 35 Soini Y, Hurskainen T, Hoyhtya M, Oikarinen A, Harmainen HA. 72 KD and 92 KD Type IV Collagenase, Type IV Collagen, and Laminin mRNAs in Breast Cancer: A Study by In Situ Hybridization. *J Histochem Cytochem* 1994; **42**: 945-951
- 36 Jones JL, Glynn P, Rosemary Walker A. Expression of MMP-2 and MMP-9, their inhibitors, and the activator MT1-MMP in primary breast carcinomas, *J. Pathol* 1999; **189**: 161-168
- 37 Polette M, Gilbert N, Stas I, Nawrocki B, Noel A, Remacle A, Stetler-Stevenson WG, Birembaut P, Foidart M . Gelatinase A expression and localization in human breast cancers. An in situ hybridization study and immunohistochemical detection using confocal microscopy. *Virchows Arch* 1994; **424**: 641-645
- 38 Talvensaari-Mattila A, Paakko P, Turpeenniemi-Hujanen T. Matrix metalloproteinase-2 (MMP-2) is associated with survival in breast carcinoma. *Br J Cancer* 2003; **89**: 1270-1275
- 39 Talvensaari-Mattila A, Paakko P, Blanco-Sequeiros G, Turpeenniemi-Hujanen T. Matrix metalloproteinase-2 (MMP-2) is associated with the risk for a relapse in postmenopausal patients with node-positive breast carcinoma treated with antiestrogen adjuvant therapy. *Breast Cancer Res Treat* 2001; **65**: 55-61
- 40 Talvensaari-Mattila A, Paakko P, Hoyhtya M, Blanco-Sequeiros G, Turpeenniemi-Hujanen T. Matrix metalloproteinase-2 immunoreactive protein: a marker of aggressiveness in breast carcinoma. *Cancer (Phila)* 1998; **83**: 1153-1162
- 41 Talvensaari-Mattila A, Paakko P, Turpeenniemi-Hujanen T. MMP-2 positivity and age less than 40 years increases the risk for recurrence in premenopausal patients with node-positive breast carcinoma. *Breast Cancer Res Treat* 1999; **58**: 287-293.
- 42 Brummer O, Athar S, Riethdorf L, Loning T, Herbst H. Matrix-metalloproteinases 1, 2, and 3 and their tissue inhibitors 1 and 2 in benign and malignant breast lesions: an in situ hybridization study. *Virchows Arch* 1999; **435**:566-573.
- 43 Ree AH, Florenes VA, Berg JP, Maelandsmo GM, Nesland JM, Fodstad O. High levels of messenger RNAs for tissue inhibitors of metalloproteinases (TIMP-1 and TIMP-2) in primary breast carcinomas are associated with development of distant metastases. *Clin. Cancer. Res* 1997; **3**: 1623-1628
- 44 Huang HJ, Neven P, Drijkoningen M, Paridaens R, Wildiers H, Van Limbergen E, Berteloot P, Amant F, Vergote I, Christiaens M R. Association between tumor characteristics and HER-2/neu by immunohistochemistry in 1362 women with primary operable breast cancer. *J Clin Pathol* 2005; **58**: 611-616
- 45 Pan MH, Chen WJ. The Cancer Preventive Potential of Tea Polyphenol EGCG in HER2-Positive Breast Cancer. Functional Food and Health, Washington, DC 2008: 335-344
- 46 Hsu M, Chang HC, Hung WC. HER-2/neu Represses the metastasis suppressor RECK via ERK and Sp Transcription Factors to Promote Cell Invasion. *The Journal of Biological Chemistry* 2006; **281**: 4718-4725
- 47 Swellam M, Lobna R. Arab EE, Bushna HA. Clinical Implications of HER-2/neu Overexpression and Proteolytic activity imbalance in breast cancer. *IUBMB Life* 2007; **59**: 394-401
- 48 Paquette B. Activation of matrix metalloproteinase -2 and -9 by 2- and 4-hydroxyestradiol. *J Steroid Biochem Mol Biol* 2003; **87**: 65-73
- 49 Thompson EW, Reich R, Shima TB, Albini A, Graf J, Martin GR, Dickson RB Lippman ME. Differential regulation of growth and invasiveness of MCF-7 breast cancer cells by antiestrogens. *Cancer*

- Res* 1988; **48**: 6764-6768
- 50 Van den Brule FA, Engel J, Stetler-Stevenson WG, Liu FT, Sobel ME, Castronovo V. Genes involved in tumor invasion and metastasis are differentially modulated by estradiol and progesterin in human breast-cancer cells. *Int J Cancer* 1992; **52**: 653-657
- 51 Grieu F, Li WQ, Iacopetta B. Genetic polymorphisms in the MMP-2 and MMP-9 genes and breast cancer phenotype 2004; **88**:197-204
- 52 Sillanpaa S, Anttila M, Suhonen K, Hämäläinen K, Turpeenniemi-Hujanen T, Puustola U, Tammi M, Sironen R, Saarikoski S, Kosma VM. Prognostic significance of extracellular matrix metalloproteinase inducer and matrix metalloproteinase 2 in epithelial ovarian cancer. *Tumor Biol* 2007; **28**:280-289
- 53 Goldman S, Weiss A, Shalev E. The effect of progesterone on gelatinase expression in the decidua and fetal membranes before and after contractions. *Am J Obstet Gynecol* 2007; **197**: 521
- 54 Saito T, Mizumoto H, Tanaka R, Satohisa S, Adachi K, Horie M, Kudo R. Overexpressed progesterone receptor form B inhibit invasive activity suppressing matrix metalloproteinases in endometrial carcinoma cells. *Cancer Lett* 2004; **209**: 237-243
- 55 Patani MR, Jain J, Marya BH, Patel MB. Role of matrix metalloproteinase-2 in glioma patient specific in age, gender & menopausal status. *Journal of Global Pharma Technology* 2011; **3**: 38-44
- 56 Li HC, Cao DC, Liu Y, Hou YF, Wu J, Lu JS, Di GH, G Liu, Li FM, Ou ZL, Jie C, Shen ZZ, Shao ZM. Prognostic value of matrix metalloproteinases (MMP-2 and MMP-9) in patients with lymph node-negative breast carcinoma. *Breast. Cancer. Res Treat* 2004; **88**: 75-85
- 57 Sato H, Takino T, Okada Y, Cao J, Shinagawa A, Yamamoto E, Seiki M A. Matrix metalloproteinase expressed on the surface of invasive tumor cells. *Nature (Lond.)* 1994; **370**: 61-65
- 58 Corcoran M L, Hewitt R E, Kleiner D E, Jr, and Stetler-Stevenson W J. MMP-2: expression, activation and inhibition. *Enzyme Prot* 1996; **49**: 7-19
- 59 Nomura H, Sato H, Seiki M, Mai M, Okada Y. Expression of membrane type matrix metalloproteinase in human gastric carcinoma. *Cancer Res* 1995; **55**: 3263-3266
- 60 Ueno H, Nakamura H, Inoue M, Imai K, Noguchi M, Sato H, Seiki M, and Okada Y. Expression and tissue localization of membrane types 1, 2, and 3 matrix metalloproteinases in human invasive breast carcinomas. *Cancer Res* 1997 **57**: 2055-2060
- 61 E Maquoi, D Assent, J Detilleux, C Pequeux, J-M Foidart A Noël. MT1-MMP protects breast carcinoma cells against type I collagen-induced apoptosis. *Oncogene* 2011; **25**:1465-1469
- 62 Ellis SM, Nabeshima K and Biswas C. Monoclonal antibody preparation and purification of a tumor cell collagenase stimulatory factor. *Cancer Res* 1989; **49**: 3385-3391
- 63 Guo H, Zucker S, Gordon MK, Toole BP, Biswas C. Stimulation of matrix metalloproteinase production by recombinant extracellular matrix metalloproteinase inducer from transfected Chinese hamster ovary cells. *J Biol Chem* 1997; **272**: 24-27
- 64 Kataoka H, DeCastro R, Zucker S, Biswas C. Tumor cell-derived collagenase-stimulatory factor increases expression of interstitial collagenase, stromelysin, and 72-kDa gelatinase. *Cancer Res* 1993; **53**: 3154-3158
- 65 Sameshima T, Nabeshima K, Toole BP, Yokogami K, Okada Y, Goya T, Koono M, Wakisaka S. Glioma cell extracellular matrix metalloproteinase inducer (EMMPRIN) (CD147) stimulates production of membrane-type matrix metalloproteinases and activated gelatinase A in co-cultures with brain-derived fibroblasts. *Cancer Lett* 2000; **157**: 177-184
- 66 Ferrara, N. Vascular endothelial growth factor: basic science and clinical progress. *Endocr Rev* 2004; **25**: 581-611
- 67 Hicklin DJ, Ellis LM. Role of the vascular endothelial growth factor pathway in tumor growth and angiogenesis. *J Clin Oncol* 2005; **23**: 1011-1027
- 68 Magolin K. Inhibition of vascular endothelial growth factor in the treatment of solid tumors. *Curr Oncol Rep* 2002; **4**: 20-28
- 69 Guidi A.J., Schnitt, S.J., Fisher, L., Tognazzi, K.Harris, J.R., Dvorak, H.F, Brown LF. Vascular permeability factor (vascular endothelial growth factor) expression and angiogenesis in patients with ductal carcinoma in situ of the breast. *Cancer* 1997; **80**: 1945-1954
- 70 Toi M, Matsumoto T, Bando H. Vascular endothelial growth factor: its prognostic, predictive, and therapeutic implications. *Lancet Oncol* 2001; **2**: 667-673
- 71 Masood R, Cal J, Zheng T, Smith DL, Hinton DR, Gill PS. Vascular endothelial growth factor (VEGF) is an autocrine growth factor for VEGF receptor-positive human tumors. *Blood* 2001; **98**: 1904-1913
- 72 Zheng SQ, Huang RQ, Zhang YJ. Role of matrix metalloproteinase (MMP)-2 and -9 and vascular endothelial growth factor C in lymph node metastasis of breast cancer. *Zhonghua Bing Li Xue Za Zhi* 2010; **39**: 240-244
- 73 Das S, Banerji A, Frei E, Chatterjee A. Rapid expression and activation of MMP-2 and MMP-9 upon exposure of human breast cancer cells (MCF-7) to fibronectin in serum free medium. *Life Sci* 2008; **82**:467-476

Peer reviewer: Kapil MEHTA, Professor, PhD, Department of Experimental Therapeutics, UT M.D. Anderson Cancer Center, Houston, TX 77054, USA.