

Manual Lymphatic Drainage with Facial Paralysis after Schwannoma: A Case Report

Margit Eidenberger

Margit Eidenberger, University of Applied Sciences for Health Professions Upper Austria Campus Health Landes-Krankenhaus Steyr Bachelor Programme Physiotherapy Sierningerstr. 170, Austria

Correspondence to: Margit Eidenberger, University of Applied Sciences for Health Professions Upper Austria Campus Health Landes-Krankenhaus Steyr Bachelor Programme Physiotherapy Sierningerstr. 170, A-4400 Steyr, Austria.

Email: Margit.Eidenberger@fhgooe.ac.at

Telephone: +4350344262-23 Fax: +4350344212-99

Received: July 11, 2015 Revised: October 28, 2015

Accepted: November 3, 2015

Published online: November 10, 2015

© 2015 ACT. All rights reserved.

Key words: Schwannoma, Facial Paralysis, Manual Lymphatic Drainage

Eidenberger M. Manual Lymphatic Drainage with Facial Paralysis after Schwannoma: A Case Report. *Journal of Tumor* 2015; 3(3): 356-359 Available from: URL: <http://www.ghrnet.org/index.php/JT/article/view/1451>

ABSTRACT

AIM: Facial paralysis is a common complication after Schwannoma surgery. Neural edema can be one of the reasons. Manual Lymphatic Drainage is the most efficient therapy in resolving lymphedemas, but has to date not been tried for facial paralysis in conjunction with Schwannoma surgery. It was therefore the aim of this paper to try Manual Lymphatic Drainage.

MATERIALS AND METHODS: Case report of a 46-year old female Caucasian patient who has suffered from facial paralysis and intraoral seroma for one year after Schwannoma resection. Over that year, the facial paralysis showed a non-therapy-induced recovery of one degree on the House-Brackmann Facial Nerve Grading Scale. Three months prior to referral, a gold implant to facilitate eye closure was inserted in the upper eyelid. The patient suffered from eye region edema, redness in the eye region and conjunctiva, dry eye syndrome, a scraping feeling and glued eye. Conventional physiotherapy (facio-oral therapy, mimic exercises) showed no results. Six Manual Lymphatic Drainage treatments were performed. This led to a regression of the edema and the seroma after the first and the third therapy sessions, respectively. The facial paralysis improved by one degree (V-IV). As a consequence, the use of lubrication ointment could be reduced.

CONCLUSION: Manual Lymphatic Drainage can be applied as an adjuvant therapy in Facial Paralysis and edema related to Schwannoma, which are not responsive to other therapies.

INTRODUCTION

Facial paralysis (FP) is a common complication after Schwannoma surgery (a benign tumor of the vestibulocochlearic nerve). The incidence ranges from 2 to 17%^[1] and depends on tumor size^[2], the selected incision and whether intraoperative nerve monitoring was applied^[3]. The severity of FP according to Kazim *et al*^[4] is significantly higher in patients with tumors ≥ 4 cm in diameter. The standard treatment of Schwannoma is surgery. Different techniques (e.g. retrosigmoidal, transtemporal, translabyrinthine) are possible. Morton *et al*^[5] described edema formation, inflammation or circulatory disturbances as possible post-operative causes of FP. Further impairment of the nervous function can be due to the development of neural edema^[6].

CASE PRESENTATION

The case of a 46-year old female Caucasian patient with facial paralysis after Schwannoma resection is presented. This patient had suffered from unilateral hearing loss on the left side (Tinnitus and Tarditus) since May 2011. On 27th October 2011, an osteoplastic retro-mastoidal trepanation with microsurgical tumor extirpation of a Schwannoma grade IVa (2.5cm Ø) with displacement of the brain stem was performed on the left side. She was discharged after four days in intensive care and eight days on the general ward after inconspicuous primary wound healing. According to House-Brackmann Facial Nerve Grading Scale (HBFNGS), she was classified with facial paralysis grade VI. She was provided with a moister chamber to prevent eye exsiccation and medical supplements

(Oleovit, Vidisic, Oculotect; 3-6x daily). Mexalen was prescribed to be taken at the patient's discretion for pain control during the short-term post-surgery phase. The audiogram showed deafness of 93%; this was partially compensated by a hearing aid device. On 17th July 2012, a gold implant to facilitate eye closure was inserted in the left upper eyelid. Only after this second surgery did the edema in the eye region, the redness, the dry eye syndrome, scraping feeling and glued eye develop (cp. Figure. 1). The patient stated that she was a waitress in a restaurant.

The patient was referred to Manual Lymphatic Drainage (MLD) in October 2012. One year after the first and three months after the second surgery her facial paralysis was still grade V HBFNGS. Ongoing conventional physiotherapy, including mimic exercises, failed to improve her symptoms. The upper and lower eyelid and the tear sack were swollen. The conjunctiva and the skin surrounding the eye were reddened caudally, laterally and laterally/cranially (Figure. 1). The patient reported the eye to be glued, especially in the mornings and a scraping feeling in addition to a dry eye syndrome. No pain or sensitivity disorders or lockjaw were reported or could be detected.

She applied eye ointments and artificial tear fluid as prescribed (Table.1). The surgery left her with a scar behind the ear, which was covered by her hair. The scar was 5cm long and 1-2mm wide. The scar was versatile over the whole length in all directions. An acute inflammation was ruled out by an ophthalmologist. The patient's informed consent was obtained. The physiotherapeutic assessment further showed a fluid accumulation (i.e. seroma) in the inner left cheek. This impaired her speech and food intake. From the outside, a swelling in the cheek region could not be assessed by inspection or palpation. There was noticeable face asymmetry when comparing the two sides. This was partially hidden by a pair of spectacles with faintly tinted glasses. As a relief for the fluid accumulation, the patient used chewing gum. Her personal goal was to overcome her troublesome eye symptoms and if possible improve the facial paralysis. Medication was recorded on a daily basis. Redness, edema and seroma were recorded on a dichotomous scale (0 = no, 1 = yes) based on the physiotherapist's assumptions and her own statements. The patient's general condition was recorded on a 5-point Likert scale. All assessments were taken on a before-after basis and at a follow-up time (4 weeks, Table. 1).

Because of the circular swelling around the eye and the above-mentioned involvement of a possible neural edema and the intraoral seroma, MLD was selected as an appropriate therapy approach.

INTERVENTION

Six MLD treatments, each lasting 45 minutes were performed once a week. Treatment consisted of the „short neck“ (i.e. stationary circles on the jugular and accessory chain), according to the Dr. Vodder method^[7], stationary circles on the chin and the ear region, treatment of the face with special eye grips and intensive drainage of the inner part of the mouth from the beginning and the inner maxilla from the third therapy on. From the fourth session on, the patient was instructed to apply a self-performed drainage of the inner mouth daily. Treatment was enhanced by special ear grips and scar treatment (stationary circles/thumb circles down to the jugular trunk and the accessory chain) based on the assumption that scars impair lymphatic flow^[8]. Therefore the lymphatic fluid was guided to the venous angle (i.e. Terminus; cp. Figure. 2) where the lymphatic vessels reach the venous system (subclavian vein and internal jugular vein).

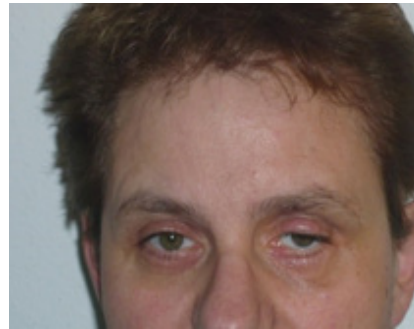


Figure 1: Patient's face

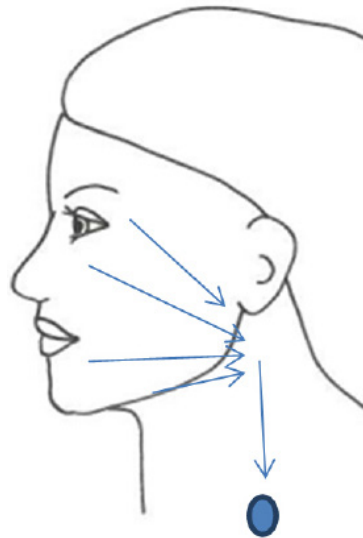


Figure 2 Lymph Flow into Terminus

Table 1 Measurements.			
	Before	After	4 weeks
Very Good			
Good		x	x
Average			
Rather Bad	x		
Bad			
	Symptoms		
Scraping	1	0	0
Seroma	1	0	0
Redness	1	0	0
Edema	1	0	0
Pain	0	0	0
Lockjaw	0	0	0
Sensitivity	0	0	0
	Medical treatment		
Oculotect	3-4x/d	1-2x/d	1-2x/d
Vidisic	6x/d	n. s.	n.s.
Oleovit	1x/d	n.s.	n.s.
	House-Brackmann Facial Nerve Grading Scale		
Grade	V	IV	IV

RESULTS

After only one treatment the edema of the eye region was removed. The patient stated a considerable relief from the intraoral seroma lasting 48 hours. After three treatments the seroma was sustainably removed and an incipient change in the motor activity was observed. Muscles innervated by the Buccal Branch, followed by the Temporal Branch, showed an improvement after another three weeks.

The final assessment (after six treatments) yielded no redness, edema, seroma, or scraping at all and a reduction in lubrication treatment. The patient considered her condition as „good“, stage IV according to HBFNGS. After four weeks follow-up treatment, the patient was in a stable condition (cp. Table. 1).

DISCUSSION

The diagnosis of grade V HBFNGS is a grave detrimental condition and can lead to social and psychological consequences. FP leads to a disability of function and impairs the quality of life^[9], especially if the patient's work life demands a high degree of public interactions, as was the case. Sinno *et al.*^[10] examined the measures patients would accept if there were possibilities of improvement. Patients would sacrifice eight years of their life and would accept a therapy with 21 % mortality risk, if complete healing were possible. For these reasons, various therapy approaches seem to be justified. In the older literature, MLD within FP is described as an indication^[11, 12] but actual evidence is scarce. A case report applying MLD for swelling after post-facial reanimation surgery of acoustic neurinoma also reported edema resolution by the sixth session, as compared to the other side of the face (measurements were within 0.5 cm difference^[13]). Various authors^[5, 14, 15] describe neural edema as a possible cause. This underlines the assumption that MLD could be an adjuvant therapeutic approach. The facial nerve proceeds from the Intraparotid Plexus below the ear lobe to ventral. The NII. (Nodices lymphatici) Retroauriculares are on the dorsal side of the ear, exactly at this patient's surgical incision. It seems possible that an iatrogenic surgery trauma led to an edema in this very section and a compression of the facial nerve, causing paralysis. Baricich *et al.*^[16] examined the effectiveness of mimic exercises and recommended them for rehabilitation of FP. These exercises did not produce an improvement in this patient. Previous neurological physiotherapies had limited success within this patient. The fact that the motor function started to improve with the onset of MLD was noticeable. A deterioration of the facial nerve blood supply plays a role in the pathophysiology of FP^[17]. An edema stretches the distance between the capillaries and the cells. This leads to a delay of diffusion, compromised cell metabolism and eventually to cell necrosis^[18]. MLD improves lymphangiomotoricity^[19] and microcirculation. The edema resolution through MLD could have influenced the trophic situation and further improved nerve function. The described fluid accumulation was classified as an intraoral seroma. Benson/Djalilian^[20] described two cases of seroma formation after retrosigmoid craniotomy, though in conjunction with the use of bone cement. In the mouth, Földi^[8] described lymphatic pathways in the gingiva superior towards the NII. Retropharyngei. These receive afferent vessels from the palate, the auditive tube and the middle ear. This is consistent with the clinical symptoms of this patient. On the surface, the M. buccinator drains to the NII. Faciales, the NII. Submandibulares and NII. Infraauriculares. A compression as above described could have occurred on the facial nerve, which could have blocked the lymphatic flow from the cheek. The Petrosus major nerve, a parasympathic branch of the facial nerve innervates the lacrimal gland. There could be a connection between the dry eye syndrome^[21] and the improvement after MLD.

LIMITATIONS

To avoid detector bias in the assessment of seroma, scraping, redness and swelling, additional assessments could have been performed by a second, independent therapist^[22]. A VAS could have been used instead

of the dichotomous mode. The question remains whether an intraoral seroma is a condition which could be analysed on a scale from 0-10. Specific questionnaires (Facial Disability Index, Facial Clinimetric Evaluation Scale) may have the advantage of a reinforced patient satisfaction and impact on the quality of life^[23]. Both instruments were tested and were shown to be valid and reliable^[24, 25]. The Visidec and Oleovit intake was not stated by the patient during anamnesis. For that reason, an assessment of the situation before and after treatment was not possible.

CONCLUSION

Edema formation could possibly play a role in the appearance and consistency of facial paralysis. Manual Lymphatic Drainage can be applied as an adjuvant therapy for facial paralysis and edema related to Schwannoma, which are not responsive to other therapies. Further research on this topic is necessary.

Abbreviations

FP: Facial Paralysis;
HBFNGS: House-Brackmann Facial Nerve Grading Scale;
MLD: Manual Lymphatic Drainage;
NII.: Nodices Lymphatici;
n.s.: not stated;
VAS: Visual Analogue Scale.

ACKNOWLEDGMENTS

The author would like to thank Dr. M.Selg and P. Orgill, B.A. for revising the manuscript critically for translation.

CONFLICT OF INTERESTS

There are no conflicts of interest with regard to the present study.

REFERENCES

- Urban PP. Erkrankungen des Hirnstamms. Klinik-Diagnostik-Therapie. Stuttgart: Schattauer Verlag 2008: 256
- Ben Ammar M, Piccirillo E, Topsakal V, Taibah A, Sanna M. Surgical results and technical refinements in translabyrinthine excision of vestibular schwannomas: the Gruppo Otologico experience. *Neurosurgery* 2012; 70(6):1481-91
- McElveen JT Jr, Belmonte RG, Fukushima T, Bullard DE. A review of facial nerve outcome in 100 consecutive cases of acoustic tumor surgery. *Laryngoscope* 2000; 110(10 Pt 1):1667-72
- Kazim SF, Shamim MS, Enam SA, Bari ME. Microsurgical excisions of vestibular schwannomas: A tumor-size-based analysis of neurological outcomes and surgical complications. *Surg Neurol Int* 2011; 2(41)
- Morton RP, Ackerman PD, Pisansky MT, Krezalek M, Leonetti JP, Raffin MJ, Anderson DE. Prognostic factors for the incidence and recovery of delayed facial nerve palsy after vestibular schwannoma resection. *J Neurosurg* 2011; 114(2):375-80
- Sargent EW, Kartush JM, Graham MD. Meatal facial nerve decompression in acoustic neuroma resection. *Am J Otol* 1995; 16(4):457-64
- Wittlinger H, Wittlinger D, Wittlinger A, Wittlinger M. Manuelle Lymphdrainage nach Dr. Vodder. Stuttgart: Georg Thieme Verlag KG 2009: 56-60.
- Földi M, Földi E, Kubik S. Lehrbuch der Lymphologie für Mediziner, Masseur und Physiotherapeuten. München: Urban & Fischer Verlag 2005: 48
- Ho AL, Scott AM, Klassen AF, Cano SJ, Pusic AL, Van Laeken N. Measuring quality of life and patient satisfaction in facial pa-

- ralysis patients: a systematic review of patient-reported outcome measures. *Plast Reconstr Surg* 2012; 130(1):91-9
10. Sinno H, Thibaudeau S, Izadpanah A, Tahiri Y, Christodoulou G, Zuker R, Lin SJ. Utility outcome scores for unilateral facial paralysis. *Ann Plast Surg* 2012; 69(4):435-8
 11. Kurz I. Einführung in die Manuelle Lymphdrainage nach Dr. Vodder. Bd. 3: Therapie II. *Heidelberg: Haug Verlag* 1986: 125
 12. Kasseroller R. Kompendium der Manuellen Lymphdrainage nach Dr. Vodder. *Heidelberg: Haug Verlag* 1996: 144
 13. Wilson CM, Ronan SL. Rehabilitation postfacial reanimation surgery after removal of acoustic neuroma: a case study. *J Neurol Phys Ther* 2010;34(1):41-9.
 14. Joseph ST, Vishwakarma R, Ramani MK, Aurora R. Cochlear implant and delayed facial palsy. *Cochlear Implants Int* 2009; 10(4):229-36
 15. Cakarar S, Can T, Cankaya B, Erdem MA, Yazici S, Ayintap E, Özden AV, Keskin C. Peripheral facial nerve paralysis after upper third molar extraction. *J Craniofac Surg* 2010; 21(6):1825-7
 16. Baricich A, Cabrio C, Paggio R, Cisari C, Aluffi P. Peripheral facial nerve palsy: how effective is rehabilitation? *Otol Neurotol* 2012; 33(7):1118-26
 17. Murakawa K, Ishimoto E, Noma K, Ishida K, Nishijima M, Izumi R. Circulatory effects of stellate ganglion block in idiopathic facial palsy. *Masui* 1994; 43(3):356-60
 18. Yates J. A Physician's Guide to Therapeutic Massage. 3rd ed. *University of Toronto Press* 2004: 30f
 19. Tan IC, Maus EA, Rasmussen JC, Marshall MV, Adams KE, Fife CE, Smith LA, Chan W, Sevick-Muraca EM. Assessment of lymphatic contractile function following manual lymphatic drainage using near-infrared fluorescence imaging. *Arch Phys Med Rehabil* 2011; 92(5):756-764
 20. Benson AG, Djalilian HR. Complications of hydroxyapatite bone cement reconstruction of retrosigmoid craniotomy: two cases. *Ear Nose Throat J* 2009; 88(11):E1-4
 21. Finsterer J. Management of peripheral facial nerve palsy. *Eur Arch Otorhinolaryngol* 2008; 265(7): 743–752
 22. Lewis SC, Warlow CP. How to spot bias and other potential problems in randomised controlled trial. *J Neurol Neurosurg Psychiatry* 2004; 75:181-187
 23. Ng JH, Ngo RY. The use of the facial clinimetric evaluation scale as a patient-based grading system in Bell's palsy. *Laryngoscope* 2013;123(5):1256-60
 24. VanSwearingen JM, Brach JS. The Facial Disability Index: reliability and validity of a disability assessment instrument for disorders of the facial neuromuscular system. *Phys Ther* 1996;76(12):1288-98
 25. Kahn JB, Gliklich RE, Boyev KP, Stewart MG, Metson RB, McKenna MJ. Validation of a patient-graded instrument for facial nerve paralysis: the FaCE scale. *Laryngoscope* 2001;111(3):387-98
- Peer reviewer:** N. Scott Litofsky, MD, Professor and Chief, Division of Neurological Surgery, University of Missouri-Columbia School of Medicine, One Hospital Drive, MC 321, Columbia, Missouri 65212 USA.