

Clinical Protocol Standardized in a Public Health System Using a Prototype for Actinic Keratosis and Field Cancerization Treatment

Ana G. Salvio, Elisangela R. de Oliveira, Dora P. Ramirez, Kate C. Blanco, Natalia M. Inada, Cristina Kurachi, Vanderlei S. Bagnato

Ana G. Salvio, Elisangela R. de Oliveira, Department of Skin, Amaral Carvalho Foundation, Brazil., Jahu, São Paulo, Brazil

Dora P. Ramirez, Federal University of São Carlos, PPG-Biotec, São Carlos, São Paulo, Brazil

Kate C. Blanco, Natalia M. Inada, Cristina Kurachi, Vanderlei S. Bagnato, University of São Paulo, São Carlos Institute of Physics, São Carlos, São Paulo, Brazil

Correspondence to: Kate Cristina Blanco, CEPOF, Av. Trabalhador São-carlense, 400, São Carlos, São Paulo, Brazil.

Email: blancokate@gmail.com

Telephone: +551633739810

Received: November 9, 2015 Revised: December 27, 2015

Accepted: December 30, 2015

Published online: April 18, 2016

© 2016 The Authors. Published by ACT Publishing Group Ltd.

Key words: Photodynamic therapy; Actinic keratosis; Methyl aminolevulinate; Field cancerization

Salvio AG, de Oliveira ER, Ramirez DP, Blanco KC, Inada NM, Kurachi C, Bagnato VS. Clinical Protocol Standardized in a Public Health System Using a Prototype for Actinic Keratosis and Field Cancerization Treatment. *Journal of Tumor* 2016; 4(5): 407-410 Available from: URL: <http://www.ghrnet.org/index.php/jt/article/view/1465>

ABSTRACT

AIM: Actinic keratoses (AKs) are pre-malignant skin lesions. The sun exposure is the main cause of AKs. The highest incidence of AK occurs in the arms and back of hands of photodamaged skin. New approaches to Photodynamic Therapy (PDT) includes new advances for the simultaneous treatment of these large areas. The PDT is an option of effective treatment and not invasive of AK with excellent aesthetic results.

METHODS: A new development in this regard is the use a new equipment of Brazilian technology developed in Physics Institute of São Carlos (University of São Paulo, Brazil) for the treatment of AK. The PDT of AKs was performed by application of the cream (3 hours) containing 15% Methyl-aminolevulinic acid (MAL), followed by 20 minutes of photoactivation using a source of red light at 630 nm and 36J/cm².

RESULTS: The complete response was of 70% in 80 patients with the presence of 24 to 205 lesions with a mean of 63.5. Conclusion: the PDT using a new prototype named Kerato PDT may represent a promising therapeutic alternative for AK of arms.

INTRODUCTION

The cumulative sun exposure is responsible for the development of skin cancer and its precursor lesions, such as AKs^[1,2]. AK is an sun-induced precancerous lesion characterized by yellowish or brownish scaly, thin, adherent and dry tissue, and may present underlying erythema^[3-5]. It affects fair-skinned individuals and especially in the body regions that are frequently exposed to the sun, such as hands, forearms, face, ears, neck and scalp^[6]. The AKs is precursor to squamous cell skin cancer in 10-20% in 10 years of the initial of lesion^[7]. The main mechanisms in the development of AK are inflammation, oxidative stress, immunosuppression, impaired apoptosis, mutagenesis, cell growth dis-regulation and proliferation, and tissue remodeling.

The AK may be characterized as an type of generalized lesions that usually affect large areas multiple. In some cases, the chemical processes for treatment may be aggressive for the patient compromising the welfare them^[8,9].

The type of treatment used in AK depends on the number and size of the lesions, and especially the extent of the affected skin^[8,10]. Among the several treatment options, we can highlight cryotherapy with liquid nitrogen, which is considered an effective, low-cost treatment, with a cure rate of up to 98%^[11,12]. This treatment option

is made as an individual approach for each lesion, which makes the process slow. Additionally, there are other drawbacks: only visible lesions may be treated (since nitrogen application is visually driven); there is no treatment of the incipient lesion, and healthy tissue adjacent to the lesion can be destroyed in the process^[13]. Chemicals such as topical 5-fluorouracil, imiquimod and chemical peeling are also used^[14,15]. Such methods cause a local inflammatory process, which may cause discomfort to the patient by promoting itching, burning sensation and skin ulceration^[16,17]. This symptoms may limit the technique use and reduce patients' adherence to treatment.

Topical photodynamic therapy (PDT) is an option in the treatment of pemalignant lesions as disseminated AKs. This therapy is based on three basic elements: the presence of a photosensitizer, a drug that absorbs light to trigger a series of chemical reactions; light at an appropriate wavelength, and the molecular oxygen present in the tissue to be treated, which reacts with the activated drug resulting in reactive oxygen species that are capable of inducing the cellular tissue necrosis, with subsequent re-epithelialization^[18]. Our research group has a long experience in clinical trials using PDT for the treatment of non-melanoma skin cancer^[19], onychomycosis^[20], condyloma and cervical intraepithelial neoplasia^[21]. PDT allows treatment of a large extension of skin, achieving both subclinical and clinical lesion, less aggressively and more efficiently, with good aesthetic outcome. Nevertheless, to the present day, PDT efficacy for large lesions is uncertain, because most of the available light sources do not allow a proper and uniform illumination of large areas. Aiming to expand and improve the treatment of high grades AKs, a device to treat simultaneously both upper limbs was developed by the University of São Paulo, and the medication (a cream containing 15% MAL) produced by a national company (PDTPharma, LTDA) with relative low cost. In this study, two treatment protocols have been proposed, using 15% ALA cream and different incubation times, in order to find the ideal time of incubation for the drug concerning the treatment of disseminated AK with the developed device.

METHODS

Study population

A total of a hundred and twenty patients participated in this study. After approval of the Ethics Committee from the Amaral Carvalho Foundation (000042/2012), the written informed consent was obtained from each study participant. Male and female patients, over 18 years, with a clinical diagnosis of widespread AK on the hands and forearm were included in this protocol. The study was conducted in the Department of skin to hospital Amaral Carvalho, Jahu, SP, Brazil. The exclusion criteria were hypersensitivity to metil-aminolevulinic acid or other component of the formula, diagnosis of porphyria, pregnancy and breastfeeding. All patients provided written informed consent, and the study was approved by the regional committee for medical research ethics.

Equipment

A device to treat simultaneously both upper limbs was developed by the Optics Group (Laboratory of Biophotonics and Technical Support Laboratory-LAT) at the São Carlos Institute of Physics, University of São Paulo, Brasil (Patent PI: 100413-0). This device allows both upper limbs to receive light emitted by diodes with the correct dose of energy (Figure 1). It was designed to allow the most uniform illumination of the fore arms and hands, providing the treatment of field cancerization.




Figure 1 Prototype Kerato PDT[®] using LEDs emitting at 630 ± 10 nm and an irradiance of 15 mW/cm^2 . The anatomical arrangement of their LED plates enables uniform illumination of the upper limbs simultaneously, with a constant circulation of the air through two fans.

Photosensitizer

The pro-drug used was the commercial MAL produced by the national company PDTPharma (Cravinhos, São Paulo - Brazil) at 15% (w/w) in an oil in water emulsion (o/w).

Treatment procedure

All macroscopy AK lesions in the forearm were counted and photographed. All regions were clean with a solution of 0,5% clorexidin and superficial debridement was made to remove scales and crusts to facilitate the penetration of the cream. Immediately stop bleeding, a amount of MAL cream at the concentrações of 150mg/g (PDTPharma, Cravinhos, SP, Brazil) was applied throught the hands and forearms, with 2 mm thickness. Subsequently, this area was occluded with PVC film and aluminum foil, and with a bandage for 3 hours. After, the dressing was removed, the cream was washed off with saline solution. This area was immediately illuminated with a red ($630 \pm 10 \text{ nm}$) LED light source with a delivered energy of 36 J/cm^2 , for 40 minutes.

Evaluation of response

The clinical response of the skin were analysed by the dermatologist visually and by the comparison of the photographs of the skin lesions before and 30 days after the PDT, under standardised conditions and using a digital camera (Sony HX1).

Statistical analysis

Data were statistically analyzed using the Mann-Whitney test when the P values were less than 0.10.

RESULTS

The prototype used Kerato PDT[®] in this study was developed by the Laboratory Support Technician from the Optics Group of the São Carlos Institute of Physics (Patente PI: 1000413-0) with the advantage of widespread actinic keratoses and cancerization field treatment on the upper limbs. This apparatus is basically constituted by plates LED (light emitting diode) emitting a band centered on the wavelength of 630 nm, at a fluence rate of 36 J/cm^2 after a total illumination time of 40 minutes at an irradiance 15 mW/cm^2 . The anatomical arrangement of their plates LED enables uniform illumination of the upper limbs simultaneously as shown at figure 1.

According to gender, fifty nine patients were male (49%) and sixty one patients were female (51%). Before the PDT, the number of AK lesions by patient ranged from 18 to 230 (media of 141,47 lesions per patient (Fiugre 2). The sum of all AK of the 120

patients were 8,559, after the treatment. And 30 days after only a PDT application, this total decreased to 2,787, which represents a regression of almost 70% of the total of AK (Figure 2A). These numbers showed as the medium of lesions/patients were: 141.47 lesions per patient before the treatment (Figure 2B) and 46 lesions/patients 30 days after PDT (Figure 2B). In figure 3 we are presenting a representative clinical evaluation of the number of AKs before (A and C) and after PDT (B and D). According to medical visual analysis, it was observed a reduction of 70% in the number of AK 30 days after the procedure. The values were statistically analyzed by Mann-Whitney and showed statistical significance ($p < 0.001$).

DISCUSSION

AK lesions are typically found in patients with extensive sun exposure. Large quantities of lesions are observed in patients with sun-exposed areas, which also complicates the treatment. Due to the potential of AK to form a squamous cell carcinoma, the realization of a comprehensive treatment highly efficient is important. We observed in this study a reduction of 70% of AKs by clinical evaluation performed after 30 days of treatment.

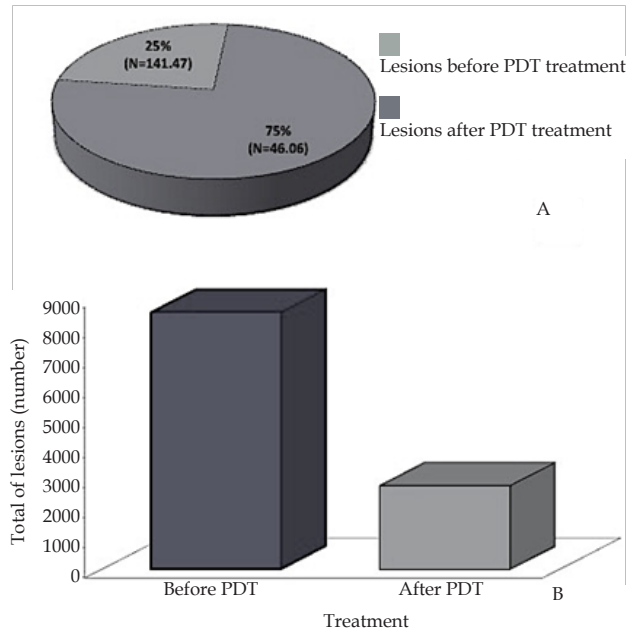


Figure 2 Sum of all AK of the 120 patients were 8,559 before PDT and 2,787 after PDT (A). Medium of the 141.47 lesions per patient before the treatment and 46 lesions per patient after 30 days of treatment (B).

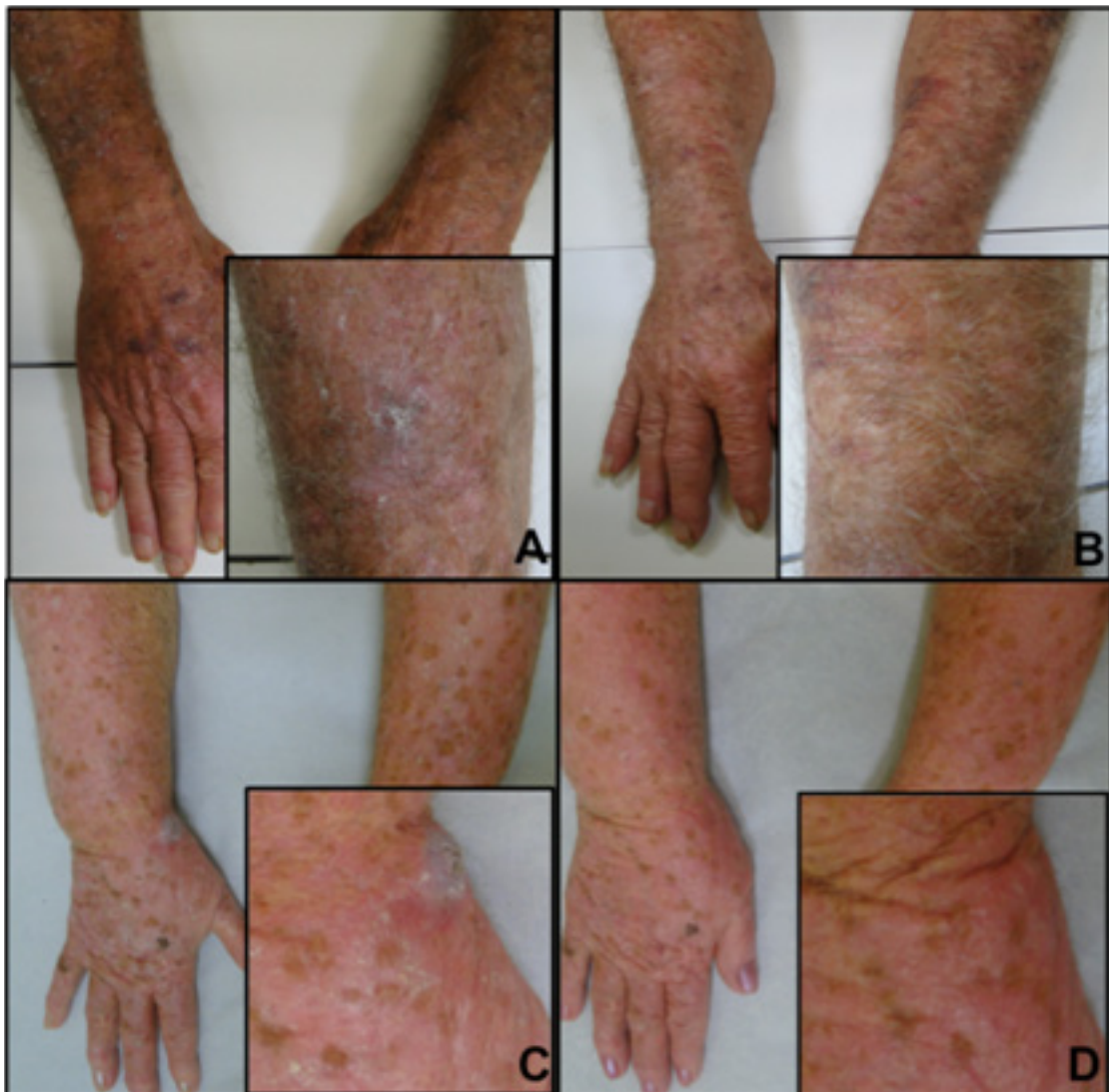


Figure 3 Clinical presentation of multiple medium-high grade AKs on the upper limbs in the context of field cancerisation. Zoom view of the lesions all over the limbs, before PDT (B and C). The same local of the zoom view 30 days after PDT (A and D).

When the AKs are present with a small number of lesions, there are multiple treatment options. The problem is when the AKs are widespread. In this case, the treatment is more difficult. We proposed the treatment of widespread AKs with a modern device to perform the uniform illumination of the upper limbs. Using this technique we provide treatment for field cancerization and also AKs. Using this device capable to illuminate a large extension of both upper limbs, we are standardizing a clinical protocol for the treatment of field cancerization and AK of all grades. Szeimies *et al* 2012 observed in patients with photodamaged skin and multiple AK, that after MAL-PDT, the AK clearance rate was 89,5% and histopathological improvement with a significant increase in collagen deposition in treating the skin. Other type of procedure indicated nowadays for AK grades 1 and 2 is the daylight-mediated PDT that can be administered throughout the year, although it is not indicated at temperatures below 10°C or at excessively high temperatures^[22], as here in Brazil.

As Brazil is a country under development, we have always challenges in our public health system due to the lack of the financial investment in health promotion. For our reality, the large use of PDT with the real costs for the government is impossible and the solution was the development of this prototype, used associated with the medication produced in Brazil. The reduction by 70% of AK after just one PDT session motivates us to standardize this protocol in the public health system, once our country presents a high incidence of UV and AKs are the fourth most common cause of dermatologic consultation in Brazil^[23].

In conclusion, topical PDT using this anatomic prototype presents many benefits as a therapeutic alternative for widespread AK and field cancerization of arms, since larger areas can be treated with a only ambulatory PDT session with excellent outcome. The prevention is the best way to avoid these premalignant lesions, with relative low cost since both the device and the medication are produced in Brazil. The studies are ongoing evaluating a long term follow up.

ACKNOWLEDGEMENTS

The authors acknowledge the financial support of The Brazilian Development Bank (BNDES, grant 09.2.1458.1) and Center of Optics and Photonics (CEPOF/FAPESP, grant 13/07276-1).

CONFLICT OF INTERESTS

There are no conflicts of interest with regard to the present study.

REFERENCES

- Salasche SJ. Epidemiology of Actinic Keratoses and Squamous Cell Carcinoma. *J. Am. Acad. Dermatol.* 2000; **42**: 4-7.
- Ulrich M, Maltusch A, Rówert-Huber J, González S, Sterry W, Stockfleth E, Astner S. Actinic Keratoses: Non-Invasive Diagnosis for Field Cancerisation. *Br. J. Dermatol.* 2007; **156**: 13-17.
- Roewert-Huber J, Stockfleth E, Kerl H. Pathology and Pathobiology of Actinic (solar) Keratosis - An Update. *Br. J. Dermatol.* 2007; **157**: 18-20.
- Ko CJ. Actinic Keratosis: Facts and Controversies. *Clin. Dermatol.* 2010; **28**: 249-253.
- Ceilley RI, Jorizzo JL. Current Issues in the Management of Actinic Keratosis. *J. Am. Acad. Dermatol.* 2013; **68**: S28-S38.
- Goldberg LH, Mamelak AJ. Review Of actinic Keratosis. Part I: Etiology, Epidemiology and Clinical Presentation. *J. Drugs Dermatol* 2010; **9**: 1125-1132.
- Fuchs A, Marmur E. The Kinetics of Skin Cancer: Progression of Actinic Keratosis to Squamous Cell Carcinoma. *Dermatol. Surg.* 2007; **33**: 1099-1101.
- Dinehart SM. The Treatment of Actinic Keratoses. *J. Am. Acad. Dermatol.* 2000; **42**: 25-28.
- Hwang S, Schwartz RA. Keratosis Pilaris: A Common Follicular Hyperkeratosis. *Cutis* 2008; **82**: 177-180.
- Holmes C, Foley P, Freeman M, Chong AH. Solar Keratosis: Epidemiology, Pathogenesis, Presentation and Treatment. *Australasian Journal of Dermatology* 2007; **48**: 67-76.
- Lubritz RR, Smolewski SA. Cryosurgery Cure Rate of Actinic Keratoses. *J. Am. Acad. Dermatol.* 1982; **7**: 631-632.
- De Berker D, McGregor JM, Hughes BR. Guidelines for the Management of Actinic Keratoses. *Br. J. Dermatol.* 2007; **156**: 222-230.
- Chamberlain AJ, Kurwa HA. Photodynamic Therapy: Is It a Valuable Treatment Option for Actinic Keratoses? *American Journal of Clinical Dermatology.* 2003; **4**: 149-155.
- Tutrone WD, Saini R, Caglar S, Weinberg JM, Crespo I. 5-Fluorouracil and Imiquimod. *J. Topical Therapy for Actinic Keratoses* 2003; **71**: 365-370+372.
- Swanson N, Abramovits W, Berman B, Kulp J, Rigel DS, Levy S. Imiquimod 2.5% and 3.75% for the Treatment of Actinic Keratoses: Results of Two Placebo-Controlled Studies of Daily Application to the Face and Balding Scalp for Two 2-Week Cycles. *J. Am. Acad. Dermatol.* 2010; **62**: 582-590.
- Schön MP, Schön M. Imiquimod: Mode of Action. *Br. J. Dermatol.* 2007; **157**: 8-13.
- Love WE, Bernhard JD, Bordeaux JS. Topical Imiquimod or Fluorouracil Therapy for Basal and Squamous Cell Carcinoma: A Systematic Review. *Arch. Dermatol.* 2009; **145**: 1431-1438.
- Braathen LR, Szeimies RM, Basset-Seguín N, Bissonnette R, Foley P, Pariser D, Roelandts R, Wennberg AM, Morton, C. a. Guidelines on the Use of Photodynamic Therapy for Nonmelanoma Skin Cancer: An International Consensus. International Society for Photodynamic Therapy in Dermatology, 2005. *J. Am. Acad. Dermatol.* 2007; **56**(1): 125-143.
- Ramirez DP, Kurachi C, Inada NM, Moriyama LT, Salvio AG, Vollet Filho JD, Pires L, Buzzá HH, de Andrade CT, Greco C, Bagnato VS. Experience and BCC Subtypes as Determinants of MAL-PDT Response: Preliminary Results of a National Brazilian Project. *Photodiagnosis Photodyn. Ther.* 2014; **11**: 22-26.
- Silva AP da, Kurachi C, Bagnato VS, Inada NM. Fast Elimination of Onychomycosis by Hematoporphyrin Derivative-Photodynamic Therapy. *Photodiagnosis Photodyn. Ther.* 2013; **10**: 328-330.
- Inada NM, da Costa MM, Guimarães OCC, da Silva Ribeiro E, Kurachi C, Quintana SM, Lombardi W, Bagnato VS. Photodiagnosis and Treatment of Condyloma Acuminatum Using 5-Aminolevulinic Acid and Homemade Devices. *Photodiagnosis Photodyn. Ther.* 2012; **9**: 60-68.
- Gilaberte Y, Aguilar M, Almagro M, Correia O, Guillén C, Harto A, Pérez-García B, Pérez-Pérez L, Redondo P, Sánchez-Carpintero I, Serra-Guillén C, Valladares LM. Spanish-Portuguese Consensus Statement on the Use of Daylight Photodynamic Therapy With Methyl Aminolevulinic in the Treatment of Actinic Keratosis. *Actas Dermosifiliogr.* 2015; **106**, 8: 623-631.
- Schmitt JV, Miot HA. Actinic Keratosis: A Clinical and Epidemiological Revision. *Anais Brasileiros De Dermatologia.* 2012; **87**: 425-434.

Peer reviewers: PinKang Wei, Department of Traditional Chinese Medicine, Changzheng hospital, Second Military University, Shanghai, China; Guzin Gonullu Demirag, Department of Medical Oncology, Ondokuz mayis University, Medical School Atakum, Samsun, Turkey; Margarita Angelova Kamenova, UMBALSM 'N.I. Pirogov', Department of general and clinical pathology, bul. Totleben 21, 1606, Bulgaria.