

Gastric Adenocarcinoma Presents as Gastrocolic Fistula and Perforation

Shahar Grunner, Yael Klionsky, Hayim Gilshtein

Shahar Grunner, Yael Klionsky, Trauma and Acute Care Surgery section, General Surgery department, Rambam Health Care Campus, Haifa, Israel

Hayim Gilshtein, Colorectal Surgery section, General Surgery department, Rambam Health Care Campus, Haifa, Israel

Correspondence to: Shahar Grunner, Trauma and Acute Care Surgery section, General Surgery department, Rambam Health Care Campus, Haifa, Israel.

Email: s_grunner@rambam.health.gov.il

Telephone: +97247772316

Received: November 16, 2015 Revised: December 18, 2015

Accepted: December 22, 2015

Published online: February 2, 2016

ABSTRACT

A 65-year-old man one year post neoadjuvant treatment for rectal adenocarcinoma in the lower rectum presented with severe abdominal pain and a two week history of watery diarrhea. An abdominal CT showed free air under the diaphragm with a suspected gastrocolic fistula. In the operating theatre, an exploratory laparotomy revealed cloudy fluid with pus and perforation of the transverse colon with a large mass invading the greater curvature of the stomach from the antrum into the transverse colon. A distal gastrectomy, extended right hemicolectomy, gastrojejunostomy, and end ileostomy were performed to excise the mass and the perforated area.

© 2016 ACT. All rights reserved.

Key words: Gastric adenocarcinoma; Gastrocolic Fistula; Perforation

Grunner S, Klionsky Y, Gilshtein H. Gastric Adenocarcinoma Presents as Gastrocolic Fistula and Perforation. *Journal of Tumor* 2016; 4(1): 367-368 Available from: URL: <http://www.ghrnet.org/index.php/JT/article/view/1590>

INTRODUCTION

Gastrocolic fistula formation is a rare complication of gastric adenocarcinoma^[1]. It is most commonly seen in benign conditions such as peptic ulcer disease, diverticulitis, and Crohn's disease. The combination of a gastrocolic fistula with a colon perforation is rare. Clinical signs of a gastrocolic fistula include feculent vomiting, diarrhea, and weight loss.

We present a patient diagnosed with perforation of hollow viscus. Only during the operation did it become apparent that the adenocarcinoma of the antrum invaded the transverse colon, causing perforation of the adjacent transverse colon^[2].

CASE REPORT

A 65-year-old man presented with a two week history of watery diarrhea, shortness of breath, and nausea without vomiting. The patient had a history of uncomplicated diabetes mellitus type II, COPD, and emphysema relating to 90-pack-per-year smoking history. In 2013 the patient was diagnosed with a rectal adenocarcinoma cancer in situ 5 cm from the anus staged by TRUS at T3N2. He was treated with 25 courses of chemoradiation therapy without excision of the tumor due to poor respiratory status attributed to his severe COPD.

Physical exam revealed cachexia with diffuse abdominal tenderness. Labs were significant for lactate acidosis (5 mmol/L), negative for leukocytosis, and chemistry remained within normal limits. Chest X-Ray did not reveal free air under the diaphragm. An abdominal CT was performed showing free abdominal air and intraperitoneal fluid. Contents of the nasogastric tube yielded 500 ml of fecal content.

In the operating theatre, a laparoscopic procedure was abandoned for a laparotomy. Opening the abdomen revealed cloudy fluid with pus and a perforation in the transverse colon. A large mass was found invading the greater curvature of the antrum, creating a fistula into the transverse colon. A distal gastrectomy, extended right

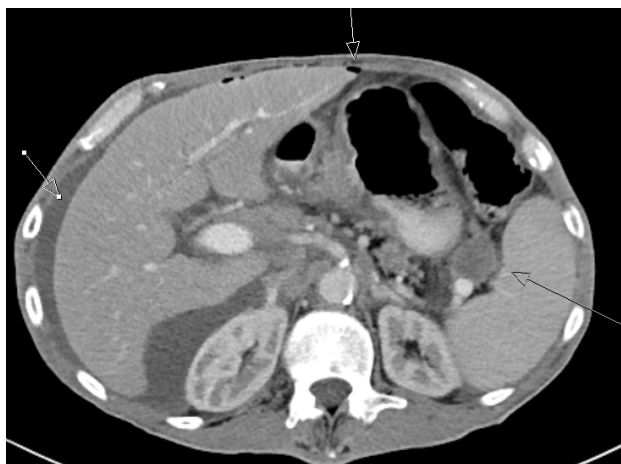

Figure 1 Arrows clockwise from left pointing at free fluid, air bubbles and enlarged lymph nodes.

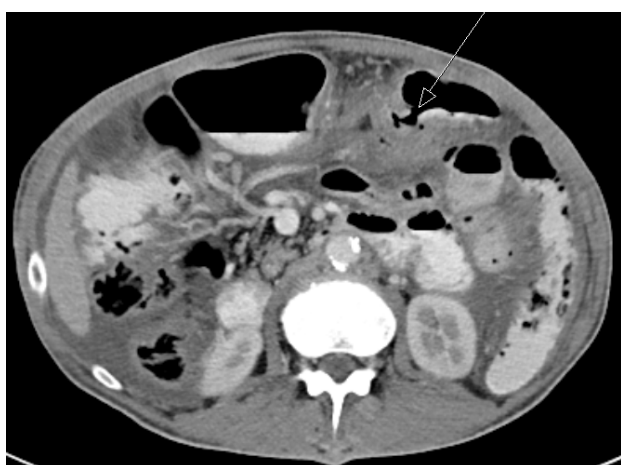


Figure 2 Arrow pointing to suspected gastrocolic fistula.

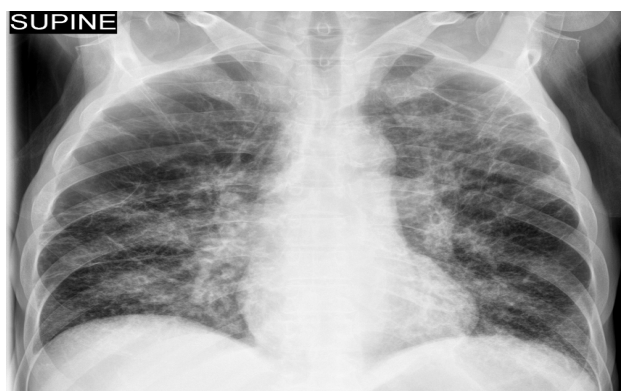

Figure 3 Chest X-Ray showing severe COPD and no free air under the diaphragm.

hemicolectomy, gastrojejunostomy, and ileostomy were performed to excise the mass and the fistula^[3] The remaining colon was closed with a stapler. We performed an extended right colectomy without anastomosis because we did not want to do another anastomosis in the fecal peritonitis environment; moreover, at the time of the operation his rectal adenocarcinoma status was not clear. Negative margins were taken. The pathological report was significant for primary gastric adenocarcinoma without lymph node metastasis.

The first post-op complication involved respiratory difficulties related to COPD. Treatment with steroids resulted in a significant

improvement. The patient went into shock on POD 1. This was initially thought to be of an infectious origin, but it did not respond to antibiotic treatment. An echocardiography noted severely reduced-global left ventricle dysfunction, an ECG noted SVT, and labs showed increased troponin. The patient was discharged on POD 10, eating and drinking with normal bowel habits. The patient was scheduled to follow up with adjuvant chemotherapy for gastric adenocarcinoma. Later on, PET-CT and TRUS found no residual disease, gastric or rectal carcinoma.

DISCUSSION

Since the patient was only treated with neoadjuvant chemoradiotherapy for rectal cancer, the main differential diagnosis during the operation was perforation of the colon secondary to rectal obstruction of primary rectal carcinoma or complications due to its metastasis. Benign etiologies, including perforation due to a duodenal ulcer were considered; however, it was decided management needed to begin with a diagnostic laparoscopy. The operation revealed a mass in the antrum of the stomach that penetrated into the transverse colon and a perforation of the transverse colon. There were no findings in the pelvis, so there was no connection of his current status to his known rectal cancer. During surgery, the focus was on palliative treatment resulting in a distal gastrectomy, right extended colectomy, and end ileostomy. Pathology reports documented a well differentiated gastric adenocarcinoma with T4N0 (16 lymph nodes were negative for metastasis). Ultimately, the palliative treatment was actually curative surgery.

CONCLUSIONS

Complications in oncological patients can be attributed to a known primary malignancy. This case highlights that fact that any acute deterioration should also include the possibility of a secondary primary tumor. The signs of acute abdominal pain combined with diarrhea should raise the suspicion of a GI fistula in the stomach or small bowel to the colon.

CONFLICT OF INTERESTS

The authors declare no conflicts of interest in this work.

REFERENCES

1. Gastrocolic fistula: a rare complication of gastric carcinoma. Lee LS, Foo CS, Chen CM, Poh CC. *Singapore Med J* 2009; 50(8): e274.
2. A case of combined gastrojejunal and gastrocolic fistula secondary to gastric cancer. Sang-Wook Choi, Jin-Mo Yang, Sung-Soo Kim, Sung-Ho Kang, Hee-Jeong Ro. *Journal of Korean Medical Science* Vol. 11, No.5, 437-439 Oct. 1996.
3. Successful palliation of a gastrocolic fistula secondary to gastric cancer by insertion of a covered colonic stent. Chul-Hyun Lim, Sang Woo Kim, Jin Soo Kim, Yu Kyung Cho, Jae Myung Park, In Seok Lee, Myung-Gyu Choi, In-Sik Chung. *Gastrointestinal endoscopy* Volume 73, No. 6 2011 1314-6.

Peer reviewers: Chen Junqiang, Professor, Department of Gastrointestinal Surgery, the First Affiliated Hospital of Guangxi Medical University, Nanning, China; Francesco Giovinazzo MD, PhD, Department of Surgery, Aberdeen Royal Infirmary, Foresterhill Road, Aberdeen, the United Kingdom.