

A Rare Case of Primitive Neuroectodermal Tumour (Pnet) of Kidney with Review of Literature

Narendra Kumar, Deepak Das, Vijai Simha, Vani Bharani, Uttam Kumar Mete

Narendra Kumar, Additional Professor, Department of radiotherapy Postgraduate; Department of Medical Education and Research (PGIMER) Chandigarh, Sector 12, 160012, Chandigarh, India

Deepak Das, Department of radiotherapy PGIMER Chandigarh, Sector 12, 160012, Chandigarh, India

Vijai Simha, Senior Registrar, Department of radiotherapy, PGIMER Chandigarh, Sector 12, 160012, Chandigarh, India

Vani Bharani, Senior Registrar, Department of Pathology, PGIMER Chandigarh, Sector 12, 160012 Chandigarh, India

Uttam Kumar Mete, Professor, Department of Urology, PGIMER Chandigarh, Sector 12, 160012, Chandigarh, India

Correspondence to: Narendra Kumar, Additional Professor, Department of radiotherapy Postgraduate Department of Medical Education and Research (PGIMER) Chandigarh, Sector 12, 160012, Chandigarh, India.

Email: dmnarendra74@gmail.com

Telephone: +91-172-2756280

Received: March 8, 2016

Revised: April 28, 2016

Accepted: May 3, 2016

Published online: June 29, 2016

ABSTRACT

We report a case of primitive neuroectodermal tumour of the kidney in a middle aged male who presented as a large left sided renal mass similar to renal cell carcinoma. A cytoreductive nephrectomy was done which showed primitive neuroectodermal tumour in the left kidney. A Positron Emission Tomography CT scan was done which showed metastasis in the lung and para-aortic lymph nodes. We describe the natural history, clinical and pathological features and management strategy of this rare variety of tumour.

Key words: Primitive Neuroectodermal Tumour; PNET; Cytoreductive Nephrectomy; Ewings sarcoma family of tumours

Kumar N, Das D, Simha V, Bharani V, Mete UK. A Rare Case of Primitive Neuroectodermal Tumour (Pnet) of Kidney with Review of Literature. *Journal of Tumor* 2015; 4(3): 445-447 Available from: URL: <http://www.ghrnet.org/index.php/jt/article/view/1634>

INTRODUCTION

Primitive neuroectodermal tumour (PNET) is presumed to be of neural crest origin, mostly presenting as bone or soft tissue masses. It usually occurs in children and young adults. PNET occurs rarely as primary renal neoplasm and exhibits highly aggressive biological behaviour. We report a case of a 54 year old male who presented with mass in the left side of abdomen. On computerised tomography (CT), he was found to have a large left renal mass. He underwent cytoreductive nephrectomy where the pathology report showed PNET of the kidney. Positron emission tomography (PET) CT done was suggestive of malignant left renal mass with metastasis to right lung and paraaortic lymph nodes

CASE REPORT

A 54 year old male came to the radiotherapy OPD August 2015 with the complaint of swelling in left side of abdomen for 3 months which was gradually progressive in size. He had no other associated symptoms. On per abdominal examination, he was found to have around 10×10 cm mass occupying most of left side of the abdomen which was firm, fixed and nontender.

A CT of the abdomen demonstrated a heterogenous mass lesion measuring 12 × 10.5 × 18.4 cm with enhancing solid component and non enhancing cystic component arising from left kidney involving mid and lower pole and part of upper pole. There was loss of fat plane between mass and left psoas muscle. Left renal vein was normal. Right kidney showed few cysts largest of size 3.8 × 3.3 cm. There was few small lymph nodes seen in paraaortic region and along renal vessels. There was no free fluid in peritoneal cavity and bilateral lung fields were normal.

PET-CT demonstrated intense 2-[18F]flouro-2-deoxy-glucose (FDG) uptake (standardised uptake value[SUV] maximum 11.8)

in the large heterogeneously enhancing soft tissue mass lesion measuring 13.5 × 11.5 × 20.6 cm involving the left kidney. The fat planes with the left psoas muscle were lost and the lesion was seen to infiltrate into the muscle. Intense FDG uptake (SUV maximum 7.5) was noted in two enlarged pleural based nodular lesions in upper lobe and middle lobe of right lung measuring 2 × 1.4 cm. Intense FDG uptake (SUV maximum 8.5) was noted in right lower paratracheal, AP window, subcarinal and bilateral hilar lymph nodes. Mild FDG uptake was noted in a few enlarged paraaortic and aortocaval lymph nodes. These features were suggested of primary left renal lesion with metastatic right lung lesions and paraaortic lymph nodes.

Then the patient underwent cytoreductive nephrectomy. Grossly the mass had a size of 19 × 13 × 12 cm. Capsule was intact with no areas of haemorrhage or necrosis. The cut surface showed a tumour mass, almost occupying whole of the renal parenchyma measuring 17 × 11 × 9 cm. It was tan-brown to tan-red in colour with large areas of necrosis and haemorrhage. Renal sinus could not be delineated.

Microscopically tumour arranged in nests and forming sheets. The tumour cells were round to oval with fine nuclear chromatin, occasional nucleoli and scanty to moderate cytoplasm. Frequent mitosis and large areas of necrosis were seen. On immunohistochemistry, tumour cells show strong positivity for vimentin, membranous positivity for cluster of differentiation (CD) 99 and cytoplasmic positivity for neuron specific enolase (NSE). Immunostain for epithelial membrane antigen (EMA) and CD34 was negative. Perinephric fat was involved by tumour. Ureteric and vascular resection limit were free of tumour.

The patient was subsequently begun on systemic chemotherapy with 6 cycles of chemotherapy with cisplatin (30 mg/m²) and etoposide (100 mg/m²). Patient was reassessed with CT scan at the end of three cycles of chemotherapy on which showed partial response. The patient is presently asymptomatic and is planned for further chemotherapy and palliative radiotherapy.

DISCUSSION

Primitive neuroectodermal tumor is a malignant neoplasm of neural crest origin. It was first described by Arthur Pourdy Stout in 1918, where it occurred in the ulnar nerve. It belongs to the Ewing sarcoma family of tumours and is one of the small blue round cell tumours. It is a very rare tumour representing about 1% of all sarcomas. It can occur in the trunk, extremities, brain, spinal cord and sympathetic nervous system as well as peripheral tissues, paraspinous region, and less commonly, genitourinary tract^[1]. Renal PNET was first described by Seemayer *et al.*^[2,3].

Renal PNET usually occurs in children and young adults. The peak age at diagnosis of PNET in general is 10-15 years of age. Average age at diagnosis of renal PNET as seen in the literature has been 27.8 years, ranging from 4 to 62 years. In our patient the age at presentation was 54 years which is not the usual age at which PNET of the kidney can be suspected; rather it is closer to the median age of presentation of renal cell carcinoma which is 64 yrs. There is a slight male predominance seen in the literature for PNET in general as well as renal PNET. The tumours tend to be very large and maximum diameter of renal PNET is more than 10 cm (average 12.4 cm) with size ranging from 4 to 24 cm^[4,5]. This difference in size may be a differentiating feature from renal carcinoma as the tumours of renal cell carcinoma can be smaller than 3cm and can be multi-focal in the setting of Von Hippel Lindau syndrome. Multifocality is a feature that has never been described in PNET of the kidney.

The presenting symptoms of renal PNET are nonspecific and

similar to other renal tumours^[4]. Pain, palpable mass and hematuria are the most common symptoms^[5]. Imaging of renal PNET often reveals large mass with large areas of haemorrhage and necrosis partially or completely replacing kidney. The mass often has multiple septum like structures. The haemorrhage is diffuse or central in case of PNET but it is central in case of renal cell carcinoma^[6]. In several case series, tumour extension has been shown to cause thrombosis of the renal veins as well as the inferior vena cava upto the right atrium^[7].

To summarize, there is no single feature except a younger age at presentation which can lead to a preoperative suspicion of a PNET in a patient presenting as a renal mass (even this was not present in the index patient). The diagnosis of renal PNET is usually made postoperatively, based on morphology, immunohistochemical and cytogenetic analyses. Grossly, renal PNET looks greyish white with areas of necrosis and haemorrhage due to rapid tumour growth. Viable tumour is often found preserved around the blood vessels. Microscopically, the picture is that of a primitive, undifferentiated neoplasm. On hematoxylin and eosin-stained sections, there are monotonous sheets of small round blue cells with hyperchromatic nuclei and scant cytoplasm. The histological hallmark is formation of Homer-Wright rosettes or perivascular pseudorosettes involving small round hyperchromatic cells. Immunohistochemically the tumour cells are strongly positive for CD99 and Friend Leukemia Virus Integration (FLI)-1. Virtually all cases express one of several different reciprocal translocations, most of which involve breakpoints that are clustered within a single gene locus designated the EWSR1 gene on chromosome 22q12. In 85 to 90% cases of Ewing family tumours, a recurrent chromosomal translocation, t(11; 22)(q24; q12), fuses the 5' portion of the EWSR1 gene on chromosome 22 to the 3' portion of the FLI1 (friend leukemia integration locus-1) gene on chromosome 11 which can be detected by fluorescence in situ hybridization. Using a large panel of immunohistochemical markers is often essential [cytokeratin, EMA, WT1 (Wilms tumour 1), synaptophysin, muscle specific actin, desmin, myogenin, leukocyte common antigen (LCA) and CD45] to exclude other round cell tumours because of their important similarities^[1-6,8-14]. Differential diagnosis of renal PNET includes Wilms tumour, neuroblastoma, clear cell carcinoma, lymphoma, rhabdomyosarcoma, small cell variant of osteosarcoma and small cell anaplastic neuroendocrine carcinoma.

Renal PNET is a highly aggressive tumour with high metastatic potential and almost 50% of patients present with distant metastases, most commonly to regional lymph nodes, lungs, liver and bones^[1-3,11,12]. Prognostic factors are tumour stage, grade, patient's age, extent of surgery, surgical margin status and treatment beginning time^[2,11]. The 5-year disease-free survival rate is 45% to 55% and median relapse free survival is 2 years in patients with metastatic disease^[1,9].

There are no standard guidelines for the treatment of renal PNET^[11]. The primary treatment is surgery followed by chemotherapy^[12]. Cisplatin based multi-agent chemotherapy can be considered the standard of care. PNET has shown sensitivity to chemotherapy regimens containing drugs- vincristine, adriamycin, ifosfamide, etoposide, cisplatin^[11]. The index patient had partial response to cisplatin etoposide doublet chemotherapy. Additional multi-agent chemotherapy has not been shown to be effective in the setting of metastatic Ewing family of tumours.

CONFLICT OF INTERESTS

There are no conflicts of interest with regard to the present study.

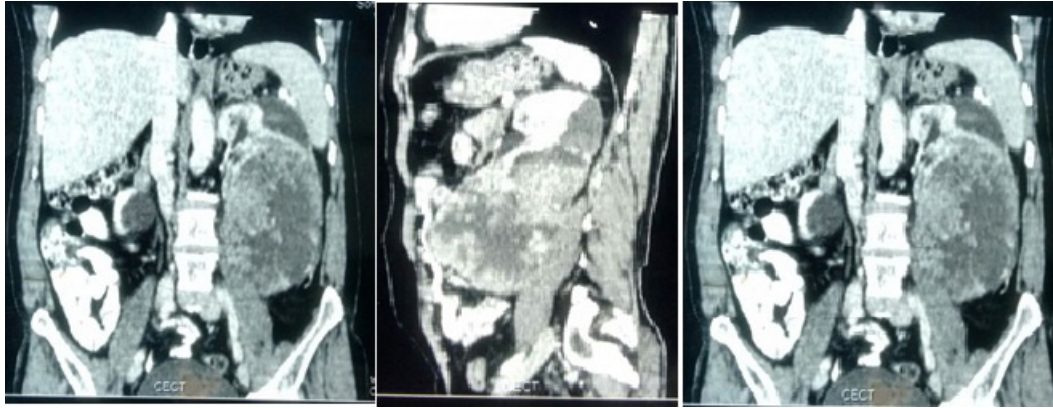


Figure 1 Shows a large retroperitoneal tumour with loss of fat planes with the kidney.

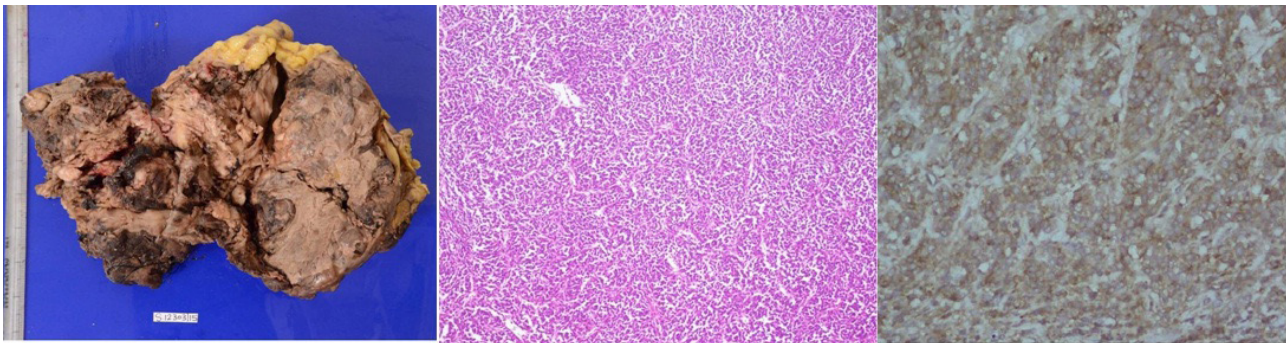


Figure 2 Left nephrectomy specimen showing large areas of haemorrhage and necrosis. Microscopy shows tumour arranged in sheets with intervening blood vessel. Immunostaining shows diffuse strong immunopositivity for CD99 immunostain.

REFERENCES

- Asiri M, Al-Sayyad A. Renal primitive neuroectodermal tumour of childhood: A case report and review of literature. *Can Urol Assoc J* 2010; **4**(6): 158-60.
- Kairouani M, Mokrim M, Mellas N, Khenoussi B, M'rabti HE, Boutayeb S, Errihani H. Metastatic Ewing's sarcoma/PNET of kidney in 40 year old patient. *International Journal of Surgery Case Reports* 2012; **3**: 215-217.
- Ohgaki K, Horiuchi K, Mizutani S, Sato M, Kondo Y. Primary Ewing's sarcoma/primitive neuroectodermal tumour of the kidney that responded to low dose chemotherapy with ifosfamide, etoposide, and doxorubicin. *Int J Clin Oncol* 2010; **15**: 210-214.
- Sun C, Du Z, Tong S, Xu K, Ding W, Sun J and Qiang Ding. Primitive neuroectodermal tumour of kidney: case report and review of literature. *World J Surg Oncol* 2012; **10**: 279.
- Juan CJ, Wu CJ, Chen CY, Lee SS, Chen A, and Fan HC. Primitive neuroectodermal tumour of the kidney associated with Budd-Chiari syndrome in a 17-year-old girl. *J Formos Med Assoc* 2001; **100**: 628-30.
- Gupta S, Billadelo L, Casalino DD. Renal Primitive Neuroectodermal Tumour. *J Urol* 2012; **187**: 2211-2212.
- Chu WC, Reznikov B, Lee EY, Grant RM, Cheng FW, Babyn P. Primitive neuroectodermal tumour (PNET) of the kidney: a rare renal tumour in adolescents with seemingly characteristic radiological features. *Pediatr Radiol.* 2008; **38**(10): 1089-1094
- Zhong J, Chen N, Chen X, Gong J, Nie L, Xu M, and Zhou Q. Peripheral primitive neuroectodermal tumour of the kidney in a 51-year-old female following breast cancer: A case report and review of literature. *Oncology letters* 2015; **9**: 108-112.
- Xie J, Wen J, Bi YL, Li HZ. Primitive neuroectodermal tumour of the kidney: An unusual case mimicking renal angiomyolipomatumour with minimal fat. *Can Urol Assoc J* 2015; **9**: 5-6: E337-9.
- Mahawang P, Amornvesukit T, Soontrapa S, Sukpanichnant S. Primitive neuroectodermal tumour of the kidney with inferior vena cava thrombosis. *Thai JSurg* 2010; **31**: 35-37.
- Marinova L. Retroperitoneal primitive neuroectodermal tumour (PNET). A case report and review of literature. *Reports of practical oncology and radiotherapy* 2010; **14**: 221-224.
- Giridhar P, Mallick S, Kumaran D, George A, Kaushal S, Julka PK. Primitive neuro-ectodermal tumour of the kidney in adult: Report of four consecutive cases and review of literature. *J Egypt Nat Can Inst* 2015; **27**(4): 235-238.
- Su CC, Liu CL, Lin CN, Leea YH, Shen KH. A rare, highly aggressive primitive neuroectodermal tumour of the kidney: case report and literature review. *Urol Sci* 2012; **23**: 58-60.
- Abbas M, Dammrich ME, Braubach P. Role of immunohistochemistry and fluorescence in-situ hybridisation (FISH) in the diagnosis of spindle and round cell tumours of the kidney. *J Egypt Nat Can Inst* 2015; **27**: 173-178.

Peer reviewers: Katsuyuki Aozasa, MD, PhD, Emeritus Professor, 1-37-16 Niwashirodai, Sakai, Osaka, Japan; Gulhane Research and Training Hospital, Department of Urology, Istanbul, Turkey.