

## Direct, Duodenum-Guided Access to the Renal Hilum During Laparoscopic Radical Nephrectomy

Anastasios D. Asimakopoulos, Jean-Luc Hoepffner, Thierry Piechaud, Camille Mugnier, Richard Gaston

Anastasios D. Asimakopoulos, Department of Experimental Medicine and Surgery, UOC of Urology, University of Rome Tor Vergata, Policlinico Casilino, Rome, Italy

Anastasios D. Asimakopoulos, Jean-Luc Hoepffner, Thierry Piechaud, Camille Mugnier, Richard Gaston, Department of Urology, Clinique Saint-Augustin, Bordeaux x, France

Correspondence to: Anastasios D. Asimakopoulos, MD, PhD, FEBU, Department of Experimental Medicine and Surgery, UOC of Urology, University of Rome Tor Vergata, Policlinico Casilino, Rome, Italy

Email: [tasospao2003@yahoo.com](mailto:tasospao2003@yahoo.com)

Telephone: +39-3406054387 Fax: +39-0623188266

Received: November 8, 2015 Revised: December 18, 2015

Accepted: December 22, 2015

Published online: April 18, 2016

© 2016 The Authors. Published by ACT Publishing Group Ltd.

**Key words:** Nephrectomy; Laparoscopy; Radical nephrectomy; Duodenum; Treitz ligament

Asimakopoulos AD, Hoepffner JL, Piechaud T, Mugnier C, Gaston R. Direct, Duodenum-Guided Access to the Renal Hilum During Laparoscopic Radical Nephrectomy. *Journal of Tumor* 2016; 4(2): 403-406 Available from: URL: <http://www.ghrnet.org/index.php/jt/article/view/1672>

### ABSTRACT

**AIM:** To provide a step-by-step description of the surgical technique that allows for a direct, duodenum-guided access to the renal hilar vessels during laparoscopic radical nephrectomy (LRN).

**MATERIALS AND METHODS:** For a right-sided LRN, a Kocher maneuver exposes the underlying vena cava (VC). The cephalad dissection of its lateral margin leads to the right renal vein (RRV). The right renal artery is identified posteriorly between RRV and VC and clip-secured. The access to the left renal hilum is guided by the identification of the fourth portion of the duodenum and the inferior mesenteric vein. The Treitz ligament is incised. The duodenum is medialized exposing the aortic wall and the left renal vein. The lateral surface of the aorta is carefully dissected till the emergence of the left renal artery.

**CONCLUSIONS:** The described approach, although technically challenging represents a feasible, safe and oncologically valid technique to perform LRN in the hands of an experienced laparoscopist.

### INTRODUCTION

Laparoscopic radical nephrectomy (LRN) is the recommended standard of care for patients with T2 renal tumours or smaller masses not treatable by nephron-sparing surgery (NSS)<sup>[1]</sup>, with equivalent long-term cancer-free survival rates to open radical nephrectomy<sup>[2]</sup>.

Conventionally, LRN should be based on the oncologic principles declared by Robson in 1963<sup>[3]</sup>, where early ligation of the renal artery represents one fundamental step. However, artery ligation during LRN is usually described as a late maneuver<sup>[4]</sup>, following several other surgical steps. During LRN, in fact, after the medial mobilization of the colon, the Gerota's fatty tissue at the level of the lower pole of the kidney is incised and lifted to locate the psoas muscle. The psoas is followed to expose the ureter, just lateral and deep to the gonadal vessels. Both the ureter and the gonadal vessels on the left side and just the ureter on the right are lifted and followed cranially to the hilum of the kidney, which vascular elements are then exposed, dissected, ligated and transected.

It is evident that these steps determine some manipulation of the kidney before artery ligation, that could, theoretically, increase the risk of cancer cell release<sup>[5]</sup>.

With the current manuscript we describe our technique of early control of the renal hilum guided by the preliminary dissection of the duodenum.

## MATERIALS AND METHODS

### (a) Patient positioning and ports

Following general anaesthesia, an orogastric tube and a Foley urethral catheter are inserted. The patient is placed in the extended lateral decubitus in a "praying" position. A standard four to five-port transperitoneal technique is followed<sup>[6]</sup>.

### (b) Main retroperitoneal landmarks-Surgical anatomy

In a radical nephrectomy, the dissection takes place outside Gerota's fascia, in the fibrofatty tissue of the posterior and anterior pararenal spaces.

The left renal artery originates on the left lateral surface of the aorta, practically at the level of the ligament of Treitz. The left renal vein and its branches are situated ventral to the artery in the dissection plane of Toldt's fascia. The gonadal vein runs parallel and anterior to the ureter. The adrenal vein is encountered on the superior margin of the renal vein, in a more medial position. The second lumbar vein takes off from the posterior surface of the renal vein<sup>[7-8]</sup>.

On the right side, following the inferior vena cava cephalad, the right gonadal vein is the first vascular structure encountered. It runs parallel to the ureter, which is situated posteriorly. More cephalad, the renal vein joins the vena cava on a course that is often very short. The renal artery is situated inferior and posterior to the renal vein. It crosses the inferior vena cava posteriorly. The adrenal vein drains into the suprarenal portion of the vena cava<sup>[8]</sup>.

The posterior anatomic relations of the 2<sup>nd</sup> and 4<sup>th</sup> portion of the duodenum aid in the identification of the renal hilum. The 2<sup>nd</sup> portion of the duodenum ("descending") is related posteriorly to the medial surface of right kidney and structures at its hilum, inferior vena cava, and psoas major muscle while the 4<sup>th</sup> portion ("ascending") is related posteriorly to the left psoas major muscle and left renal vessels<sup>[9]</sup>.

At the level of the duodenojejunal flexure, the presence of the suspensory muscle of the duodenum marks the formal division between the duodenum and the jejunum.

The suspensory muscle of the duodenum consists of a lower muscular portion with a broad base, and an upper tendinous portion<sup>[10]</sup>. It arises from the right crus of the diaphragm as it passes around the oesophagus, continues as connective tissue around the stems of the celiac trunk and superior mesenteric artery, passes behind the pancreas, and enters the upper part of the mesentery, inserting into the junction between the duodenum and jejunum<sup>[10]</sup>. Here, the muscles are continuous with the muscular layers of the duodenum<sup>[10]</sup>.

### (c) Operative steps

#### Right side

If necessary, the right colon is reflected medially by releasing its lateral attachments. The underlying duodenum is exposed (Figure 1).

The assistant gently pulls on the second portion of the duodenum to put tension on its retroperitoneal connections, that are then carefully incised in a semicircle adjacent to the duodenum.

A wide Kocher maneuver exposes the anterior surface of the underlying vena cava. The progressive cephalad dissection of its lateral margin leads to the right renal vein (Figure 2). The careful dissection of the lateral border of the IVC reveals also the psoas major muscle, important landmark for all the subsequent dissection maneuvers (Figures 3 and 4).

The renal artery joins the renal hilum by crossing the posterior surface of the inferior vena cava. After the posterior dissection of the junction between the right renal vein and vena cava, the trunk of the

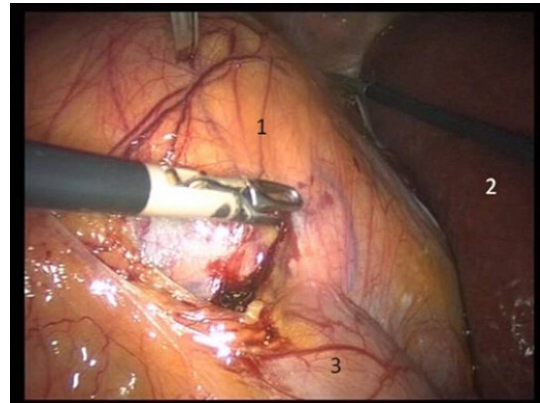


Figure 1 1: kidney, 2: liver, 3: duodenum.

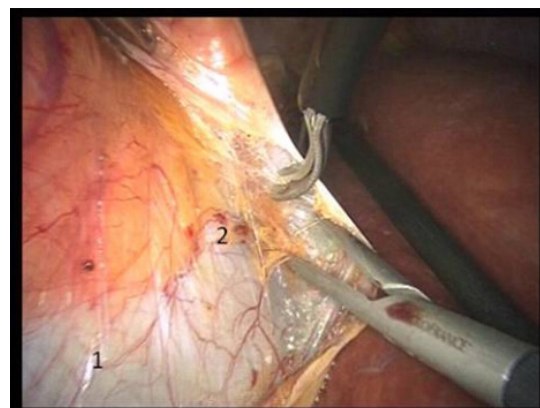


Figure 2 1: inferior vena cava, 2: right renal vein.

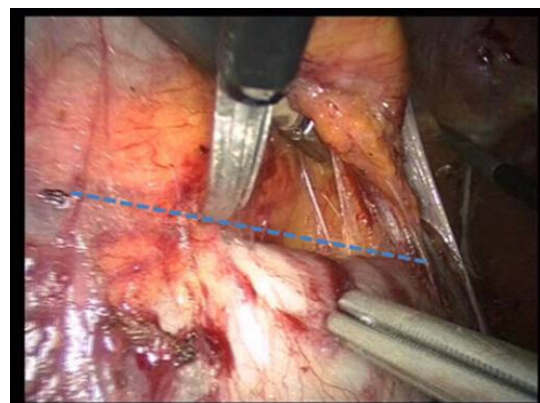


Figure 3 Blue dotted line: lateral border of the inferior vena cava.

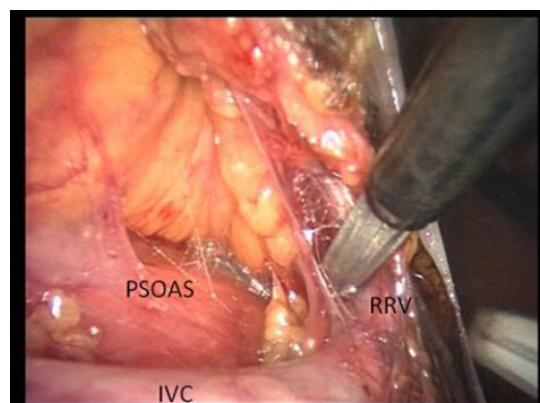


Figure 4 IVC: inferior vena cava, RRV: right renal vein.

renal artery is identified (Figure 5).

The gonadal vein lies far below, and drains directly into the inferior vena cava. A dissection lateral to the confluence of the gonadal vein to the inferior vena cava also reveals the psoas muscle.

The renal artery is dissected free, clipped three times proximally and twice distally, then divided between clips. Sometimes, one or two clips should be applied on the artery in order to stop the renal blood flow and control the empty vein. The artery control can then be completed after cutting the renal vein.

#### Left side

The dissection of the left renal pedicle may be performed by first approaching the renal artery at its take off from the left side of the aorta.

Contrarily to the normal procedure we do not incise the Toldt's line; consequently, the descending colon is not mobilized and it remains attached to the lateral abdominal wall.

The procedure begins with the identification of the fourth portion of the duodenum and the inferior mesenteric vein.

First the posterior peritoneum, laterally to the duodenum and then the Treitz ligament, which suspends the 4<sup>th</sup> portion of the duodenum to the diaphragm pillars, are evidenced and incised (Figures 6a and 6b respectively).

The duodenum is medialized exposing the aortic wall and the left renal vein. The dissection of the adipose and lymphatic tissue surrounding these vessels improves their visualization and creates a quadrilateral narrow working space delimited by the aorta inferiorly, Gerota's capsule laterally, the duodenum and cava vein medially and by the vascular arc of the inferior mesenteric vein superiorly<sup>[5]</sup>.

The lateral surface of the aorta is carefully dissected in an upward direction till the emergence of the left renal artery. The gonadal artery (Figure 7) may be easily controlled with bipolar coagulation or clips.

The inferior aspect of the renal artery is then dissected. We cranially retract the renal vein in order to identify the upper aspect of the left renal artery that is also carefully dissected till its aortic origin (Figure 8).

The renal artery is secured with 10 mm metallic clips (leaving about 1 cm of stump from the aorta) and the renal vein with Hem-o-lock clips (Teleflex Medical, Research Triangle Park, NC, USA) or Multifire Endo GIA™ 30 12-mm stapler.

When the renal artery has been controlled, the procedure continues as for the standard technique of LRN.

#### (d) Postoperative care

No drain is usually placed. The orogastric tube is removed at the end of the procedure, and the intravenous perfusion is stopped on day 1. Pain is usually controlled with paracetamol. A light diet can generally be resumed one day after surgery. The Foley catheter is usually removed on day 1. The patient leaves the hospital usually on the third postoperative day. Vigorous activities are limited for at least one month after surgery.

## DISCUSSION

The advantages of the direct access to the renal artery are several, since it allows for: (1) Early control of the renal artery that leads to lower risk of bleeding during the next surgical steps; (2) Absence of kidney manipulation before ligation of the artery that minimizes the risk of cancer cell release and respects the oncologic principles of Robson; (3) Proximal control of the main arterial trunk near its origin that avoids anatomic variations or ramifications; (4) Avoiding

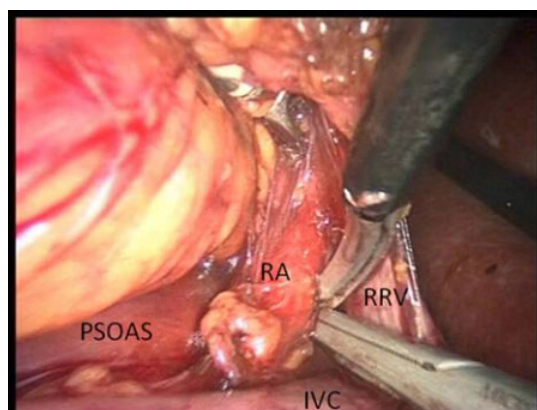


Figure 5 RA: right artery, RRV: right renal vein, IVC: inferior vena cava.

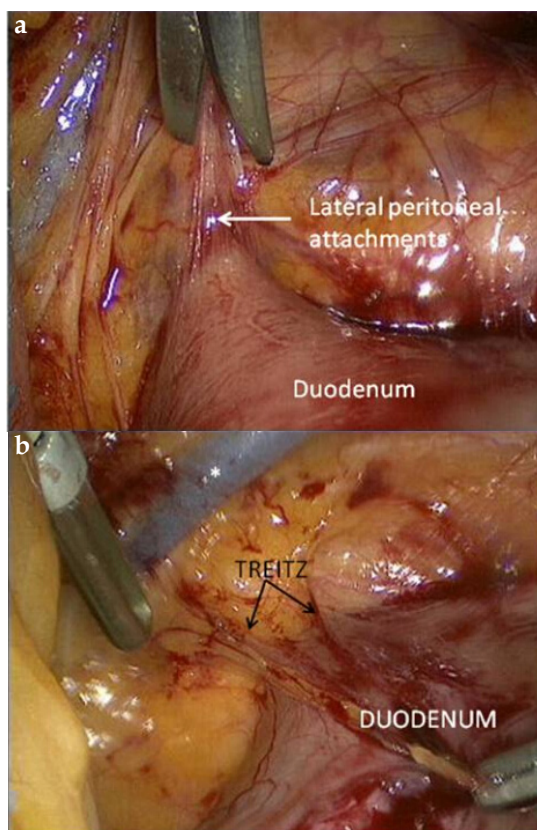


Figure 6 \*= inferior mesenteric vein.

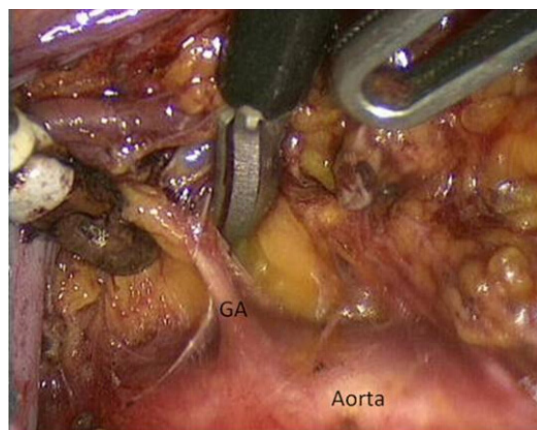


Figure 7 GA: left gonadal artery. It emerges from the abdominal aorta a little below the renal artery.

eventual volumetric interferences with large renal masses or even locally advanced renal tumors during the dissection of the renal hilum; (5) A complete removal of the hilar lymph nodes, improving the N-staging of the disease.

This approach is technically demanding and requires a solid laparoscopic experience and knowledge of the anatomy of both the peritoneal and extraperitoneal space. While on the right side the procedure seems straightforward, some critical issues should be highlighted for the application of this technique on the left: (1) The limited space of dissection increases the difficulty of the procedure and requires laparoscopic experience; (2) Both the renal artery and vein should be carefully circumscribed; their proximal dissection reveals important collateral vessels (Figures 9 and 10 respectively) that if injured could cause bleedings - hardly managed in such a restricted working space; (3) Attention should be paid in order to avoid ligation of the superior mesenteric artery (laying above the left renal vein).

## CONCLUSIONS

The direct, duodenum-guided approach to the renal hilum during LRN is feasible. It requires laparoscopic experience and solid knowledge of the anatomy of the retroperitoneal space. It allows for a preliminary control of the main arterial trunk and safer performance of the subsequent dissection maneuvers.

## CONFLICT OF INTERESTS

There are no conflicts of interest with regard to the present study.

## REFERENCES

- 1 Ljungberg B, Cowan NC, Hanbury DC, Hora M, Kuczyk MA, Merseburger AS, Patard JJ, Mulders PF, Sinescu IC. EAU guidelines on renal cell carcinoma: the 2010 update. *Eur Urol.* 2010; **58**(3): 398-406.
- 2 Burgess NA, Koo BC, Calvert RC, Hindmarsh A, Donaldson PJ, Rhodes M. Randomized trial of laparoscopic v open nephrectomy. *J Endourol* 2007; **21**: 610-3.
- 3 Robson CJ. Radical nephrectomy for renal cell carcinoma. *J Urol* 1963; **89**: 37-42.
- 4 Rosenblatt A, Bollens R, Cohen BE. Manual of laparoscopic urology. Chapter II, pages 21-34. 2008 Springer-Verlag Berlin Heidelberg.
- 5 Porpiglia F, Renard J, Billia M, Morra I, Scoffone C, Cracco C, Tarabuzzi R, Terrone C, Scarpa RM. Left laparoscopic radical nephrectomy with direct access to the renal artery: technical advantages. *Eur Urol.* 2006; **49**(6): 1004-10.
- 6 Asimakopoulos AD, D'Orazio A, Pereira CF, Hoepffner JL, Mugnier C, Gaston R, Piechaud T. Surgery illustrated--focus on details: Laparoscopic repair of obstructing retrocaval ureter. *BJU Int.* 2011 Apr; **107**(8): 1330-4.
- 7 Mirilas P, Skandalakis JE. Surgical anatomy of the retroperitoneal spaces part II: the architecture of the retroperitoneal space. *Am Surg.* 2010; **76**(1): 33-42.
- 8 Mirilas P, Skandalakis JE. Surgical anatomy of the retroperitoneal spaces, Part III: Retroperitoneal blood vessels and lymphatics. *Am Surg.* 2010; **76**(2): 139-44.
- 9 Butler P, Mitchell A, Healy JC. Applied Radiological Anatomy. Cambridge University Press. (2012) ISBN:0521766664.

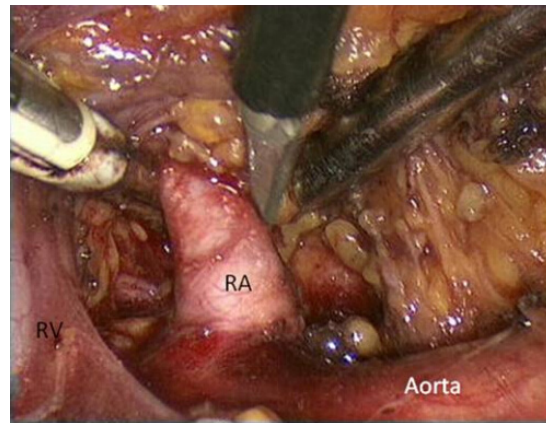


Figure 8 Evidence of the narrow working space developed during this technique. The vascular elements of the renal hilum are evidenced, with the artery laying under the vein. The left renal vein passes in front of the aorta, just below the origin of the superior mesenteric artery (not visualized here). RA: renal artery, RV: renal vein.

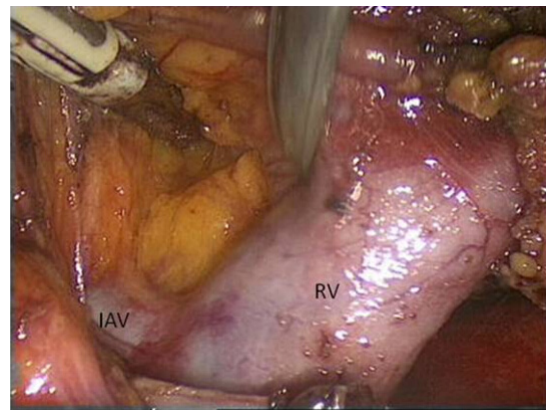


Figure 9 RV: renal vein, IAV: inferior adrenal vein.

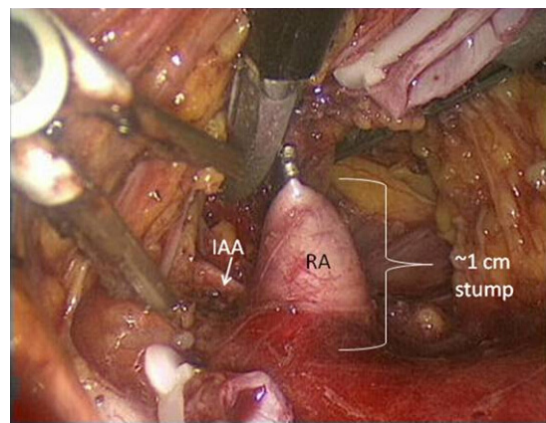


Figure 10 RA: renal artery, IAA: inferior adrenal artery.

- 10 Kim SK, Cho CD, Wojtowycz AR. The ligament of Treitz (the suspensory ligament of the duodenum): anatomic and radiographic correlation. *Abdom Imaging.* 2008; **33**(4): 395-7.

Peer reviewer: Tal Grenader Dr, Oncology Institute, Shaare Zedek Medical Center, P.O. Box 3235, 91031 Jerusalem, Israel.