

Guidelines for Adjuvant Therapy in Gall Bladder and Bile Duct Carcinomas

Aman Sharma

Aman Sharma, Department of Radiotherapy & oncology, Regional Cancer Centre, Indira Gandhi Medical college India Pin 171001.

Conflict-of-interest statement: The author(s) declare(s) that there is no conflict of interest regarding the publication of this paper.

Open-Access: This article is an open-access article which was selected by an in-house editor and fully peer-reviewed by external reviewers. It is distributed in accordance with the Creative Commons Attribution Non Commercial (CC BY-NC 4.0) license, which permits others to distribute, remix, adapt, build upon this work non-commercially, and license their derivative works on different terms, provided the original work is properly cited and the use is non-commercial. See: <http://creativecommons.org/licenses/by-nc/4.0/>

Correspondence to: Aman Sharma, Assistant Professor, Department of Radiotherapy and Oncology, Regional Cancer Centre, Indira Gandhi Medical college 171001 India.

Email: amans757@gmail.com
Telephone: +919816797193

Received: September 29, 2017

Revised: November 25, 2017

Accepted: November 27, 2017

Published online: November 27, 2018

ABSTRACT

Biliary tract cancers are rare cancers that arise from epithelial lining of gallbladder and bile ducts. Gallbladder cancer (GBC) is the most common cancer of the biliary tract and accounts for two thirds of the cases, whereas bile duct cancer accounts for the remaining one-third. Although anatomically these malignancies are related and have similar metastatic patterns, each has a distinct clinical presentation, molecular pathology, and prognosis. Radical surgery offers the only chance of cure, given their proximity to the complex anatomy of porta hepatis, only one third of cases at presentation are resectable, after radical resection relapse is often very frequent. Pattern of recurrence is typically local, although first relapse at a distant site is not uncommon. With high rates of relapse, strategy aimed at

optimizing local control with postoperative radiation alone or in combination with chemotherapy or optimizing systemic recurrence with chemotherapy have potential to improve treatment outcomes. Evidence for use of adjuvant therapy for these rare tumors is fragmentary and has not been evaluated in prospective randomised controlled trials. On basis of uncontrolled institutional series and registry analyses adjuvant approach is favoured and used in up to 70% of centres worldwide. However there is lack of consensus regarding optimal use of post operative therapy, in the present article we review and present pertinent data for use of adjuvant radiotherapy, chemo-radiotherapy and chemotherapy for intrahepatic, extrahepatic cholangiocarcinomas and carcinoma of the gall bladder and propose guidelines for use of adjuvant therapy based upon retrospective data.

Key words: Gall bladder cancer, Cholangiocarcinomas, Adjuvant therapy, Concurrent Chemo-Radiotherapy, Radiotherapy, Chemotherapy

© 2017 The Author(s). Published by ACT Publishing Group Ltd. All rights reserved.

Sharma A. Guidelines for Adjuvant Therapy in Gall Bladder and Bile Duct Carcinomas. *Journal of Tumor* 2018; 6(1): 526-535 Available from: URL: <http://www.ghrnet.org/index.php/jt/article/view/2298>

INTRODUCTION

Cholangiocarcinomas

Cholangiocarcinomas are rare carcinoma^[1], comprising less than 10% of primary malignancies of liver; occur frequently in fifth and sixth decades of life. Cholangiocarcinomas can arise at any site (intra or extrahepatic) of biliary system. Hilar cholangiocarcinomas are most common (67%), followed by distal cholangiocarcinoma (27%), and then intrahepatic cholangiocarcinoma (6%)^[2]. Cholangiocarcinoma is more prevalent in Southeast-Asia than in other parts of world. Clinical features are nonspecific and depend on the location of the tumor, usual clinical presentation can be painless jaundice, fatigue, pruritus, fever, vague abdominal pain, and anorexia. Overall, these are highly lethal cancers, with reported 1- and 2-year survival of 25% and 13%, respectively^[3].

Extrahepatic bile duct cancer

Surgery

Extrahepatic bile duct carcinoma (EHBC) is a rare malignancy with devastating outcome. These tumors are usually classified as upper, middle, or distal bile duct cancer; however, tumors are rarely confined to one segment. They have propensity to spread along bile duct system; locally by direct extension into adjacent structures, regional spread commonly involves pericholedochal, peripancreatic, hilar, cystic lymph nodes and distant spread occurs to liver and peritoneum. Surgical resection offers the only chance of cure. Overall survival (OS) in inoperable is less than 6 months and 5-year survival rate is 0%. Prognosis usually depends on tumor location and extent of resection. Pancreatoduodenectomy is generally performed in cases of distal and mid third cancer whereas bile duct resection, with or without hepatectomy is performed for proximal third cancer, all accompanied by regional lymphadenectomy. It is increasingly evident that margin-negative resection, often requiring hepatic resection, is only potentially curative procedure. Reported 5-year survival rates of extrahepatic bile duct cancer are 20%-30%^[2, 4-6], recurrence beyond 5 years are not uncommon^[4]. Tumor location and performance of a complete resection have significant effect on prognosis. Even with optimal margins, two of three patients experience recurrence within 2 years, and 60% of these recurrences are loco-regional^[2-6].

Adjuvant Radiotherapy

Given the dismal outcome after surgery, postoperative radiotherapy (RT) has been advocated to improve treatment outcome although benefit of RT is not well established. Studies assessing adjuvant radiotherapy show inconsistent results^[7-14], small retrospective series demonstrate that RT significantly improved survival in margin-positive disease^[13] while others series have failed to show benefit of RT^[11]. Role of RT following margin-negative resection is even less clear.

Retrospective series comparing surgery alone versus post operative

radiotherapy have been highlighted in Table 1. Use of higher radiation dose and addition of brachytherapy have been proposed as potential contributors to improved survival for these rare tumors. Increasing dose of RT has been associated with prolongation of survival (MS 4.5 months, 9 months, 18 months and 25 months for RT doses of < 45Gy, 45Gy-55Gy, 55Gy-65Gy, 66-70Gy, respectively)^[9]. Patients subjected to > 55Gy RT dose have experienced better survival than those receiving < 55Gy (2-year OS 48% vs. 0% and MS 24 months vs 6 months).

In absence of prospective randomized controlled trials addressing role of post-operative RT we highlight the role of RT within large population based series. Results of large retrospective series evaluating adjuvant RT have been briefly mentioned in table 2. In a large cohort of patients within SEER database RT was not associated with improvement in survival^[15]. However in the study more patients with poor prognosis (nodal metastasis & other high-risk features) were subjected to the RT arm and on adjustment of these factors on multivariate analysis adjuvant RT was independently associated with improved OS. Interestingly, the initial positive effect of RT was lost on longer follow up & RT had negative impact on survival. This detrimental effect on survival with RT was for patients treated before 1990 and was limited to patients with Stage I disease. Less-advanced radio-therapeutic techniques at that time coupled with selection bias from variables that remained unknown (lack of information on extent of surgery, margin status) could have resulted in discrepancies in observed results. Another large retrospective^[16] demonstrated improved survival with use of RT (MS 16 versus 9 months). On multivariate analysis RT not associated with improved OS, multivariate analysis of this study had few limitations as it did not stratify patients by margin status and only limited numbers of variables were considered for analysis (i.e., age, gender, race, SEER location, and year of diagnosis). Results from recent meta-analysis^[17] that included patients treated with modern RT techniques and that had information on margin status for resected EHBC, showed that

Table 1 Comparison of outcomes with and without use of adjuvant radiotherapy

Study	Year	No	Sx alone	Sx+RT	RT DOSE median	MS Surgery	Median Survival Sx+RT	comment
Hanna et al[7]	1978	17	-	-	40Gy	Median os 12 mo		RT showed glimmer of hope in an otherwise desolate field.
Schoenthaler et al[8]	1994	107	62	45	54Gy	6.5 mo	11mo; R1 resection; p = 0.0005; R2 resection; p = 0.05.	Postop RT associated with significant survival advantage with positive microscopic and gross residual disease
Alden et al[9]	1994	48	24	24	46Gy+; 25Gy; 1192	5.5 mo	12 mo; p = 0.0003.	Dose response with RT 2-year survival of 48%vs0% for patients treated with >55Gy or < 55Gy.
Alden et al[10]	1995	81	22; 15	34; 10	54Gy	6 mo; 68 mo	17 mo, P = 0.01; 68 mo.	Distal cancer survived better than proximal 53%vs13% at 5 yrs. MS proximal cancer after RT was more than double that without RT.
Pitt et al[11]	1995	50	27	23	46 Gy	15 mo	14 mo	For localized perihilar cholangiocarcinoma, resection prolongs survival whereas radiation has no effect on either survival/late toxicity
Kamada et al[12]	1996	91	20	71	67.8Gy; Mean RT dose (ILRT+; EBRT)	8 mo; R1 Disease; 3yr OS 0%.	24 mo; R1 Disease; 44%; p < 0.001.	Survival advantage with positive margins disease.
Todoroki et al[13]	2000	66	19	47	43Gy; EBRT+21Gy ILRT	13.5%; @5 yr.	33.9%; @5yr; p = 0.014.	Local-regional control significantly higher with RT (79.2%vs31.2%). Improved with use of adjuvant RT in R1 disease with acceptable treatment mortality and morbidity.
Heron et al[14]	2003	62	22	40	(ILRT 25Gy+ EBRT 46Gy)	Distal; MS not reached. Proximal; MS; 24mo.	62.5 mo; 17 mo; P = 0.007.	Improved OS in proximal tumors adjuvant RT. For distal tumors addition of RT appears to offer an advantage.

delivery of postoperative RT was associated with improved OS, benefit of RT remained significant despite the fact that more than 50% of patients in RT cohorts had lymph nodes metastasis and/or involved resection margins (69% vs 31%). Modern RT was tolerated well and was associated with low toxicity (2–9% late obstruction/ GI bleeding). In absence of large prospective randomised trials, meta-analysis is reasonable option to generate high level evidence; this recently published meta-analysis confirms the benefit in survival with use of modern RT techniques for EHBC.

Adjuvant Chemo-radiotherapy

Concurrent chemo-radiotherapy (CRT) has proven efficacy against other gastrointestinal cancers, but only few reports have evaluated adjuvant CRT for EHBC^[18-22]. Recent series highlighting the role of CRT have been mentioned in Table no 3, results within these series suggest that adjuvant CRT might effectively control loco-regional disease and improve patient survival, with low toxicity levels. Five year local control in these series ranges from 62%-78%, 5 year disease free survival is 26%-37% and 5 year survival is to the tune of 30%-40%^[18-22]. Although there is paucity of prospective randomised trials to support benefit of CRT but results within these series appear encouraging^[2-14]. In recent study^[18] adjuvant CRT was independent prognostic factor for loco-regional control (LRC), disease free survival (DFS) and OS, 5-year LRC, DFS and OS rate were 54.8%, 30.6%, and 33.9%, respectively. These findings have been further confirmed within a meta-analysis^[23] results of which have been

briefly highlighted in Table 4.

Adjuvant CRT followed by adjuvant Chemotherapy

A recent single centre study evaluated role of adjuvant CRT with or without further adjuvant chemotherapy. Three year DFS for CRT-alone and CRT followed by adjuvant chemotherapy was 26.6% and 45.2% respectively and 3-year OS was 30.8% and 62.6% respectively^[24]. Although at present there is paucity of literature for combining chemotherapy to concurrent chemo-radiotherapy to further improve outcomes, guiding factors for such treatment selection may include good general and nutritional status coupled with good compliance to concurrent chemo-radiotherapy course.

Summary & guidelines for adjuvant therapy for extra-hepatic cholangiocarcinomas: (1) Adjuvant RT traditionally used in patients with adverse prognostic features whereas smaller tumors, margin negative with no LN involvement often treated with surgery alone. There is some evidence that older RT techniques are associated with detrimental effect on survival especially in early stage disease. (2) Use of Modern radiotherapy is associated with improvement in survival, adjuvant RT indicated for margin positive disease and lymph node metastasis. (3) CRT is the preferred adjuvant treatment of choice (more efficacious than RT alone) indicated in margin positive and lymph node metastasis, CRT may be considered for locally confined disease with at least T2 or higher stage.

Table 2 Large Retrospective Data Analyzing Adjuvant Radiotherapy in Extra-hepatic Cholangiocarcinomas

Study	Year	N	Analysis	Surgery Alone	Sx+RT	Median OS Sx	Median OS RT	P value	Comments
Tamara et al[15]	2011	1491	1973-2003	1081	473	36 mo	28 mo	0.38	Older studies from 1973 using primitive RT techniques included, Adjuvant RT associated with worse outcomes. More patients in RT arm had node positive disease.
Shinohara et al[16]	2011	4758	1988-2003	1379	713	9 mo	16 mo	p < 0.0001	Only recent studies included, surgical details available, Adjuvant RT in large cohort associate with improved survival; however on Cox proportional hazard model adjuvant RT not associated with significant improvement in survival. Margin status mot available.
Beltran et al[17]	2011	858	1995-2008	458	400	-	-	p < 0.001; HR0.62; 95%CI 0.48-0.78	Only large study that evaluated margin status, modern series using 3D- conventional RT techniques evaluated, Adjuvant RT associated with improved survival despite RT cohorts had more frequently positive margins (69%vs31%, p < 0.001). Late RT induced toxicity low (2-9% obstruction/GI bleeding)

Table 3 Adjuvant Chemo radiation in Cholangiocarcinomas.

Study	Year	N	R0	R1	R2	N1	RT DOSE (median)	CCRT (%)	5yr OS (%)	5yr DFS (%)	5yr LC (%)
Kim et al[18]	2002	84	47	25	12	27	40	85	31	26	-
Hughes et al[19]	2007	34	25	9	0	28	50.4	100	35	30	70
Nelson et al[20]	2008	45	36	6	3	11	50.4	98	33	37	78
Borghero et al[21]	2008	42	15	27	0	19	45	100	36	34	62
Jin-Hong et al[22]	2009	81	52	37	0	43	50	83	39	30	70

Table 4 Result from meta-analysis evaluating adjuvant chemotherapy, radiotherapy, or both for Biliary Neoplasm.

N	7612
Year	1960-2010
Site	Bile duct &GBC
OS(Bile duct+ GB cancer). Sx alone adjuvant therapy	Adjuvant therapy improved trend in OS. Odds Ratio(OR), 0.74(95%CI, 0.55-1.01; p = 0.06). High risk group significant benefit of adjuvant therapy. LN-positive disease (OR, 0.49; p = 0.004). R1 disease (OR, 0.36; p = 0.002).
OS (Bile duct carcinoma). Sx alone adjuvant therapy	Bile ducts: OR 0.71 (95%CI, 0.46-1.07; p = 0.10).
OS(GB cancer). Sx alone adjuvant therapy	Gallbladder: OR, 0.81 (95%CI, 0.49-1.35; p = 0.41)
OS benefit by modality	CT OR 0.39 (95%CI, 0.23-0.66; p = 0.001). CRT OR 0.61 (95%CI, 0.38-0.99; p = 0.049). RT alone 0.98 (95%CI, 0.67-1.43; p = 0.90)

Intrahepatic Cholangiocarcinomas

Intrahepatic cholangiocarcinoma (IHC) is a rare malignant tumor with a rising incidence (not solely explained by reclassification and improved detection)^[22, 25]. IHC spreads along sinusoids, duct wall and periductal tissue, it may be confined to duct as intraductal growth, can spread along Glisson’s sheath, cause permeation of portal connective tissue and cause vascular involvement. Sinusoidal invasion and portal vein invasion are the most frequent mode of intrahepatic spread. IHC is associated with early lymphatic spread; rate of metastasis to hilar lymph nodes is about 50%^[25].

Surgery

Surgery is only choice of curative therapy. IHC has no characteristic symptoms at its early stage and is often diagnosed in advanced stage. Consequently, respectability rates are usually low, extended hepatectomy possibly in combination with resection of other structures (e.g. extrahepatic bile duct, portal vein and inferior vena cava) along with radical lymphadenectomy. Prognostic factors for IHC are tumor number, vascular invasion, and LN metastasis whereas tumor size provides no prognostic information. Aggressive surgical strategies significantly increase survival^[3, 26-28], radical resection of cholangiocarcinomas over past 10 years has resulted in increased proportion of patients with negative resection margins and a consequent improvement in 5-year survival^[26, 29]. Even after surgical techniques and improved postoperative management, extended hepatectomy still entails significant morbidity and mortality, most

surgical series have reported mortality rates lower than 5%, but complication rate is still high (20%-50%)^[27, 30]. Prognosis for patient with IHC after resection is unsatisfactory. Five year OS rate varies from 14%-36%, and it does not exceed 40% in more recent surgical series^[3, 27-33].

Adjuvant Radiotherapy

Because of the low incidence of IHC, large randomized trials evaluating effectiveness of radiation are not available. Retrospective series demonstrate that adjuvant RT may improve survival in patients with microscopically positive margins^[13, 33-35]. The largest analysis of IHC performed to date suggests that RT prolongs OS both postoperatively and definitively^[36]. This analysis of 3,839 patients revealed that patients diagnosed between 1993-1997 and 1998-2003 had improved OS (HR 0.87 & HR 0.55 respectively) compared with those diagnosed between 1988-1992. Survival was better for patients treated with surgery & RT versus surgery alone (11months vs 6 months). Adjuvant RT was associated with 22% reduction in mortality. Findings within the study have briefly been highlighted in Table 5.

Adjuvant Chemo-radiotherapy

CRT is associated with improved outcomes as compared to adjuvant RT^[18-23]. Adjuvant CRT in bile duct carcinomas^[18-23] is indicated for patients with margin and node positive disease & it may be considered for early localised margin negative disease given the

Table 5 Adjuvant Radiotherapy Intra-hepatic Choangiocarcinomas results within largest series ever published.

N	3839
Surgery Alone	25%
Radiotherapy Alone	10%
Sx+RT	7%
No treatment	58%
Median Age	73 years (22–102years)
Median OS	Sx+RT 11 mo (95% CI 9-13mo)
	Sx-Alone 6 mo(95% CI 5-6mo)
	R-Alone 7 mo(95% CI 6-8mo)
	No Treatment 3 mo
Multivariate analysis	Sx+RT: HR, 0.40; 95%CI, 0.34–0.47 (maximum benefit)
	Sx-Alone: HR, 0.49; 95%CI, 0.44–0.54
	RT-Alone: HR, 0.68; 95%CI, 0.59–0.77
OS Sx+RT with respect Sx Alone	HR, 0.82; 95% CI, 0.70–0.96
OS RT-alone versus No treatment	HR, 0.67; 95% CI, 0.58–0.76

Table 7 Large series of Adjuvant Radiotherapy Carcinoma Gall Bladder.

	Mojica et al[46]	Wang et al[47]
Series	SEERdatabase	SEERdatabase
Period	1992-2002	1988-2003
N	3187	4180
Medial Follow up	26mo	–
Surgery	73%	100%
Adjuvant RT	20%	18%
Media OS	Sx+RT 14mo	Sx+RT 15mo
	Sx-alone 8mo (p ≤ 0.001)	Sx-alone 8mo (p ≤ 0.001)
Sub group Analysis	Benefit of RT in nodal disease and local invasion	
	1)Regional disease	
	Median OS improved	
	Sx Alone 5mo	
	Sx+RT 16mo(p < 0.0001)	
	2)Local Invasion of Liver	
	Median OS	
Sx 11mo		
Sx+RT 14mo(p = 0.011)		
Adjuvant RT provides a survival benefit in node-positive or ≥ T2 disease.		

Table 6 Small Retrospective series for Adjuvant Radiotherapy carcinoma Gall Bladder.

Study	Year	N	RT Dose	OS	Comments
Houry S et al[41]	1989	20	42Gy	Mean OS	Survival better than historic control treated with Sx-alone
				Stage IV 9.7 mo	
				Stage V 7.2 mo	
Bosset et al[42]	1989	7	54Gy	Five patients alive without evidence of disease], follow up period range 5-58 mo	RT improves survival, recommend in post-operative setting.
Mahe et al[43]	1994	19	30Gy in 10 50Gy in 25	T1-T2	RT well tolerated can improve local control and survival.
				median OS 48 mo	
				Pallative patients Median OS 6 mo	
Kraybill et al[44]	1994	96	variable	Median OS 11 mo	Improvement in survival in patients undergoing surgery, and radiation dose greater than 40Gy.
Lindell et al[45]	2003	20		Sx + RT 5 yr OS 47%	Tendency to longer survival after adjuvant radiotherapy although not statistically significant.
				Sx-alone 5 yr OS 13%	
				Median OS	
				Sx+RT 29 mo Sx-alone 20 mo	

increasing mortality trends coupled with high rates of loco-regional failure^[25-33].

Adjuvant Chemotherapy in Cholangiocarcinomas

The role of adjuvant chemotherapy is even less clear. There is some evidence emerging that^[23] patients receiving chemotherapy may benefit from adjuvant chemotherapy.

Summary & Guidelines for Adjuvant treatment Intra-hepatic Cholangiocarcinoma

(A) CRT preferred adjuvant treatment of choice & indicated for: (1) Node positive; (2) Margin positive; (3) Consider adjuvant CRT for locally confined (T2/3) node negative disease. (B) Adjuvant RT indicated if patient not fit for CRT, benefit of RT confined to node and margin positive disease. (C) Adjuvant Chemotherapy in margin positive disease after CRT may be considered in selected patients.

Carcinoma of the Gall Bladder (GBC)

Incidence of GBC steadily increases with age, women are affected more often than men. Three distinct pockets of high incidence are well documented—central and South America, central and Eastern Europe, and Japan. Northern India has one of the highest incidences of GBC in world (9 per 100,000 per year)^[37]. GBC clinically presents with continuous pain, jaundice, anorexia, and weight loss. Palpable GB mass is advanced and considered unresectable disease. GBC is characterized by local invasion, extensive regional lymph node metastasis, vascular encasement, and distant metastases. Regional lymph involve hepatic hilus (nodes along the common bile duct, hepatic artery, portal vein and cystic duct) whereas celiac, periduodenal, peripancreatic, and superior mesenteric artery node involvement is now considered distant metastatic disease. GBC is

aggressive disease with late presentation, rapid progression, early recurrence, and dismal outcome^[38,39].

Surgery

Surgery remains the only definitively curative therapy however, only 10% of patients with GBC present with early-stage disease and are considered surgical candidates^[40]. An unusual aspect of GBC management is that it is often diagnosed incidentally after routine cholecystectomy many of these cases require a second, definitive procedure and T stage usually guides operative planning. Carcinomas in situ and carcinomas involving just the submucosal layers can be observed after simple cholecystectomy, however if tumor involves muscle radical cholecystectomy, with removal of 2-3cms of normal liver around gallbladder bed (segments IVB and V) and lymphatics within hepatoduodenal ligament, behind head of the pancreas and along common hepatic artery must be additionally excised. Even after complete resection, loco-regional recurrence rates are high. Pattern of failure after curative resection includes peritoneal spread, hepatic metastases, local extra-hepatic recurrence and distant metastases. Five-year survival in most large series is less than 5%, and median survival is less than 6 months^[38,39]. Even recent series suggest meagre improvement in median survival from 4 months (1973-1992) to 6 months (1993-2002) with more current therapy^[39].

Adjuvant Radiotherapy

Data supporting role of adjuvant RT is sparse and generally limited to small retrospective series and anecdotal reports. Early reports evaluating RT primarily demonstrated that delivery of RT is safe and efficacious^[41,42]. Small retrospective series have suggested possible benefit to RT^[41-44], whereas others have not^[45]. These series have briefly highlighted in table 6.

Table 8 Adjuvant Chemo-radiotherapy in Carcinoma Gall Bladder.

Series	Year	N	RT dose (median)	Chemo	R0/R1/R2	5yr LC	5yr OS	COMMENT
Kresl et al[49]	2002	21	54Gy	5-FU	5/4/2012	73%	33% (Margin -) 64%	Results superior to historical controls. 5 yr LC 100% EBRT doses > 54 Gy vs. 65% who received lower dose
Czito et al[50]	2005	22	45Gy	5-FU	6/4/2012	59%	37%	CRT may improve survival.
Gold et al[51]	2009	25	50.4Gy	5 FU	25/0/0	78%	45%	On multivariate analysis CRT independent predictor of improved OS (HR0.3; 95%CI0.13-0.69; p = 0.004)
Kim et al[52]	2012	41	40-50Gy	5 FU	37/8R1+R2	80%	44%	CRT after R0 resection can achieve a good long-term survival rate.

Table 9 Evidence based Recommendations for adjuvant therapy in carcinoma of the bile duct and GB cancer.

	Adjuvant RT	Evidence for RT	Adjuvant CRT	Evidence for CRT	Chemotherapy	Evidence for adjuvant Chemotherapy
EHBDC	Indicated* in: 1. Margin +ve; 2.Node+ve; 3.Benefit in in locally confined (T2/3) margin negative disease uncertain. Improved survival with modern RT techniques.	Metaanalysis17, Large modern retrospective series 16	Indicated* in: 1. Margin +ve; 2.Node+ve; 3. Consider for locally confined (T2/3) margin negative. Improves overall survival for margin positive and node positive. More efficacious than RT alone.	Metaanalysis23, Modern retrospective series 18-22	Indicated for margin positive after CRT	Meta-analysis 23 Retrospective series24
IHBDC	Indicated* same as EHBDC; Improved OS in margin positive disease.	Large retrospective analysis 38	Indicated* in: 1. Margin +ve; 2.Node+ve; 3. Consider for locally confined margin negative. Better OS in margin and node positive disease.	Metaanalysis23, Modern retrospective series 18-22	Insufficient data; margin positive after CRT otherwise	Meta-analysis 23. Retrospective series24
GB carcinoma	Indicated * in: 1. T2 disease and higher disease; 2. Node after radical surgery; 3. Margin +ve (improved survival)	Large retrospective analysis 47-48	Indicated* in: 1. T2 disease and higher disease; 2. Node after radical surgery; 3. Margin +ve (improved survival) more efficacious than RT alone	Meta-analysis, large retrospective series 23,53	May consider for. Node positive & T4 disease (associated with small benefit)	Large retrospective analysis 23,53. Prospective phase III trial 54

*Dose response with RT (RT alone as well as CRT) has been observed^{9,49}, we recommend to use a dose of 54Gy if patient has good general condition, performance status and dose volume parameters for all critical organs at risk are satisfied else at least a dose of 50.4 Gy is recommended. Modern day Linac based radiotherapy is associated with improved treatment outcomes 17, it is preferable to use Intensity modulated radiotherapy and Image guided radiotherapy to increase coverage of tumor bed and regional lymphatics and decrease dose to adjoining critical structures.

In a large multi-centre study^[46] delivery of RT improved survival when compared surgery alone (MS 14 months versus 8 months) despite the fact that patients in RT arm had more advanced disease and fewer stage I disease patients. Benefit of RT persisted after radical surgery as well in patients subjected to simple cholecystectomy & radical surgery. Nodes positive patients derived greatest benefit from RT (MS 16months versus 5months), patients with liver invasion and negative lymph nodes (T3 N0) also benefited from RT (MS 14 months versus 11 months) whereas stage I disease did not appear to benefit from RT. Another large multicentre study^[47] reported similar findings and delivery of RT was associated with improved survival (MS 15 months vs 8 months) despite the fact that more patients with loco-regionally advanced disease were subjected to RT. Adjuvant RT improved survival for specific sub-cohorts of patients stage T2 or greater disease, node-positive disease (derived greatest net benefit)^[47,48]. Results of these two^[46,47] large studies have been mentioned in table 7.

Adjuvant Concurrent Chemo-radiotherapy

Most published series analysing CRT are small, retrospective single-institution series, majority of which seem to indicate potential benefit from adjuvant CRT^[49-52] (Table 8). In most of these series median RT dose ranged from 45-54Gy along with concurrent 5 fluoro-uracil, 5 year local control rate ranges from 59%-80% whereas 5 year OS is approximately 33%-45%. There is associated dose response to RT and dose \geq 54Gy were associated with improved treatment outcomes (100% local control)^[49]. A recent meta-analysis^[23] showed that as compared to RT alone delivery of CRT was associated significant improvement in survival. Benefit of CRT has been further confirmed in large series within SEER database^[53] where propensity scoring in 1,137 patients showed that patients with T2 or N1 disease will gain survival benefit from adjuvant CRT, for T2N0 disease normogram predict improvement in 3-year survival from 42% to 51%, similarly for T3N1 disease model predicts that 3-year overall survival would increase from 11% with surgery alone to 21% with adjuvant chemotherapy and 42% with adjuvant CRT.

Adjuvant Chemotherapy

As discussed previously role of adjuvant chemotherapy is even less clear and more studies are warranted to clearly define the role of chemotherapy. The only prospective randomized phase III trial^[54] conducted till date evaluated adjuvant chemotherapy with 5-fluorouracil and mitomycin versus surgery alone for resected patients with pancreaticobiliary malignancies, accrued 140 patients with GBC. In the trial 5-year overall and disease free survival rates were significantly better in patients receiving chemotherapy (26% vs 14%, $p = 0.0367$ and 20.3%, vs 11.6%, $p = 0.021$ respectively). Survival after noncurative resection was significantly better in chemotherapy group (9% vs 0%, $p = 0.0226$) but no difference was seen when adjuvant chemotherapy was offered to patients operated with curative intent. Multivariate analysis revealed that adjuvant chemotherapy tended to reduce both the risk of death and the risk of disease recurrence. Recent meta-analysis^[23] evaluating adjuvant chemotherapy, concurrent chemotherapy, radiotherapy for both gallbladder and bile duct cancers revealed that patients receiving chemotherapy or CRT derived greater benefit than RT alone and greatest benefit of adjuvant therapy was seen in LN-positive disease and R1 disease. Adjuvant chemotherapy may be considered in selected patients with nodal metastasis or T4 disease.

Summary & Guidelines for Adjuvant therapy in Gall Bladder

Carcinomas

(A) CRT preferred adjuvant treatment of choice & recommended for: (1) T2 disease and higher disease; (2) Node after radical surgery; (3) Margin +ve node positive. (B) Adjuvant RT recommended if patient not fit for CRT (indications remain same as CRT). (C) Adjuvant Chemotherapy associated with small benefit in node positive and T4 disease patients.

Future perspectives and requirement in the future

(A) Innovations in surgical intervention

Past few decades have witnessed tremendous development and evolution of liver surgery that has significantly improved management of Cholangiocarcinomas. Extensive liver resection for bile duct carcinoma with jaundice has high morbidity and mortality rates because of postoperative liver failure, to minimize postoperative liver dysfunction, a portal venous branch is embolized before surgery to induce atrophy of the lobe to be resected and hypertrophy of the contralateral lobe. Portal embolization does not produce major side effects when hepatectomy with bile duct resection and lymphadenectomy is performed. For intrahepatic and hilar tumors with extension to liver preoperative portal vein occlusion has allowed safer major liver resection with negative margins, improving survival^[55-56]. For hilar tumors, aggressive operative approaches, including routine partial hepatectomy, caudate lobe resection, selective pancreatectomy and portal vein resection are associated with higher R0 resection rate and improved survival^[57].

Orthoptic liver transplant (OLT)

For locally unresectable tumors due to invasion of major vessels, bilobar tumor involvement, or insufficient hepatic reserve, total hepatectomy with regional lymphadenectomy and orthoptic liver transplant addresses all margins as well as treats underlying liver disease. Early experience with OLT was not encouraging, with reported 5-year survival ranging from 18 to 25%^[58-59]. However more recent reports indicate that 5-year patient survivals of over 80% can be achieved when liver transplantation is combined with neoadjuvant radiation and chemotherapy in patients with early-stage disease^[60] can be achieved. A recent multi-institutional analysis also confirmed improved outcomes, this study showed that 5-year survival of 45% during most recent era could be achieved with OLT^[61]. Currently, the role of OLT for locally advanced disease recurrence, and the risk that immunosuppression will accelerate the progression of unidentified tumor however Cholangiocarcinoma that presents at an early, but unresectable stage appear to benefit from OLT when compared to similar patients treated with medical therapy alone.

(B) Radiation Therapy: Intensity modulated Radiotherapy/ Stereotactic body radiotherapy

Historically, it was difficult to safely treat tumor bed with lymphatics given the large amount of liver, bowel and kidney were encompassed within RT portals. These organs have lesser tolerance to RT doses and substantial dose delivery to such organs can lead to development of significant morbidity. This can be seen as decrease in survival in some older series when patients were subjected to RT, at other instances initial positive impact of RT was lost on longer follow up where RT was associated detriment in survival^[15]. However modern day radiotherapy has witnessed tremendous change in planning and delivery of RT. Today RT techniques are not only capable of creating highly conformal radiation distributions while sparing adjacent normal tissue sparing but also allow for dose escalation. Use of Modern RT techniques has significantly improved survival

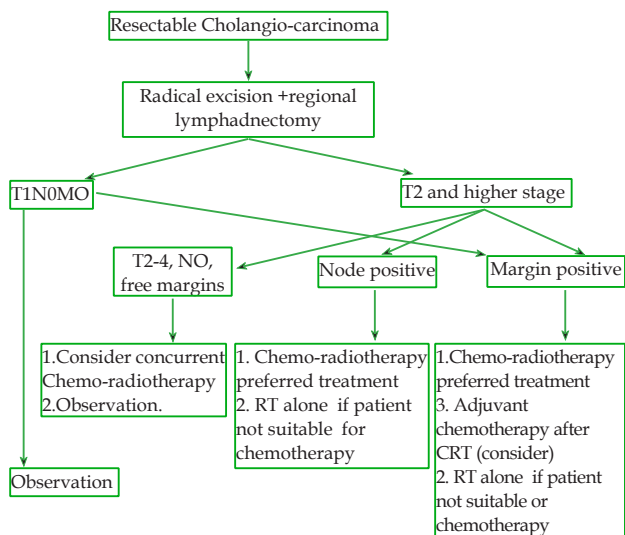


Figure 1 Flow chart depicting management and indications of adjuvant treatment for Resectable Cholangiocarcinomas.

with very limited toxicity when used in adjuvant setting^[17]. Intensity-modulated radiation therapy (IMRT) is the most commonly used highly conformal technique. A recent study evaluated the feasibility dose escalation with use of IMRT with image guidance in patients with GBC to median doses of 59 Gy^[62]. Using IMRT, the liver and kidneys were protected to dose constraints well below accepted levels of tolerance. All patients were treated successfully, treatment was well tolerated and only one patient developed grade 3 toxicity.

Stereotactic body Radiotherapy (SBRT)

SBRT is form of high precision radiotherapy which delivers high doses within a few fractions. SBRT has emerged as an effective treatment option for metastatic lesions of lung and liver as well as primary early stage non-small cell lung cancer in medically inoperable patients. SBRT has been also been explored as a promising treatment alternative for primary liver tumors and other abdominal tumour^[63]. A recent single-institutional study reported clinical outcomes and toxicity with SBRT for cholangiocarcinoma^[64]. In this study ten patients with unresectable primary or recurrent cholangiocarcinoma underwent SBRT with median RT dose of 55 Gy in 2-5 fractions, median follow-up was 14 months, freedom from progression within the SBRT field was 100%. OS estimates for the cohort at 6 and 12 months were 83% and 73%, respectively. As regards to toxicity, acute toxicity (nausea, fatigue, and abdominal pain) were common but relatively mild, with no patient developing Grade ≥ 3 toxicity. Late toxicity was common, abdominal pain was the most common late toxicity but was mild in nature however two patients experienced serious late toxicities; one required placement of biliary stent for Grade 3 biliary stenosis, and another developed Grade 5 liver failure. Another study^[65] treated 27 patients of unresectable cholangiocarcinomas to a dose of 45 Gy in 3 fractions; median progression-free survival and overall survival were 6.7 and 10.6 months, respectively. With a median follow-up of 5.4 years, 6 patients had severe duodenal/pyloric ulceration and 3 patients developed duodenal stenosis. Similarly another study^[66] reported long term follow up in unresectable, non-metastatic, hilar cholangiocarcinoma treated with gemcitabine based chemoradiation plus SBRT (30 Gy in 3 fractions), treatment was well tolerated and only one grade 2 late toxicity was recorded. The overall local response was 80%, Median time to progression was 30 months.

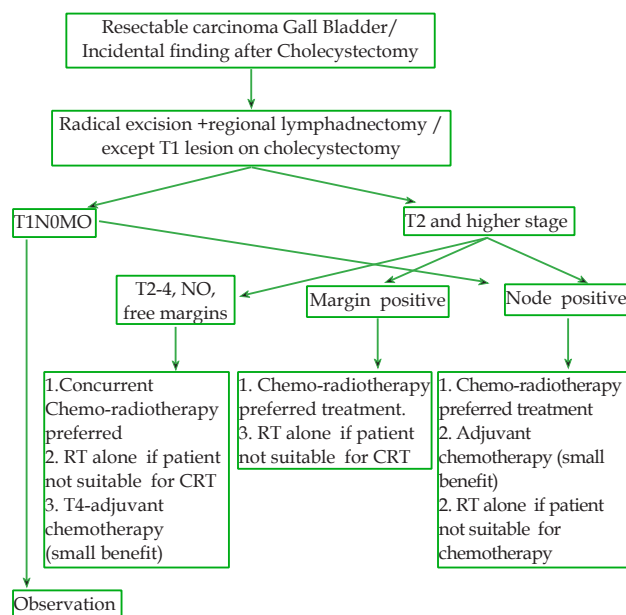


Figure 2 Flow chart depicting management and indications of adjuvant treatment for Resectable Gall Bladder carcinomas

Two-year survival was 80% and four-year survival 30%. SBRT has also been used in neoadjuvant setting before OLT, where a dose of 40 Gy in 5 sessions in given over 7-12 days has shown encouraging results^[67].

Targeted Therapies

BTC can be classified as collection of distinct disease that could be segregated both by anatomic location of tumor’s origin and underlying genetics. *KRAS* mutation appear to be common (approximately 40% to 50%) in IHCC as compared to GBC and EHCC whereas *ERBB2/HER2* amplifications are found in subsets of GBC^[68]. A number of novel inhibitors of key oncogenic pathways are in development and have been evaluated in BTCs as single agents, as combined targeted agents, and in combination with classic chemotherapy. Both small-molecule inhibitors of the kinase domain and blocking antibodies have been used in BTC^[69-70]. A randomized phase II study evaluating the impact of addition cetuximab to gemcitabine and oxaliplatin suggested benefit in terms of PFS at 4 months^[71]. Similarly another phase II study of sorafenib as a single agent in 36 treatment-naive patients reported an RR of 6%, median PFS of 2 months, and median OS of 6 month^[72]. In a single-arm phase II study, the efficacy and safety of bevacizumab, a humanized monoclonal antibody against VEGF, in combination with GEMOX in patients with advanced BTC was established^[73], 40% of patients had partial response, median OS was 12.7 months, and the median PFS was 7.0 months. Treatment was generally well tolerated, and grade 3 and 4 toxicities included neutropenia, elevation of transaminases, peripheral neuropathy, hypertension, anorexia, and thrombocytopenia. An interim report of a phase II study of bevacizumab in combination with erlotinib in 34 patients with CC and GBC observed a promising RR of 20% and a time to progression of more than 7 months^[70]. Combining targeted agents that inhibit different pathways critical to cancer growth and survival represents an attractive strategy and holds promise in future.

Our proposed guidelines for use of adjuvant therapy in carcinoma of the bile duct and GB cancer have been highlighted in table 9 and are depicted in figure 1 and 2. We also emphasis that it is of utmost importance to routinely incorporate patient related factors such as

age, performance status, general condition, pre-existing co-morbidity, financial constraints etc before decision of adjuvant therapy is considered.

REFERENCES

- Landis SH, Murray T, Bolden S, Wingo PA. Cancer statistics, 1998. *CA Cancer J Clin* 1998; 48: 6-29. [PMID: 9449931]; [DOI: 10.3322/canclin.48.1.6].
- DeOliveira ML, Cunningham SC, Cameron JL et al. Cholangiocarcinoma: thirty-one-year experience with 564 patients at a single institution. *Ann Surg* 2007; 245: 755. [PMID: 17457168]; [DOI: 10.1097/01.sla.0000251366.62632.d3].
- Patel T. Worldwide trends in mortality from biliary tract malignancies. *BMC Cancer* 2002; 2: 10. [PMID: 11991810]; [DOI: 10.1186/1471-2407-2-10]
- Jang JY, Kim SW, Park DJ, Ahn YJ, Yoon YS, Choi MG, Suh KS, Lee KU, Park YH. Actual Long-term Outcome of Extrahepatic Bile Duct Cancer After Surgical Resection. *Ann Surg* 2005; 241: 77-84. [PMID: 15621994]; [DOI: 10.1097/01.sla.0000150166.94732.88]
- Stain SC, Baer HU, Dennison AR, Blumgart LH. Current management of hilar cholangiocarcinoma. *SurgGynecol Obstet* 1992; 75: 579-588. [PMID: 1280374]
- de Groen PC, Gores GJ, LaRusso NF, Gunderson LL, Nagorney DM. Biliary tract cancers. *N Engl J Med*. 1999; 341: 1368-78. [PMID: 10536130]; [DOI: 10.1056/NEJM199910283411807]
- Hanna SS, Rider WD. Carcinoma of the gallbladder or extrahepatic bile ducts: The role of radiotherapy. *Can Med Assoc J* 1978; 118: 59-61. [PMID: 74280]
- Schoenthaler R, Phillips TL, Castro J, Efrid JT, Better A, Way LW. Carcinoma of the extrahepatic bile ducts: the University of California at San Francisco experience. *Ann Surg* 1994; 219: 267-274. [PMID: 8147607]
- Alden ME, Mohiuddin M. The impact of radiation dose in combined external beam and intraluminal Ir-192 brachytherapy for bile duct cancer. *Int J Radiat Oncol Biol Phys* 1994; 28: 945-51. [PMID: 8138448]; [DOI: 10.1016/0360-3016(94)90115-5]
- Alden ME, Waterman FM, Topham AK, Barbot DJ, Shapiro MJ, Mohiuddin M. Cholangiocarcinoma: Clinical significance of tumor location along the extrahepatic bile duct. *Radiology* 1995; 197: 511-516. [PMID: 7480704]; [DOI: 10.1148/radiology.197.2.7480704]
- Pitt HA, Nakeeb A, Abrams RA, Coleman J, Piantadosi S, Yeo CJ, Lillemore KD, Cameron JL. Perihilar cholangiocarcinoma: Postoperative radiotherapy does not improve survival. *Ann Surg* 1995; 221: 788-798. [PMID: 7794082]
- Kamada T, Saitou H, Takamura A, Nojima T, Okushiba SI. The role of radiotherapy in the management of extrahepatic bile duct cancer: An analysis of 145 consecutive patients treated with intraluminal and/or external beam radiotherapy. *Int J Radiat Oncol Biol Phys* 1996; 34: 767-74. [PMID: 8598352]; [DOI: org/10.1016/0360-3016(95)02132-9]
- Todoroki T, Ohara K, Kawamoto T, Koike N, Yoshida S, Kashiwagi H, Otsuka M, Fukao K. Benefits of adjuvant radiotherapy after radical resection of locally advanced main hepatic duct carcinoma. *Int J Radiat Oncol Biol Phys* 2000; 46: 581-587. [PMID: 10701737]; [DOI: org/10.1016/S0360-3016(99)00472-1]
- Heron DE, Stein DE, Eschelmann DJ, Topham AK, Waterman FM, Rosato EL, Alden M, Anne PR. Cholangiocarcinoma: The impact of tumor location and treatment strategy on outcome. *Am J Clin Oncol* 2003; 26: 422-428. [PMID: 12902899]; [DOI: 10.1097/01.COC.0000026833.73428.1F]
- Vern-Gross TZ, Shivnani AT, Chen K, Lee CM, Tward JD, MacDonald OK, Crane CH, Talamonti MS, Munoz LL, Small W Jr. Survival outcomes in resected extrahepatic cholangiocarcinoma: effect of adjuvant radiotherapy in a surveillance, epidemiology, and end results analysis. *Int. J. Radiation Oncology Biol. Phys.* 2011; 81: 189-198. [PMID: 20971573]; [DOI: 10.1016/j.ijrobp.2010.05.001]
- Shinohara ET, Mitra N, Guo M, Metz JM. Radiotherapy is associated with improved survival in adjuvant and palliative treatment of extrahepatic cholangiocarcinomas. *Int. J. Radiation Oncology Biol. Phys.* 2009; 74: 1191-1198. [PMID: 19201549]; [DOI: 10.1016/j.ijrobp.2008.09.017]
- Bonet Beltrán M, Allal AS, Gich I, Solé JM, Carrió I. Is adjuvant radiotherapy needed after curative resection of extrahepatic biliary tract cancers? A systematic review with a meta-analysis of observational studies. *Cancer Treatment Reviews* 2012; 38: 111-119. [PMID: 21652148]; [DOI: 10.1016/j.ctrv.2011.05.003]
- Kim S, Kim SW, Bang YJ, Heo DS, Ha SW. Role of postoperative radiotherapy in the management of extrahepatic bile duct cancer. *Int J Radiat Oncol Biol Phys* 2002; 54: 414-419. [PMID: 12243816]; [DOI: org/10.1016/S0360-3016(02)02952-8]
- Hughes MA, Frassica DA, Yeo CJ, Riall TS, Lillemoe KD, Cameron JL, Donehower RC, Laheru DA, Hruban RH, Abrams RA. Adjuvant concurrent chemoradiation for adenocarcinoma of the distal common bile duct. *Int J Radiat Oncol Biol Phys* 2007; 68: 178-182. [PMID: 17276614]; [DOI: 10.1016/j.ijrobp.2006.11.048]
- Nelson JW, Ghafoori AP, Willett CG, Tyler DS, Pappas TN, Clary BM, Hurwitz HI, Bendell JC, Morse MA, Clough RW, Czito BG. Concurrent chemoradiotherapy in resected extrahepatic cholangiocarcinoma. *Int J Radiat Oncol Biol Phys* 2009; 73(1): 148-53. [PMID: 18805651]; [DOI: 10.1016/j.ijrobp.2008.07.008]
- Borghero Y, Crane CH, Szklaruk J, Oyarzo M, Curley S, Pisters PW, Evans D, Abdalla EK, Thomas MB, Das P, Wistuba II, Krishnan S, Vauthey JN. Extrahepatic bile duct adenocarcinoma: Patients at high-risk for local recurrence treated with surgery and adjuvant chemoradiation have an equivalent overall survival to patients with standard-risk treated with surgery alone. *Ann Surg Oncol* 2008; 15: 3147-3156. [PMID: 18754070]; [DOI: 10.1245/s10434-008-9998-7]
- Park JH, Choi EK, Ahn SD, Lee SW, Song SY, Yoon SM, Kim YS, Lee YS, Lee SG, Hwang S, Lee YJ, Park KM, Kim TW, Chang HM, Lee JL, Kim JH. Postoperative chemoradiotherapy for extrahepatic bile duct cancer. *Int. J. Radiation Oncology Biol. Phys.* 2011; 79: 696-704. [PMID: 20510541]; [DOI: 10.1016/j.ijrobp.2009.12.031]
- Horgan AM, Amir E, Walter T, Knox JJ. Adjuvant Therapy in the Treatment of Biliary Tract Cancer: A Systematic Review and Meta-Analysis. *J Clin Oncol* 2012; 30: 1934-1940. [PMID: 22529261]; [DOI: 10.1200/JCO.2011.40.5381]
- Lim KH, Oh DY, Chie EK, Jang JY, Im SA, Kim TY, Kim SW, Ha SW, Bang YJ. Adjuvant concurrent chemoradiation therapy (CCRT) alone versus CCRT followed by adjuvant chemotherapy: Which is better in patients with radically resected extrahepatic biliary tract cancer?: a non-randomized, single center study. *BMC Cancer* 2009; 9: 345. [PMID: 19781103]; [DOI: 10.1186/1471-2407-9-345]
- Patel T. Increasing incidence and mortality of primary intrahepatic cholangiocarcinoma in the United States. *Hepatology* 2001; 33: 1353-1357. [PMID: 11391522]; [DOI: 10.1053/jhep.2001.25087]
- Lang H, Sotiropoulos GC, Fruhauf NR, Dömland M, Andreas Paul A, Kind E, Malagó M, Broelsch CE. Extended hepatectomy for intrahepatic cholangiocellular carcinoma (ICC): When is it worthwhile? Single center experience with 27 resections in 50 patients over a 5-year period. *Ann Surg* 2005; 241: 134-143. [PMID: 15622001]; [DOI: 10.1097/01.sla.0000149426.08580.a1]
- Washburn WK, Lewis WD and Jenkins RL. Aggressive surgical resection for cholangiocarcinoma. *Arch Surg.* 1995; 130: 270-276. [PMID: 7534059]; [DOI: 10.1001/archsurg.1995.01430030040006]
- Khan SA, Thomas HC, Davidson BR, Taylor-Robinson SD.

- Cholangiocarcinoma. *Lancet*. 2005; 366: 1303-1314. [PMID: 16214602]; [DOI: 10.1016/S0140-6736(05)67530-7]
29. Neuhaus P, Jonas S, Settmacher U, Thelen A, Benckert C, Lopez-Hänninen E, Hintze RE. Surgical management of proximal bile duct cancer: extended right lobe resection increases resectability and radicality. *Langenbecks Arch Surg*. 2003; 388: 194-200. [PMID: 12819970]; [DOI: 10.1007/s00423-003-0383-5]
 30. Anderson CD, Pinson CW, Berlin J, Chari RS. Diagnosis and treatment of cholangiocarcinoma. *Oncologist* 2004; 9: 43-57. [PMID: 14755014]
 31. Nakeeb A, Tran KQ, Black MJ, Erickson BA, Ritch PS, Quebbeman EJ, Wilson SD, Demeure MJ, Rilling WS, Dua KS, Pitt HA. Improved survival in resected biliary malignancies. *Surgery* 2002; 132: 555-64. [PMID: 12407338], [DOI: org/10.1067/msy.2002.127555]
 32. Morimoto Y, Tanaka Y, Ito T, Nakahara M, Nakaba H, Nishida T, Fujikawa M, Ito T, Yamamoto S, Kitagawa T. Long-term survival and prognostic factors in the surgical treatment for intrahepatic cholangiocarcinoma. *J Hepatobiliary Pancreat Surg* 2003; 10: 432-440. [PMID: 14714164]; [DOI: 10.1007/s00534-002-0842-3]
 33. Jarnagin WR, Shoup M. Surgical management of cholangiocarcinoma. *Semin Liver Dis* 2004; 24: 189-99. [PMID: 15192791]; [DOI: 10.1055/s-2004-828895]
 34. Stein DE, Heron DE, Rosato EL, Anné PR, Topham AK. Positive microscopic margins alter outcome in lymph node-negative cholangiocarcinoma when resection is combined with adjuvant radiotherapy. *Am J Clin Oncol* 2005; 28: 21-23. [PMID: 15685030]; [DOI: 10.1097/01.coc.0000139017.90599.f5]
 35. Cameron JL, Pitt HA, Zinner MJ, Kaufman SL, Coleman J. Management of proximal cholangiocarcinomas by surgical resection and radiotherapy. *Am J Surg* 1990; 159: 91-98. [PMID: 1688486]; [doi.org/10.1016/S0002-9610(05)80612-9]
 36. Shinohara ET, Mitra N, Guo M, Metz JM. Radiation therapy is associated with improved survival in the adjuvant and definitive treatment of intrahepatic cholangiocarcinoma. *Int. J. Radiation Oncology Biol. Phys.* 2008; 72: 1495-1501. [PMID: 18472359]; [DOI: 10.1016/j.ijrobp.2008.03.018]
 37. National Cancer Registry Programme. Two-year report of the Population Based Cancer Registries 1997-1998. New Delhi: Indian Council of Medical Research, 2002.
 38. Perpetuo MD, Valdivieso M, Heilbrun LK, Nelson RS, Connor T, Bodey GP. Natural history study of gallbladder cancer: a review of 36 years experience at M. D. Anderson Hospital and Tumor Institute. *Cancer* 1978; 42: 3. [PMID: 667804]
 39. Kiran RP, Pokala N, Dudrick SJ. Incidence pattern and survival for gallbladder cancer over three decades—an analysis of 10,301 patients. *Ann Surg Oncol* 2007; 14: 827. [PMID: 17109082]; [DOI: 10.1245/s10434-006-9224-4]
 40. Ogura Y, Mizumoto R, Isaji S, Kusuda T, Matsuda S, Tabata M. Radical operations for carcinoma of the gallbladder: present status in Japan. *World J Surg* 1991; 15: 337-43. [PMID: 1853612]
 41. Houry S, Schlienger M, Huguier M, Lacaine F, Penne F, Laugier A. Houry S, Schlienger M, Huguier M et al. Gallbladder carcinoma: Role of radiation therapy. *Br J Surg* 1989; 76: 448-450. [PMID: 2472186]; [DOI.org/10.1002/bjs.1800760508]
 42. Bosset JF, Manton G, Gillet M, Pelissier E, Boulenger M, Maingon P, Corbion O, Schraub S. Primary carcinoma of the gallbladder. Adjuvant postoperative external irradiation. *Cancer* 1989 64: 1843-1847. [PMID: 2790698]
 43. Mahe M, Stampfli C, Romestaing P, Salerno N, Gerard JP. Primary carcinoma of the gall-bladder: Potential for external radiation therapy. *Radiother Oncol* 1994; 33: 204-208. [PMID: 7536333]; [DOI.org/10.1016/0167-8140(94)90355-7]
 44. Kraybill WG, Lee H, Picus J, Ramachandran G, Lopez MJ, Kucik N, Myerson RJ. Multidisciplinary treatment of biliary tract cancers. *J Surg Oncol* 1994; 55: 239-245. [PMID: 8159005]
 45. Lindell G, Holmin T, Ewers SB, Tranberg KG, Stenram U, Ihse I. Extended operation with or without intraoperative (IORT) and external (EBRT) radiotherapy for gallbladder carcinoma. *Hepatogastroenterology* 2003; 50: 310-314. [PMID: 12749210]
 46. Mojica P, Smith D, Ellenhorn J. Adjuvant radiation therapy is associated with improved survival for gallbladder carcinoma with regional metastatic disease. *J Surg Oncol* 2007; 96: 8-13. [PMID: 17516546]; [DOI: 10.1002/jso.20831]
 47. Wang SJ, Fuller CD, Kim JS, Sittig DF, Thomas CR Jr, Ravdin PM. Prediction Model for Estimating the Survival Benefit of Adjuvant Radiotherapy for Gallbladder Cancer. *J Clin Oncol* 2008; 26: 2112-2117. [PMID: 18378567]; [DOI: 10.1200/JCO.2007.14.7934]
 48. Williams TM, Majithia L, Wang SJ, Thomas CR Jr. Defining the Role of Adjuvant Therapy: Cholangiocarcinoma and Gall Bladder Cancer. *Semin Radiat Oncol* 2014; 24: 94-104. [PMID: 24635866]; [DOI: 10.1016/j.semradonc.2014.01.001]
 49. Kresl JJ, Schild SE, Henning GT, Gunderson LL, Donohue J, Pitot H, Haddock MG, Nagorney D. Adjuvant external beam radiation therapy with concurrent chemotherapy in the management of gallbladder carcinoma. *Int J Radiat Oncol Biol Phys* 2002; 52: 167-175. [PMID: 11777635]; [DOI.org/10.1016/S0360-3016(01)01764-3]
 50. Czito BG, Hurwitz HI, Clough RW, Tyler DS, Morse MA, Clary BM, Pappas TN, Fernando NH, Willett CG. Adjuvant external-beam radiotherapy with concurrent chemotherapy after resection of primary gallbladder carcinoma: A 23-year experience. *Int J Radiat Oncol Biol Phys* 2005; 62: 1030-1034. [PMID: 15990005]; [DOI: 10.1016/j.ijrobp.2004.12.059]
 51. Gold DG, Miller RC, Haddock MG, Gunderson LL, Quevedo F, Donohue JH, Bhatia S, Nagorney DM. Adjuvant therapy for gallbladder carcinoma: the mayo clinic experience. *Int. J. Radiation Oncology Biol. Phys.* 2009; 75: 150-155. [PMID: 19297105]; [DOI: 10.1016/j.ijrobp.2008.10.052]
 52. Kim K, Chie EK, Jang JY, Kim SW, Han SW, Oh DY, Im SA, Kim TY, Bang YJ, Ha SW. Postoperative chemoradiotherapy for gallbladder cancer. *Strahlenther Onkol.* 2012; 188(5): 388-92. [PMID: 22402869]; [DOI: 10.1007/s00066-012-0074-7]
 53. Wang SJ, Lemieux A, Kalpathy-Cramer J, Ord CB, Walker GV, Fuller CD, Kim JS, Thomas CR Jr. Nomogram for Predicting the Benefit of Adjuvant Chemoradiotherapy for Resected Gallbladder Cancer. *J Clin Oncol* 2011; 29: 4627-4632. [PMID: 22067404]; [DOI: 10.1200/JCO.2010.33.8020]
 54. Takada T, Amano H, Yasuda H, Nimura Y, Matsushiro T, Kato H, Nagakawa T, Nakayama T. Is postoperative adjuvant chemotherapy useful for gallbladder carcinoma? A phase III multicenter prospective randomized controlled trial in patients with resected pancreaticobiliary carcinoma. *Cancer* 2002; 95: 1685-1695. [PMID: 12365016]; [DOI: 10.1002/cncr.10831]
 55. Makuuchi M, Thai BL, Takayasu K, Takayama T, Kosuge T, Gunvén P, Yamazaki S, Hasegawa H, Ozaki H. Preoperative portal embolization to increase safety of major hepatectomy for hilar bile duct carcinoma: a preliminary report. *Surgery* 1990; 107(5): 521-527. [PMID: 2333592]
 56. Kawasaki S, Imamura H, Kobayashi A, Noike T, Miwa S, Miyagawa S. Results of surgical resection for patients with hilar bile duct cancer: application of extended hepatectomy after biliary drainage and hemihepatic portal vein embolization. *Ann Surg* 2003; 238(1): 84-92. [PMID: 12832969]; [DOI: 10.1097/01.SLA.0000074984.83031.02]
 57. Ito F, Agni R, Rettammel RJ, Been MJ, Cho CS, Mahvi DM, Rikkers LF, Weber SM. Resection of hilar cholangiocarcinoma: concomitant liver resection decreases hepatic recurrence. *Ann Surg* 2008; 248(2) 273-279. [PMID: 18650638]; [DOI: 10.1097/SLA.0b013e31817f2bfd]
 58. Goldstein RM, Stone M, Tillery GW, Senzer N, Levy M, Husberg BS, Gonwa T, Klintmalm G. Is liver transplantation indicated for cholangiocarcinoma? *Am J Surg* 1993; 166: 768-771. [PMID:

- 8273866]; [DOI.org/10.1016/S0002-9610(05)80696-8]
59. Meyer CG, Penn I, James L. Liver transplantation for cholangiocarcinoma: results in 207 patients. *Transplantation*. 2000; 69(8): 1633-1637. [PMID: 10836374]
 60. Heimbach JK, Gores GJ, Nagorney DM, Rosen CB. Liver transplantation for perihilar cholangiocarcinoma after aggressive neoadjuvant therapy: a new paradigm for liver and biliary malignancies? *Surgery* 2006; 140: 331-334. [PMID: 16934588]; [DOI: 10.1016/j.surg.2006.01.010]
 61. Becker NS, Rodriguez JA, Barshes NR, O'Mahony CA, Goss JA, Aloia TA. Outcomes analysis for 280 patients with cholangiocarcinoma treated with liver transplantation over an 18-year period. *J Gastrointest Surg*. 2008; 12(1): 117-122. [PMID: 17963015]; [DOI: 10.1007/s11605-007-0335-4]
 62. Fuller CD, Dang ND, Wang SJ, Desai P, Choi M, Thomas CR Jr, Fuss M. Image-guided intensity-modulated radiotherapy (IG-IMRT) for biliary adenocarcinomas: initial clinical results. *Radiother Oncol* 2009; 92: 249-254. [PMID: 19324442]; [DOI: 10.1016/j.radonc.2009.02.015]
 63. Chang BK, Timmerman RD. Stereotactic body radiation therapy: a comprehensive review. *Am J Clin Oncol* 2007; 30: 637-44. [PMID: 18091059]; [DOI: 10.1097/COC.0b013e3180ca7cb1]
 64. Barney BM, Olivier KR, Miller RC, Haddock MG. Clinical outcomes and toxicity using Stereotactic Body Radiotherapy (SBRT) for advanced cholangiocarcinoma. *Radiat Oncol* 2012; 7: 67. [PMID: 22553982]; [DOI: 10.1186/1748-717X-7-67]
 65. Kopeck N, Holt MI, Hansen AT, Hoyer M. Stereotactic body radiotherapy for unresectable cholangiocarcinoma. *Radiother Oncol* 2010; 94(1): 47-52. [PMID: 19963295]; [DOI: 10.1016/j.radonc.2009.11.004]
 66. Polistina FA, Guglielmi R, Baiocchi C, Francescon P, Scalchi P, Febraro A, Costantin G, Ambrosino G. Chemoradiation treatment with gemcitabine plus stereotactic body radiotherapy for unresectable, non-metastatic, locally advanced hilar cholangiocarcinoma Results of a five year experience. *Radiotherapy and Oncology* 2011; 99: 120-123. [PMID: 21621289]; [DOI: 10.1016/j.radonc.2011.05.016]
 67. Hong JC, Jones CM, Duffy JP, Petrowsky H, Farmer DG, French S, Finn R, Durazo FA, Saab S, Tong MJ, Hiatt JR, Busuttil RW. Comparative Analysis of Resection and Liver Transplantation for Intrahepatic and Hilar Cholangiocarcinoma. *Arch Surg*. 2011; 146(6): 683-689. [PMID: 21690444]; [DOI: 10.1001/archsurg.2011.116]
 68. Hezel AF, Deshpande V, Zhu AX. Genetics of Biliary Tract Cancers and Emerging Targeted Therapies. *J Clin Oncol*: 2010; 28(21): 3531-3540. [PMID: 20547994]; [DOI: 10.1200/JCO.2009.27.4787]
 69. Paule B, Herelle MO, Rage E, Ducreux M, Adam R, Guettier C, Bralet MP. Cetuximab plus gemcitabine-oxaliplatin (GEMOX) in patients with refractory advanced intrahepatic cholangiocarcinomas. *Oncology* 2007; 72: 105-110. [PMID: 18025804]; [DOI: 10.1159/000111117]
 70. Lubner SJ, Mahoney MR, Kolesar JL, Loconte NK, Kim GP, Pitot HC, Philip PA, Picus J, Yong WP, Horvath L, Van Hazel G, Erlichman CE, Holen KD. Report of a multicenter phase II trial testing a combination of biweekly bevacizumab and daily erlotinib in patients unresectable biliary cancer: a phase II Consortium study. *J Clin Oncol* 2010; 28(21): 3491-7. [PMID: 20530271]; [DOI: 10.1200/JCO.2010.28.4075]
 71. Malka D, Trarbach T, Fartoux L, Mendiboune J, de la Fouchardière C, Viret F, Assenat E, Boucher E, Rosmorduc O, Greten T. A multicenter, randomized phase II trial of gemcitabine and oxaliplatin (GEMOX) alone or in combination with biweekly cetuximab in the first-line treatment of advanced biliary cancer: Interim analysis of the BINGO trial. *J Clin Oncol*. 2009; 27(suppl 15s): XXXX. abstr 4520. [DOI: 10.1200/JCO.2009.27.15S.4520]
 72. Bengala C, Bertolini F, Malavasi N, Boni C, Aitini E, Dealis C, Zironi S, Depenni R, Fontana A, Del Giovane C, Luppi G, Conte P. Sorafenib in patients with advanced biliary tract carcinoma: A phase II trial. *Br J Cancer* 2010; 102: 68-72. [PMID: 19935794]; [DOI: 10.1038/sj.bjc.6605458]
 73. Zhu AX, Meyerhardt JA, Blaszkowsky LS, Kambadakone AR, Muzikansky A, Zheng H, Clark JW, Abrams TA, Chan JA, Enzinger PC, Bhargava P, Kwak EL, Allen JN, Jain SR, Stuart K, Horgan K, Sheehan S, Fuchs CS, Ryan DP, Sahani DV. Efficacy and safety of gemcitabine, oxaliplatin, and bevacizumab in patients with advanced biliary tract cancers and correlation of FDG-PET changes with clinical outcome: A phase II study. *Lancet Oncol*. 2010; 11: 48-54. [PMID: 19932054]; [DOI: 10.1016/S1470-2045(09)70333-X]