

A Spontaneously Regressing Botryomycoma of the Tongue in A Young Boy With Down Syndrome

Daniel Satgé^{1,2}, Nicolas Bourdon³, Clotilde Mircher⁴

1 University Institute for Clinical Research, Biostatistics, Epidemiology and Public Health, EA2415 Cancer Team, Montpellier, France;

2 Oncodéfi, Montpellier, France;

3 Centre d'otologie, chirurgie de la face et du cou, Saint Brieux, France;

4 Institut Jérôme Lejeune, Paris, France.

Conflict-of-interest statement: The author(s) declare(s) that there is no conflict of interest regarding the publication of this paper.

Open-Access: This article is an open-access article which was selected by an in-house editor and fully peer-reviewed by external reviewers. It is distributed in accordance with the Creative Commons Attribution Non Commercial (CC BY-NC 4.0) license, which permits others to distribute, remix, adapt, build upon this work non-commercially, and license their derivative works on different terms, provided the original work is properly cited and the use is non-commercial. See: <http://creativecommons.org/licenses/by-nc/4.0/>

Correspondence to: Daniel Satgé MD, PhD, Director, ONCODEFI, 209 Avenue des apothicaires, 34090 Montpellier, France.

Email: daniel.satge@oncodefi.org

Telephone: +33(0)983548513

Received: December 3, 2019

Revised: December 20, 2019

Accepted: December 22, 2019

Published online: December 30, 2019

ABSTRACT

A 4 1/2-year-old boy with Down syndrome (DS) presented a tongue botryomycoma which recurred after complete surgical resection; then spontaneously regressed. Beside Riga-Fede disease reported in DS it is a first observation of a tongue botryomycoma in this genetic condition.

Key words: Down syndrome; Tongue; Botryomycoma; Pyogenic granuloma; Neoplasm regression spontaneous

© 2019 The Author(s). Published by ACT Publishing Group Ltd. All rights reserved.

Satgé D, Bourdon N, Mircher C. A Spontaneously Regressing Botryomycoma of the Tongue in A Young Boy With Down Syndrome. *Journal of Tumor* 2019; 7(1): 549-550 Available from: URL: <http://www.ghrnet.org/index.php/jt/article/view/2769>

CASE REPORT

A benign oral tumor may sometimes mimic a malignancy, particularly when it recurs after surgical excision. We report the first observation of botryomycoma (pyogenic granuloma) of the tongue in a young boy with Down syndrome (DS) which recurred after surgical resection and eventually spontaneously regressed.

A 4 1/2-year-old boy with DS presented an abnormal growth on the left side of its anterior tongue which appeared progressively in few weeks. The child was treated for mild hypothyroidism. He had experienced recurrent otitis and bronchitis. He was the second child of a family without particular history of cancer or benign tumors. The child had difficulties to eat and progressively avoided solid food. He also had difficulties to speak. A sharp tooth close to the abnormal growth was filled. The tumor was well limited, and sometimes bleeding. The surgical resection completely removed the whole tumor with a minimal histological margin of 0.5 cm of normal tissue. The 1.1 × 0.8 cm nodule had the aspect of a well-defined botryomycoma with capillary sized vessels in a loose and edematous stroma. The surface was partly ulcerated. There were no important nuclear anomalies and no excess of mitoses. Four months after resection the lesion rapidly recurred and reached a similar size as before its resection (Figure 1). Given the histological features indicating a benign probably reactive tumor, a wait and see policy was decided by the surgeon and parents. The lesion progressively disappeared, and did not recur 24 months after surgery. There remains only a slight white bulge (Figure 2). The child did not receive a particular medical treatment for his tumor or for another medical problem during this period.

Botryomycoma, so called pyogenic granuloma is a common vascular lesion occurring in children and adults, appearing mainly in the face and upper extremity. Pyogenic granuloma is a misnomer since the lesion is neither pyogenic nor granulomatous. It is a reactive like lesion which may arise following local irritation, traumatic injury, hormone effects or some medications in adults^[1]. A retrospective study found that only 15/202 (7.8%) botryomycoma occur in oral cavity, often on the gingiva and rarely on the tongue^[1].

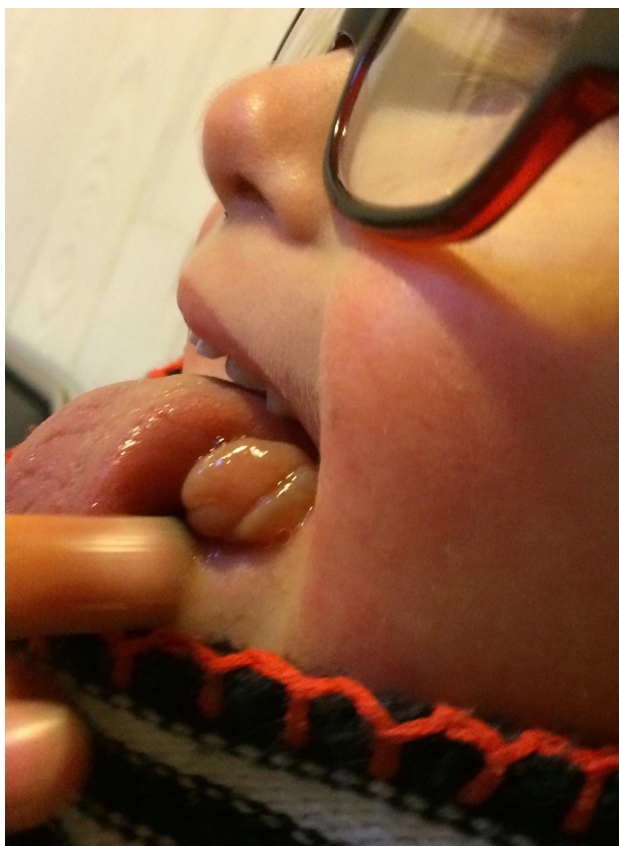


Figure 1 After surgery the recurring tumor had the same size as before resection.

The lesion is usually treated by surgical resection, cryotherapy, or desiccation after histological control^[1]. Botryomycoma may rarely spontaneously disappear. Usually the lesion is treated by surgical resection after histological control^[1].

Benign tumors of the tongue are rarely reported in children and adults with DS^[2]. A fibro-proliferative polyp with fibrous architecture different from a botryomycoma has been resected from the left border of a tongue in a young boy with DS^[3]. Three cases of Riga-Fede disease of the ventral tongue have been described in young children with DS^[4]. These traumatic reactive lesions with indurated well defined borders which contains many lymphocytes, macrophages, plasma cells and numerous eosinophils. Rega-Fede disease may disappear after removal of the traumatic cause, smoothening of incisor edges or covering dental edges with composite resin. Recurrence of a resected botryomycoma rarely occurs and must not be considered as the indication of a malignant process.

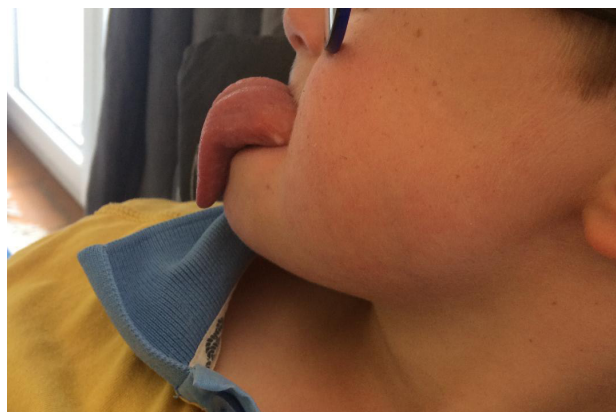

Figure 2 After spontaneous regression remains a small white bulge.

We are not aware of a previous report of a cutaneous or oral botryomycoma in an individual with DS^[5] and of other regressing malignant or benign solid tumors in DS^[5]. Although tumors of the tongue may be impressive in a young child with DS, they usually are of reactive nature and may spontaneously disappear. A histological control may be useful to discard a very unlikely malignant lesion.

A grant from the *Fondation Jérôme Lejeune* supports the study of tumors in Down syndrome.

ACKNOWLEDGMENTS

Authors acknowledge the parents of the boy who agreed for the publication and provided photos.

REFERENCES

1. Koo MG, Lee SH, Han SE. Pyogenic Granuloma: A Retrospective Analysis of Cases Treated Over a 10-Year. *Arch Craniofac Surg.* 2017;**18**:16-20. doi:10.7181/acfs.2017.18.1.16
2. Hennequin M, Faulks D, de Fréminville B, Delage-Corre M. Oral cancers and Down syndrome In : *Cancer in Children and Adults with Intellectual Disability*. Ed Daniel Satgé, Joav Merrick. Nova Sciences Publisher 2011; 185-190
3. Vargas SO, Perez-Atayde AR, Padwa BL, Springer KM. Immunosuppression-related fibroproliferative polyps of the tongue. *Pediatr Dev Pathol.* 2007;**10**:256-265
4. Polat Ekinçi A, Kılıç S, Babuna Kobaner G. Early-onset and persistent traumatic granuloma of the tongue (Riga-Fede disease) associated with neonatal teeth and Down syndrome. *J Eur Acad Dermatol Venereol.* 2019;**33**:e131-132. doi: 10.1111/jdv.15336
5. Satgé D, Sommelet D, Geneix A, Nishi M, Malet P, Vekemans MJ. A tumor profile in Down syndrome. *Am J Med Genet* 1998;**78**:207-216