

CASE REPORT

A Rare Case of Giant Cell Tumor of Bone with Thoracic Extension with Horner's Syndrome

Saswata Ghosh, Susmita Kundu, Saurav Kar, Palash Nandan Dhara

Saswata Ghosh, Susmita Kundu, Saurav Kar, Palash Nandan Dhara, Malda Medical College, Malda West Bengal, India

Correspondence to: Saswata Ghosh, Assistant Professor, Malda Medical College, Malda West Bengal, India

Email: drsaswata1969@gmail.com

Telephone: +91-9434197906

Received: May 8, 2014 Revised: June 17, 2014

Accepted: June 24, 2014

Published online: July 18, 2015

ABSTRACT

Giant-cell tumor of the bone (GCTOB) generally accounts for 4-5% of primary bone tumors and ~20% of benign bone tumors. It is characterized by the presence of multinucleated giant cells (osteoclast-like cells). Although classified as a benign tumor, GCTOB has been observed to metastasize to the lungs in up to 5% of cases. Patients usually present with pain and limited range of motion caused by tumor's proximity to the joint space. There may be swelling as well, if the tumor has been growing for a long time. Some patients may be asymptomatic until they develop a pathologic fracture at the site of the tumor. The symptoms may include muscular aches and pains in arms, legs and abdominal pain. Patients may also experience nerve pain which feels like an electric shock. In a population based study of Horner's syndrome in the pediatric age group, the incidence of Horner's syndrome was estimated to be 1.42 per 100 000 patients younger than 19 years, with a birth prevalence of 1 in 6250 for those with a congenital onset. We are presenting a case of a 27 year old male patient who presents with right sided chest pain and cough for 3 months and absence of perspiration of 2 months which was ultimately proved to be a case of Giant cell tumor of bone with thoracic extension with Horner's syndrome.

© 2015 ACT. All rights reserved.

Key words: Giant cell tumor of bone; Horner's syndrome

Ghosh S, Kundu S, Kar S, Dhara PN. A Rare Case of Giant Cell

Tumor of Bone with Thoracic Extension with Horner's Syndrome. *Journal of Tumor* 2015; 2(3): 320-322 Available from: URL: <http://www.ghrnet.org/index.php/JT/article/view/659>

INTRODUCTION

Giant cell tumors (GCT) are benign primary bone tumors that usually occur in the epiphysis of the long bones but rarely in the axial skeleton. They are found most commonly after skeletal maturity and show slight female predominance^[3].

Histologically, giant cell tumors consist of multinucleated osteoclastic giant cells in the stroma of spindle-shaped cells^[4]. Because giant cell tumors are typically aggressive locally, curettage can lead to a high rate of local recurrence. In the extremities, it has been reported that the combination of adjuvant therapy reduces the rate of local recurrence^[5-8]. When the spine is involved, these adjuvant therapies present the risk of postoperative complications because of the presence of major blood vessels and the spinal cord. Therefore, complete excision of giant cell tumors is generally considered to be the best treatment option. However, due to the difficulties of removing spinal tumors, complete resection is often not feasible for giant cell tumors, especially when they have expanded into the thoracic cavity.

The spinal axis is involved in 8-11% of GCTs and order of frequency in spine is sacral, thoracic, cervical and lumbar, so the majority of this tumor in spine is detected in sacrum.

In several large series, only 1-2% of GCTs occurred in the thoracic spine.

CASE HISTORY

A 27 year old male patient (Body length 1.55 meter, body weight 70 kg) from a suburban area of Kolkata, India came to us (on 23.4.2013) with the chief complaints of right sided chest pain and cough for 3 months and absence of perspiration on the right side of the body for 2 months. Right sided chest pain was both at the front and the back with insidious onset and gradually increasing severity, enough to disturb his sleep and day to day activities.

There was radiation of the pain along inner border of right arm and forearm. Cough was dry in nature with scanty mucoid expectoration and occasional nocturnal exacerbation. There was no episode of haemoptysis as well. Regarding family history, none of his family members have any history of neoplasm and there was no significant history of taking medications of his mother while she was pregnant. Regarding personal history, patient is non-smoker, non-alcoholic, farmer by occupation and not exposed to any chemical substance. On general survey, patient had grade 2 clubbing and no peripheral lymphadenopathy.

On examination of the respiratory system, dull percussion note on along right midclavicular line from 2nd Space downwards and diminished VBS on right infraclavicular, mammary and inframammary area were noted. Evidence of Horner's syndrome i.e. ptosis, miosis, anhidrosis, enophthalmos and loss of cilio-spinal reflex (Figure 1) was observed along with atrophy of right hypothenar eminence, diminished power of right biceps with exaggerated right elbow and wrist jerk. Blood report shows RBC 4.5 l/cu mm and WBC 8000/cu mm. His chest x-ray postero-anterior view (on 30.4.2013) showed homogenous opacity occupying upper and mid zone of right hemithorax (Figure 2) which was further been corroborated by his CT thorax images (Figure 3 A and B on 03.5.2013). CT guided fine needle aspiration cytology report (on 10.5.2013) showed acute on chronic organizing inflammation with epithelial atypia and giant cell reaction. Subsequently we went for tru-cut biopsy which revealed soft tissue extension of giant cell tumour of bone (on 20.5.2013). Detailed histopathology described that the Tumor was composed of round, oval or spindle shaped cells showing mild to moderate nuclear pleomorphism and diffusely distributed multinucleated osteoclast like giant cells (Figure 4). Immunohistochemistry (on 30.5.2013) shows that the tumour is cytonegative for cytokeratin, epithelial membrane antigen (EMA) and thyroid transcription factor-1 (TTF-1) (Figure 5). Patient was further referred to CTVS department where surgical excision of the tumor was done (on 14.6.2014) and post-operative radiotherapy was given (50 gy in 25 fractions i.e. 5days a week over 5 weeks). Patient is relatively stable and asymptomatic at present but features of Horner syndrome still persists.

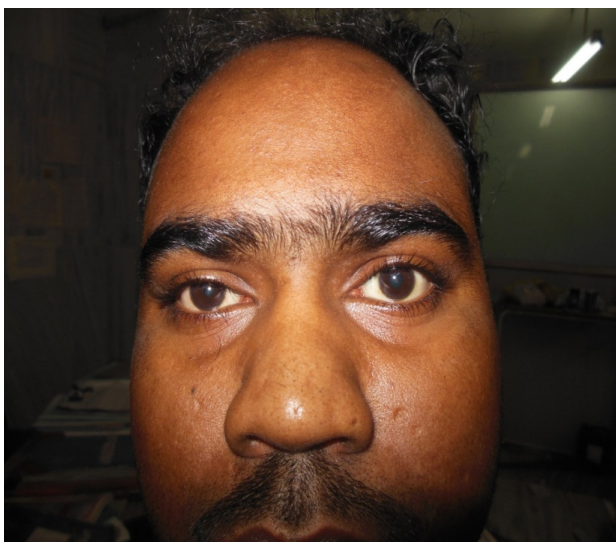

Figure 1 Features of Horner's Syndrome- Ptosis & Miosis of the Rt Eye.

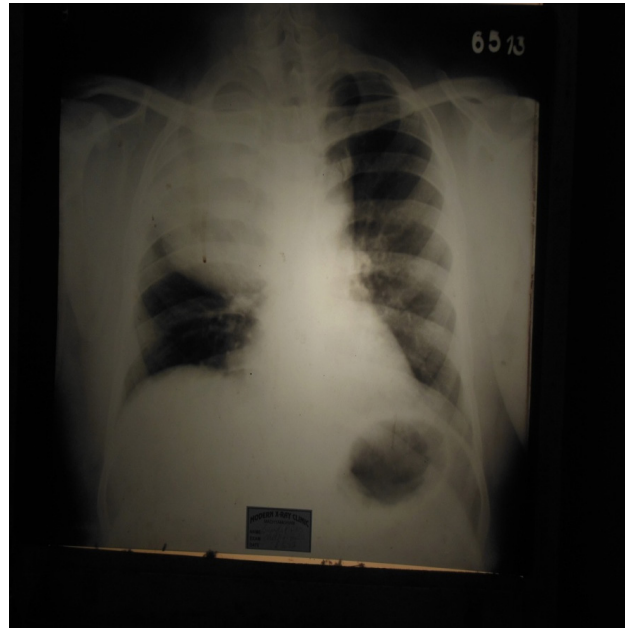

Figure 2 Chest x-ray PA view showed homogenous opacity occupying upper and mid zone of right hemithorax.

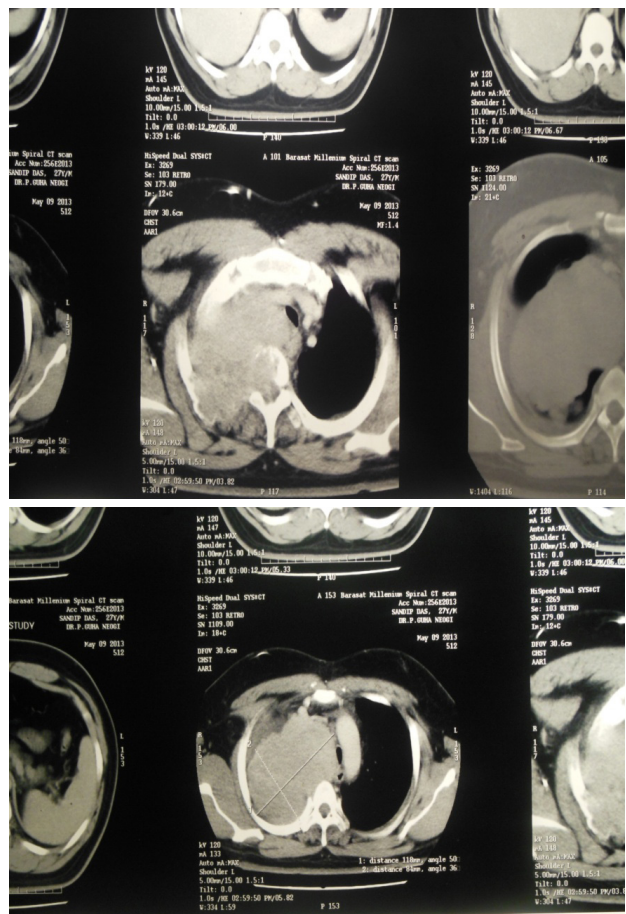


Figure 3 CT Scan of Thorax showing SOL in Right Lung with vertebral erosion.

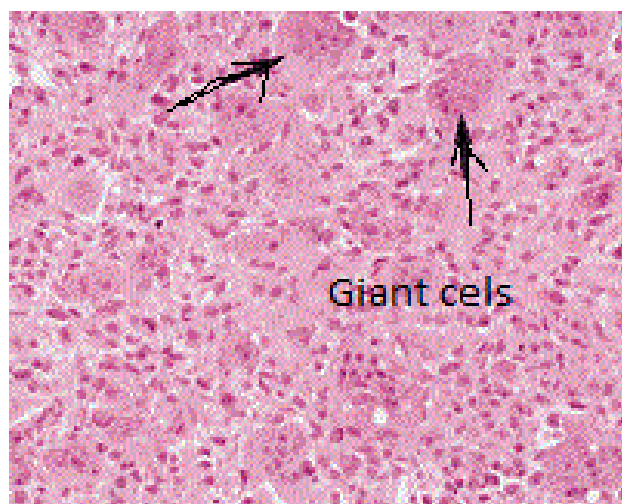


Figure 4 Histopathological slide showing Giant cells.

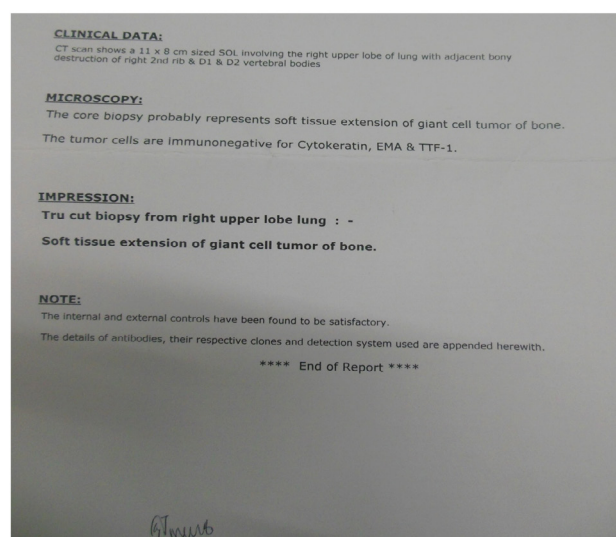


Figure 5 Immunohistochemistry report confirms the case as soft tissue extension of giant cell tumor of bone.

DISCUSSION

Horner's syndrome (also Horner syndrome, Bernard-Horner syndrome, Claude Bernard-Horner syndrome or as oculosympathetic palsy) is the combination of dropping of the eyelid (ptosis) and constriction of the pupil (miosis), sometimes accompanied by decreased sweating (anhidrosis) of the face on the same side; redness of the conjunctiva of the eye is often also present. Horner syndrome is acquired as a result of disease but may also be congenital (inborn) or iatrogenic (caused by medical treatment). Although most causes are relatively benign, Horner syndrome may reflect serious disease in the neck or chest such as a Pancoast tumor (tumor in the apex of the lung) or thyrocervical venous dilatation.

Due to lesion or compression of one side of the cervical or thoracic sympathetic chain, which generates symptoms on the ipsilateral (same side as lesion) side of the body.

Lateral medullary syndrome.

Cluster headache - combination termed Horton's headache.

Trauma-base of neck, usually blunt trauma, sometimes surgery.

Middle ear infection.

Tumors-often bronchogenic carcinoma of the superior fissure (Pancoast tumor) on apex of lung.

The diagnosis of giant cell tumors is based on biopsy findings. The key histomorphologic feature is, as the name of the entity suggests, (multinucleated) giant cells with up to a hundred nuclei that have prominent nucleoli. Surrounding mononuclear and small multinucleated cells have nuclei similar to those in the giant cells; this distinguishes the lesion from other osteogenic lesions which commonly have (benign) osteoclast-type giant cells.

But the thoracic extension of the giant-cell tumor of the bone is extremely rare and that presenting with Horner's syndrome is an extremely unusual condition.

CONFLICT OF INTERESTS

There are no conflicts of interest with regard to the present study.

REFERENCES

- Gamberi G, Serra M, Ragazzini P, Magagnoli G, Pazzaglia L, Ponticelli F, Ferrari C, Zanasi M, Bertoni F, Picci P, Benassi M. "Identification of markers of possible prognostic value in 57 giant-cell tumors of bone". *Oncol Rep* 2003; **10**(2): 351-356. PMID 12579271.
- Werner M. Giant cell tumour of bone: morphological, biological and histogenetical aspects. *Springer-Verlag* 2006; **30**: 484-489
- Pai SB, Lalitha RM, Prasad K, Rao SG, Harish K. "Giant cell tumor of the temporal bone-a case report". *BMC Ear Nose Throat Disord* 2005; **5**: 8. doi:10.1186/1472-6815-5-8. PMC 1253509. PMID 16162299
- Werner, M. Giant cell tumour of bone: morphological, biological and histogenetical aspects. *Springer-Verlag* 2006; **30**: 484-489
Huang I, Xu J, Wood DJ, Zheng MH. Gene Expression of Osteoprotegerin Ligand, Osteoprotegerin, and REceptor Activator of NF-kB in Giant Cell Tumor of Bone. *American Journal of Pathology* 2000; **156**(3): 761-767
- Thomas DM, Skubitz T. Giant-cell tumour of bone. *Current Opinion in Oncology* 2009; **21**: 338-344
- Werner M. Giant-cell tumour of bone: morphological, biological and histogenetical aspects. *Springer-Verlag* 2006; **30**, 484-489
- Wuelling M, Delling G, Kaiser E. The Origin of the Neoplastic Stromal Cell in Giant Cell Tumor of Bone. *Human Pathology* 2003; **34**: 983-993
- Murphy MD, Nomikos GC, Flemming DJ, Gannon FH, Temple HT, Kransdorf MJ. "From the archives of AFIP. Imaging of giant cell tumor and giant cell reparative granuloma of bone: radiologic-pathologic correlation". *Radiographics* 2001; **21**(5): 1283-309

Peer reviewers: Xuewu Zhang, Professor, College of Light Industry and Food Science, South China University of Technology, 381 Wushan Road, Guangzhou 510640, China; Ashraf K Khalil, Professor, Institute of Biotechnology & Genetic Engineering, City for Scientific Research & Technology Applications, Alexandria, 21934, Egypt.