

## Outcomes of Self-Expandable Metallic Stent Insertion on Acute Colorectal Obstruction: A Single Endoscopist Experience

Vitton Chinswangwatanakul, Chotirot Angkurawaranon, Chainarong Phalanusitthepha, Asada Methasate, Atthaphorn Trakarnsanga, Jirawat Swangsri, Thawatchai Akaraviputh

Vitton Chinswangwatanakul, Chotirot Angkurawaranon, Chainarong Phalanusitthepha, Asada Methasate, Atthaphorn Trakarnsanga, Jirawat Swangsri, Thawatchai Akaraviputh, Member of The Royal College of Surgeons of Thailand, Minimally Invasive Surgery Unit, Division of General Surgery, Department of Surgery, Faculty of Medicine Siriraj Hospital, Mahidol University, Bangkok, 10700, Thailand

Correspondence to: Thawatchai Akaraviputh, MD, Minimally Invasive Surgery Unit, Division of General Surgery, Department of Surgery, Faculty of Medicine Siriraj Hospital, Mahidol University, Bangkok, Thailand

Email: [thawatchai.aka@mahidol.ac.th](mailto:thawatchai.aka@mahidol.ac.th)

Telephone: +66-2419-8006 Fax: +66-2412-1370

Received: March 9, 2014 Revised: August 16, 2014

Accepted: August 20, 2014

Published online: October 12, 2014

### ABSTRACT

**AIM:** Self-expandable metallic stents (SEMS) have been widely used to relieve acute malignant colorectal obstruction. Many studies came from multiple centers or multiple endoscopists. The primary objective of this study is to evaluate oncologic outcomes of SEMS done by a single endoscopist.

**METHOD:** From January 2003 to December 2013, retrospective medical records reviewed a total of 123 patients who underwent colonoscopy with SEMS by a single surgeon's experience. Patients' clinicopathological data were analyzed.

**RESULTS:** The intent of the SEMS placement was for palliation 28.5% and for bridge-to-surgery 71.5%. The technical success was found in 120 patients (97.6%) and the clinical success was 118 patients (98.3%). Early and late complications occurred in 8 patients (6.5%) and 13 patients (10.5%) subsequently. Overall SEMS complications were 17%. Most common overall SEMS complications were stent migration (4.8%) and obstruction (4.1%).

**CONCLUSION:** SEMS is feasible and safe in the management of acute malignant colorectal obstruction with the advantage of relieving

obstruction, bridge to surgery, and acceptable complication rates. The good outcomes of SEMS can be dependable on the volume center.

© 2014 ACT. All rights reserved.

**Key words:** Self-expandable metallic stent (SEMS); Colorectal; obstruction; Complication; Technical success; Clinical success

Chinswangwatanakul V, Angkurawaranon C, Phalanusitthepha C, Methasate A, Trakarnsanga A, Swangsri J, Akaraviputh T. Outcomes of Self-Expandable Metallic Stent Insertion on Acute Colorectal Obstruction: A Single Endoscopist Experience. *Journal of Tumor* 2014; 2(9): 237-240 Available from: URL: <http://www.ghrnet.org/index.php/JT/article/view/872>

### INTRODUCTION

Colorectal cancer is a growing national concern. The high morbidity and mortality rate are often found in the patient with clinical colonic obstruction requiring emergency surgery<sup>[1]</sup>. Colonic stenting has been widely used for relieving acute colorectal obstruction while avoiding stoma formation in palliative cases, and to assist in bowel decompression and preparation as a bridge-to-surgery in resectable cases. Many studies revealed that the colonic stenting can prevent unnecessary stoma with low overall complications and mortality rates<sup>[2]</sup>.

At present, colonic stenting with Self-expandable metallic stents (SEMS) has been applied for both as a bridge-to-surgery and as a palliative intent in many Thai institutions. There are no previous reports with a high number of patients on the results of SEMS done by a single endoscopist. The objective of this study is to evaluate the outcomes of SEMS in acute colorectal obstruction done by a single endoscopist.

### METHODS

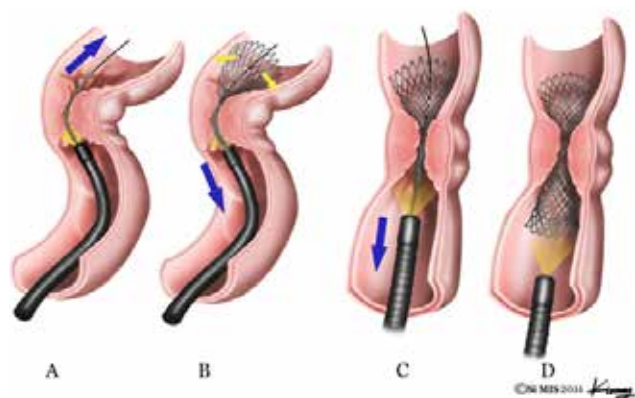
#### Patients

From January 2003 to December 2013, a total of 123 Thai patients

with acute colorectal obstruction underwent colonoscopy with SEMS placement by a single experienced endoscopic surgeon (T. A karaviputh). Patients' data and medical records were retrospectively reviewed. This study was approved by the Ethical Committee of Siriraj Institutional Review Board, Siriraj Hospital, Mahidol University. Table I summarizes the patients and tumor characteristics. The patients' co-morbidities were calculated according to the Charlson comorbidity index score (CCI)<sup>[2]</sup>. The colon and rectum cancer staging, margin status was according to the NCCN guidelines Version 4. 2013<sup>[3,4]</sup>. Acute colorectal obstruction was diagnosed clinically with typical signs and symptoms of acute colonic obstruction and radiologically via plain abdominal X-ray series, barium enema (BE), or computed tomography (CT) or diagnosed endoscopically prior to stent placement. The acute complications after stent placement were recorded as "early" if complications occurred within 7 days after stent deployment, and as "late" if they occurred more than 7 days after the deployment. The technical success was defined as achieving stent insertion and deployment at the obstructing site. The clinical success was defined as a relief of clinical colonic obstruction via flatus or defecation within 72 hours of stent placement without requiring additional procedure.

#### Techniques of colonic stent (SEMS) placement

All patients were monitored and sedated under anesthetic team. All stent procedures were performed by a single well-experienced surgeon (T. Akaraviputh) from the Minimally Invasive Surgery Unit, Department of Surgery, Siriraj Hospital, Mahidol University. Stents utilized for colonic decompression included WallFlex™ Colonic Stent (Boston Scientific, Natick, MA). Only un-covered stents were used. The endoscopy utilized was a one-channel therapeutic colonoscopy (CF-1T140L, Olympus Co., Japan). All procedures were performed under fluoroscopy guidance. The patients were placed in supine or left lateral decubitus position. The techniques of SEMS insertion composed of the following 4 steps (Figure 1). First step is passing guide wire through the obstruction via sphincterotome catheter with contrast injection to evaluate the obstructive lesion. The second step is application of SEMS through the scope over the guide wire and partial stent deployment up to 50% under fluoroscopy. The third step is pulling back the scope along with the stent until the fair part of the stent reaches the upper border of the tumor or pathologic lesion. The last step is fully deployment of the stent. Routine plain abdominal X-rays were performed within 24 hours after stent deployment.



**Figure 1** Technique of SEMS placement in acute colorectal obstruction. A: Passing stent and guide wire through lesion with contrast injection. B: Partial stent deployment. C: Pull back stent and scope until fair part of stent reach upper border. D: Fully deployment of SEMS.

#### Techniques of colonic stent (SEMS) placement

All patients were monitored and sedated under anesthetic team. All stent procedures were performed by a single well-experienced surgeon (T. Akaraviputh) from the Minimally Invasive Surgery Unit, Department of Surgery, Siriraj Hospital, Mahidol University. Stents utilized for colonic decompression included WallFlex™ Colonic Stent (Boston Scientific, Natick, MA). Only un-covered stents were used. The endoscopy utilized was a one-channel therapeutic colonoscopy (CF-1T140L, Olympus Co., Japan). All procedures were performed under fluoroscopy guidance. The patients were placed in supine or left lateral decubitus position. The techniques of SEMS insertion composed of the following 4 steps (Figure 1). First step is passing guide wire through the obstruction via sphincterotome catheter with contrast injection to evaluate the obstructive lesion. The second step is application of SEMS through the scope over the guide wire and partial stent deployment up to 50% under fluoroscopy. The third step is pulling back the scope along with the stent until the fair part of the stent reaches the upper border of the tumor or pathologic lesion. The last step is fully deployment of the stent. Routine plain abdominal X-rays were performed within 24 hours after stent deployment.

#### Statistical Analysis

Statistical analysis was performed using SPSS statistical software, version 18.0; SPSS, Inc., Chicago, IL, USA. For categorical variables, the Fisher's exact test was applied.

## RESULTS

A total of 123 patients underwent SEMS insertion. The patient and tumor demographic data are summarized in table 1. The majority of the obstructed lesion was malignant and located distal to the splenic flexure. Of the 123 patients who underwent SEMS placement, 3 patients (2.4%) failed to deploy and underwent immediate surgical procedures for relieving obstruction (Figure 2). The technical success rate was 97.6%, the opposite of the failure rate. The two patients with clinical stent failure underwent urgent laparotomy with open resection with end colostomy (Hartmann's operation). The overall SEMS complications occurred in 21 patients; 8 patients with early complications and 13 patients with late complications (Table 2). The majority of the complications that occurred were due to stent obstruction (5 patients, 4.1%) and stent migration (6 patients, 4.8%). The patients that had major perforations were preceded to emergency laparotomy and underwent open resection with end-colostomy (Hartmann's operation). The patients that had obstruction and stent migrations underwent re-endoscopic procedures with additional SEMS deployment. The patients who complained of severe pain/tenesmus from the stent had the stent removed.

The 30-day morbidity was stent related 16%, and non-stent related 0.8% (1 patient with bleeding from the tumor and developed acute renal failure). The 30 day morbidity was found only in non-stent related group 1.6% (2 patients; one developed septicemia from urinary tract infection and aspiration pneumonia).

## DISCUSSION

Since the introduction of colonic stents in application to relieve colonic obstruction in both a palliative and a bridge to surgery intent, many published systemic reviews and randomized control trials have acknowledged the usefulness of colonic stents<sup>[3-10]</sup>. This study, the technical and clinical success rates of SEMS (97.6% and 98.3%) were comparable to a comparative study by Kavanagh *et al*<sup>[11]</sup> and higher

Table 1 Patient and tumor demographic data.	
Patient and tumor characteristics (N=76)	Frequency (Percent)
Age (years)	Mean 68, range 15-108
Sex	
Male	67 (54.5)
Female	56 (45.5)
ASA class	
I	23 (18.7)
II	68 (55.3)
III	30 (24.4)
IV	2 (1.6)
Charlson Comorbidity Index (CCI)	
CCI score ≤ 3	71 (58.1)
CCI score 4-5	13 (10.5)
CCI score 6-7	34 (27.4)
CCI score ≥ 8	5 (4)
Disease Nature	
Malignant obstruction	117 (95.1)
Non-malignant obstruction	6 (4.9)
Type of operation	
Elective	59 (48)
Emergency	64 (52)
Intent of operation	
Palliative	35 (28.5)
Bridge to surgery	88 (71.5)
Clinical bowel obstruction	
Complete	61 (49.6)
Partial	58 (47.1)
None	4 (3.3)
Obstruction location	
Transverse colon	3 (2.4)
Splenic flexure	5 (4.1)
Descending	14 (11.4)
Descendosigmoid	5 (4.1)
Sigmoid	42 (34.1)
Rectosigmoid	29 (23.6)
Rectum	25 (20.3)
Tumor distance from anal verge (cm)	Mean 27, Range 3-85
Clinical tumor staging	
Stage I	16 (13)
Stage II	27 (23.6)
Stage III	54 (45.5)
Stage IV	20 (17.9)

Table 2 SEMS procedures and complications.	
SEMS procedures	Frequency (Percent)
Anesthetic type	
General anesthesia	71 (57.7)
Total intravenous anesthesia	52 (42.3)
Position deployment	
Supine	68 (55.3)
Lateral	55 (44.7)
Length of stent (mm)	Median, Range 60-120
SEMS procedure time (min)	Mean 31.4, Range 6-118
Technical stent failure	3 (2.4)
Clinical stent failure	2 (1.7)
SEMS complications	
Early complications (< 7 days)	8 (6.5)
Late complications (> 7 days)	13 (10.5)
Overall SEMS complications	21 (17%)
Early SEMS complications (<7days)	
Obstruction	1 (0.8)
Minor perforation	1 (0.8)
Major perforation	1 (0.8)
Migration	2 (1.6)
Pain/tenesmus	1 (0.8)
Cardiovascular/Pulmonary	2 (1.6)
Late SEMS complications (>7days)	
Bleeding	1 (0.8)
Obstruction	4 (3.3)
Migration	4 (3.3)
Minor perforation	1 (0.8)
Major perforation	1 (0.8)
Pulmonary/Cardiovascular	1 (0.8)
Fistula	1 (0.8)
Re-endoscopy	7 (5.7)
30-day morbidity	
Stent related	20 (16.2)
Non-stent related	1 (0.8)
30-day mortality	
Stent related	0
Non-stent related	2 (1.6)

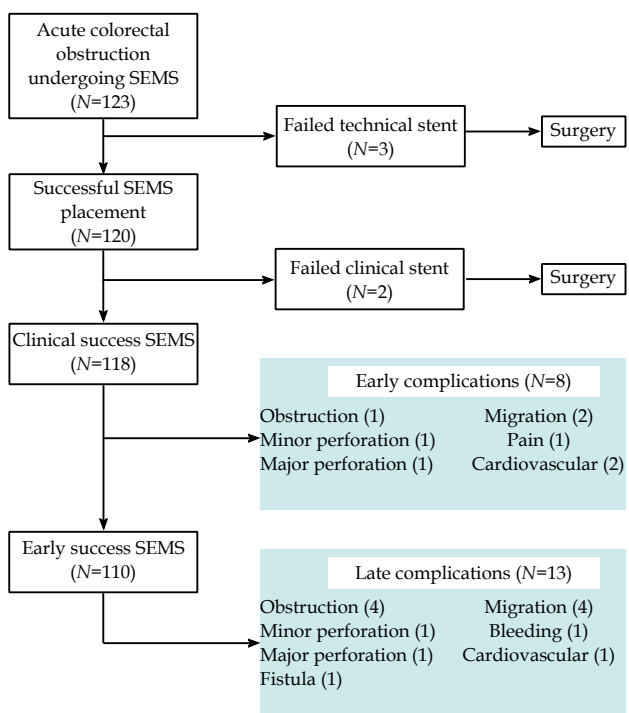


Figure 2 The results and management of acute colorectal obstruction with SEMS placement.

than the systematic reviews and meta-analysis by Cirrochi *et al*<sup>[12]</sup>, Tan *et al*<sup>[7]</sup>. All of the meta-analysis by Cirrochi *et al* which included 3 RCTs, Tan *et al* which included 4 RCTs and Cochrane review of 5 RCTs had considerably lower success rate, leading to the conclusion of a statistically significant higher clinical success rate in the emergency surgery group. Yet, with the low technical and clinical success rate, all the previous meta-analysis concurred with colonic stents seemed to be safe as emergency surgery with no statistically significant difference in morbidity, mortality, and overall complication rate.

The SEMS complications that occurred in our study were comparable to the Cochrane review. The SEMS migration rate and obstruction rate are higher than the Cochrane review (4.8% and 4.1 % respectively). However the total stent related perforation rate was less than Cochrane's review (3.2 vs 5.9 % respectively). The authors' study had a lower overall complication rate of 17% compared to the Cochrane stent group 39.2%. The lower complication rates may be attributable to the study design of a single surgeon's experience. According to the authors' results concur with other published meta-analysis stating that colonic stents seemed to be safe as emergency surgery with no statistically significant difference in morbidity, mortality, and overall complication rate.

## CONCLUSIONS

Colonic stents are established as an effective treatment of acute malignant colonic obstruction in both a palliative intent and as a bridge-to-surgery. The study confirms the efficacy and safety of the colonic SEMS placement with acceptable complications and low morbidity and mortality rates.

## CONFLICT OF INTERESTS

There are no conflicts of interest with regard to the present study.

## REFERENCES

- 1 Harris GJ, Senagore AJ, Lavery IC, Fazio VW. The management of neoplastic colorectal obstruction with colonic endoluminal stenting devices. *American journal of surgery* 2001 Jun; **181(6)**: 499-506. PubMed PMID: 11513773
- 2 Charlson ME, Pompei P, Ales KL, MacKenzie CR. A new method of classifying prognostic comorbidity in longitudinal studies: development and validation. *Journal of chronic diseases* 1987; **40(5)**: 373-83. PubMed PMID: 3558716
- 3 Targownik LE, Spiegel BM, Sack J, Hines OJ, Dulai GS, Gralnek IM, Farrell JJ. Colonic stent vs. emergency surgery for management of acute left-sided malignant colonic obstruction: a decision analysis. *Gastrointestinal endoscopy* 2004 Dec; **60(6)**: 865-74. PubMed PMID: 15604999
- 4 Khot UP, Lang AW, Murali K, Parker MC. Systematic review of the efficacy and safety of colorectal stents. *The British journal of surgery* 2002 Sep; **89(9)**: 1096-102. PubMed PMID: 12190673
- 5 Sebastian S, Johnston S, Geoghegan T, Torreggiani W, Buckley M. Pooled analysis of the efficacy and safety of self-expanding metal stenting in malignant colorectal obstruction. *The American journal of gastroenterology* 2004 Oct; **99(10)**: 2051-7. PubMed PMID: 15447772
- 6 Sagar J. Colorectal stents for the management of malignant colonic obstructions. *The Cochrane database of systematic reviews* 2011 (11):CD007378. PubMed PMID: 22071835.
- 7 Tan CJ, Dasari BV, Gardiner K. Systematic review and meta-analysis of randomized clinical trials of self-expanding metallic stents as a bridge to surgery versus emergency surgery for malignant left-sided large bowel obstruction. *The British journal of surgery* 2012 Apr; **99(4)**: 469-76. PubMed PMID: 22261931
- 8 Tilney HS, Lovegrove RE, Purkayastha S, Sains PS, Weston-Petrides GK, Darzi AW, Tekkis PP, Heriot AG. Comparison of colonic stenting and open surgery for malignant large bowel obstruction. *Surgical endoscopy* 2007 Feb; **21(2)**: 225-33. PubMed PMID: 17160651
- 9 Watt AM, Faragher IG, Griffin TT, Rieger NA, Maddern GJ. Self-expanding metallic stents for relieving malignant colorectal obstruction: a systematic review. *Annals of surgery* 2007 Jul; **246(1)**: 24-30. PubMed PMID: 17592286. Pubmed Central PMCID: 1899207
- 10 Zhang Y, Shi J, Shi B, Song CY, Xie WF, Chen YX. Self-expanding metallic stent as a bridge to surgery versus emergency surgery for obstructive colorectal cancer: a meta-analysis. *Surgical endoscopy* 2012 Jan; **26(1)**: 110-9. PubMed PMID: 21789642.
- 11 Kavanagh DO, Nolan B, Judge C, Hyland JM, Mulcahy HE, O'Connell PR, Winter DC, Doherty GA. A comparative study of short- and medium-term outcomes comparing emergent surgery and stenting as a bridge to surgery in patients with acute malignant colonic obstruction. *Diseases of the colon and rectum* 2013 Apr; **56(4)**: 433-40. PubMed PMID: 23478610
- 12 Ciocchi R, Farinella E, Trastulli S, Desiderio J, Listorti C, Boselli C, Parisi A, Noya G, Sagar J. Safety and efficacy of endoscopic colonic stenting as a bridge to surgery in the management of intestinal obstruction due to left colon and rectal cancer: a systematic review and meta-analysis. *Surgical oncology* 2013 Mar; **22(1)**: 14-21. PubMed PMID: 23183301

**Peer reviewers:** Wael Yassin Mansour, Lab. of Radiobiology & Experimental Radiooncology, Campus Sciences N27, Center of Oncology, University Medical Center Hamburg-Eppendorf, Martinistr. 52. 20246 Hamburg, Germany; Sun-Young Kong, MD&PhD, Department of Laboratory Medicine, National Cancer Center, Madu-1 dong, Goyang, Gyeonggido, 410-769, Korea.