

A Rare Adult Case with Neuroblastoma

George Imvrios, Dimitrios Filis, Ioannis Fouzas, Sofia Papadopoulou, Athanasios Kofinas, Eyaggelia Katsiki, Ioanna Dimitropoulou, Georgios Hahalís, Vasilios Papanikolaou

George Imvrios, Dimitrios Filis, Ioannis Fouzas, Sofia Papadopoulou, Athanasios Kofinas, Eyaggelia Katsiki, Ioanna Dimitropoulou, Georgios Hahalís, Vasilios Papanikolaou, Division of Transplantation, Department of Surgery, Aristotle University Medical School, Hippokraton General Hospital, Thessaloniki, Greece
Correspondence to: Dimitrios Filis, Division of Transplantation, Department of Surgery, Aristotle University Medical School, Hippokraton General Hospital, Thessaloniki, Greece
Email: dfilis@hotmail.com
Telephone: +6981456979
Received: June 13, 2014 Revised: October 19, 2014
Accepted: October 23, 2014
Published online: November 31, 2014

Key words: Neuroblastoma; Adults

Imvrios G, Filis D, Fouzas I, Papadopoulou S, Kofinas A, Katsiki E, Dimitropoulou I, Hahalís G, Papanikolaou V. A Rare Adult Case with Neuroblastoma. *Journal of Tumor* 2014; 2(10): 278-281 Available from: URL: <http://www.ghrnet.org/index.php/JT/article/view/956>

ABSTRACT

Introduction: Neuroblastoma (NB) is the most common extracranial solid tumor in early childhood. According to the international bibliography it constitutes the 7-10% of all pediatric cancers, whereas it rarely occurs in adults. This neoplasm originates in the neural crest and it mainly arises from the adrenal medulla. **Materials and Methods:** A 26-year-old female presented to our emergency department (ED) with a palpable abdominal mass as the chief complaint. The imaging tests (ultrasound, CT, MRI) revealed a large lesion in the right lumbar region, which was pushing the right kidney and the right hepatic lobe without infiltrating either of them. Moreover, the inferior vena cava was displaced and compressed. The patient underwent investigative laparotomy and mass excision. The ipsilateral adrenal gland was also removed. The following histopathological examination of the mass showed that the tumor was neuroblastoma. **Conclusion:** NB is an aggressive tumor of the sympathetic nervous system, as it can infiltrate the surrounding tissues and spread via lymphatic and hematogenous dissemination. Its treatment is based on the pediatric guidelines due to its rare appearance in adults. Surgical therapy is the preferable treatment for stage 1-2A patients, while chemotherapy and radiotherapy are usually given to stage 2B-3-4 patients.

INTRODUCTION

Neuroblastoma, the most common extracranial solid tumor in children, is considered to be a malignancy of early childhood^[1]. It constitutes 7-10% of all pediatric cancers, rarely occurring in adults^[1,2]. This tumor originates from the neural crest and mainly arises from the adrenergic cells in the adrenal medulla. The etiology of this tumor is unknown in most of cases, whereas only few cases are familial^[3]. Neuroblastoma may occasionally coexist with some other disorder of the neural crest, such as von Recklinghausen's disease, Hirschsprung's disease or neurofibromatosis^[4].

CASE REPORT

A 26-year-old female presented to the emergency department with a palpable abdominal mass and general symptoms, such as mild abdominal pain, fatigue, flatulence, nausea and vomiting. The clinical examination confirmed the presence of the mass and revealed abdominal sensibility. The blood test results were not outside the normal range (Hematocrit: 38%, White Blood Cells: 9.000/ μ L, Platelets: 290.000/ μ L, Na⁺: 137 mEq/L, K⁺: 3.8 mEq/L, Mg: 2.4 mEq/L, SGOT: 26 IU/L, SGPT: 17 IU/L, ALP: 46 U/L, GGT: 20 IU/L, URE: 28 mg/dL, CRE: 1 mg/dL). The tumor markers (Carcinoembryonic antigen/CEA, Carbohydrate antigen 19-9/CA 19-9, Alpha fetoprotein/AFP) were negative, whereas the bone marrow biopsy confirmed that the bone marrow was not infiltrated by tumor cells. The imaging tests (Ultrasound, CT and MRI scan) revealed a large (25-30 cm in diameter) lesion in the right lumbar region (Figure 1, 2), which was pushing the right kidney and the right hepatic lobe and displacing the compressed inferior vena cava. The CT angiography showed that the main nutrient vessel of the mass was the right renal artery (Figure 3, 4).

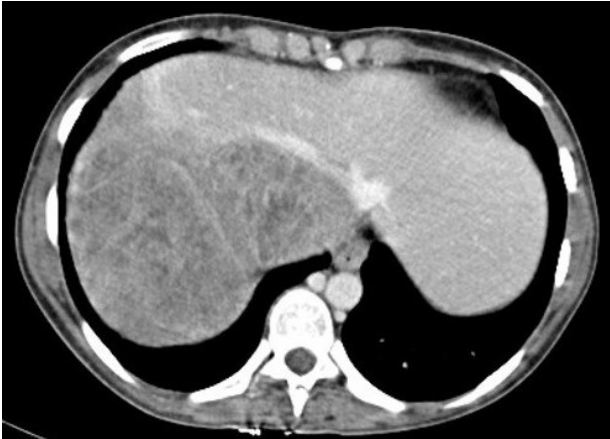

Figure 1 CT scan, axial plane. The mass compresses and displaces the right hepatic lobe and IVC.

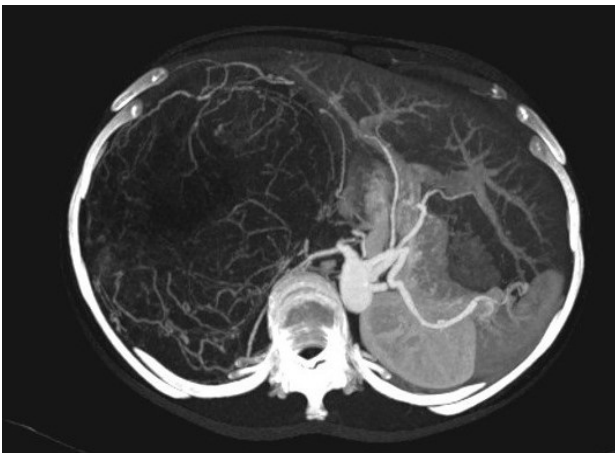


Figure 2 CT angiography, axial plane.

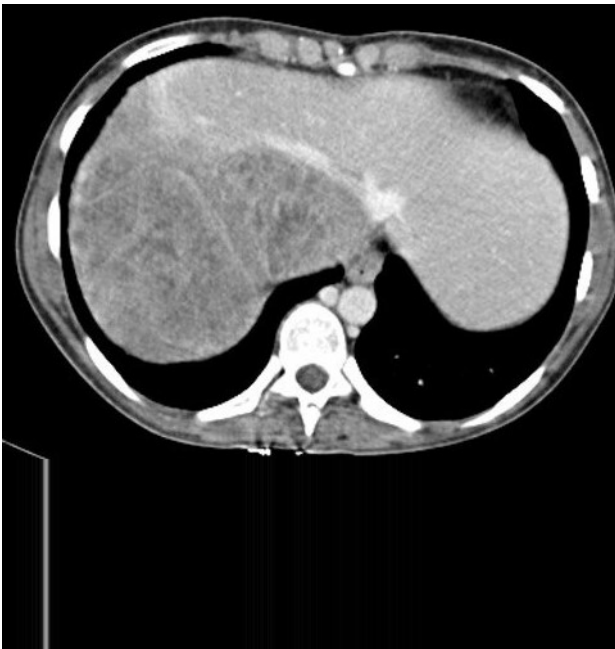

Figure 3 CT angiography, coronal plane. The main feeding vessel of the lesion is a branch of the right renal artery.

Subsequently, the patient underwent laparotomy. The tumor was pushing the descending part of the duodenum toward the midline and the upper pole of the kidney to the right iliac fossa. The right hepatic lobe and the inferior vena cava were also displaced, but neither of

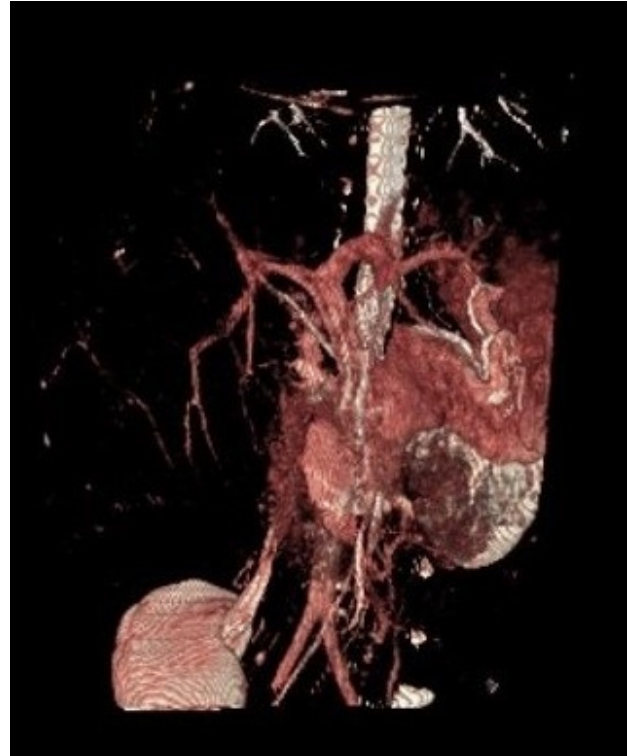


Figure 4 CT angiography, coronal plane, 3D reconstruction.

them was infiltrated. Eventually the mass and the ipsilateral adrenal gland were removed, while the lymph node dissection completed the surgery.

Grossly, the tumor measured 28×1,513 cm, was well circumscribed, nodular, with mainly firm and focally soft, fleshy consistency and white - gray and focally yellow - tan appearance. Microscopically the tumor was composed of sheets of small cells with hyperchromatic nuclei and scanty cytoplasm, arranged in a lobular pattern with abundant neuropil between the tumor cells. It's characterized by the presence of more than 5% and less than 10% of cells showing evidence of ganglionic differentiation (Figure 5). Necrosis was a rather constant feature. The tumor cells showed strong and diffuse immunoreactivity to NSE, chromogranin and synaptophysin.

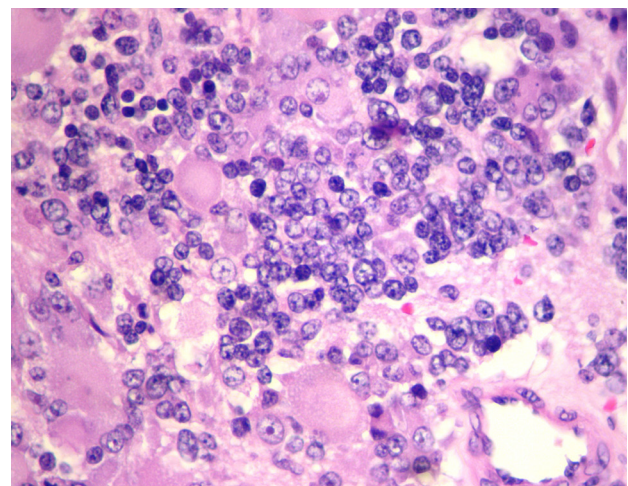


Figure 5 Tumor cells with ganglionic differentiation. (HE×400)

The diagnosis of stroma-poor neuroblastoma, differentiating was made. There was also a metastatic focus in a regional lymph node.

According to the International Neuroblastoma Pathology Classification (INPC) this tumor belongs to the differentiating neuroblastomata.

DISCUSSION

Neuroblastoma is a tumor of the sympathetic nervous system, originating in the sympathetic ganglia and the medullary region of the adrenal gland^[2,5,6]. This pediatric cancer occurs primarily in children under the age of 5 years and the female:male ratio is 1:1^[6]. It is extremely rare in adults with 60-70% of these cases usually diagnosed at an advanced stage, when the patient has already metastases^[6].

The symptoms of an adult with neuroblastoma don't differ from those of a child with neuroblastoma. The following examinations and their findings are similar among the younger and the older patients. The main difference is the prognosis, as the children have more possibilities to be diagnosed in a lower stage and survive. Concerning the treatment, there aren't guidelines for the management of the neuroblastoma in adults. So until today its treatment is based on the guidelines for the pediatric tumor.

The clinical symptoms of neuroblastoma vary depending on the location of the primary tumor and the extent of the metastases in other parts of the body. The compression of the surrounding organs due to the mass growth usually causes characteristic symptoms, such as spinal cord compression which leads to paralysis. As previously mentioned, metastases cause additional symptoms, such as periorbital ecchymosis (raccoon eyes), when the neuroblastoma has metastasized to the orbit. Fever, anemia, weight loss and fatigue are general warning signs that are less frequent^[3,6].

Neuroblastoma is known to be an aggressive tumor, as it has the tendency to infiltrate the surrounding tissues and spread via lymphatic and hematogenous dissemination. The bone marrow, the bones, the liver and the skin are the sites most prone to metastases. Metastases rarely occurs in the lungs or the brain^[7].

The diagnosis is based on a wide range of examinations. Urine tests can measure the urinary VMA (Vanillylmandelic acid), HVA (Homovanillic acid) and catecholamine levels (The neuroblastoma cells produce and release catecholamines)^[6,8,9]. Imaging tests are also important and include X-ray, ultrasound, CT and MIBG scan. Specifically, the abdominal X-ray shows non-specific findings, such as calcifications (dotted, amorphous) and displacement of the intestinal helixes or evidence of bone metastases, such as unclear boundaries, lytic lesions and pathological fractures. The abdominal ultrasound reveals the presence of cystic elements within the tumor as well as calcifications, while a pathognomonic feature is the presence of nodules, increased echogenicity and homogeneous composition. In abdominal CT scan findings, tumors with heterogeneous composition (necrotic, hemorrhagic and cystic components) are consistent with the presence of neuroblastoma^[3,10]. Calcifications occur at a rate of 80%^[10] and liver metastases can be observed in advanced stages due to diffuse infiltration (stage IV-S). Great diagnostic accuracy regarding the preoperative staging of the tumor is achieved through the 123-IMIBG, which highlights the fixation of the radiopharmaceutical in the primary intraventricular mass and the increased drug concentration in the metastatic foci^[3,11].

According to the international bibliography, this is the classification of neuroblastoma (Table 1)^[12].

Table 1 International neuroblastoma staging system

Stage	Description
1	Localized tumor. Complete excision with or without microscopic residual. Ipsilateral lymph nodes negative.
2A	Localized unilateral tumor .Incomplete gross excision. Ipsilateral lymph nodes negative.
2B	Localized unilateral tumor. Complete or incomplete excision. Ipsilateral and regional lymph nodes positive. Contralateral lymph nodes negative .
3	Unresectable unilateral tumor infiltrating across the midline with or without lymph node involvement. Unilateral tumor with contralateral lymph node involvement. Midline tumor with bilateral infiltration or bilateral lymph node involvement.
4	Dissemination of tumor to distant lymph nodes , bone, bone marrow, liver or other organs .
4S	Localized primary tumor in patients < 1 year with limited dissemination to liver, skin or bone marrow.

According to the international bibliography, the treatment of neuroblastoma is based on pediatric guidelines due to its rare appearance in adults.

The treatment of stage 1-2A patients is mainly surgical excision and close monitoring. In stage 2B tumors most writers suggest the surgery and the adjuvant chemotherapy as the treatment of choice, while some others believe that both preoperative and postoperative chemotherapy are needed. In advanced 3-4 stage tumors the preoperative chemotherapy is necessary^[3,6].

The prognosis of neuroblastoma is based on the spread of the tumor, the presence of metastases and the age of the patient. In general, almost 90% of the stage 1-2A patients have a good outcome. On the contrary the stage 4 patients have a poor prognosis^[13,14].

Our patient was in stage 2A according to the international bibliography, so she did not undergo postoperatively adjuvant chemotherapy. The 6-month follow-up (MRI and CT scan) hasn't detected recrudescence of neuroblastoma or secondary tumors.

CONCLUSION

Neuroblastoma is an extremely rare tumor in adulthood. However, it should be included in the differential diagnosis of the adrenal and all the hypernephroid tumors. Due to its more aggressive behavior compared to pediatric cancer and the absence of data regarding its management, we believe that an international record of incidents of neuroblastoma in adults is needed more than ever.

CONFLICT OF INTERESTS

There are no conflicts of interest with regard to the present study.

REFERENCES

- 1 Franks LM, Bollen A, Seeger RC, Stram DO, Matthay KK. Neuroblastoma in adults and adolescents: an indolent course with poor survival. *American Cancer Society* 1997;**79**: 2028-2035
- 2 Soares PBM, Filho SQ, Pereira de Souza W, Bonan PRF, Martelli-Junior H. Neuroblastoma in an adult: Case report. *Rev Med Chile* 2010; **138**: 1131-1134
- 3 Hallett A, Traunecker H. A review and update on neuroblastoma. *Paediatrics and Child Health* 2010; **22(3)**: 103-107
- 4 Clausen N, Andersson P, Tommerup N. Familial Occurrence of Neuroblastoma, Von Recklinghausen's Neurofibromatosis, Hirschsprung's Agangliosis and Jaw-winking Syndrome. *Acta Paediatrica* 1989; **78(5)**: 736-741
- 5 Yapanoglu T, Ozbey I, Aksou Y, Gursan N, Polat O. Neuroblas-

- toma in Adulthood. *Turk J Med Sci* 2008; **38(3)**: 281-283
- 6 Simpson JK, Gaze MN. Current Management of Neuroblastoma. *The oncologist* 1998; **3**: 253-262
 - 7 Kaye JA, Warhol MJ, Kretschmar C, Landsberg L, Frei E 3rd. Neuroblastoma in adults. Three case reports and a review of the literature. *Cancer* 1986; **58(5)**: 1149-1157
 - 8 Reynolds CP, German DC, Weinberg AG, Smith RG. Catecholamine fluorescence and tissue culture morphology. Technics in the diagnosis of neuroblastoma. *AM J Clin Pathol* 1981; **75(3)**: 275-82
 - 9 Tuchman M, Ramnaraine MLR, Woods WG, Krivit W. Three Years of Experience With Random Urinary Homovanillic and Vanillylmandelic. Acid Levels in the Diagnosis of Neuroblastoma. American Academy of Pediatrics
 - 10 Stark DD, Moss AA, Brasch RC, Lorimier AA, Albin AR, London DA, Gooding CA. Neuroblastoma: diagnostic imaging and staging. *Radiology* 1983, Volume 148, Issue 1
 - 11 Bousvaros A, Kirks DR, Grossman H. Imaging of neuroblastoma: an overview, *Pediatric Radiology* 1986; **16(2)**: 89-106
 - 12 Henry MC, Tashjian DB, Breuer CK. Neuroblastoma update. *Curr Opin Oncol* 2005; **17(1)**: 19-23
 - 13 Weinstein JL, Katzenstein HM, Cohn SL. Advances in the diagnosis and treatment of neuroblastoma. *Oncologist* 2003; **8**: 278-292
 - 14 Kumar V, Abbas AK, Fausto N, Robbins RM. Basic Pathology, Eighth Edition, Chapter 7, Pages 268-270
- Peer reviewers:** Jordi Bruna, Hospital Universitari Bellvitge-ICO Duran i Reynals, Unit of Neuro-Oncology, department of Neurology, Feixa Llarga s/n 08907, Hopsitalet. Barcelona. Spain; Aman Sharma, Attending Consultant, Department of Radiation Oncology, Fortis Memorial Research Institute, Sector 44, Gurgaon, Haryana, 122002 India.