

## Hematological Profiles During Acute and Subacute Brucellosis in Sprague-Dawley Rats Experimentally Infected with *B. abortus* biotype 1

Mst. Minara Khatun, Md. Ariful Islam, Byeong-Kirl Baek

Mst. Minara Khatun, Md. Ariful Islam, Byeong-Kirl Baek, Department of Veterinary Public Health, College of Veterinary Medicine, Chonbuk National University, Jeonju, Republic of Korea

Mst. Minara Khatun, Md. Ariful Islam, Department of Microbiology and Hygiene, Faculty of Veterinary Science, Bangladesh Agricultural University, Mymensingh, Bangladesh

Correspondence to: Mst. Minara Khatun, Department of Microbiology and Hygiene, Faculty of Veterinary Science, Bangladesh Agricultural University, Mymensingh-2202, Bangladesh.

Email: [mmkhatun@bau.edu.bd](mailto:mmkhatun@bau.edu.bd)

Telephone: +88-091-67401-6 ext. 6396

Fax: +88-091-61510

Received: May 5, 2016

Revised: June 24, 2016

Accepted: June 27, 2016

Published online: September 20, 2016

### ABSTRACT

**AIM:** The aim of this study was to assess the hematological abnormalities such as anemia, leucopenia and thrombocytopenia of Sprague-Dawley (SD) rats during the course of infection.

**METHODS:** The SD rats were experimentally infected ip with *B. abortus* biotype 1 with  $1 \times 10^9$  colony forming unit (CFU)/ml. Blood samples were collected from the rats at 0, 3, 7, 14, 21, 28, 35, 42, 60, 90 and 120 days, after infection. Hematological analysis of the blood samples were performed using an automated blood analyzer. Blood films were prepared on a microscopic slide using blood samples obtained from the uninfected control, acutely and subacutely infected SD rats. Thin blood films were stained with Wright-Giemsastain and examined under light microscope (Olympus, BX51) for observing the hematological changes at 1000X magnification.

**RESULTS:** Hematological analysis revealed significant decrease of WBC, RBC, HGB, HCT and PLT in the infected rats, compared

to uninfected control rats ( $p < 0.05$ ). The blood film of acutely infected rats was characterized by abnormal red blood cells with infiltration of macrophages. Blood film of sub-acutely infected rats was characterized by abnormally shaped red blood cells with infiltration of lymphocytes and macrophages. Blood film of uninfected control rats showed normal shape of red blood cells with very few infiltrations by neutrophils. All of the rats infected with *B. abortus* during acute and subacute infection manifested splenomegaly. The highest spleen weights were recorded ( $2.25 \pm 0.12$  g) at 21 days after infection ( $p < 0.001$ ).

**CONCLUSION:** *B. abortus* induced hematological changes in SD rats during the acute and subacute stages of infection that could be useful for diagnosis of brucellosis in the free ranging wild rats.

**Key words:** Hematological profile; *Brucella abortus*; SD rats; Acute and subacute stage

© 2016 The Authors. Published by ACT Publishing Group Ltd.

Khatun MM, Islam MA, Baek BK. Hematological Profiles During Acute and Subacute Brucellosis in Sprague-Dawley Rats Experimentally Infected with *B. abortus* biotype 1. *International Journal of Hematology Research* 2016; 2(3): 143-148 Available from: URL: <http://www.ghrnet.org/index.php/ijhr/article/view/1710>

### INTRODUCTION

Brucellosis is a zoonotic disease, caused by the several species of the genus *Brucella* and constitutes an important public health problem in many parts of the world<sup>[1]</sup>. The disease is transmitted to animals through ingestion of aborted materials, artificial insemination with contaminated semen<sup>[2]</sup> and natural breeding with infected bulls<sup>[3]</sup>. Humans can be infected with *Brucella* by contact with infected animals and drinking of unpasteurized milk and milk products<sup>[4]</sup>. Brucellosis in wildlife is the most likely source of infection for

humans as well as domesticated animals<sup>[5]</sup>. Rats are found to be carriers of *Brucella abortus* in many parts of the world<sup>[6,7]</sup>. Brucellosis is a multisystemic disease with a broad spectrum of clinical manifestations<sup>[8]</sup>. Brucellosis is an inflammatory disease that can affect all organs or systems in the body<sup>[9]</sup>. The disease also produces a variety of nonspecific hematological abnormalities. Bonemarrow and the spleen are commonly involved and such involvement may result in a hypoplastic pattern in the peripheral blood smear<sup>[10]</sup>. Reproductive failure, infertility and abortion are the main clinical manifestations of brucellosis in domesticated animals. Undulant fever, loss of weight, weakness, malaise and sweating are the common clinical symptoms of brucellosis in human patients. Hematological abnormalities including anemia, leucopenia, thrombocytopenia and pancytopenia can be encountered during the course of brucellosis<sup>[11]</sup>.

Brucellosis is an infectious disease involving the lymphoproliferative system. Changes in the hematological parameters are observed in most patients, but pancytopenia is rare. Hemophagocytosis, hypersplenisms or granulomatous changes in the bone marrow may be responsible for pancytopenia occurring during brucellosis<sup>[12]</sup>. Additionally, bone marrow involvement due to simultaneous presentation of malignant diseases with brucellosis rarely leads to pancytopenia. Reports of hematological abnormalities in brucellosis have arisen from studies in humans. There are no reports concerning hematological abnormalities in rats infected with *B. abortus*.

## MATERIALS AND METHODS

### Experimental animals

Adult SD rats ( $n = 40$ ) of 8-weeks of age were purchased from a SPF commercial company (Koatech, Korea). The rats were kept in cages in an isolated animal experimental house and supplied with food and water *ad libitum*. The rats were handled according to the guidelines of the Chonbuk National University. All rats were free from *Brucella* or abnormalities before experiment.

### Experimental infection

The SD rats ( $n = 36$ ) were intraperitoneally inoculated with 0.1 mL saline solution containing  $1 \times 10^9$  colony forming unit (CFU) of *B. abortus* biotype 1. The control rats ( $n = 4$ ) were kept uninfected.

### Clinical examination

The rectal temperature, food and water intake of the experimentally infected rats were recorded daily until two weeks of experimental infection.

### Specimen collection

Specimens of blood and tissues were collected from the rats at 0, 3, 7, 14, 21, 28, 35, 42, 60, 90 and 120 days after infection. Blood samples were collected from the rats with or without anticoagulant, through aseptical cardiac puncture, under general anesthesia induced by intraperitoneal administration of 10mg/ml Zoletil. Then the rats were euthanized and specimens of spleen were collected aseptically. Spleens were weighted by an electronic balance (Tokyo, Japan) and observed for spleen enlargement.

### Hematological examination

Blood samples, collected at 0, 3, 7, 14, 21, 28, 35, 42, 60, 90 and 120 days after infection, were analyzed by an automated blood counter (ABX Vet ABC Hematology Analyzer, USA). The total white blood cells (WBC), red blood cell (RBC), hemoglobin (HGB), platelets

(PLT) and hematocrit (HCT) levels of the blood samples were measured.

### Examination of blood films

Blood films were prepared on a microscopic slide, using blood samples obtained from the uninfected control, acutely and subacutely infected SD rats. Thin bloods films were stained with Wright-Giemsa stain, according to the standard protocol. Briefly, air-dried blood films on microscope slides were fixed in absolute methanol for at least 5 min. Staining solution I (0.3 g of Wright stain powder was dissolved in 100 mL absolute methanol) was applied for 2 min on the horizontally positioned slides. The slides were rinsed with distilled water for 30 seconds and air-dried. Staining solution II (1 g Giemsa stain powder was dissolved in 66 ml glycerol and heated to 56°C for 90 to 120 min. After addition of 66 mL absolute methanol and thorough mixing, the solution was left at room temperature in a closed container) was applied on the horizontally positioned slides for 5 min. Then the slides were rinsed with ample amounts of water and dried in air. Finally, cover glasses were mounted on the areas of stained blood film. The stained blood films were examined under light microscope (Olympus, BX51) for observing the hematological changes at 1000× magnification.

### Statistical analysis

Hematological parameters (WBC, PLT, RBC, HCT, HGB value) and spleen weight data between infected and uninfected control rats were analyzed for statistical significance by the Student t test, using Microsoft Excel 2000. Significance of all the analyses was established at  $p$  value of  $< 0.05$ .

## RESULTS

### Clinical Examination

The infected rats manifested fever, anorexia and weakness. The highest rectal temperature were recorded as  $38 \pm 0.5^\circ\text{C}$  at 3 days after infection. The rectal temperature as well as food and water intake of infected rats became normalized two weeks after infection.

### Hematological findings

**Total leukocyte count and platelet counts:** During the acute course of infection the total WBC counts of the infected rats were either increased or decreased, as compared to the uninfected control rats. The statistically significant increase ( $p < 0.05$ ) of mean WBC counts was recorded at 14 days after infection ( $8.25 \pm 0.5 \times 10^3/\text{mm}^3$ ). The highest mean value of WBC count was recorded at 21 days after infection ( $8.35 \pm 0.44 \times 10^3/\text{mm}^3$ ) ( $p < 0.001$ ). The mean value of WBC count sharply declined at 28 days after infection ( $4.65 \pm 0.99 \times 10^3/\text{mm}^3$ ) ( $p < 0.05$ ) and the mean WBC counts remained almost same level at 35 and 42 days after infection ( $4.12 \pm 0.85$  and  $4.02 \pm 1.8 \times 10^3/\text{mm}^3$ , respectively). A second decrease of the mean WBC counts was recorded at 60 days after infection and the value gradually decreased at 90 and 120 days after infection ( $2 \pm 0.4$  and  $1.75 \pm 0.26 \times 10^3/\text{mm}^3$ , respectively) ( $p < 0.001$ ).

Platelet counts started decreasing from 3 days after infection as compared to uninfected control rats. Decreased platelets counts were also recorded at 7 and 14 days after infection ( $517 \pm 77.08$  and  $511.75 \pm 88.5 \times 10^3/\text{mm}^3$ , respectively) that were not statistically significant. However, at 21 days after infection platelet counts ( $475 \pm 23.8 \times 10^3/\text{mm}^3$ ) decreased significantly ( $p < 0.05$ ) as compared to uninfected control rats. A sharp decline of platelet counts were recorded at 28 days after infection. The platelet counts decreased significantly ( $p <$

0.001) from 28 days after infection until the end of the experiment. The results of total WBC and PLT counts are presented in Figure 1.

**Total RBC counts:** The RBC counts of infected rats at 3 and 7 days were almost similar, as compared to uninfected control rats. A significant decrease of RBC counts was recorded at 14 days ( $6.27 \pm 0.6 \times 10^3/\text{mm}^3$ ), after infection ( $p < 0.05$ ), as compared to uninfected control rats. The RBC counts at 21, 28 and 35 days after infection were recorded as  $5.51 \pm 0.61$ ,  $5.46 \pm 0.86$  and  $5.02 \pm 0.95 \times 10^3/\text{mm}^3$ , respectively. At 42, 60, 90 and 120 days after infection, the RBC counts ( $4.99 \pm 1.17$ ,  $4.76 \pm 1.33$ ,  $4.57 \pm 1.34$  and  $3.85 \pm 1.63 \times 10^3/\text{mm}^3$ , respectively) were found to be significantly decreased ( $p < 0.001$ ), when compared to the uninfected control rats (Figure 2).

**Hematocrit count:** The hematocrit value decreased significantly at 7 days (45.6%) after infection ( $p < 0.001$ ), when compared to the uninfected control rats. A sharp decrease of hematocrit value was recorded at 14 days after infection (40.4 %). The hematocrit values remained almost same level from 21 days (36.6%) to 60 days (34.8%) after infection. Then the hematocrit values gradually decreased from 90 days (33.7 %) to 120 days (28.7%) after infection. The hematocrit values of SD rats are presented in Figure 3.

### Hemoglobin concentration

Statistically significant decrease of hemoglobin concentration was noted at 7 days after infection ( $16.12 \pm 0.22$  g/dL) ( $p < 0.05$ ), as compared to the uninfected control rats. Then the mean hemoglobin concentration gradually decreased and attained the following levels at 14, 21 and 28 days after infection;  $13.9 \pm 0.12$  and  $13.92 \pm 0.09$ ,  $13.1 \pm 1.14$  g/dL, respectively. The mean hemoglobin concentrations decreased significantly at 35 days after infection ( $11.27 \pm 0.63$  g/dL) ( $p < 0.001$ ). In the infected rats the mean hemoglobin concentration continued to decrease from 35 days to 120 days after infection (Figure 4).

### The results of blood film examinations

Blood film of acutely infected rat at 21 days after infection with *B. abortus* showed abnormal shapes of the red blood cells with extensive to moderate infiltration of inflammatory cells such as lymphocytes, neutrophils and macrophages. Blood film prepared from the rat during subacute infection at 90 days after infection with *B. abortus*, manifested moderate to diffuse infiltration of lymphocytes, macrophages as well as neutrophils. The blood films results from Wright-Giemsa stain at 1000X magnification in acute and subacutely infected rats, as well as uninfected control rats are shown in Figure 5.

### Spleen weight and Splenomegaly

The spleen weight of rats at 0, 3, 7, 14, 21, 28, 35, 42, 60, 90 and 120 days after infection with *B. abortus* biotype 1 was measured (Table 1). The highest spleen weight was recorded ( $2.25 \pm 0.12$  g) at 21 days after infection ( $p < 0.001$ ). All of the rats infected with *B. abortus* during acute and subacute infection manifested splenomegaly (Figure 6).

## DISCUSSION

Infection in wildlife with *B. abortus* is a significant reservoir. Controlling of brucellosis in the wildlife reservoirs is important for the eradication of brucellosis in livestock as well as humans. The early detection of the disease is a prerequisite for controlling of brucellosis in the wildlife reservoirs. The knowledge of hematological profiles of *B. abortus* infection is essential for accurate diagnosis

of brucellosis in the free ranging wildlife reservoir. Hematologic complications in the course of acute brucellosis are not rare<sup>[13,14]</sup> and usually have the form of a mild pancytopenia that is attributed to bone marrow suppression because *Brucella* species show an affinity for reticuloendothelial tissue. In the present study, mild to severe forms of pancytopenia were recorded in the SD, rats following experimental infection with *B. abortus* biotype 1. Pancytopenia was more severe in the subacute stage of infection, compared to the acute stage in our experiment. Hypersplenism can be one of the etiologies of pancytopenia<sup>[14]</sup>. When the spleen enlarges, it traps and stores an excessive number of blood cells and platelets, thereby reducing the number of blood cells and platelets in the bloodstream. This process creates a vicious cycle: the more cells and platelets the spleen traps, the larger it grows; the larger it grows, the more cells and platelets it traps. Eventually, the greatly enlarged spleen also traps normal red blood cells, destroying them along with the abnormal ones. *B. abortus* infection in mice has been reported to cause enlargement of the spleen<sup>[15]</sup>.

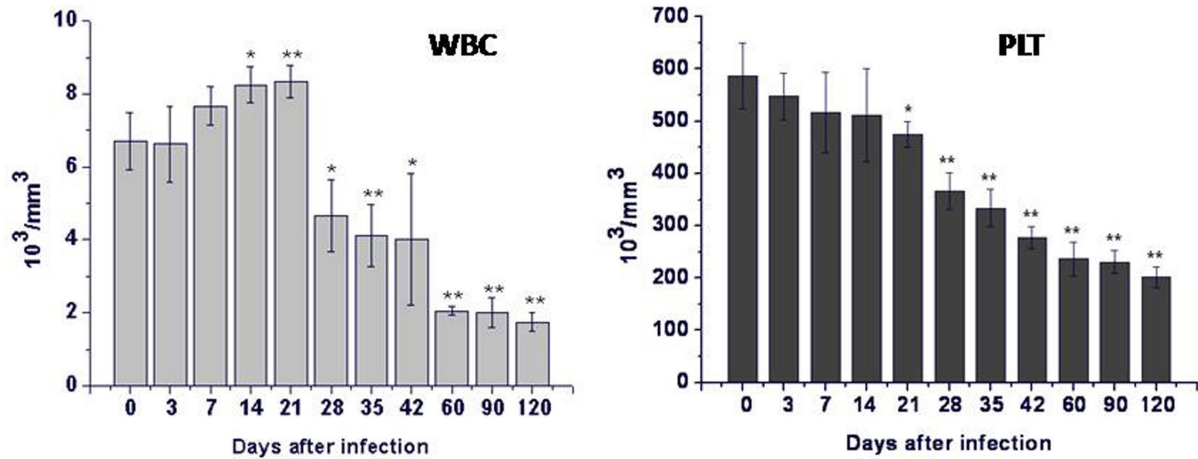
Thrombocytopenia and pancytopenia are reported in human brucellosis<sup>[16,17]</sup>. In the present study, thrombocytopenia was recorded in the SD rats during the acute and subacute stages of brucellosis. The mechanisms implicated in the platelet depletion in the course of brucellosis include hemophagocytosis<sup>[18,19]</sup> and disseminated intravascular coagulation<sup>[20]</sup>. In certain cases, though, brucellosis induces a severe immune reaction in the form of hemolytic anemia and thrombocytopenia<sup>[21,22,23]</sup>, sometimes even with the presence of platelet antibodies. Another mechanism that could be implicated in *Brucella*-attributed thrombocytopenia is granulomatous infiltration of the bone marrow in the chronic form of the disease.

Anemia is the most frequently observed hematological abnormality in brucellosis<sup>[12,24]</sup>. In the present study, the mean value of hematocrit, RBC counts, hemoglobin concentration were significantly decreased in infected rats, as compared to the uninfected control rats ( $p < 0.05$  or  $p < 0.001$ ). These changes of hematological parameters are the clear indication of anemia in the infected SD rats. In case of human anemia was detected in 48 (44%) patients with proven brucellosis<sup>[10]</sup>. Crosby *et al.*<sup>[25]</sup> studied hematologic abnormalities in 38 patients with brucellosis. Anemia was found in 74% of patients, leukopenia in 45%, neutropenia in 21%, lymphopenia in 63%, and thrombocytopenia in 39.5%.

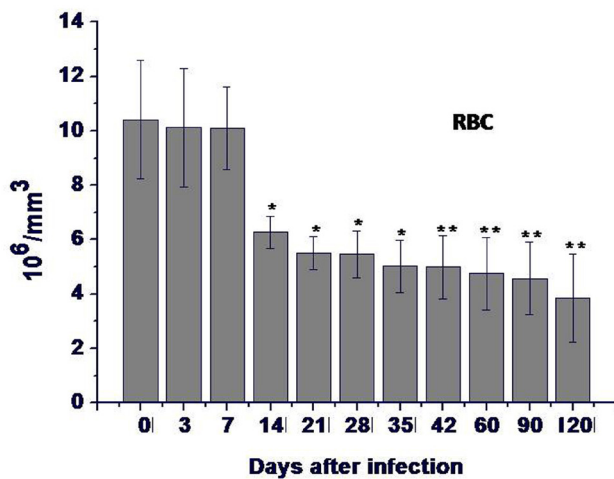
Lymphocytes are white blood cells important in cell-mediated (T-cells) and humoral (B-cells) immune responses and both increases and decreases in lymphocytes can be signs of disease<sup>[26]</sup>. In this experiment, the value of WBC counts significantly increased at 21 days after infection, compared to the uninfected control rats ( $p > 0.001$ ). However, significant decreases of WBC counts were recorded among experimentally infected rats after 21 days of infection, throughout the experiments ( $p < 0.05$  or  $p < 0.001$ ).

**Table 1** Weight of the spleen of rats at 0, 3, 7, 14, 21, 28, 35, 42, 60, 90 and 120 days after infection.

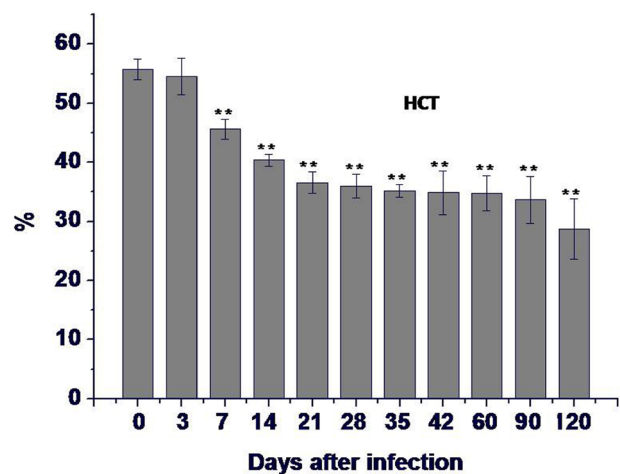
Days after infection	Spleen weight (g) (Mean $\pm$ SD)
0	0.495 $\pm$ 0.05
3	1.475 $\pm$ 0.09
7	1.375 $\pm$ 0.09
14	1.2975 $\pm$ 0.07
21	2.25 $\pm$ 0.12
28	2.175 $\pm$ 0.09
35	1.88 $\pm$ 0.03
42	1.2375 $\pm$ 0.04
60	1.191 $\pm$ 0.02
90	0.8825 $\pm$ 0.05
120	0.6075 $\pm$ 0.02



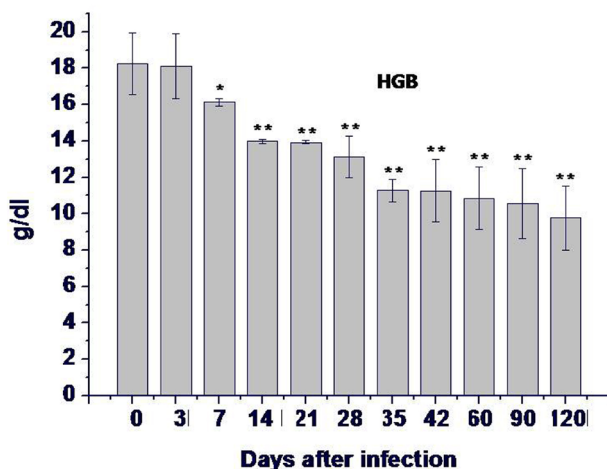
**Figure 1** Total white blood cell (WBC) and platelet (PLT) counts of rats at days after infection. The results are expressed as mean value of four rats  $\pm$  SD. Statistically significant differences of WBC and PLT counts in control and infected rats at different time points of infection are indicated by asterisks (\*  $p < 0.01$  and \*\*,  $p < 0.001$ ).



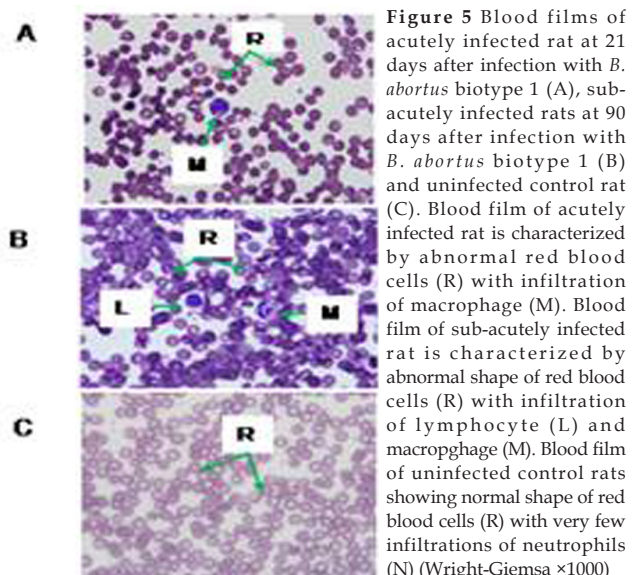
**Figure 2** Total red blood cell (RBC) counts of rats at days after infection. The results are expressed as mean value of four rats  $\pm$  SD. Statistically significant differences of total RBC counts between control and infected rats at different time points of infection are indicated by asterisks (\*  $p < 0.01$  and \*\*,  $p < 0.001$ ).



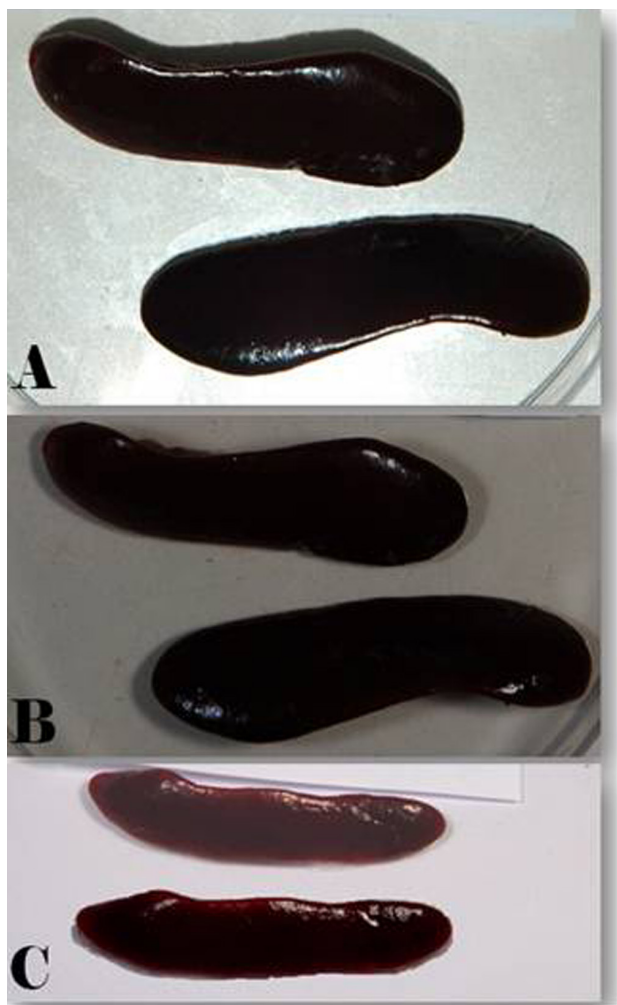
**Figure 3** The hematocrit (HCT) values of rats at days after infection. The results are expressed as mean value of four rats  $\pm$  SD. Statistically significant differences of hematocrit values between control and infected rats at different time points of infection are indicated by asterisks (\*\*,  $p < 0.001$ ).



**Figure 4** Hemoglobin concentration (HGB) of rats at days after infection. The results are expressed as mean value of four rats  $\pm$  SD. Statistically significant differences of hemoglobin concentrations between control and infected rats at different time points of infection are indicated by asterisks (\*  $p < 0.01$  and \*\*,  $p < 0.001$ ).



**Figure 5** Blood films of acutely infected rat at 21 days after infection with *B. abortus* biotype 1 (A), sub-acutely infected rats at 90 days after infection with *B. abortus* biotype 1 (B) and uninfected control rat (C). Blood film of acutely infected rat is characterized by abnormal red blood cells (R) with infiltration of macrophage (M). Blood film of sub-acutely infected rat is characterized by abnormal shape of red blood cells (R) with infiltration of lymphocyte (L) and macrophage (M). Blood film of uninfected control rats showing normal shape of red blood cells (R) with very few infiltrations of neutrophils (N) (Wright-Giemsa  $\times 1000$ )



**Figure 6** Splens from SD rats experimentally infected with *B. abortus* biotype 1 at 21 days after infection showing enlarged spleen (A). Splens from rats experimentally infected with *B. abortus* biotype 1 at 90 days after infection showing enlarged spleen (B). Splens from uninfected control rats (C).

## CONCLUSIONS

*B. abortus* induced hematological changes in SD rats during the acute and subacute stages of infection which could be useful for the diagnosis of free ranging wildlife.

## ACKNOWLEDGEMENTS

The authors would like to thank Dr. S. M. Boyle (Virginia Tech, USA) for editing this manuscript and Islamic Development Bank, Saudia Arabia for providing the fund.

## CONFLICT OF INTEREST

The authors have no conflicts of interest to declare.

## REFERENCES

- 1 Pappas G, Akritidis N, Bosilkovski M, Tsianos E. Brucellosis. *N Eng J Med.* 2005; **352**: 2325-36.
- 2 Lim HS, Min YS, Lee HS. Investigation of a series of brucellosis cases in Gyeongsangbuk-do during 2003-2004. *J Prev Med Public Health.* 2005; **38**: 482-88.
- 3 Crawford RP, Huber JD, Adams BS. Epidemiology and Surveillance. In: Nielson K, Duncan JR (eds.): *Animal Brucellosis.* Boca Raton 131 -151, CRC Press; 1990.
- 4 Pappas G, Papadimitriou P, Akritidis N, Christou L, Tsianos EV. The new global map of human brucellosis. *Lancet Infect Dis.* 2006; **6**(2): 91-9.
- 5 Davis DS, Elzer PH. Brucella vaccines in wildlife. *Vet Microbiol.* 2002; **90**(1-4): 533-34.
- 6 Oliakova NV, Antoniuk VI. The gray rat as a carrier of infectious agents in Siberia and the Far East. *Med Parasitol.* 1989; **3**(5-6): 73-7.
- 7 Garcia-Carrillo C, 1990. Laboratory animal models for brucellosis. In: Nielsen K, Duncan JR (Eds.), *Animal Brucellosis.* CRC Press, Boca Raton, Florida. Pp. 423-442.
- 8 Celebi H, Vardi S, Uygun A, Tahtaci M, Karabay O, Tamer A. Severe thrombocytopenia in acute brucellosis: a case report. *Internet J Hematol.* 2006; **3**(2): 1-3.
- 9 Öztürk ZA, Saymer H, Kuyumcu ME, Yesil Y, Savas E, Saymer ZA, et al. Mean platelet volume in assessment of brucellosis disease. *Biomed Res.* 2012; **23**(4): 541-46.
- 10 Al-Eissa Y, Al-Nasser M. Hematological manifestations of childhood brucellosis. *Infection.* 1993; **21**(1): 23-6.
- 11 Troy SB, Rickman LS, Davis CE. Brucellosis in San Diego: Epidemiology and species related difference in acute clinical presentations. *Medicine.* 2005; **84**(3): 174-87.
- 12 Akdeniz H, Irmak H, Seckinli T, Buzgan T, Demiroz AP. Hematological manifestations in brucellosis cases in Turkey. *Acta Med Okayama.* 1998; **52**(1): 63-5.
- 13 Colmenero JD, Reguera JM, Martos F, Sanchez-De-Mora D, Delgado M., Causse M, Martin-Farfan A, Juarez C. Complications associated with *Brucella melitensis* infection. *Medicine.* 1996; **75**(4): 195-11.
- 14 Young EJ, Tarry A, Genta RM, Ayden N, Gotuzzo E. Thrombocytopenic purpura associated with brucellosis: report of two cases and literature review. *Clin Infect Dis.* 2000; **31**(4): 904-09.
- 15 Palmer MV, Cheville NF, Tatum FM. Morphometric and histopathologic analysis of lymphoid depletion in murine spleen following infection with *Brucella abortus* 2308 or RB51 or an htrA deletion mutant. *Vet Pathol.* 1996; **33**(3): 282-89.
- 16 Akbayram S, Dogan M, Akgun C, Peker E, Parlak M, Caksen H, Oner AF. An analysis of children with brucellosis associated with pancytopenia. *Pediatr Hematol Oncol.* 2011; **28**(3): 203-08.
- 17 Karli A, Sensoy G, Albayrak C, Koken O, Cıralıklı S, Belet N and Albayrak D. Pancytopenia as the initial manifestation of brucellosis in Children. *Vector Borne Zoonotic Dis.* 2015; **15**(9): 545-49.
- 18 Martin-Moreno S, Soto-Guzman O, Bernalgo-de Quiros J, Reverte-Cejudo D, Bascones-Cases C. Pancytopenia due to hemophagocytosis in patients with brucellosis: a report of four cases. *J Infect Dis.* 1983; **147**(3): 445-49.
- 19 Kokkini G, Giotaki HG, Moutsopoulos HM. Transient hemophagocytosis in *Brucella melitensis* infection. *Arch Pathol Lab Med.* 1984; **108**(3): 213-16.
- 20 Tejada RFJ, Lopez RA, Antona DM, Julia NJA. Disseminated intravascular coagulation secondary to acute brucellosis. *An Med Interna.* 2001; **18**: 342-43.
- 21 Frutus F, Gato A, Gaspar G, Alcaraz M. Hemolysis secondary to acute brucellosis. *Enferm Infecc Microbiol Clin.* 1991; **9**: 259-60.
- 22 Di Mario A, Sica S, Zini G, Salutari P, Leone G. Microangiopathic hemolytic anemia and severe thrombocytopenia in Brucella infection. *Ann Hematol.* 1995; **70**(1): 59-0.
- 23 Yaramis A, Kervancioglu M, Yildirim I, Soker M, Derman O, Tas MA. Severe microangiopathic hemolytic anemia and thrombocytopenia in a child with Brucella infection. *Ann Hematol.* 2001; **80**(9): 546-48.
- 24 Galanakis E, Bourantas KL, Leveidiotou S, Lapatsanis PD. Childhood brucellosis in north-western Greece: a retrospective

- analysis. *Eur J Pediatr.* 1996; **155**(1): 1-6.
- 25 Crosby E, Llosa L, Miro Quesada M, Carillo C, Cotuzzo E. Hematologic changes in brucellosis. *J Infect Dis.* 1984; **150**(3): 419-24.
- 26 Tizard IR. *Veterinary immunology: an introduction.* W.B. Saunders, Company, Philadelphia, Pennsylvania. p 498. 1992.
- Peer reviewer:** Kwabena Nsiah, Department of Biochemistry and Biotechnology, Kwame Nkrumah University of Science and Technology, UPO, Kumasi, Ghana.