

## May Hegglin Anomaly with R1339X Masquerading as Idiopathic Thrombocytopenic Purpura And Dengue Fever (A Presentation of Family)

Huang Hin Chin, Tze Shin Leong, Lee Ping Chew

Huang Hin Chin, Tze Shin Leong, Lee Ping Chew, Haematology Unit, Medical Department, Sarawak General Hospital, Jalan Hospital, 93586 Kuching, Sarawak, Malaysia

**Conflict-of-interest statement:** The author(s) declare(s) that there is no conflict of interest regarding the publication of this paper.

**Open-Access:** This article is an open-access article which was selected by an in-house editor and fully peer-reviewed by external reviewers. It is distributed in accordance with the Creative Commons Attribution Non Commercial (CC BY-NC 4.0) license, which permits others to distribute, remix, adapt, build upon this work non-commercially, and license their derivative works on different terms, provided the original work is properly cited and the use is non-commercial. See: <http://creativecommons.org/licenses/by-nc/4.0/>

**Correspondence to:** Huang Hin Chin, Haematology Unit, Medical Department, Sarawak General Hospital, Jalan Hospital, 93586 Kuching, Sarawak, Malaysia.  
Email: [huang\\_hin@hotmail.com](mailto:huang_hin@hotmail.com)  
Telephone: +06082-276666  
Fax: +06082-240767

Received: June 15, 2017

Revised: July 15, 2017

Accepted: July 17, 2017

Published online: September 7, 2017

### ABSTRACT

May Hegglin anomaly (MHA) is a rare disorder characterised by large platelets, thrombocytopenia and Dohle-like body neutrophil inclusions. The present report pertains to a Chinese family on the island of Borneo, Malaysia with MHA. Two of the family members presented to the hospital with thrombocytopenia and were treated as idiopathic thrombocytopenic purpura (ITP) and dengue fever respectively. A diagnosis of MHA was suspected after careful family history taking and review of the peripheral blood film which showed large platelets and Dohle-like body neutrophil inclusions. A genetic

mutation screening on this family of 10 was performed and showed that 6 of the family members have MYH9 mutation on exon 41. MHA may be misdiagnosed as ITP or dengue fever especially in the tropics and incur unnecessary treatment. As such, detailed history taking and careful examination of peripheral blood film may help to prevent such misdiagnoses.

**Key words:** May Hegglin; Idiopathic thrombocytopenic purpura; Dengue fever

**Key Messages:** May Hegglin anomaly (MHA) is a hereditary thrombocytopenia characterised by giant platelets, thrombocytopenia, and Döhle-like body neutrophil inclusions. This disease is rare and can be mistaken as ITP and dengue fever. Hence, detailed history with peripheral blood film examination help to identify patients with MHA and thus prevent unnecessary treatment.

© 2017 The Author(s). Published by ACT Publishing Group Ltd. All rights reserved.

Chin HH, Leong TS, Chew LP. May Hegglin Anomaly with R1339X Masquerading as Idiopathic Thrombocytopenic Purpura And Dengue Fever (A Presentation of Family). *International Journal of Hematology Research* 2017; 3(1): 168-170 Available from: URL: <http://www.ghrnet.org/index.php/ijhr/article/view/2092>

### INTRODUCTION

May Hegglin anomaly (MHA) is an inherited blood disorder via autosomal dominant manner. It belongs to a rare group of disorders that occurs due to mutations in the MYH9 gene on chromosome 22, specifically encodes the non-muscle myosin heavy chain-IIA<sup>[1]</sup>. MYH9 gene defects include MHA, Sebastian syndrome, Fechtner syndrome and Epstein syndrome. These are characterised by giant platelets, thrombocytopenia, and Döhle-like body neutrophil inclusions.

MHA was first diagnosed by Dr. May Hegglin in 1909 when she saw an asymptomatic woman with giant platelets and sky blue crescent-shaped inclusion bodies within the cytoplasm of eosinophil,

neutrophil and monocytes<sup>[2]</sup>. Clinical manifestations of MHA vary from mild to severe bleeding, but the latter tends to be unusual<sup>[3]</sup>. A rare disorder, it is often misdiagnosed and can lead to inappropriate administration of drugs. Longstanding thrombocytopenia is commonly treated as immune thrombocytopenic purpura (ITP), whereas in the tropics “spurious” thrombocytopenia is commonly labelled as dengue haemorrhagic fever. In this case report, we examine a family with a rare inheritable form of platelet disorder which was misdiagnosed as ITP and dengue fever respectively.

## CASE HISTORY

Mr B, a Chinese boy, was presumed to be suffering from ITP since he was 3 years old when he presented with thrombocytopenia. He was given several courses of steroids but his platelet counts never recovered. He defaulted his follow up soon after. Twenty years later, he presented to the Emergency Department with fever and severe thrombocytopenia (with a platelet count of 3,000). Apart from mild dehydration, he had no rashes or headache (dengue triad). Physical examinations were unremarkable with no evidence of hepatosplenomegaly or lymphadenopathy. Mr. B was diagnosed with dengue fever and resuscitated with fluids for 5 days. Full blood counts only revealed thrombocytopenia with other laboratory tests being unremarkable namely electrolytes, coagulation profiles, creatinine, blood urea, nitrogen and liver function test. Dengue serology were negative. Peripheral blood film showed thrombocytopenia with large platelets and Döhle-like body neutrophil inclusions. Bone marrow examination was declined by the patient. He remained asymptomatic with persistent thrombocytopenia (platelet <20,000) during his 3 monthly follow-up at the haematology clinic for the last 1 year.

Ms A was a 26-year-old pregnant lady was referred to the haematology team for immune thrombocytopenia purpura (ITP) in pregnancy at 24 weeks’ period of amenorrhoea. She too, was diagnosed with ITP since the age of 5 but never responded to steroids. She defaulted her follow-up as she was not tolerating the side effects of steroids. Physical examinations were unremarkable for Ms A. There no features to suggest autoimmune disorders or hepatosplenomegaly. Ms A’s peripheral blood film showed giant platelets and Döhle-like body neutrophil inclusions. She was presumed to have May Hegglin anomaly (MHA) and was followed up closely. At 38 weeks, she went into labour with a platelet count of less than 10,000, thus needing platelet transfusions. She delivered a healthy baby boy via spontaneous vaginal delivery and her estimated blood lost was 200 mL.

From further history taking on the family history, we were delighted to discover that Ms A and Mr B were first-degree cousins from Mr.B’s mother (Figure 1). Hereditary thrombocytopenia was thus considered and genetic mutation screening of family members was performed together with the Northern Blood Research Centre Kolling Institute of Medical Research Royal North Shore Hospital in Australia.

A pathogenic MYH9 mutation was identified in exon 41, which is consistent with a diagnosis of MHA was made, within the family members as shown in the family tree. This heterozygous C5797T transition in the *MYH9* gene, resulted in a premature termination in position 1933 (R1933X) that subsequently disturbed the tail domain of the protein of platelet resulting in the MYH9- related disorder.

All family members are asymptomatic for bleeding and has no medical problem apart from Mr B’s mother who has end stage renal failure and is on renal replacement therapy for the last 10 years. Despite having end stage renal failure and a platelet count of less than

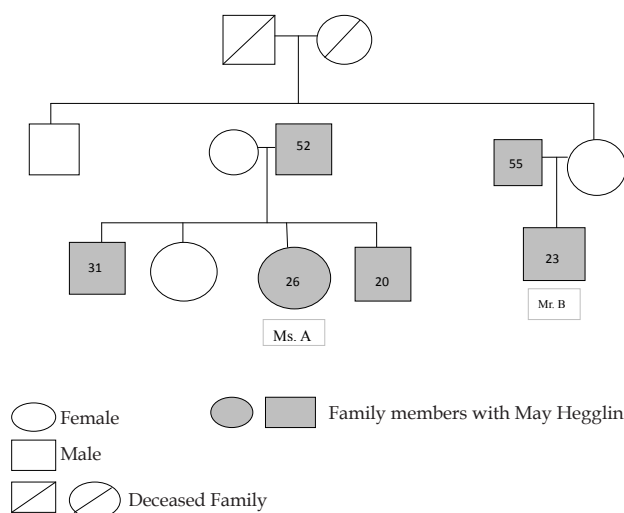
20,000, she never had any bleeding problem. Incidentally, we also found that all the family members were also carriers for the alpha thalassaemia gene.

## DISCUSSION

Mr. B and his family pedigree of MHA with heterozygous mutation (R1933X) of MYH9 gene is probably the first reported case of MHA in Malaysia. This autosomal dominant anomaly may be under-reported and more common than otherwise presumed. Although rare in occurrence, it has occurred in several Japanese and Taiwanese families<sup>[4,5]</sup>. In tropical Malaysia, this disease poses a great diagnostic challenge as Malaysia is situated in an endemic region for infectious diseases that can cause thrombocytopenia. Examples of these diseases include dengue, leptospirosis and malaria. According to WHO, Malaysia ranked third among countries in the Western Pacific Region (WPRO) in terms of the number of reported cases of dengue disease in the period 1991–2007<sup>[6]</sup>.

Mr. B was treated for dengue fever and subjected to multiple fluid boluses. His cousin, Ms. A was prescribed steroids and treated for ITP when she presented with thrombocytopenia. These treatments were unsuccessful for treating MHA. Most MHA patients are asymptomatic with the disease entity discovered incidentally. Some experiences a spectrum of symptoms ranging from mild bleeding to a rare extend of having risk of thrombosis<sup>[7]</sup>. It can be distinguished from ITP or dengue fever through an understanding of the patient’s family history and careful examination of the patient’s peripheral blood smear to look for conventional giant platelets and Döhle-like body neutrophil inclusions (Table 1).

MHA investigation has evolved tremendously from a basic conventional examination of the blood morphology to specific mutation analysis. Through blood film examination, we can identify giant platelets, thrombocytopenia, and inclusions in the cytoplasm of leukocytes on Giemsa stains. Bleeding time may be prolonged according to the degree of thrombocytopenia. Immunocytochemistry plays a role by detecting *NMMHCIIA* complexes within the leukocytes<sup>[8]</sup>. Today, genetic mutation screening can aid in distinguishing the heterogenous exons involved. Approximately 40 mutations have been identified within the MYH9 gene, mainly missense nucleotide substitutions<sup>[9]</sup>. These mutations will lead to an array of MYH9 disorders, for example MHA. It also helps to



**Figure 1** Pedigree of this patient and some affected family members.

**Table 1** Clinical and laboratory differences between MHA, ITP and Dengue Fever.

	MHA	ITP	DENGUE FEVER
Family History	Yes	No	No
Onset	Chronic	Acute	Acute
History of Fever	No	Can be precipitated by fever	Yes
Bleeding Tendency	Mild	Variable	Variable
Previous history of normal platelet	No	Yes	Yes
Peripheral Blood Film	Large platelet, Dohle-like body neutrophil	Normal; Reduced number of platelets	Leukopenia, Reduced number of platelets
Response to platelet transfusion	Good	Poor	Poor
Treatment	Supportive	Steroid, IV Ig	Supportive

postulate the risk of developing high-tone hearing loss, cataracts, or renal impairment especially in relation to heterozygous R1933X mutation<sup>[10]</sup>. One of the family members with MHA did have renal complications needing renal replacement therapy.

MHA cannot be prevented or specifically treated. Most patients do not have clinically significant bleeding tendencies. Severe bleeding, trauma or surgery is indicative of platelet transfusion. Intravenous desmopressin acetate (DDVAP) usage preoperatively can be considered to prevent bleeding<sup>[2]</sup>. Splenectomy and corticosteroids are not useful in treating MHA. There are no reported significant increase risks of bleeding in pregnant women with MHA<sup>[11]</sup>.

## CONCLUSION

We presented 2 cases of MHA with R1933x mutation and first family pedigree from Malaysia. There may be concurrent illnesses that may have presented initially during the admissions to the hospital, however, the subsequent follow-up had proven that the platelet count was persistently low. We discovered that MHA can mimic ITP and can easily be under-investigated. Yet, developing countries are faced with various infectious diseases and a lack of investigation modalities especially in primary care facilities where patients always present at. Presently, there are very limited availability of DNA analysis in Malaysia to provide confirmatory results. The simplicity of history taking and examination of a blood film may help us to clinch this diagnosis and avoid unnecessary invasive diagnostic studies such as bone marrow aspiration, harmful treatment of corticosteroids or the use of immunosuppressant.

## REFERENCES

1. Kelley MJ, Jawien W, Lin A, Hoffmeister K, Pugh EW, Doheny KF, Korczak JF. Autosomal dominant macrothrombocytopenia with leukocyte inclusions (May-Hegglin anomaly) is linked to chromosome 22q12-13. *Hum. Genet* 2000; **106**(5): 557-564
2. May R. Leukozyteneinschlusse. *Dtsch Arch Klin Med* 1909; **96**: 1-6.
3. Sehbai AS, Abraham J, Brown VK. Perioperative management of a patient with May-Hegglin anomaly requiring craniotomy. *Am J Hematol* 2005; **79**: 303-308
4. Ishii A, Honnma T, Ishida M, Sano F, Hamada H, Takayanagi M. Pregnancy complicated by the May-Hegglin anomaly. *J Perinat Med* 1993; **21**(3): 247-252.
5. Sung CC, Lin SH, Chao TK, Chen YC. R1933X mutation in the MYH9 gene in May-Hegglin anomaly mimicking idiopathic thrombocytopenic purpura. *J Formos Med Assoc* 2014 Jan; **113**(1): 56-59.
6. Mohd-Zaki AH, Brett J, Ismail E, L'Azou M. Epidemiology of Dengue Disease in Malaysia (2000–2012): A Systematic Literature Review. *PLoS Negl Trop Dis* 2014; **8**(11): e3159.
7. Zuberi AZ, Ahmed BN, Iqbal S, Page S. May-Hegglin Anomaly and the Devastating Consequences of Acute Cerebral Hemispheric Infarction. *Ann Hematol Oncol* 2016; **3**(1): 1070.
8. Kunishima S, Matsushita T, Kojima T, Sako M, Kimura F, Jo EK. Immunofluorescence analysis of neutrophil nonmuscle myosin heavy chain-A in MYH9 disorders: association of subcellular localization with MYH9 mutations. *Lab Invest* 2003 Jan. **83**(1): 115-122.
9. Althaus K, Greinacher A. MYH9-related platelet disorders. *Semin Thromb Hemost* 2009; **35**: 189-203
10. Balduini CL, Iolascon A, Savoia A. Inherited thrombocytopenias: from genes to therapy. *Haematologica* 2002; **87**: 860-880
11. Chabane H, Gallais Y, Pathier D, Tchernia G, Gaussem P. Delivery management in a woman with thrombocytopenia of the May-Hegglin anomaly type. *Eur J Obstet Gynecol Reprod Biol.* 2001 Nov; **99**(1): 124-125