

Fluorescence Guided Brain Tumor Surgery: Case Report

Salvador Manrique-Guzman, Lucino Castillo-Rueda, Stefan Wolfsberger, Tenoch Herrada-Pineda, Francisco Revilla-Pacheco, Jaime Torres-Corzo, Mauro Loyo-Varela, Walter Stummer

Salvador Manrique-Guzman, Tenoch Herrada Pineda, Francisco Revilla Pacheco, Mauro Loyo-Varela, Department of Neurosurgery, ABC Medical Center, Mexico City, Mexico

Lucino Castillo-Rueda, Jaime Torres-Corzo, Department of Neurosurgery, Hospital Central Dr. Ignacio Morones Prieto S.S.A., San Luis Potosí, S.L.P. Mexico

Stefan Wolfsberger, Department of Neurosurgery, Medical University, Vienna, Austria

Walter Stummer, Department of Neurosurgery. Heinrich-Heine-Universität, Düsseldorf, Germany

Correspondence to: Salvador Manrique-Guzman, MD, MSc, Department Of Neurosurgery, ABC Medical Center. Mexico City. Mexico.

Email: manriquemd@yahoo.com

Telephone: +52-55-55161226

Received: March 13, 2015 Revised: April 18, 2015

Accepted: April 21, 2015

Published online: May 13, 2015

© 2015 ACT. All rights reserved.

Key words: Glioblastoma; 5-aminolevulinic acid; Extent of resection; Protoporphyrin IX; Meningioma

Manrique-Guzman S, Castillo-Rueda L, Wolfsberger S, Pineda TH, Pacheco FR, Loyo-Varela M, Stummer W. Fluorescence Guided Brain Tumor Surgery: Case Report. *International Journal of Neurology Research* 2015; 1(2): 88-92 Available from: URL: <http://www.ghrnet.org/index.php/ijnr/article/view/1112>

INTRODUCTION

Glioblastoma is the most common primary CNS tumor, the incidence of malignant glioma is around 5/100,000, approximately 22,500 new cases each year. Malignant glioma may develop at all ages, the peak incidence being in the fifth and sixth decade of life^[1,2]. Median survival is generally less than one year from time of diagnosis, most patient die within two years^[3]. Malignant glioma comprises glioblastoma (World Health Organization Grade IV), anaplastic astrocytoma (WHO grade III), mixed anaplastic oligoastrocytoma (WHO grade III) and anaplastic oligodendroglioma (WHO grade III). Glioblastoma has the worst prognosis^[4]. Malignant gliomas are 40% more common in men and twice as common in whites as in blacks. The median age of diagnosis is 64 years in GBM and 45 in case of anaplastic gliomas^[1,5].

A multidisciplinary team should evaluate the patient. Rapid symptom relief should be prompted with high doses of corticosteroids with quick tapering according to individual needs. There is no need for prolonged steroid therapy after tumor resection or prophylaxis during radiotherapy. Antiepileptic therapy is indicated in patients presenting with initial seizure^[4].

For newly diagnosed patients surgery is the gold standard as the initial therapeutic approach for tumor debulking and obtaining tissue

ABSTRACT

Glioblastoma is the most common malignant glioma in adults with 22,500 new cases diagnosed each year. Median survival is less than one year with high rates of neurological disabilities. The current treatment approach includes surgery, chemotherapy and radiotherapy. Tumor resection has prognostic value and maximizing tumor resection should be always attempted. Fluorescence guided surgery for brain tumors have improved tumor resection with specificity up to 98%. Limitations for this technology includes lack of modified surgical microscopes in neurosurgical centers worldwide. We present the first two cases done in Mexico with no surgical complications using fluorescent technique. This paper supports the safety and advantages of using fluorescence guided surgery for malignant gliomas.

for diagnosis. Tumor resection has prognostic value, maximizing tumor resection should be attempted considering neurological function and preserving quality of life (QoL). Once the diagnosis for malignant glioma is established, fractionates focal radiotherapy (60 Gy) and chemotherapy is continue. The first-line choice for chemotherapy is Temozolamide (TMZ 75 mg/m²), administered daily (7 day/week) around 1 or 1.5 hour before radiotherapy during the initial phase. For the maintenance phase the doses rises to 150-200 mg/m² on a daily x5 schedule every 28 days with blood count checked on days 21 and 28. Concomitant and adjuvant TMZ chemotherapy improved survival from 2 to 5 year in large randomized trial^[3,4].

Continued refinement in microsurgical techniques and the use of adjunctive technologies have reduced major neurological morbidity to 8.5% and mortality of 1.7% for patients undergoing craniotomy^[6]. Radical resection of malignant gliomas carries the risk of injuring the adjacent neural and vascular structures in the brain, especially because of the infiltrative nature of the neoplasm, more evident in eloquent brain areas (Table 1)^[7]. Evidence shows the presence of tumor cells centimeters beyond the presumed tumor margin^[8].

Table 1 Grading of the intraparenchymal tumors according to the functional location of the lesion according to Sawaya et al.

Grade	Functional location
I: Non-eloquent brain	Frontal or temporal pole. Right parieto-occipital lobe. Cerebellar hemisphere.
II: Near eloquent brain	Near sensory or motor cortex. Near calcarine fissure. Near speech center. Corpus callosum. Near dentate nucleus. Near brain stem
III: Eloquent brain	Motor or sensory cortex. Visual center. Speech center. Internal capsule. Basal ganglia. Hypothalamus and thalamus. Brainstem. Dentate nucleus.

Several factors can influence the survival of patient with GBM, which are age, preoperative performance status according to the KPS, tumor location, preoperative imaging characteristics, extent of tumor excision and postoperative treatment (TMZ & RT)^[6,9].

Neurosurgeons have a central role in determining patient outcome by maximizing resection, always with arbitrary decision^[10]. Multiple resections for carefully selected patients with recurrent disease have demonstrated ability of increasing efficiency of adjuvant therapies. Repeated resections can be achieved with no significant increase in postoperative deficits or wound infections^[11].

The treatment of patients with high-grade glioma remains a challenge for modern therapy. Cytoreductive surgery for malignant gliomas has been performed for decades, from lobectomies to hemispherectomies^[12,13]. The optimal extent of resection depends on tumor size and location, the patient's general and neurological status and the surgeon experience. Survival advantage can be achieved when the extent of resection reaches more than 89%. Aggressive resection of 98% or more of the tumor volume was a significant independent predictor of patient survival (adjusted rate ratio 1.6, 95% CI 1.3-2, *p*<0.0001)^[14-17].

In recent years, surgery has drawn efforts to improve outcome, using cut of the edge technology like fluorescence visualization of the tumor by 5-aminolevulinic acid, navigation-guided fence-post-procedure, intraoperative neurophysiological monitoring and intraoperative magnetic resonance imaging^[18-24].

Fluorescence guided surgery has been recently added to the neurosurgeon arsenal to improve tumor resection. 5-aminolevulinic acid (5-ALA) is a tool for identifying residual tumor and extending resection margin of malignant glioma. This technique was tested in a randomized Phase III study in Europe^[25]. The exogenous administration (orally) of 5-ALA is formed within the mitochondria from succinyle-choline acetate and glycine by 5-ALA-synthetasa, located at the mitochondrial membrane. 5-ALA is the released and dehydrogenated in the cytoplasm producing porphobilinogen then coproporphyrinogen III and finally returns into the mitochondria as protoporphyrin IX (PpIX), a natural precursor of heme, in the target tissue. It causes a negative feedback control exerted by heme on the enzymatic step in ALA synthesis^[26] (Figure 1).

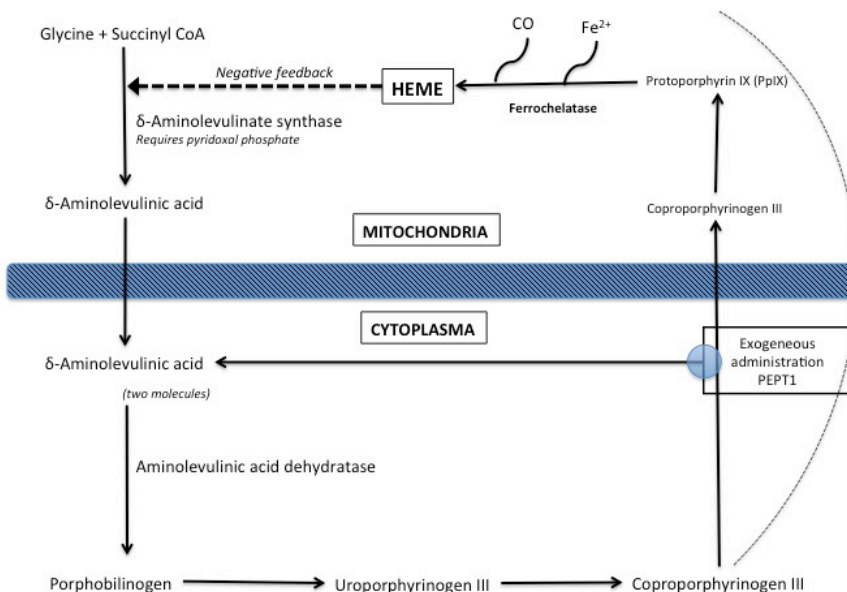


Figure 1 Heme synthesis Pathway. Heme synthesis is conducted in the cytoplasm and mitochondria. It is mainly biosynthesized in liver and red blood cell by 5-aminolevulinic synthase and ferrochelatase. Exogenous ALA bypasses the ALAS inhibition. This causes ferrochelatase saturation and protoporphyrin IX accumulation.

PpIX is present in nearly every nucleated cell; preferential formation and accumulation of this photosensitizer have been demonstrated in tissues known to have a high cellular turnover. The selective accumulation of PpIX is still poorly understood, with a high specificity of 98%. Quantitative data demonstrate PpIX concentration yielded the best classification efficiency (87%) as a diagnostic variable. The probability of classifying tissue as normal given that it is normal 92% with sensitivity (probability of classifying tissue, as abnormal tumor given that it is abnormal is 84%. The positive predictive value (PPV) is 95% and the Negative Predictive Value (NPV) is 77%^[27]. One theory relies in a reduced ferrochelatase activity^[28,29].

Using a modified neurosurgical microscope, porphyrin can be intra-operatively visualized (fluorescence) to identify residual malignant tumor. Due to the intra-tumoral synthesis, 5-ALA differ from other fluorescing agents that have been investigated for tumor discrimination such as fluorescein, which enter the malignant gliomas via the defective blood-brain barrier^[30]. Absorptions of blue light elevated the PpIX molecules from a electronic ground state to a higher excited state, especially to a blue spectrum (around 400-440 nm). Under excitation of light, the intensity of PpIX fluorescence emitted by tumors decreases continuously due to a photochemical decomposition of PpIX called photo-bleaching^[26].

5-ALA is orally given on an empty stomach 3 to 4 hour prior to the anesthesia induction. It is preferentially then, taken up by the liver, kidney, endothelium and skin. The maximum PpIX plasma level is reached in 4 h after oral administration of 5-ALA with the recommend dose (20 mg/kg). The plasma levels rapidly decline during the subsequent 20 h and becomes undetectable after 48 h. It has a half-life of 1-3 h. Approximately 30% of the orally administrated 5-ALA is excrete unchanged in urine within 12h. It has shown to be safe in a number of studies, mild elevation of liver enzymes with no other signs of hepatic disorders were reported (GTP 85%, GOT 81% & GGT 96%) on day 7 after administration of 5-ALA. Skin photosensitivity occurred in <1% of patients^[26].

CASE PRESENTATION

We present two clinical scenarios of the first two cases performed in Mexico using 5-ALA. The first case is of a 44 year-old male with prior history of brain tumor resection in another hospital with pathological result compatible with Grade III malignant glioma according the WHO classification and adjuvant TMZ and fractionated radiotherapy (55 Gy) in 2001. He was then brought back to the operating room for tumor recurrence in another hospital and finally brought to us with frontal lobe syndrome. He was surgically intervened in the Centro Medico Nacional 20 de Noviembre, ISSSTE, Mexico City, in December 2010. Consent form was sign for 5-ALA (20 mg/kg. Gliolan[®], Medac HmbH Wedel, Germany) and a modified neurosurgical microscope was used (OPMI Pentero 900[®], Carl Zeiss GmbH, Oberkochen, Germany). There were no complications during the surgical procedure and the patient was discharged 4 days after. The pathology report was consistent with the same grade III malignant glioma. During the patient follow-up MR no tumor recurrence is seen (Figures 2 and 3).

The second case is from a 37 year-old female with no relevant past-medical history presenting in to the office complaining of headaches, nausea, amaurosis fugax, left-eye ptosis and facial asymmetry. The head MR showed a left frontal extra-axial lesion with important perilesional edema. This case was performed in the Department of Neurosurgery, Hospital Central Dr. Ignacio Morones Prieto S.S.A.,

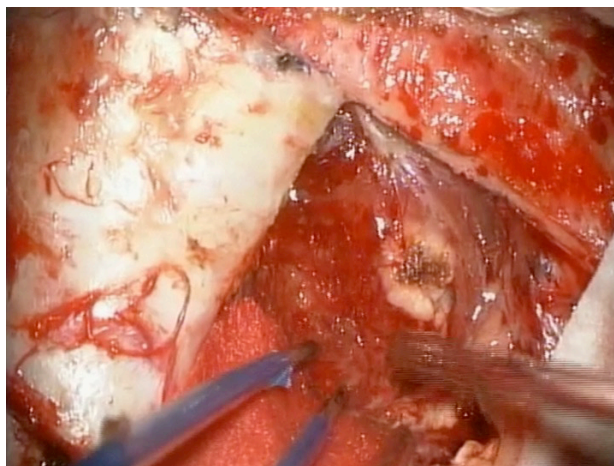


Figure 2 Intraoperative image using conventional white-light illumination with no differentiation between normal brain tissue and the tumor margin.

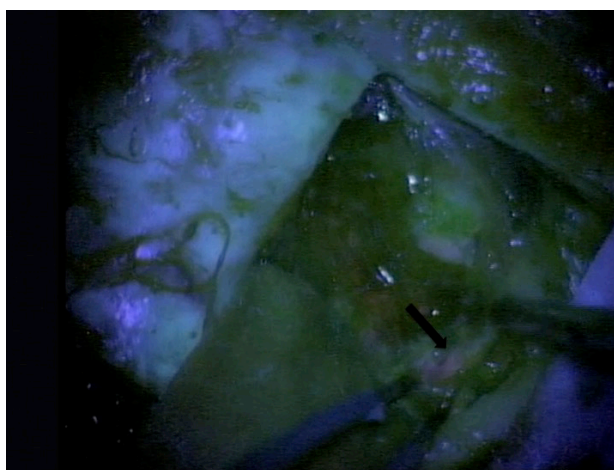


Figure 3 Intraoperative image using a modified microscope (OPMI Pentero, Carl Zeiss) equipped with fluorescence kit. Using 5-ALA, tumor cells acquire fluorescent macroscopic properties allowing the surgeon to extent the resection margins. (Black arrow).

San Luis Potosí, S.L.P. Mexico. After signing the consent form the patient was taken to the operating room with previous administration of 5-ALA (20 mg/kg. Gliolan[®], Medac HmbH Wedel, Germany). We also used a modified microscope (OPMI Pentero 900[®], Carl Zeiss GmbH, Oberkochen, Germany) using standard surgical techniques and Neuronavigation system (AxiEM Medtronic, Inc.[®]) achieving gross total resection. No complications were registered during surgery or after, and the patient was discharged from the hospital 3 days after the surgery. The final pathology report was compatible with Grade I Meningioma. During the patient follow-up MR no tumor recurrence is seen (Figures 4 and 5)

DISCUSSION

Fluorescence guided surgery for malignant gliomas using 5-ALA has proven to be a safe and useful tool for identifying residual tumor and optimizing the extend of resection. As describe by Kamp and cols., we also found it useful identifying normal brain tissue or changes like gliosis, necrosis, vascular hyalization and scar formation in our patient with prior history of TMZ and radiotherapy^[31].

Infiltration of eloquent areas is based with preop imaging (MR). Complete resection carries a higher risk of postoperative neurological

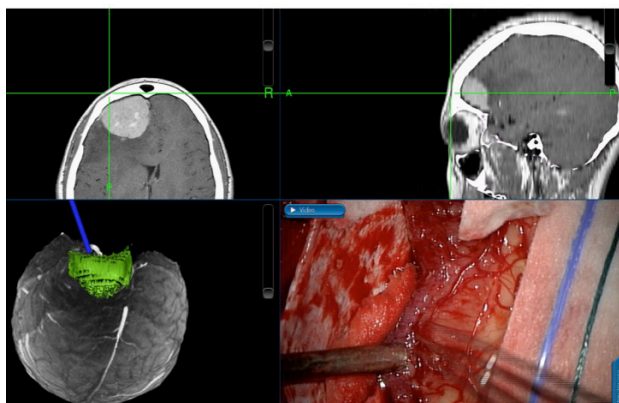


Figure 4 Intraoperative image using a Neuronavigation system (AxiEM Medtronic, Inc) using conventional white-light illumination with no clear differentiation of tumor cells extending beyond the arachnoid layer.

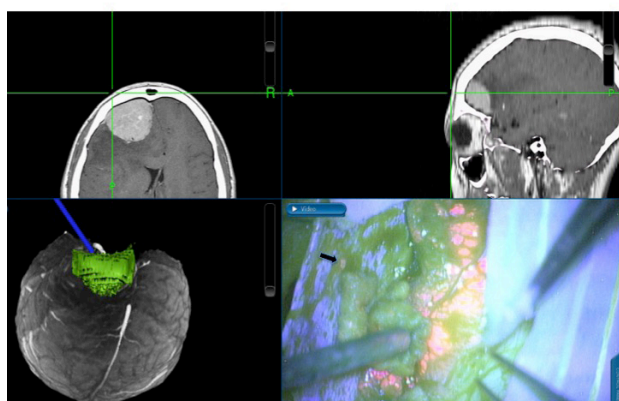


Figure 5 Intraoperative image using a Neuronavigation system (AxiEM Medtronic, Inc) using a modified microscope (OPMI Pentero, Carl Zeiss) equipped with fluorescence kit. Using 5-ALA, tumor cells can be seen extending beyond the arachnoid layer. (Black arrow).

deficit, but incomplete resection decreases survival. 5-ALA is not only a diagnostic drug; it has the value and risk of extended cytoreduction in surgery for malignant gliomas.

There is limited worldwide experience using the 5-ALA in extra-axial lesion such as meningiomas. Valdes and cols., demonstrated in a pool of 15 patients improvement in completing surgical resections and identifying tumor cells that spread beyond the arachnoid layer. For meningiomas, PpIX has a sensibility of 83% and specificity of 100%^[32]. With our patient we were able to complete tumor removal and also were able to identify any tumor cell population in the tumor margin.

Preserving the balance between surgical resection and function preservations is major challenge to all neurosurgeons. New technologies reduce the risk of temporal or permanent neurological deficit and increase the patient opportunity for an increase survival. The use of ALA for diagnosis and treatment has evolved. The side-effect profile is minimal. It is important to point out that this technology is also available in countries with an emerging economy such as in Mexico.

CONCLUSIONS

Fluorescence guided surgery to improve surgical resection using 5-ALA and a modified microscope has proven to be a safe tool to achieve a more aggressive tumor removal and improving survival.

5-ALA is useful to discriminate neoplastic tissue from adjacent normal brain. One major limitation include that 5-ALA is still not available worldwide and is non-FDA-approved. The second major limitation is that not all neurosurgical centers have a modified microscope with blue spectrum light source to provoke PpIX excitation. Conjoint efforts must be address to provide this useful technology to all surgical centers to improve patient's survival.

CONFLICT OF INTERESTS

The Author has no conflicts of interest to declare.

REFERENCES

1. Wen PY, Kesari S. Malignant gliomas in adults. *The New England journal of medicine*. 2008;359(5):492-507.
2. Ferlay J, Shin HR, Bray F, Forman D, Mathers C, Parkin DM. Estimates of worldwide burden of cancer in 2008: GLOBOCAN 2008. *International journal of cancer Journal international du cancer*. 2010;127(12):2893-917.
3. Stupp R, Mason WP, van den Bent MJ, Weller M, Fisher B, Taphoorn MJ, et al. Radiotherapy plus concomitant and adjuvant temozolomide for glioblastoma. *The New England journal of medicine*. 2005;352(10):987-96.
4. Stupp R, Tonn JC, Brada M, Pentheroudakis G, Group EGW. High-grade malignant glioma: ESMO Clinical Practice Guidelines for diagnosis, treatment and follow-up. *Annals of oncology : official journal of the European Society for Medical Oncology / ESMO*. 2010;21 Suppl 5:v190-3.
5. Louis DN, Ohgaki H, Wiestler OD, Cavenee WK, Burger PC, Jouvet A, et al. The 2007 WHO classification of tumours of the central nervous system. *Acta neuropathologica*. 2007;114(2):97-109.
6. Allahdini F, Amirjamshidi A, Reza-Zarei M, Abdollahi M. Evaluating the prognostic factors effective on the outcome of patients with glioblastoma multiformis: does maximal resection of the tumor lengthen the median survival? *World neurosurgery*. 2010;73(2):128-34; discussion e16.
7. Sawaya R, Hammoud M, Schoppa D, Hess KR, Wu SZ, Shi WM, et al. Neurosurgical outcomes in a modern series of 400 craniotomies for treatment of parenchymal tumors. *Neurosurgery*. 1998;42(5):1044-55; discussion 55-6.
8. Lathia JD, Gallagher J, Myers JT, Li M, Vasanji A, McLendon RE, et al. Direct in vivo evidence for tumor propagation by glioblastoma cancer stem cells. *PLoS one*. 2011;6(9):e24807.
9. Chaichana KL, McGirt MJ, Frazier J, Attenello F, Guerrero-Cazares H, Quinones-Hinojosa A. Relationship of glioblastoma multiforme to the lateral ventricles predicts survival following tumor resection. *Journal of neuro-oncology*. 2008;89(2):219-24.
10. Orringer D, Lau D, Khatri S, Zamora-Berridi GJ, Zhang K, Wu C, et al. Extent of resection in patients with glioblastoma: limiting factors, perception of resectability, and effect on survival. *Journal of neurosurgery*. 2012;117(5):851-9.
11. Chaichana KL, Zadnik P, Weingart JD, Olivi A, Gallia GL, Blakeley J, et al. Multiple resections for patients with glioblastoma: prolonging survival. *Journal of neurosurgery*. 2013;118(4):812-20.
12. Stummer W, van den Bent MJ, Westphal M. Cytoreductive surgery of glioblastoma as the key to successful adjuvant therapies: new arguments in an old discussion. *Acta neurochirurgica*. 2011;153(6):1211-8.
13. Dandy WE. Removal of right cerebral hemisphere for certain tumors with hemiplegia: Preliminary report. *Journal of the American Medical Association*. 1928;90(11):823-5.
14. Lacroix M, Abi-Said D, Fourney DR, Gokaslan ZL, Shi W, DeMonte F, et al. A multivariate analysis of 416 patients with glioblastoma multiforme: prognosis, extent of resection, and survival. *Journal of*

- neurosurgery. 2001;95(2):190-8.
15. Sanai N, Berger MS. Glioma extent of resection and its impact on patient outcome. *Neurosurgery*. 2008;62(4):753-64; discussion 264-6.
 16. McGirt MJ, Chaichana KL, Gathinji M, Attenello FJ, Than K, Olivi A, et al. Independent association of extent of resection with survival in patients with malignant brain astrocytoma. *Journal of neurosurgery*. 2009;110(1):156-62.
 17. Keles GE, Anderson B, Berger MS. The effect of extent of resection on time to tumor progression and survival in patients with glioblastoma multiforme of the cerebral hemisphere. *Surgical neurology*. 1999;52(4):371-9.
 18. Yamaguchi S, Kobayashi H, Terasaka S, Ishii N, Ikeda J, Kanno H, et al. The impact of extent of resection and histological subtype on the outcome of adult patients with high-grade gliomas. *Japanese journal of clinical oncology*. 2012;42(4):270-7.
 19. von Campe G, Moschopoulos M, Hefti M. 5-Aminolevulinic acid-induced protoporphyrin IX fluorescence as immediate intraoperative indicator to improve the safety of malignant or high-grade brain tumor diagnosis in frameless stereotactic biopsies. *Acta neurochirurgica*. 2012;154(4):585-8; discussion 8.
 20. Kubben PL, ter Meulen KJ, Schijns OE, ter Laak-Poort MP, van Overbeeke JJ, van Santbrink H. Intraoperative MRI-guided resection of glioblastoma multiforme: a systematic review. *The Lancet Oncology*. 2011;12(11):1062-70.
 21. Senft C, Bink A, Franz K, Vatter H, Gasser T, Seifert V. Intraoperative MRI guidance and extent of resection in glioma surgery: a randomised, controlled trial. *The Lancet Oncology*. 2011;12(11):997-1003.
 22. Sanai N, Mirzadeh Z, Berger MS. Functional outcome after language mapping for glioma resection. *The New England journal of medicine*. 2008;358(1):18-27.
 23. D'Andrea G, Angelini A, Romano A, Di Lauro A, Sessa G, Bozzao A, et al. Intraoperative DTI and brain mapping for surgery of neoplasm of the motor cortex and the corticospinal tract: our protocol and series in BrainSUITE. *Neurosurgical review*. 2012;35(3):401-12; discussion 12.
 24. Garrett MC, Pouratian N, Liao LM. Use of language mapping to aid in resection of gliomas in eloquent brain regions. *Neurosurgery clinics of North America*. 2012;23(3):497-506.
 25. Stummer W, Tonn JC, Mehdorn HM, Nestler U, Franz K, Goetz C, et al. Counterbalancing risks and gains from extended resections in malignant glioma surgery: a supplemental analysis from the randomized 5-aminolevulinic acid glioma resection study. *Clinical article. Journal of neurosurgery*. 2011;114(3):613-23.
 26. Chung IW, Eljamel S. Risk factors for developing oral 5-aminolevulinic acid-induced side effects in patients undergoing fluorescence guided resection. *Photodiagnosis and photodynamic therapy*. 2013;10(4):362-7.
 27. Valdes PA, Leblond F, Kim A, Harris BT, Wilson BC, Fan X, et al. Quantitative fluorescence in intracranial tumor: implications for ALA-induced PpIX as an intraoperative biomarker. *Journal of neurosurgery*. 2011;115(1):11-7.
 28. Uehlinger P, Zellweger M, Wagnier G, Juillerat-Jeanneret L, van den Bergh H, Lange N. 5-Aminolevulinic acid and its derivatives: physical chemical properties and protoporphyrin IX formation in cultured cells. *Journal of photochemistry and photobiology B, Biology*. 2000;54(1):72-80.
 29. Ennis SR, Novotny A, Xiang J, Shakui P, Masada T, Stummer W, et al. Transport of 5-aminolevulinic acid between blood and brain. *Brain research*. 2003;959(2):226-34.
 30. Stummer W, Pichlmeier U, Meinel T, Wiestler OD, Zanella F, Reulen HJ, et al. Fluorescence-guided surgery with 5-aminolevulinic acid for resection of malignant glioma: a randomised controlled multicentre phase III trial. *The Lancet Oncology*. 2006;7(5):392-401.
 31. Kamp MA, Felsberg J, Sadat H, Kuzibaev J, Steiger HJ, Rapp M, et al. 5-ALA-induced fluorescence behavior of reactive tissue changes following glioblastoma treatment with radiation and chemotherapy. *Acta neurochirurgica*. 2015;157(2):207-14.
 32. Valdes PA, Bekelis K, Harris BT, Wilson BC, Leblond F, Kim A, et al. 5-Aminolevulinic acid-induced protoporphyrin IX fluorescence in meningioma: qualitative and quantitative measurements in vivo. *Neurosurgery*. 2014;10 Suppl 1:74-82; discussion -3.

Peer reviewers: Masashi Kameyama, Division of Nuclear Medicine, Department of Radiology, School of Medicine, Keio University, 35 Shinanomachi Shinjuku-ku, Tokyo, 160-8582, Japan; David Hung-Chi Pan, M.D., Department of Neurosurgery, Taipei Veterans General Hospital, 201 Shih-Pai Road, Sec 2, Taipei, Taiwan.