

EEG-fMRI Co-Registration: From Research to a Potential Pre-Surgical Tool

Ashalatha Radhakrishnan, Mahalaxmi Ganjoo, Anu Sundar, Anuvitha Chandran, Sujesh Sreedharan, Ramshekhar Menon, Bejoy Thomas, Chandrashekharan Kesavadas

Ashalatha Radhakrishnan, Mahalaxmi Ganjoo, Anu Sundar, Anuvitha Chandran, Sujesh Sreedharan, Ramshekhar Menon, Bejoy Thomas, Chandrashekharan Kesavadas, R Madhavan Nayar Centre for Comprehensive Epilepsy Care, Sree Chitra Tirunal Institute for Medical Sciences and Technology, Trivandrum, India

Conflict-of-interest statement: The author(s) declare(s) that there is no conflict of interest regarding the publication of this paper.

Correspondence to: Ashalatha Radhakrishnan, Consultant Neurologist and Epileptologist, Department of Neurology, Sree Chitra Tirunal Institute for Medical Sciences and Technology, Trivandrum-695011, Kerala, India.

Email: drashalatha@sctimst.ac.in

Telephone: +91-471-2524282

Fax: +91-471-2446433

Received: May 16, 2016

Revised: June 16, 2016

Accepted: June 19, 2016

Published online: December 16, 2016

ABSTRACT

Functional magnetic resonance imaging (fMRI) and electroencephalography (EEG) are validated modalities for identifying neuronal activity and they are complementary in that fMRI offers high spatial resolution while EEG provides high temporal resolution. Hence integration of these two modalities would in turn be a promising tool to delineate a focal ictal onset zone, both as part of research and for focal resection of the same zone to abolish drug-resistant seizures. This review focuses on this new technique with details of the biophysical difficulties encountered, methodology with relevant EEG-fMRI integration studies in epilepsy research and emphasis on its application as a potential presurgical evaluation tool in evaluation of drug resistant epilepsy.

Key words: Inter-ictal epileptiform discharges; Ictal onset zone; Epileptogenic zone; EEG; Functional MRI; Blood oxygen level dependent (BOLD) signal

© 2016 The Author(s). Published by ACT Publishing Group Ltd. This is an open access article under the CC BY-NC-ND license (<http://creativecommons.org/licenses/by-nc-nd/4.0/>).

Radhakrishnan A, Ganjoo M, Sundar A, Chandran A, Sreedharan S, Menon R, Thomas B, Kesavadas C. EEG-fMRI Co-Registration: From Research to a Potential Pre-Surgical Tool. *International Journal of Neurology Research* 2016; 2(3-4): 277-284 Available from: URL: <http://www.ghrnet.org/index.php/jnr/article/view/1728>

INTRODUCTION

Based on various studies, about 1% (65 million) of the world population has epilepsy and the incidence is higher in developing countries^[1]. Electroencephalography (EEG) and Video-EEG are the principal tools used to detect the presence of ictal and interictal epileptiform discharges (IEDs), delineate the irritative zone and categorize the seizure syndrome. To increase its sensitivity it is used with other modalities like PET (positron emission tomography), SPECT (single photon emission computed tomography) giving the measure of increased glucose utilization and an increased blood flow respectively, to areas of electrical activity and thus an estimate of increased activity and MEG (magnetoencephalogram) that detects the electrical potential at the scalp through changes in the magnetic field.

A new tool, simultaneous recording of EEG and functional MRI (fMRI) is being used mainly as a research modality that exploits the complementary advantages of both the techniques, EEG and functional MRI^[2-13]. EEG detects the electrical activity from the surface of the scalp originating from the cortical pyramidal cells. It has very high temporal resolution in the order of milliseconds, but poor spatial resolution. It presents with 2D data that is used to interpret the 3D structure of the brain and doing so restricts accuracy ("Inverse problem"). Also, it is rather insensitive to deeper sources of the brain. Functional MRI has a very high spatial resolution, in the order of millimetres, superior than PET which is inadequate to study IEDs; and resolution increases with the strength of the magnet (1 Tesla to 7 Tesla). It has poor temporal resolution in the order of seconds. Thus co-registering the data from EEG and fMRI has the potential to overcome these limitations and offer an accurate localization method for the ictal onset zone.

Functional MRI (fMRI) uses the oxygenation and de-oxygenation states in the brain during an activity to produce a signal^[14]. Deoxygenated haemoglobin is paramagnetic and changes the local magnetic field inhomogeneities while oxy-haemoglobin is diamagnetic and does not influence the magnetic field. When the ictal onset zone generates an IED, the region consumes more glucose and thus more oxygen for its oxidation, and reduces the local oxy-haemoglobin concentration which induces increased cerebral blood flow (CBF) to that region and increases local cerebral blood volume (CBV). But the CBF over-compensates for the local oxygen depletion resulting in decreased cerebral metabolic rate of oxygen (CMRO₂) increasing oxy-haemoglobin concentration; thus producing a higher signal and is referred to as “activations”. The complete neuro-vascular coupling is not fully understood and the aspects of blood oxygen level dependent (BOLD) coupling that best reflect the neuronal activity is an area of active research. Nevertheless, it can be proven that BOLD activations are indirect measures of neuronal activity.

TECHNIQUE AND PRINCIPLES OF EEG-fMRI

A literature search was done using Medline, Embase and Biosis from 2000 to 2016 on the various aspects of the technique of EEG-fMRI, especially on its utility as a clinical rather than a research tool in epilepsy by the primary author (AR) who has expertise in performing and validating EEG-fMRI.

De-activations in EEG-fMRI

Deactivations observed in EEG-fMRI are especially pronounced in the vicinity of the lesion or ictal onset zone and sometimes at a distance mostly in the homologous cortical areas and in subcortical regions. Raichle *et al*^[15] studied deactivation patterns with PET scanning and showed that tasks like cognition and memory showed increased response in some regions with the decrease in activations of the areas that had activations at resting state. These deactivated areas (that were previously active at rest) he named ‘default mode network’. These networks are believed to take part in the basic awareness and consciousness of the individual, as indicated by Laufs *et al*^[13] who showed deactivations in the default mode network while a patient experienced absence seizures.

Mechanisms and hypothesis proposed for the deactivations are the steal phenomenon, where blood is drawn towards the activated areas reducing blood flow to the adjacent areas, pathological states involving the cerebral vasculature starving some regions for oxygen when blood flow to activated region increases, natural deactivations in some pathways with activations in others and GABA mediated inhibition that utilizes very low energy but has huge inhibitory capacity^[16,17].

Technical difficulties in EEG-fMRI data acquisition

The equipment connections and signal transduction in EEG-fMRI co-registration are depicted in Figure 1. Simultaneous EEG-fMRI presents a lot of technical difficulties. EEG electrodes are metallic and as per Faraday’s law of electromagnetic induction, the strong electromagnetic fields used in the MR are absorbed by and induce heating of conductive objects, causing discomfort and possible burns to the subject and burning of the main circuitry of the amplifier. The MR-compatible EEG equipment that is now available makes use of non-ferrous electrodes and leads with current limiting resistors that vary in resistivity between 5 to 15 Kilo-ohms that minimize the risk of heating and helps in safe recordings^[18]. But not all MR sequences are compatible with EEG-fMRI settings, in sequences with high

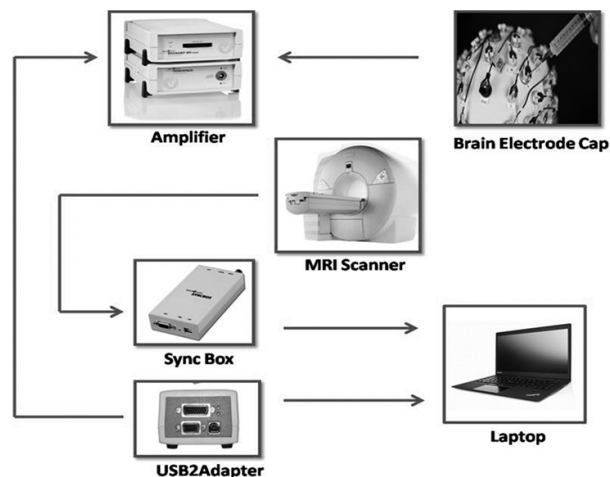


Figure 1 The equipment connections and signal transduction in EEG-fMRI co-registration.

Table 1 List of sequences safe and unsafe for use with MR compatible EEG equipment during simultaneous EEG-fMRI recordings.

Sr. No.	Sequences	Compatibility with EEG-fMRI
1	Spoiled gradient echo	Safe
2	Magnetization prepared gradient echo	Safe
3	EPI -gradient echo	Safe
4	EPI -spin echo	Unsafe
5	FLAIR	Unsafe
6	Spin echo	Unsafe
7	Turbo spin echo	Unsafe
8	Fast spin echo	Unsafe
9	Ultra-fast spin echo	Unsafe

EPI-echoplanar imaging; FLAIR-fluid attenuated inversion recovery sequence.

SAR (specific absorption rate) the electromagnetic fields (both static and gradient fields) generate high frequency alternating currents in conductive materials of the system which may raise the temperature of the cables and electrodes and become unsafe even with MR compatible equipment.

EEG detects very low amplitude electrophysiological potential in the scalp and is very sensitive to external electro-magnetic fields (both static and rapidly switching gradient magnetic fields) and radio frequency pulses, thus EEG recording inside the MR scanner with strength ranging from 1 T to 7 T produces artefacts about 50 times higher than the baseline EEG^[19]. These are called ‘gradient artefacts’ and can be corrected (Figure 2) by an advanced software designed for simultaneous EEG-fMRI data acquisition (e.g. Vision Analyzer, Brain Products, Mizar 40 Amplifier, EB Neuro, MicroMed, etc.). The regular EEG amplifiers and amplification cables cannot be used inside the scanning room as they affect the MR signals and their presence gives poor quality MR images. There are MR-compatible EEG amplifiers available (e.g. Brain Products, Munich, Germany) and fibre optic cables connecting the amplifier to the recording computer outside the scanning room. The optic cables do not allow a conductive bridge to develop, preserving the image quality.

Another artefact commonly encountered in simultaneous EEG-fMRI is ‘ballistocardiogram artefact’ or ‘pulse artefact’ (Figure 3). It is generated because the fast moving blood in the arteries causes pulsatile movements on the scalp resulting in corresponding movements of the electrodes. These can also be corrected by a software that correlates the electrocardiogram (EKG) spikes with the corresponding high frequency EEG used for simultaneous EEG-fMRI data acquisition and processing (Figure 3).

Artefact removal steps

The gradient and the cardio ballistic artefacts are removed by the steps mentioned below; the detailed step-by-step method varies between different softwares, the theoretical aspects are covered.

For gradient artefact (Figure 2): (1) The volume markers or slice markers, that identify the rate of gradient switching and are supplied by MRI hardware system, are acquired and correlated with the EEG data; (2) This synchronization is introduced into the algorithm for gradient correction; (3) Average artefact subtraction method is generally used for its removal.

For cardio-ballistic artefact (Figure 3): (1) The cardiac artefacts are detected by the software with the algorithm designed to detect

the high amplitude, regular spikes in the EKG channel alone; (2) It then marks the corresponding spikes in all the other channels (most softwares provide the option of manually checking the EEG with pulse artefacts that can be corrected); (2); Artefacts are removed by average subtraction method.

TECHNIQUE OF EEG-fMRI DATA ACQUISITION AND PROCESSING

EEG-fMRI is essentially a functional MRI technique with potential of high resolution 3D localization of the ictal onset zone. This has encouraged research in both data acquisition and analysis. EEG-BOLD

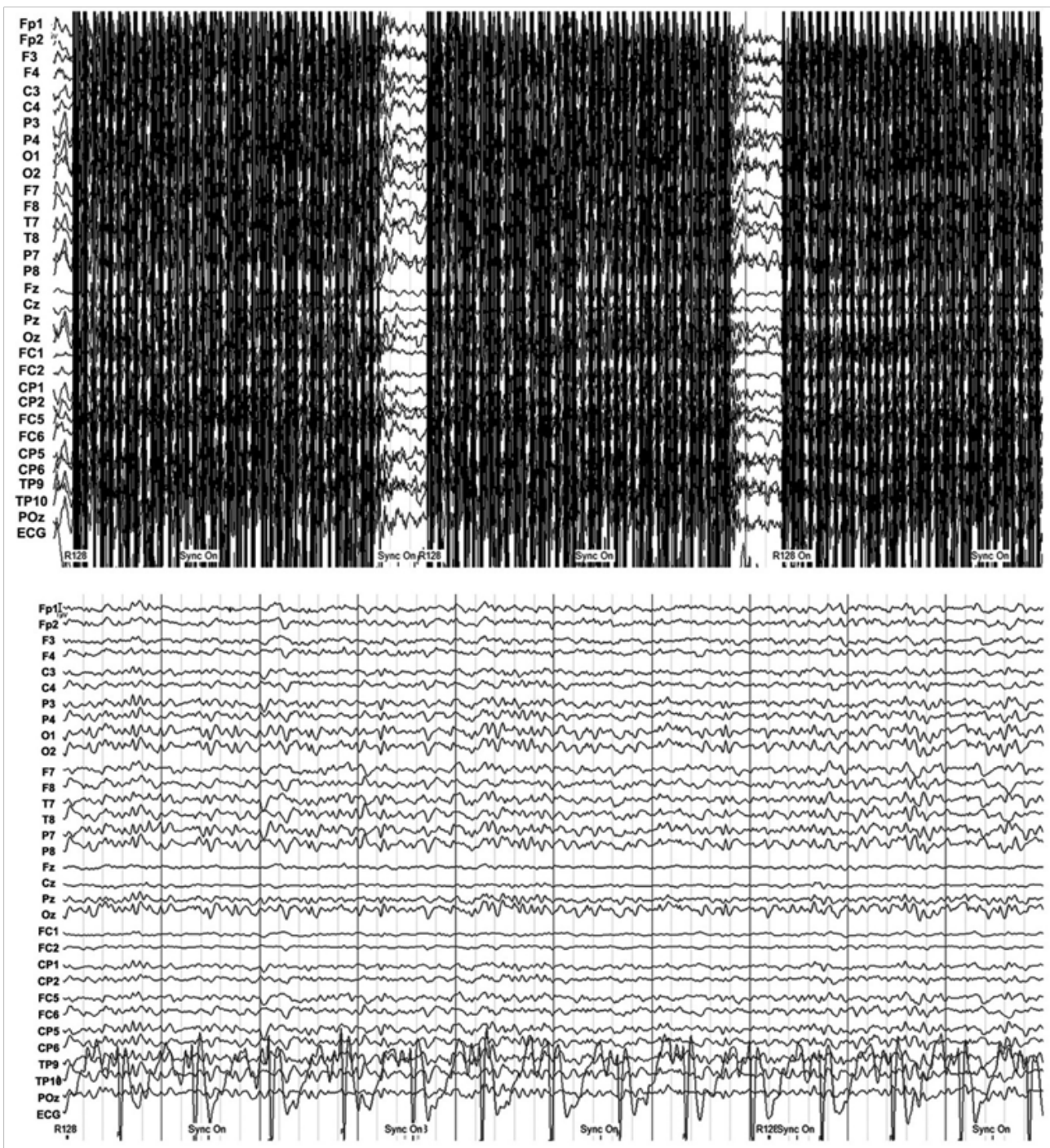


Figure 2 The gradient artefact (top) and the underlying EEG after its removal (bottom).

coupling is not a well understood process because the IEDs and the hemodynamic response are non-linear with variable response times but can be correlated assuming that the EEG spike source and the hemodynamic response function(HRF) signal source are linearly associated. EEG derived time courses are convoluted with fMRI response and voxel-wise correlated with the BOLD signal.

fMRI data is very sensitive to motion; so the head movements are restricted with pads or pillow having micro polystyrene balls with vacuum obtained through suction; as it tightly fits the head and reduces discomfort. The MR compatible EEG leads are pasted as per the international 10-20 or 10-10 system (16, 32 or 64 or even more scalp electrodes and one or two ECG electrodes that are helpful to later

eliminate pulse artefact) and connected to MR compatible amplifier that can be kept inside the scanner room. The fMRI signal can only be obtained in a scanner with strength 1.5 Tesla or higher. BOLD signal is a T2* weighted image that makes use of the paramagnetic properties wherein the deoxyhemoglobin causes local magnetic field distortions and increase the transverse spin magnetization leading to quicker T2* signal loss (“transverse decay”).

The gradient-echo T2* weighted echo planar imaging (EPI) are commonly used. Short TE (between 40 to 50 ms) with long TR (between 2 to 4 sec), with standard matrix mostly 64 × 64, and average voxel dimension between 3 × 3 × 3 mm to 5 × 5 × 5 mm. A total of 20 to 40 slices are taken out of which the first few slices are elimi-

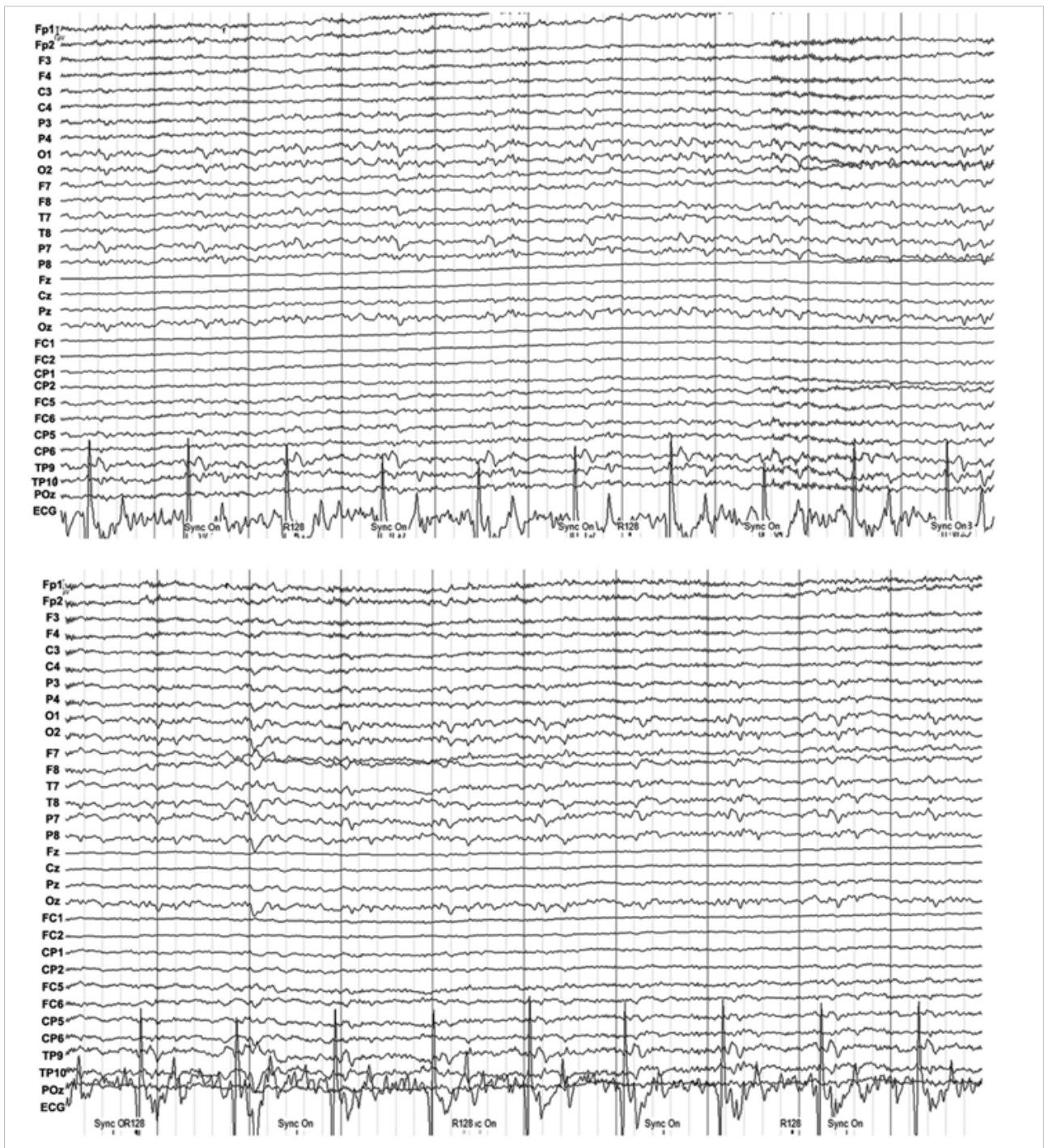


Figure 3 The pulse artefact (top) and the underlying EEG after its removal (bottom).

nated from the study due to unsteady tissue magnetization. Structural T1 weighted images are recorded to later co-register with the fMRI images for localizing. The entire recording time varies between 20 min to an hour^[20-22].

The fMRI data is analyzed after standard pre-processing steps of realignment (to correct for subject motion), slice time correction and spatial smoothing (to reduce the noise). Post-processing the images is with the softwares like SPM (Statistical parametric mapping, developed by Wellcome Department of Imaging Neuroscience, London), FSL (FMRIB software library by Analysis group, Oxford, UK), Brain Voyager (Brain Innovation, Maastricht, Netherlands) etc; detects HRF and the corresponding BOLD signal.

The EEG data is clouded with the scanner artefacts. These MR and pulse artefacts are corrected for and the EEG is read by an experienced neurologist. The IEDs are marked and the time points when they occurred are used to correlate the EEG data with the BOLD signal, after introduction of 3 to 5 sec time correction factor.

After artefact subtraction and pre-processing, the respective results of both EEG and fMRI are co-registered and the final localization of the irritative zone is obtained (Figure 4).

TYPES OF EPILEPSIES WHERE EEG-fMRI CO-REGISTRATION IS HELPFUL

EEG-fMRI co-registration is not suitable for studying all types of

epilepsies. In generalized seizures and partial seizures with diffuse ictal onset zone, combining the EEG and fMRI does not improve localization and prognosis. Absences and benign rolandic epilepsies have seizures usually disappearing in adolescence and EEG-fMRI is used as a research tool. In partial seizures with secondary generalizations, it increases accuracy of localizing ictal onset zone, and in partial seizures with multiple seizure foci EEG-fMRI co-registration aids in its confirmation.

CHRONOLOGY OF DEVELOPMENT OF EEG-fMRI CO-REGISTRATION STUDIES

Before the gradient artefact correction algorithms were designed, these artefacts were avoided by using 'EEG-triggered fMRI method'^[3,4] wherein fMRI scanning was initiated only after an EEG event. Its drawbacks were that it required an expert to monitor the EEG at all times and it could take only a few frames, as many as the spikes observed. This paved way to the 'continuous EEG-fMRI' sessions by the development of the required algorithms and strong amplifiers^[5].

There have been many studies conducted evaluating the efficiency of simultaneous and continuous EEG-fMRI in epilepsy^[3-8,10,12,23-27]. Majority deal with inter-ictal studies rather than ictal ones as epileptic seizures are infrequent and rarely occur while performing a 20 to 40 minutes of sequence inside the MR

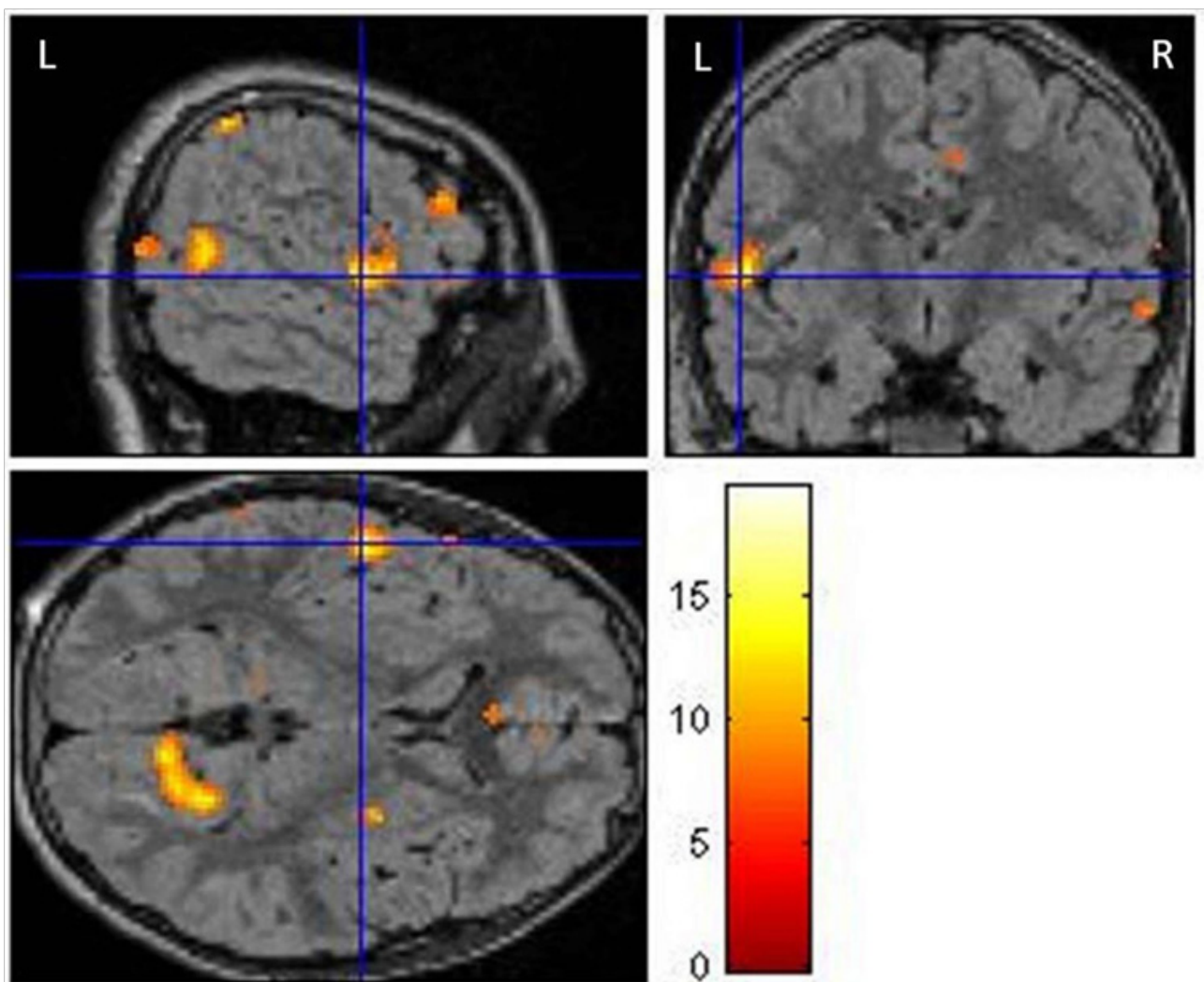


Figure 4 The final localization of the irritative zone after EEG-fMRI co-registration.

scanner. Nonetheless, the inter-ictal spikes and corresponding BOLD responses have given fairly accurate representations of the underlying irritative zone. Different parameters were used by various researchers like different statistical methods, replicability within subjects, number of electrodes (16, 32, 64, etc.) and the methods of electrode placement, and relationships to regions and/or other abnormality seen in the MRI (e.g. atrophy, malformations, etc.).

One of the first simultaneous and continuous EEG-fMRI studies in clinical practice was performed by Zijlmans *et al*^[6] where he evaluated 29 patients previously rejected for surgery. These patients showed no clear localizations or multifocality in imaging modalities like PET, SPECT, MEG and/or intra cranial EEG (icEEG). The study proved useful for 8 patients out of which 4 underwent successful surgery (14% of the original cohort). One of the patients, presumed to be having frontal lobe epilepsy but inconclusive findings in the modalities mentioned above, showed maximum activation of EEG-fMRI in the left basifrontal region which was confirmed by icEEG and was surgically resected. This study brought to light the usefulness of EEG-fMRI in decision-making for surgery when other methods do not help.

Aghakhani *et al*^[24] conducted a study on idiopathic generalized epilepsy patients in which 14 out of 15 patients showing generalized spike or poly-spikes also showed concordant BOLD response.

A unique feature about the response was that activation response was found mostly in the thalamus and bilaterally symmetrical and widespread deactivation responses were found in some cortical areas. This study further suggested that thalamo-cortical circuits are involved in this epilepsy.

A case study by Sercheli *et al*^[8] demonstrated the BOLD response associated with interictal activity in a patient with mesial temporal epilepsy before and after amygdalohippocampectomy. Their study showed that in some complicated cases the EEG alone was too ineffective in localizing the epileptogenic zone and a combined modality like EEG-fMRI can greatly aid in the localization and eventual success of the epilepsy surgery.

Thornton *et al*^[23] studied 76 refractory epilepsy patients undergoing pre-surgical evaluation. Though the EEG-fMRI procedure did not form any basis for the surgery, it still gave useful information on concordance between maximum BOLD activation, the resected area and the surgical outcome. In this study, 10 patients underwent surgery, 6 patients underwent anterior temporal lobe resection and 4 underwent neocortical resection (2 frontal, 1 parietal, 1 occipital). 33% ($n=21$) of the patients showed high activation in the BOLD study in resected areas. There was a direct and proportional relationship between the success of the surgery and the resection of the area showing high BOLD response in EEG-fMRI.

Table 2 Summary of simultaneous EEG-fMRI recording and co-registration.

Steps	Data acquisition	Pre-processing	Post-processing	Analysis	Co-registration
EEG	With MR compatible electrodes placed in the 10-20 system	Artefact reduction: both gradient and pulse artefact and applying a low and high pass filter (usually 1 and 70 Hz respectively)	Marking the IEDs	After the IEDs are marked and the temporal information used to construct fMRI images, EEG is not analyzed further	fMRI co-registered data is used to solve the "inverse problem"
fMRI	Gradient echo- EPI sequence with short TE, long TR and 20-40 slices for BOLD signal and a structural T1 weighted image to co-register with.	Realignment, spatial smoothing, slice time correction, normalization	Constructing GLM statistical maps, ICA, taking time points for measuring BOLD activity, marking ROIs, ICA source distribution analysis	The HRF and corresponding BOLD response is measured	EEG co-registered data is used to derive neuronal and hemodynamic models of the IEDs

fMRI: functional MRI; EPI: echo planar imaging; BOLD: blood oxygen level dependent; IEDs: interictal epileptiform discharges; GLM: generalised linear model; ROI: region of interest; ICA: independent component analysis.

Table 3 EEG-fMRI and BOLD activation studies in pre-surgical workup of epilepsy.

Author,Year	Description	Remarks
Al Asmi <i>et al</i> ^[5] 2003	48 studies performed on 38 patients both lesional and non-lesional cases were included	EEG-fMRI activations were concordant with EEG and icEEG in both MRI lesion positive and negative patients. Activations recorded near or in the epileptogenic lesion.
Zijlmans <i>et al</i> ^[6] 2007	29 subjects, they did not show good source localization with traditional methods. 4 patients underwent surgery successfully.	EEG-fMRI proved to be helpful in decision making and in detecting suspected multi-focality of the seizure onset zone.
Sercheli <i>et al</i> ^[8] 2009	A patient with MTLE was selected and the EEG-fMRI response was evaluated before and after surgery. The surgery was successful and gave relief to the refractory patient.	EEG-fMRI proved to be helpful in the complicated case where traditional methods did not localize the seizure onset zone with convincing accuracy.
Thornton <i>et al</i> ^[23] 2010	76 refractory epilepsy cases were studied. 10 underwent surgery. EEG-fMRI not used in surgical decision making but showed usefulness in source localization	EEG-fMRI showed direct co-relation between resection of maximum BOLD activated area and degree of seizure freedom post surgery. Hence proving its use as a non-invasive tool in seizure onset zone localization.
van Houdt <i>et al</i> ^[28] 2013	16 patients recruited and their EEG-fMRI data were compared with interictal ECoG and post surgical MRI. No fixed set of HRFs was taken but HRF and corresponding BOLD was observed at varying time points.	Showed that all epilepsy patients do not conform to standard HRFs and also emphasized that it helps to reveal the propagation pattern of epileptic networks
Flanagan <i>et al</i> ^[20] 2014	EEG-fMRI in 27 patients with focal epilepsy to identify networks	Similarity found in networks involved confirming pyriform cortex as the common node in the generation of IEDs
Coan <i>et al</i> ^[29] 2015	EEG-fMRI in 30 patients with TLE and compared the BOLD activated zone with the resected zone. IED topography maps used to correlate with the HRF in patients not having IEDs during scanning	BOLD activation within or in the 2cm vicinity of the resected zone (concordance) had good long-term post surgical outcome

icEEG: intracranial EEG; MTLE: mesial temporal lobe epilepsy; HRF: hemodynamic response function; ECoG: electrocorticography; IEDs: inter ictal epileptiform discharges; BOLD: blood oxygen level dependent.

van Houdt *et al.*^[28] studied EEG-fMRI correlation with the assumption that the peak time for HRF can be different in epileptic patients and thus instead of using set of fixed HRFs, they studied it at various time points using finite impulse model. This helped in examining the onset and propagation areas in the form of BOLD clusters of neighboring voxels at varying HRF time points. The concordance of the resected zone to the BOLD area was determined by icEEG and post operative MRI correlated with pre operative structural T1 weighted image. 75 % of inter ictally active areas encompassed complete seizure onset zone and in all patients at least one BOLD cluster overlapped with these areas. They also proved that less stringent threshold values that decreases specificity and increases sensitivity can be of value when EEG-fMRI data are used to guide subdural grid placement.

Coan *et al.*^[29] performed presurgical EEG-fMRI in 30 patients and did a post surgical follow-up of 46 months. Scalp voltage topography maps were constructed. These maps used the average topography of IEDs recorded outside the scanner for long sessions that built the predictive map of the epileptic activity. Concordance of the IED related BOLD maps with the zone of resection (within or in its 2cm vicinity) showed good prognosis and seizure freedom in 53% of the patients.

CONCLUSIONS

EEG-fMRI co-registration can be a non-invasive tool for pre-surgical evaluation of refractory epilepsy and its use is most appreciated in lesion negative cases. But it should be admitted that the current data is not sufficient to assess its sensitivity and specificity and that future research in this field is necessary before it can be incorporated as a routine pre-surgical workup tool. However, EEG-fMRI co-registration can better guide intra-cranial electrode placements and thus helps in more accurate epileptic source localization. In cases where traditional methods point towards multi-focality, it can be used to confirm the hypothesis. EEG-fMRI co-registration can also be used to better assess the effect of surgery on language, memory and cognitive functions. The future research demands for comparative studies with other multimodality approaches like PET, SPECT, MEG, icEEG, etc. to determine the most efficient, patient friendly and accurate method for pre-surgical localization of the epileptogenic source or rather a combined multimodality approach should be the choice.

REFERENCES

- 1 Reynolds EH. The ILAE/IBE/WHO Global Campaign against Epilepsy: Bringing Epilepsy "Out of the Shadows." *Epilepsy Behav.* 2000; **1**: S3-S8.
- 2 Ives JR, Warach S, Schmitt F, Edelman RR, Schomer DL. Monitoring the patient's EEG during echo planar MRI. *Electroencephalogr. Clin. Neurophysiol.* 1993; **87**: 417-420
- 3 Krakow K, Woermann FG, Symms MR, Allen PJ, Lemieux L, Barker GJ, Duncan JS, Fish DR. EEG-triggered functional MRI of interictal epileptiform activity in patients with partial seizures. *Brain J. Neurol.* 1999; **122**: 1679-1688.
- 4 Lazeyras F, Blanke O, Perrig S, Zimine I, Golay X, Delavelle J, Michel CM, de Tribolet N, Villemure JG, Seck M. EEG-triggered functional MRI in patients with pharmacoresistant epilepsy. *J. Magn. Reson. Imaging JMRI* 2000; **12**: 177-185.
- 5 Al-Asmi A, Bénar C-G, Gross DW, Khani YA, Andermann F, Pike GB, Dubeau F, Gotman J. fMRI activation in continuous and spike-triggered EEG-fMRI studies of epileptic spikes. *Epilepsia* 2003; **44**: 1328-1339.
- 6 Zijlmans M, Huiskamp G, Hersevoort M, Seppenwoolde JH, van Huffelen AC, Leijten FSS. EEG-fMRI in the preoperative work-up for epilepsy surgery. *Brain J. Neurol.* 2007; **130**: 2343-2353
- 7 Pittau F, Dubeau F, Gotman J. Contribution of EEG/fMRI to the definition of the epileptic focus. *Neurology* 2012; **78**: 1479-1487.
- 8 Sercheli MS, Bilevicius E, Alessio A, Ozelo H, Pereira FRS, Rondina JM, Cendes F, Covolan RJM. EEG spike source localization before and after surgery for temporal lobe epilepsy: a BOLD EEG-fMRI and independent component analysis study. *Braz. J. Med. Biol. Res. Rev. Bras. Pesqui. Médicas E Biológicas Soc. Bras. Biofísica AI* 2009; **42**: 582-587.
- 9 Salek-Haddadi A, Friston KJ, Lemieux L, Fish DR. Studying spontaneous EEG activity with fMRI. *Brain Res. Brain Res. Rev.* 2003; **43**: 110-133.
- 10 Bénar C-G, Grova C, Kobayashi E, Bagshaw AP, Aghakhani Y, Dubeau F, Gotman J. EEG-fMRI of epileptic spikes: concordance with EEG source localization and intracranial EEG. *NeuroImage* 2006; **30**: 1161-1170
- 11 de Munck JC, Gonçalves SI, Huijboom L, Kuijper JP, Pouwels PJ, Heethaar RM, Lopes da Silva FH. The hemodynamic response of the alpha rhythm: an EEG/fMRI study. *Neuro Image* 2007; **35**: 1142-1151.
- 12 Jacobs J, Levan P, Moeller F, Boor R, Stephani U, Gotman J, Siniatchkin M. Hemodynamic changes preceding the interictal EEG spike in patients with focal epilepsy investigated using simultaneous EEG-fMRI. *Neuro Image* 2009; **45**: 1220-1231.
- 13 Laufs H, Lengler U, Hamandi K, Kleinschmidt A, Krakow K. Linking generalized spike-and-wave discharges and resting state brain activity by using EEG/fMRI in a patient with absence seizures. *Epilepsia* 2006; **47**: 444-448.
- 14 Ogawa S, Tank DW, Menon R, Ellermann JM, Kim SG, Ugurbil K. Intrinsic signal changes accompanying sensory stimulation: functional brain mapping with magnetic resonance imaging. *Proc. Natl. Acad. Sci. U. S. A.* 1992; **89**: 5951-5955.
- 15 Raichle ME, MacLeod AM, Snyder AZ, Powers WJ, Gusnard DA, Shulman GL. A default mode of brain function. *Proc. Natl. Acad. Sci. U. S. A.* 2001; **98**: 676-682.
- 16 Chatton J-Y, Pellerin L, Magistretti PJ. GABA uptake into astrocytes is not associated with significant metabolic cost: implications for brain imaging of inhibitory transmission. *Proc. Natl. Acad. Sci. U. S. A.* 2003; **100**: 12456-12461.
- 17 Stefanovic B, Warnking JM, Pike GB. Hemodynamic and metabolic responses to neuronal inhibition. *Neuro Image* 2004; **22**: 771-778.
- 18 Lemieux L, Allen PJ, Krakow K, Symms MR, Fish DR. Methodological issues in EEG correlated functional MRI experiments. *International Journal of Bioelectromagnetism* 1999; **1(1)**: 87-95.
- 19 Gotman J, Kobayashi E, Bagshaw AP, Bénar C-G, Dubeau F. Combining EEG and fMRI: A multimodal tool for epilepsy research. *J. Magn. Reson. Imaging* 2006; **23(6)**: 906-920.
- 20 Flanagan D, Badawy R, Jackson GD. EEG-fMRI in focal epilepsy: local activation and regional networks. *Clin. Neurophysiol.* 2014; **125**: 21-31.
- 21 Bagshaw AP, Aghakhani Y, Bénar C-G, Kobayashi E, Hawco C, Dubeau F, Pike GB, Gotman J. EEG-fMRI of focal epileptic spikes: analysis with multiple haemodynamic functions and comparison with gadolinium-enhanced MR angiograms. *Hum. Brain Mapp.* 2004; **22**: 179-192.
- 22 Borelli P, Avesani M, Formaggio E, Storti SF, Zanoni T, Moretto G, Flasci A, Cerini R, Manganotti P. EEG-fMRI as an useful tool to detect epileptic foci associated with secondary bilateral synchrony. *Seizure* 2010; **19**: 605-608.
- 23 Thornton R, Laufs H, Rodionov R, Cannadathu S, Carmichael DW, Vulliemoz S, Salek Haddadi A, McEvoy AW, Smith SM, Lhatoo S, Elwes RD, Guye M, Walker MC, Lemieux L, Duncan JS. EEG correlated functional MRI and postoperative outcome in focal epilepsy. *J. Neurol. Neurosurg. Psychiatry* 2010; **81**: 922-

- 927.
- 24 Aghakhani Y, Bagshaw AP, Bénar CG, Hawco C, Andermann F, Dubeau F, Gotman J. fMRI activation during spike and wave discharges in idiopathic generalized epilepsy. *Brain J. Neurol.* 2004; **127**: 1127-1144.
 - 25 Liston AD, De Munck JC, Hamandi K, Laufs H, Ossenblok P, Duncan JS, Lemieux L. Analysis of EEG-fMRI data in focal epilepsy based on automated spike classification and Signal Space Projection. *Neuro Image* 2006; **31**: 1015-1024.
 - 26 Bettus G, Wendling F, Guye M, Valton L, Régis J, Chauvel P, Bartolomei F. Enhanced EEG functional connectivity in mesial temporal lobe epilepsy. *Epilepsy Res.* 2008; **81**: 58-68.
 - 27 Hauf M, Jann K, Schindler K, Scheidegger O, Meyer K, Rummel C, Mariani L, Koeing T, Wiest R. Localizing seizure-onset zones in presurgical evaluation of drug-resistant epilepsy by electroencephalography/fMRI: effectiveness of alternative thresholding strategies. *AJNR Am. J. Neuroradiol.* 2012; **33**: 1818-1824.
 - 28 van Houdt PJ, de Munck JC, Leijten FSS, Huiskamp GJ, Colon AJ, Boon PA, Ossenblok PP. EEG-fMRI correlation patterns in the presurgical evaluation of focal epilepsy: a comparison with electrocorticographic data and surgical outcome measures. *Neuro-Image* 2013; **75**: 238-248.
 - 29 Coan AC, Chaudhary UJ, Grouiller F, Campos BM, Perani S, De Ciantis A, Vulliemoz S, Diehl B, Beltramini GC, Carmichael DW, Thornton RC, Covolan RJ, Cendes F, Lemieux L. EEG-fMRI in the presurgical evaluation of temporal lobe epilepsy. *J. Neurol. Neurosurg. Psychiatry* 2015; **20**:310-314.
- Peer reviewer:** Maria Emilia Cosenza Andraus, MD, PhD, Associate Professor, Santa Casa Da Misericórdia Do Rio De Janeiro, 25th Infirmary, Neurology Service, Rua Santa Luzia, 206, 20020-022, Rio De Janeiro, Rj, Brazil.