

CASE REPORT

Rare Ischemic Stroke Presentation after Viper Bite-A Case Report

Rajib Paul, Swagat A Sasane

Rajib Paul, Departments of Medicine and Critical Care, Apollo Hospital, Hyderabad, India

Swagat A Sasane, Resident DNB, Apollo Hospital, Hyderabad, India

Conflict-of-interest statement: The author(s) declare(s) that there is no conflict of interest regarding the publication of this paper.

Open-Access: This article is an open-access article which was selected by an in-house editor and fully peer-reviewed by external reviewers. It is distributed in accordance with the Creative Commons Attribution Non Commercial (CC BY-NC 4.0) license, which permits others to distribute, remix, adapt, build upon this work non-commercially, and license their derivative works on different terms, provided the original work is properly cited and the use is non-commercial. See: <http://creativecommons.org/licenses/by-nc/4.0/>

Correspondence to: Rajib Paul, Senior Consultant Physician and Intensivist, Apollo hospital, Hyderabad, India.

Email: drajibpaul@gmail.com

Telephone: + 9849079541

Fax: + 91-40-23608050

Received: December 31, 2016

Revised: February 28, 2017

Accepted: March 2, 2017

Published online: March 20, 2017

ABSTRACT

We present a case of 75 year old male patient who was brought to the hospital with history of unconsciousness, 6 hours, following viper bite. CT scan of brain showed multiple infarcts in right temporal and in cerebellar hemisphere. Neurological manifestations following snake bite is mainly to hemorrhagic complications. Presentation with infarction is rare and it can be attributed to various factors such as vasculitis, vasospasm, endothelial damage; toxin induced procoagulant effect and disseminated intravascular coagulation.

Key words: Snakebite; Viper; Infarct; Ischemic stroke

© 2017 The Author(s). Published by ACT Publishing Group Ltd. All rights reserved.

Paul R, Sasane SA. Rare Ischemic Stroke Presentation after Viper Bite-A Case Report. *International Journal of Neurology Research* 2016; **3(1)**: 335-337 Available from: URL: <http://www.ghrnet.org/index.php/ijnr/article/view/1955>

INTRODUCTION

According to WHO direct estimate, India measures highest number of cases of snake bites worldwide with a mortality of 35,000 to 50,000 cases per year^[1]. Predominantly, bites are more frequent among males, in the lower limb and during rainy season^[2]. Envenomation occurs in 10-80% of the snake bites^[1]. Viper being the most common cause of bite^[1-4], local envenomation is the frequent manifestation, followed by haemostatic abnormalities and neurotoxicity^[2,3,4]. coagulopathy, if present, is diagnostic of viper bites in South Asia^[1]. Viper bites have been associated rarely with cerebrovascular accidents, most commonly due to hemorrhagic and rarely due to infarct^[5]. Ischemic stroke following viper bite is rare. Most common and serious central nervous system complication following snake bite is intracranial hemorrhage. Ischemic stroke commonly involves anterior circulation. Here we describe a polyvalent anti-venom treated patient with multiple infarcts in right temporal and in cerebellar hemisphere.

CASE REPORT

We report a case of posterior circulation ischemic infarction following viper bite in a previously healthy man. A 75-year-old healthy man with history of DM type 2 on OHA was admitted with history of snake bite on his right foot. The snake was identified as Russell's viper, as per the descriptions given by relatives. A few minutes after the bite, patient noticed minimal swelling over the right foot and over ankle joint. Two hours later, patient deteriorated and became unconscious. Patient was taken to local hospital. CT scan brain was done which was normal. There was no history of convulsion or any bleeding manifestations. Patient was hemodynamically stable. He was treated with 30 vials of polyvalent anti-snake venom (ASV).

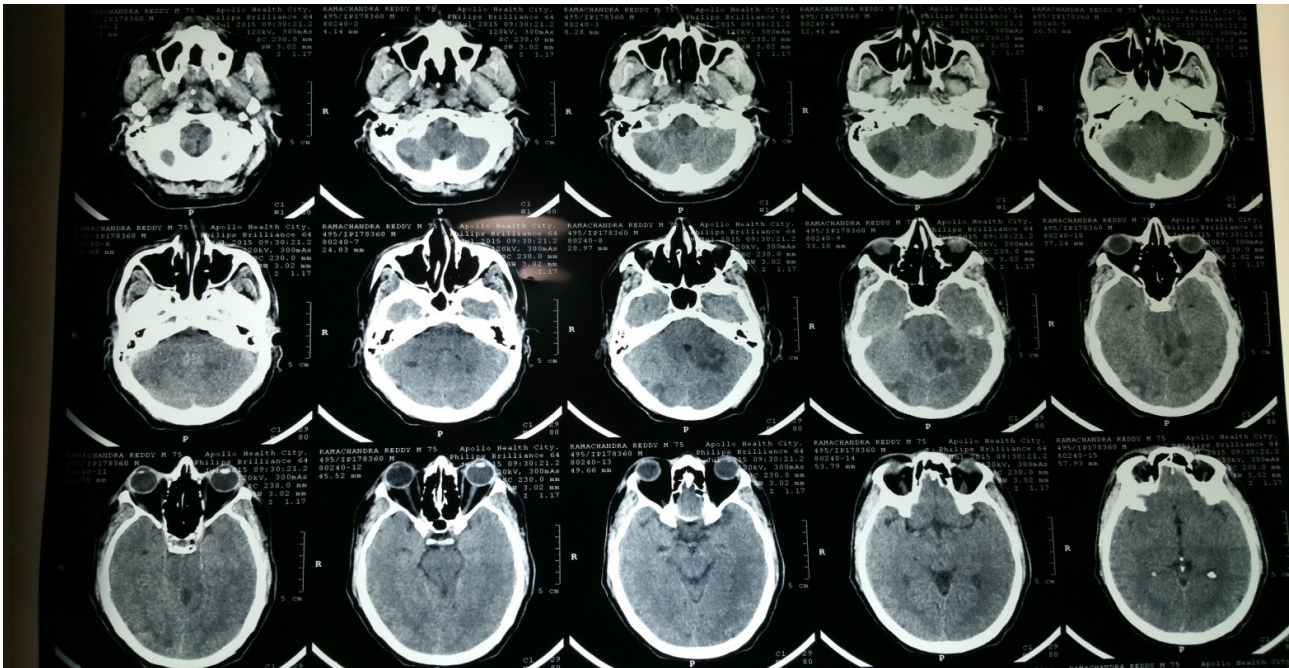


Figure 1 CT brain - patchy hypodensities in b/l cerebellar lobes, the superior vermis and the right inferior temporo occipital lobe.

Next day, after 24 hrs of snake bite patient developed weakness of right upper limb and lower limb. Repeat CT scan brain was done. Patchy hypodensities in bilateral cerebellar lobes, the superior vermis and the right inferior temporooccipital lobe were observed (Figure 1). Patient referred to our hospital for further management. On arrival patient was drowsy with weakness of right upper and lower limb, pupils were bilaterally reacting. Chest X-ray showed bilateral infiltrates. Complete blood count showed leukocytosis, PT, aPTT were prolonged, mildly elevated total bilirubin and creatinine (Table 1), 2D echo was normal. In view of increased breathing effort patient was intubated and kept on ventilator support. Tracheostomy was performed in view of early weaning, pooling of secretions and weak cough reflex. Patient was treated with prophylactic antibiotics, sedation, ventilation and physiotherapy. Patient responded to treatment and discharged in stable condition.

DISCUSSION

Viper bite is the most frequent snake bite in the Indian subcontinent. The presentation of envenomation by viper bite leads to local envenomation, followed by abnormal coagulation^[6]. The various toxins present in the viper venom can be categorized both as pro-coagulant and anticoagulant. The toxins with well established pro-coagulant/platelet aggregating properties are cerastobin^[6], factor IVa^[7], cerastocytin^[8], cerastotin^[9], and afaacytin^[10]. These various protein products have thrombin like enzymatic activity. Different toxins activate different parts of the coagulation cascade^[6-10]. Their activity is inhibited by monoclonal antibodies against GP1b or GPIIb/IIIa or thrombin receptor.

Disseminated intravascular coagulation and hypotension are also the associated risk factors in viper bite patients. Disseminated intravascular coagulation can be a cause of neurological disorder, largely due to vessel occlusion^[11]. The toxin itself can cause vasospasm which can lead to a cerebrovascular accident.

Reported case reports of infarct following snake bite are majorly due to viper bite. Most of the patients had features of local envenomation with disseminated intravascular coagulation. The

Table 1 Laboratory investigations.

Sl.no.	Laboratory parameters (units)	Value
1	Hb (g/dL)	11.3
2	PCV (%)	33
3	Platelets (/mcL)	1,04,000
4	TLC (/mcl)	19,400
5	PT (sec)	17.6
6	INR	1.45
8	D-dimer (FEU/mL)	2000
9	Fibrinogen (mg/dL)	293
10	LDH (U/L)	281
11	Bilirubin(mg/dL) Direct	3 1.5
12	SGOT(IU/L)	31
13	SGPT(IU/L)	38
14	Albumin(g/dL)	3
15	Prealbumin(mg/dL)	21
16	Urea (mg/dL)	47
17	Creatinine(mg/dL)	1.6
18	Uric acid(mg/dL)	4.3

infarct commonly involved the anterior circulation, with hemiparesis being the frequent presentation^[12-15]. As a matter of fact, cerebral infarction after snake envenomation is a complex multifactorial mechanism. It includes direct cardiotoxic effects of venom leading to dysrhythmias. This may cause cardiac thromboembolism and hyperviscosity due to hypovolemia and hypoperfusion secondary to hypotension. In a study by Thomas, *et al*^[16] it has been demonstrated that administration of the anti-snake venom within six hours of the viper bite, may prevent associated complications.

CONCLUSION

After viper bite, neurological manifestations can be attributed to various reasons, such as toxin induced vasculitis, procoagulant effect, endothelial damage, disseminated intravascular coagulation and hypotension. Needless to say, in a snake bite prone country like India, it is necessary to evaluate the incidence of ischemic stroke or neurological disorder and possible viper bite. The early detection of

the viper bite and administration of anti-snake venom can prevent this rare but devastating complication.

REFERENCES

- Alirol E, Sharma SK, Bawaskar HS, Kuch U, Chappuis F. Snake bite in South Asia: a review. *PLoS Negl Trop Dis*. 2010; **4**: Art.630. [PMID: 20126271]; [DOI: 10.1371/journal.pntd.0000603]
- Mohapatra B, Warrell DA, Suraweera W, Bhatia P, Dhingra N, Jotkar RM, Rodriguez PS, Mishra K, Whitaker R, Jha P; Million Death Study Collaborators. Snakebite mortality in India: a nationally representative mortality survey. *PLoS Negl Trop Dis*. 2011; **5**: Art.1018. [PMID: 21532748]; [DOI: 10.1371/journal.pntd.0001018]
- Inamdar IF, Aswar NR, Ubaidulla M, Dalvi SD. Snakebite: Admissions at a tertiary health care in Maharashtra, India. *S Afr Med J* 2010; **100**: 456-8. [PMID: 20822595]
- Kulkarni ML, Anees S. Snake venom poisoning: Experience with 633 cases. *Indian Pediatr* 1994; **31**: 1239-43. [PMID: 7875785]
- Mosquera A, Idrovo LA, Tafur A, Del Brutto OH. Stroke following *Bothrops* Spp. Snake bite. *Neurology* 2003; **60**: 1577-80. [PMID: 12771244]
- Farid TM, Tu AT, el-Asmar MF. Effect of cerastobin, a thrombinlike enzyme from *Cerastes viper* (Egyptian sand snake) venom, on human platelets. *Haemostasis* 1990; **20**: 296-304. [PMID: 1963167]
- Basheer AR, el-Asmar MF, Soslau G. Characterization of a potent platelet aggregation inducer from *Cerastescerastes*(Egyptian sand viper) venom. *Biochim Biophys Acta* 1995; **1250**: 97-109. [PMID: 7612660]
- Dekhil H, Wasner A, Marrakchi N, Ayed M, Bon C, Karoui H. Molecular cloning and expression of a functional snake venom serine proteinase, with platelet aggregating activity, from *Cerastes viper*. *Biochemistry* 2003; **42**: 10609-18. [PMID: 12962484]
- Marrakchi N, Barbouche R, Guermazi S, Karoui H, Bon C, el-Ayeb M. Cerastotin, a serine protease from *Cerastescerastes* venom, with platelet-aggregating and agglutinating properties. *Eur J Biochem*. 1997; **247**: 121-8. [PMID: 9249017]
- Laraba-Dejabri F, Martin-Eauclaire MF, Mauco G, Marchot P. Afaacytin, an alpha beta- Fibrinogenase from *erastescerastes*(horned viper) venom, activates purified factor X and induces serotonin release from human blood platelets. *Eur J Biochem* 1995; **233**: 756-65. [PMID: 8521839]
- Scwartzmann RJ, Hill JB. Neurological complications of disseminated intravascular coagulation. *Neurology* 1982; **32**: 791-7. [PMID: 7201575]
- Rebahi H, Nejmi H, Abouelhassan T, Hasni K, Samkaoui MA. Severe envenomation by *Cerastescerastes* viper: An unusual mechanism of acute ischemic stroke. *J Stroke Cerebrovasc Dis* 2014; **23**: 169-72. [PMID: 22964421]; [DOI: 10.1016/j.jstrokecerebrovasdis.2012.07.008]
- Pal J, Mondal S, Sinha D, Ete T, Chakraborty A, Nag A, Sarkar G, Saha B. Cerebral infarction: An unusual manifestation of viper snake bite. *Int J Med Sci* 2014; **2**: 1180-3. [DOI: 10.5455/2320-6012.ijrms20140836]
- Paul G, Paul BS, Puri S. Snake bite and stroke: Our experience of two cases. *Indian J Crit Care Med* 2014; **18**: 257-8. [PMID: 24872661; doi: 10.4103/0972-5229.130585]
- Narang SK, Paleti S, AzeezAsad MA, Samina T. Acute ischemic infarct in the middle cerebral artery territory following a Russell's viper bite. *Neurol India*. 2009; **57**: 479-80. [PMID: 19770552; DOI: 10.4103/0028-3886.55594]
- Thomas L, Tyburn B, Bucher B, Pecout F, Ketterle J, Rieux D, Smadja D, Garnier D, Plumelle Y. Prevention of thrombosis in human patients with *Bothrops lanceolatus* envenoming in Martinique: Failure of anticoagulants and efficacy of a monospecific antivenom. Research Group on snake bites in Martinique. *Am J Trop Med Hyg* 1995; **52**: 419-26. [PMID: 7771608]

Peer reviewer: Riwayat Bhagat