

## Cerebral Function Monitoring In Neonatal Intensive Care Units

Aysen Orman, Nilay Hakan, Atika Çağlar, Mustafa Aydin

Aysen Orman, Atika Çağlar, Mustafa Aydin, Department of Pediatrics-Neonatology, Firat University School of Medicine, Elazig, Turkey

Nilay Hakan, Department of Pediatrics-Neonatology, Sitki Kocman University School of Medicine, Mugla, Turkey

**Conflict-of-interest statement:** The author(s) declare(s) that there is no conflict of interest regarding the publication of this paper.

**Open-Access:** This article is an open-access article which was selected by an in-house editor and fully peer-reviewed by external reviewers. It is distributed in accordance with the Creative Commons Attribution Non Commercial (CC BY-NC 4.0) license, which permits others to distribute, remix, adapt, build upon this work non-commercially, and license their derivative works on different terms, provided the original work is properly cited and the use is non-commercial. See: <http://creativecommons.org/licenses/by-nc/4.0/>

**Correspondence to:** Mustafa Aydin, MD, Department of Pediatrics-Neonatology, Firat University School of Medicine, 23119, Elazig, Turkey.

Email: [dr1mustafa@hotmail.com](mailto:dr1mustafa@hotmail.com)

Telephone: +90 (424) 233 35 55

Fax: +90 (424) 238 80 96

Received: June 19, 2018

Revised: November 27, 2018

Accepted: November 30, 2018

Published online: December 23, 2018

### ABSTRACT

**AIM:** Cerebral function monitoring with amplitude-integrated electroencephalography (aEEG) device is a method for continuous monitoring of brain activity that is increasingly use in neonatal intensive care units.

**METHODS:** In its simplest form, aEEG is a processed single-channel EEG that is filtered and time-compressed. Several classifications are currently in use to describe patient's tracings, voltage criteria, pattern recognition, cyclicity, and the presence of seizures.

**RESULTS:** The main usage of the aEEG currently is for select newborns with birth asphyxia who benefit from therapeutic

hypothermia and for predict of their long-term neurological prognosis. The early aEEG traces of preterm infants also predict of their neurodevelopmental outcome. Current evidences demonstrated that aEEG is useful for define cerebral background activity, detect seizures, monitor treatment effects and predict neurodevelopmental outcomes of newborns. The main advantages of this device are its simplicity for both application and interpretation on one hand and the possibility of continuous long-term monitoring with real time assessment of clinical events on the other.

**CONCLUSION:** aEEG is a safe and reliable method for the bedside monitoring of neonatal cerebral function and it can also provide information about long-term neurological prognosis.

**Key words:** Cerebral function monitoring; Amplitude-integrated electroencephalography; Newborn infant; Treatment; Prognosis

© 2018 The Author(s). Published by ACT Publishing Group Ltd. All rights reserved.

Orman A, Hakan N, Çağlar A, Aydin M. Cerebral Function Monitoring In Neonatal Intensive Care Units. *International Journal of Neurology Research* 2018; **4(1)**: 464-471 Available from: URL: <http://www.ghrnet.org/index.php/jnr/article/view/2366>

### EDITORIAL

The amplitude-integrated electroencephalogram (aEEG) is a filtered and time-compressed EEG traces that can be used for long-term cerebral function monitoring (CFM) in patients of all ages. The difficulty of using conventional electroencephalogram (cEEG) in neonatal intensive care units (NICUs) has led to the introduction of the aEEG as an auxiliary device for CFM. Nevertheless, cEEG remains the gold standard in identification and localization of neonatal seizures.

The aEEG device was originally developed by Maynard and Prior in 1960<sup>[1,2]</sup>. It has been used in different age groups until now ranging from open heart surgeries to premature infants follow up in NICUs<sup>[3,4]</sup>. Currently, it is mostly used for decision making about starting therapeutic hypothermia and clinical follow-up of full-term neonates with perinatal hypoxic ischemic encephalopathy (HIE). aEEG has also been shown to be useful in predicting neurodevelopmental outcome of neonates with HIE. Another area where aEEG is used is the identification of seizures and the assessment of the effectiveness

of used therapies<sup>[5,6]</sup>. Recently, it has also been used to determine the effects of pulmonary hypertension and congenital heart diseases on the brain.

Studies have shown that there is a good correlation between aEEG and conventional EEG signals. The aEEG is usually recorded from one or two channels derived from parietal, central, or frontal electrodes. Therefore, it is considered as a single-channel EEG monitor<sup>[7,8]</sup>. aEEG is based upon cEEG that is recorded with two or four scalp electrodes, depicting the amplitude of the raw EEG on a time-compressed semi-logarithmic scale. The electrodes of the device are placed on biparietal P3-P4 or central C3-C4 localizations (**Figure 1**)<sup>[9]</sup>. The signals from these regions are amplified first and then recorded at a rate of 6 cm per hour after being filtered through various filters to purify the artifacts caused by muscle activities or surrounding electronic devices<sup>[10]</sup>. aEEG can be affected by other technical factors such as respiratory movements, interelectrode distance, head skin edema, electrocardiographic artifacts, and high frequency ventilation. Muscle or movement artefacts can result in a broad band or sudden changes activity recordings. Repetitive movements cause a similar appearance to seizure activity. Therefore, the artifacts should always be excluded and EEG traces without artifacts should be evaluated<sup>[11]</sup>. Hence, it is also important to control the impedance of the aEEG, which reflects the quality of contact between the skin and the electrode. Poor contact or low impedance can cause to emergence of artifacts and so artificially increase of the voltage of aEEG. Silver-silver electrodes and coaxial cables which traditionally used in the original aEEG device reduce the artefacts that are caused by motion or equipment<sup>[12,13]</sup>.

A special bandpass filter enhances frequencies between 2 and 15 Hz. Frequencies < 2 Hz and > 15 Hz are attenuated in order to eliminate artefacts. Amplitudes <10  $\mu$ V are displayed on a linear scale and amplitudes >10  $\mu$ V on a logarithmic scale. The lowest-detected amplitude is shown as the lower border, and the highest amplitude is shown as the upper border. By this means, even small changes in the lower amplitude remain visible, while an overloading of the display at high amplitudes is avoided. Due to time compression, 5 - 6 cm on the time scale represents 1 h, thus making the review of brain activity for hours and even days possible<sup>[14,15]</sup>. The visible information in the aEEG traces is limited to changes of the amplitude. Modern devices offer the possibility of viewing the raw EEG, so the frequency and morphology of the raw EEG curve can also be considered for interpretation. This helps to distinguish between artefacts and real seizure activity during suspicious sections of the aEEG band. Broad-band filter often rejects the less than 2 activities per second<sup>[14]</sup>.

Although aEEG offers the possibility for continuous CFM in neonates, it gives less information than a cEEG. The cEEG, using the international 10-20 system of electrode placement, is considered the gold standard for detecting electro-clinical or electrographic seizures, but the short duration of routine EEG may miss clinical or electrographic seizures. Moreover, it requires the compensator equipment and evaluation by a specialized neurologist. Another EEG monitoring protocol is continuous video-EEG. The American Clinical Neurophysiology Society guideline recommends that continuous EEG monitoring combined with synchronized video-EEG can be used for high-risk patients, including those with HIE, to screen for seizure activity. However, aEEG is straightforward to apply and can be monitored by neonatologists or nurses. More than half of neonatologists are utilize aEEG with practice variations by NICU settings<sup>[16]</sup>. But, in the study of Rakshashbuvankar et al. where aEEG and conventional video EEG was compared<sup>[17]</sup>, aEEG had low (33.7%) sensitivity for detecting the seizures lasting less than 5 minutes.

Hence, this review aims to explain the fundamentals and clinical applications of the aEEG for clinical practitioners.

### aEEG classification

The standard aEEG contains minimum and maximum peak variability of the filtered EEG amplitude. It appears as an activity band passing slowly on the display screen. The width of the band indicates the variability in the aEEG amplitude. In healthy newborns, there are regular changes in the width of the band according to the sleep-wake state and fluctuates between approximately 10 and 40  $\mu$ V (**Figure 2A**)<sup>[18,19]</sup>. The interpretation of the EEG is basically based on the sleep-wake cycles (SWCs) and the presence of seizures (**Table 1**).

### aEEG traces

Background activity in the aEEG trace is an indicator of electrical activity. Background activity varies with gestational age and drug exposure. In small preterm babies, the aEEG background is discontinuous with episodes of high amplitude activity alternate with low amplitude activity. As the gestational age increases, the aEEG background pattern becomes continuous as in full-term babies<sup>[20]</sup>. The aEEG background patterns are classified according to the upper and lower limit values of the activity bands (**Table 2**).

Two major factors in the classification of aEEG traces are voltage and pattern. Voltages in the trace are classified as normal, abnormal, and low. Interpretation of the aEEG usually involves three categories; (a) classification of the background pattern, (b) SWC and (c)

Use the positioning strips to ensure that the needles are correctly sited, or else the tracing is very hard to interpret.

Step	Action
1	Position infant supine
2	Place the sensor positioning strip vertical and parallel to the face, and align it so that the letter (A, B etc) is the same at both the ear tragus and on the sagittal suture. The forward edge of the strip should touch the ear tragus. A close up view of the strip is presented in Appendix 3
3	Mark the sites for electrode insertion on either side of the two-headed arrow on the positioning strip. Note: DO NOT shave these insertion marks.
4	Clean the scalp around the insertion sites with cleaning solution appropriate for gestation age. It may help to create a vertical part in the hair.
5	Site electrodes in the following manner. Insert a needle electrode subdermally at insertion sites. Ensure all leads are directed to the top of the head (so needles angle downwards) Secure electrode with a small amount of tape using a cross over method Connect electrodes to the sensor adaptor set
6	Gently turn infants head over and repeat process.
7	Discard the paper sensor positioning strip – it is a single patient use item
8	The reference electrode can be sited subdermally in the midline, adjacent to the anterior fontanelle, or a hydrogel (stick-on) can be placed on a site with no hair, or near the shoulder Clean the area with water and gauze Site electrode with lead directing towards the top of the head
9	Plug into the data acquisition unit (DAU)

Figure 1 Determination of localizations to place electrodes

**Table 1** aEEG interpretation (background, presence of seizures, sleep-wake cycle).

Background	Seizure activity	Sleep-wake cycle
CNV	No	Advanced
DNV	Single	Immature
Burst-suppression	Recurrent	No
Low voltage	Status epilepticus	
Flat tracing	-	-

CNV: Continuous normal voltage; DNV: Discontinuous normal voltage

presence of seizure activity. Hence, aEEG traces observed in full-term neonates can be evaluated under six main groups<sup>[21]</sup>:

1. **SWCs:** Normal voltage seen in healthy babies is characterized by wide awake and narrow sleep bands. The normal SWC seems to curl up and down like a snake with narrowing and expanding traces. The lower limit of the aEEG pattern should be  $> 5 \mu\text{V}$  and the upper limit should be  $> 10 \mu\text{V}$ . Narrow band occurs during rapid eye movement (REM) period and wide band during non-REM period (**Figure 2B**)<sup>[22]</sup>. The absence of SWCs may also suggest presence of immature brain. The presence and quality of SWCs reflect the severity of the hypoxic-ischemic insult. But, there may be significant changes in the SWCs regardless of the severity of encephalopathy in newborns underwent perinatal asphyxia. In addition, the time of onset of SWC has a predictive value for neurodevelopmental outcome<sup>[23]</sup>. However, further studies are needed in this respect.

2. **Wave-pattern:** It is seen before the completely normal trace appears in infants who recovering from hypoxic-ischemic injury. Voltage is normal, but lower ( $< 5 \mu\text{V}$ ) and upper ( $> 10 \mu\text{V}$ ) voltage fluctuations are seen.

3. **Absence of sleep-wake pattern:** It occurs after mild injuries and often following a normal sleep-wake cycle pattern. There are abnormal voltage band traces of fixed width.

4. **Burst-suppression:** It is seen in moderate or severe injuries. The longer it takes, worse the prognosis. Short-duration high-voltage bursts occur on a low-voltage trace that produce wide bands where the upper limit can be  $< 5 \mu\text{V}$  and the upper limit can exceed  $10 \mu\text{V}$  (**Figure 3**)<sup>[24]</sup>.

5. **Isoelectric line:** It is seen after severe hypoxic ischemic injury and predicts the poor prognosis. There are low-voltage traces which showing no fluctuation on an inactive background  $< 5 \mu\text{V}$  (**Figure 4**)<sup>[25]</sup>.

6. **Seizure:** The seizures must be continued for at least ten minutes in order to be visible in the aEEG. Seizures can also be subclinical (subtle). It is difficult to distinguish short-term seizures from artefacts in aEEG traces. During the seizure, upper limit may be as high as  $50 \mu\text{V}$ , so increased voltage changes are observed on the above-mentioned traces. If repeated frequently, a “saw-tooth” appearance will occur (**Figure 5**)<sup>[26]</sup>.

**aEEG in clinical practice**

Currently, aEEG is often used in the NICU settings to detect seizures and predict the prognosis in full-term neonates with HIE. However, it is increasingly used for the determination of neurodevelopmental effects of persistent pulmonary hypertension and congenital heart diseases<sup>[27]</sup>.

**aEEG in patients with HIE**

During the neonatal period, aEEG has been generally studied in full-term neonates who developed HIE secondary to perinatal asphyxia. It is known that aEEG patterns are the early predictor of brain damage in these patients. Low voltage and flat isoelectric activity are associated with poor prognosis<sup>[28]</sup>. Many studies reported that aEEG traces within the first 6-12 hours period of hypoxic-ischemic insult are very valuable<sup>[29,30]</sup>. In the total body hypothermia (TOBY) study, aEEG was used as an adjunct to determine patients who should undergo to therapeutic hypothermia. After the use of aEEG in these trials, many centers have added aEEG to their clinical protocols for evaluating the severity of encephalopathy and deciding on brain cooling therapy.

Marics et al<sup>[31]</sup> retrospectively assessed the causes and prevalence of false-positive interpretation of aEEG in newborns with moderate to severe HIE. The muscle artefacts can especially lead to an incorrect

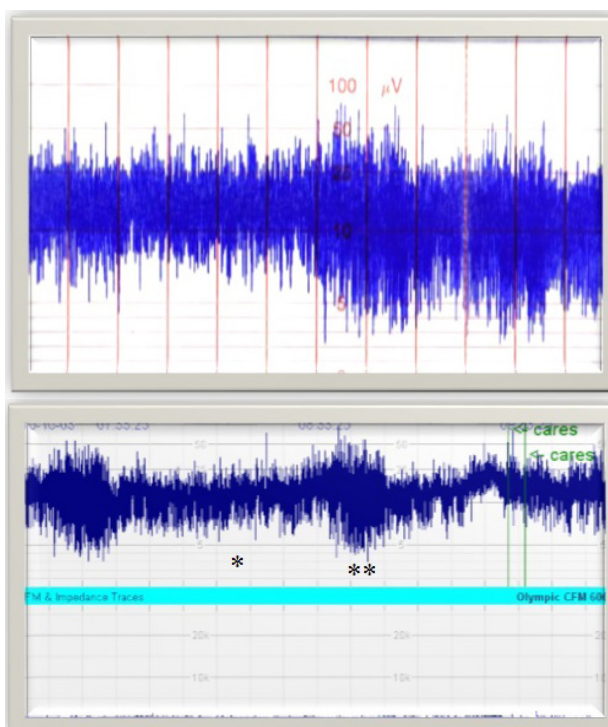
**Table 2** Classification of background activity in aEEG (lower and upper limit values of activity bands).

Background	Lower limit	Upper limit	Interpretation
CNV	$> 5 \mu\text{V}$	$> 10\text{-}25 \mu\text{V}$	Normal
DNV	$< 5 \mu\text{V}$	$> 10 \mu\text{V}$	Low amplitude can be variable
Burst-suppression	$< 5 \mu\text{V}$	-	Amplitude can rise to $25 \mu\text{V}$ with burst
Low voltage	$< 5 \mu\text{V}$	$< 5 \mu\text{V}$	There may be some variables
Flat tracing	$< 5 \mu\text{V}$	$< 5 \mu\text{V}$	Isoelectric line

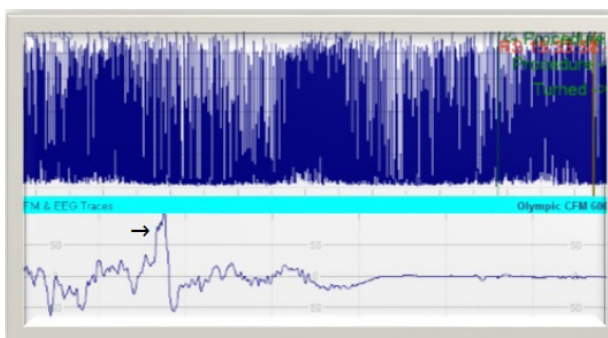
CNV: Continuous normal voltage; DNV: Discontinuous normal voltage

**Table 3** Comments on background activity of the aEEG.

Pattern 1	Minimum amplitude 5-10 $\mu\text{V}$ and maximum amplitude 10-50 $\mu\text{V}$ in the continuous background
Pattern 2	Minimum amplitude $< 5 \mu\text{V}$ and maximum amplitude $> 10 \mu\text{V}$ in the discontinuous background
Pattern 3	Minimum amplitude 0-2 $\mu\text{V}$ and burst amplitude $> 25 \mu\text{V}$ in the discontinuous background
Pattern 4	Very low voltage $< 5 \mu\text{V}$ in the continuous background
Pattern 5	Inactive, flat background activity of $< 5 \mu\text{V}$



**Figure 2** Background aEEG patterns: **A**, normal pattern in a full-term neonate (lower limit  $> 5 \mu\text{V}$  and upper limit  $> 10\text{-}25 \mu\text{V}$ ); **B**, normal aEEG voltage in which the sleep-wake patterns are observed (\* REM period and \*\* non-REM period)



**Figure 3** Burst suppression pattern (arrow showing a burst in raw EEG).

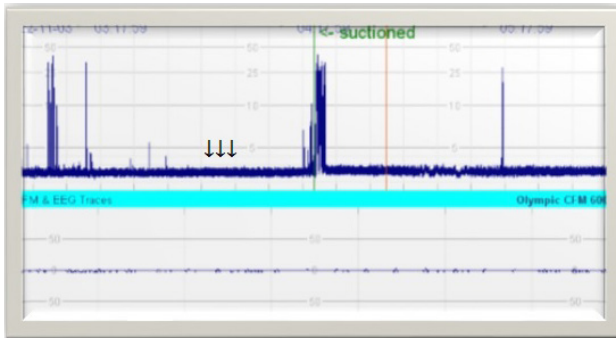


Figure 4 Isoelectric line and artifacts (arrows).

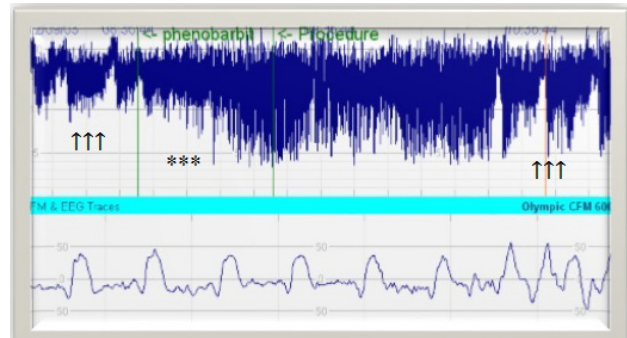


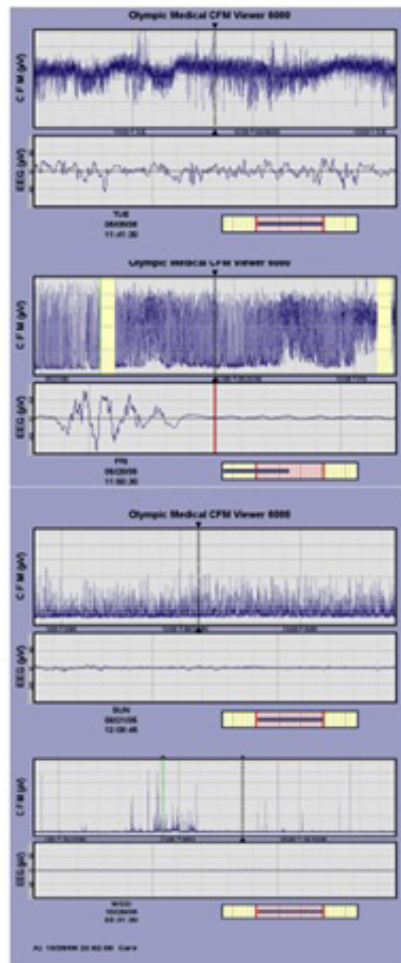
Figure 5 "Saw-tooth" appearance due to frequent seizures (arrows) and moderately abnormal aEEG trace after phenobarbital (asterisks).

Classification based on voltage

Normal amplitude

Moderately abnormal amplitude

Severely abnormal amplitude



Classification by pattern of aEEG

Continuous normal voltage

Discontinuous normal voltage / burst suppression

Continuous low voltage

Flat trace

Figure 6 Interpretation of the aEEG traces by wave amplitude and pattern.

evaluation of aEEG traces. Because the seizures are common in the first 1-2 days of life in newborns with HIE, aEEG or video EEG is recommended in these patients<sup>[32,33]</sup>. The aEEG is interpreted by measuring the waves' amplitude and monitoring the pattern (Table 3, Figure 6)<sup>[22]</sup>.

**Effects of hypothermia on aEEG traces**

There is a direct correlation between the degree of hypothermia and the suppression in the aEEG amplitude. Periodic complexes at 30 °C, suppression at 25 °C, "burst" activity and an isoelectric line at 17 °C emerge in the aEEG. However, hypothermia in which the internal temperature of the body is cooled to 33-34 °C in the case of HIE does not affect the aEEG traces. The initiation of hypothermia

to babies with HIE who have moderate to severe abnormal aEEG patterns within the first 6 hours after birth positively affects the neurological outcomes. In a study which compared cooled infants with non-cooled infants the positive predictive value of aEEG was low (64-75%) within 6 hours after birth; but it reached to 80% in both groups within 24-36 hours after birth<sup>[34]</sup>. In another study, it was reported that possibility of severe neurological damage was high (>80%) in patients having severe suppression in aEEG in the first 48 hours of life<sup>[35]</sup>. It is still unclear that whether the recovery time of pathological findings in aEEG is changed by cooling therapy.

**aEEG for detection of neonatal seizures**

Seizures in the newborns are often difficult to detect because they

are generally subclinical<sup>[36]</sup>. This may be detrimental to the immature brain and may negatively affect the long-term neurodevelopmental outcomes. Neonatal seizures are rarely idiopathic; they are commonly a manifestation of serious central nervous system diseases. Main causes of seizure in neonates are HIE (30-50%), intracranial hemorrhages (10-17%), hypocalcemia (6-15%), hypoglycemia (6-10%), central nervous system infections (5-14%), infarcts (7%), inborn error metabolism(3%) and idiopathic (10%)<sup>[37]</sup>.

The electrographic features of the neonatal seizures are quite diverse. Interhemispheric bilateral synchronized seizures are rare. Electrical seizures in the newborn infants are usually originated from central or temporal foci. In general, the seizure pattern of repetitive sharp spikes and slow waves that originated from one focus and travel from one side of the cortex to another is frequently encountered. Therefore, aEEG has been a major curiosity in the detection of seizures, the selection of anticonvulsant treatment and the evaluation of effectiveness of treatment. The limited number of electrodes applied during aEEG monitoring may fail to detect the spatially distributed seizure activities. This reduces the sensitivity of aEEG in neonatal seizures<sup>[38]</sup>. However, it may be difficult to detect the seizure in a time-compressed aEEG screening if the neonatal seizure duration is short (60% of seizures last around 90 seconds)<sup>[23]</sup>.

Nonetheless, specificity is more reliable; very few false positive results have been reported in systematic studies<sup>[39]</sup>. Shellhaas et al<sup>[39]</sup> evaluated the effects of aEEG on neonatal seizure and reported that aEEG had no effect on the use of antiepileptic drugs and ordering of neuroimaging studies but reduced unnecessary treatments initiated accidentally by considering clinical seizure. Epileptic seizures are more frequent in neonatal period compared to older children. They usually occur in case of encephalopathy and have a very wide etiology. In a study, Mastrangelo et al. <sup>[40]</sup> compared the cEEG and aEEG in terms of electrographic seizure detection in neonates with acute neonatal encephalopathy and reported that aEEG could be easily recognized prolonged electrophysiologic seizures, but missed half of short single seizures. Reliability of the aEEG in terms of detecting seizures has been questioned by many authors. Because aEEG is sensitive to amplitude changes, but insensitive to frequency changes, discharges which do not make a significant increase in amplitude maybe missed<sup>[41]</sup>. A wide range of sensitivities (26% to 76%) have been reported in studies conducted to determine neonatal seizures<sup>[42,43]</sup>. The visible information in amplitude changes during aEEG monitoring is limited. Modern aEEG devices offer the ability to display raw EEG, so the frequency and morphology of the raw EEG curve can also be interpreted, and also, it helps to differentiate artifacts from true seizure activities in the EEG band<sup>[6,23,36]</sup>. Some aEEG devices records the patient's video simultaneously for better interpretation of seizure and artifacts. It can detect unrecognized seizures due to long recording time. Therefore, the aEEG is not intended to replace cEEG, but to complete it<sup>[6,22]</sup>. Eventually, use of EEG and aEEG together is recommended in cases of hypoxia and/or intractable seizures<sup>[44]</sup>.

#### Use of aEEG in preterm infants

The use of aEEG in preterm infants has become an active research area. aEEG background activity in preterm infants was found to be more irregular compared to full-term newborns. There are more frequent bursts and low voltage times on the aEEG signal<sup>[45,46]</sup>. aEEG is quite irregular during the 24-25<sup>th</sup> gestational week, and the irregular amplitude and width gradually decrease as the maturity increases<sup>[47,48]</sup>. Full-band aEEG analysis identifies specific unusual findings in preterm infants. Some findings such as the “delta brush”

and “saw-tooth” occur at specific gestational ages. Sleep-wake state in aEEG differs from 30<sup>th</sup> gestational week and evolves exactly at the 37<sup>th</sup> gestational week<sup>[49]</sup>.

#### Effects of drugs on aEEG traces

Several drugs affect the background of aEEG amplitude. Sedatives like chloral hydrate, opiates and anticonvulsant drugs like phenobarbital and benzodiazepines temporarily suppress the EEG. Fentanyl and high dose midazolam treatments can cause deep depression in aEEG. Therefore, aEEG assessment made within 30-60 minutes after drug exposure may result in misinterpretation of the encephalopathy degree<sup>[50-52]</sup>.

#### aEEG in prediction of prognosis

The diagnostic value of cEEG on brain damage has been proven by conducted studies. aEEG has a high diagnostic value in neonates developed encephalopathy within the few hours after birth. It has been reported that aEEG is a good tool as other clinical, radiological and neurophysiological evaluations in terms of predicting neurodevelopmental outcomes in newborns with HIE<sup>[53]</sup>.

**Features showing good prognosis:** (1) Presence of normal background activity pattern; (2) Even if the aEEG trace initially is abnormal, return to normal within 48 hours during cooling and within 24 hours during normothermia; (3) The presence of SWCs or the beginning of SWCs within the first 36 hours after birth.

**Features showing poor prognosis:** (1) Abnormal background pattern; (2) Interrupted pattern and low voltage; (3) An amplitude of <5µV within the first postnatal 3 days; (4) Absence of SWC; (5) Status epilepticus; (6) Prolonged and marked moderate to severe voltage disturbances.

However, further studies exploring the predictive value of aEEG and/or video EEG monitoring on short- and long-term outcomes in high-risk neonates are needed.

#### CFM using near infrared spectroscopy (NIRS)

aEEG and NIRS may be useful in examining cerebral electrical activity and cerebral hemodynamic changes during therapeutic hypothermia<sup>[54,55]</sup>. NIRS is a technique which developed on the basis of relative transparency of light on the biological tissues. Thin-layer of the skin, skull and cerebral tissue of neonates allow the NIRS light of 700-1000 nanometer wavelengths to penetrate easily. Reflections of the NIRS light through the cerebral tissue are sent to the detector which presents about 2-3 cm depth<sup>[56]</sup>. NIRS are based upon the principle of absorbing the light by oxygenated and deoxygenated hemoglobin at different wavelengths and use to continuously monitor of cerebral hemodynamics in clinical practice for measuring changes in different concentrations<sup>[37]</sup>. Previous studies have reported that changes in cerebral oxygenation in the patients with HIE are associated with the severity of brain injury<sup>[57]</sup>. Delayed perfusion at the beginning of the secondary energy failure in hypoxic cases causes low cerebral oxygenation and cerebral vasodilatation. This suggests that the increase in brain oxygenation measured by NIRS is associated with poor prognosis<sup>[58,59]</sup>.

Ancora et al. <sup>[57]</sup> evaluated the neurodevelopmental outcome of cooled neonates with HIE by aEEG and NIRS and reported that aEEG lost its positive predictive value within the first 24 hours of life. But, the tissue oxygenation index assessed by NIRS has been reported to be useful for early prediction of infants who benefit from therapeutic approach<sup>[60]</sup>. NIRS has the potential to guide clinical management by monitoring brain oxygenation and perfusion for preventing brain damage, and avoiding unnecessary treatment. It can also provide important information about the prognosis of these babies.

In conclusion, aEEG is widely used in many developed countries around the world because it is easily accessible and helps patient management. As it has relatively low and variable sensitivity and specificity than a cEEG, it cannot replace that technique. Rather, it completes the existing means for cerebral diagnostics such as cEEG, ultrasound, and magnetic resonance imaging. There is good evidence for the prediction of outcome after birth asphyxia in full-term infants, and the aEEG has been established as a tool to identify infants who will benefit from cooling<sup>[22,61,62]</sup>. In preterm infants, there is also good evidence that long-term neurological prognosis can be predicted by early aEEG recordings. However, to date, this knowledge does not result in consequences for clinical decision making in this infant population. It is likely that aEEG will become a standard tool in NICUs in the future.

## REFERENCES

1. Maynard D, Prior PF, Scott DF. A continuous monitoring device for cerebral activity. *Electroencephalogr Clin Neurophysiol* 1969; **27**: 672-73. [PMID: 4187315]
2. Prior PF, Maynard DE, Sheaff PC, Simpson BR, Strunin L, Weaver EJ, Scott DF. Monitoring cerebral function: clinical experience with new device for continuous recording of electrical activity of brain. *Br Med J* 1971; **2**: 736-8. [PMID: 4326286]
3. Silvay G, Mindich BP, Owitz S, Koffski RM, Litwak RS. Evaluation of a new cerebral function monitor during open-heart surgery. *Mt Sinai J Med* 1983; **50**: 44-8. [PMID: 6601759]
4. Hellström-Westas L, Rosén I, Svenningsen NW. Cerebral function monitoring during the first week of life in extremely small low birthweight (ESLBW) infants. *Neuropediatrics* 1991; **22**: 27-32. [DOI: 2038424 [DOI: 10.1055/s-2008-1071411]; [PMID: 2038424]
5. Shany E, Shorer Z, Karplus M. Cerebral function monitoring after severe perinatal asphyxia. *Harefuah* 1998; **135**: 440-5.
6. Toet MC, Hellstrom-Westas L, Groenendaal F, Eken P, de Vries LS. Amplitude integrated EEG 3 and 6 hours after birth in full term neonates with hypoxic ischemic encephalopathy. *Arch Dis Child Fetal Neonatal Ed* 1999; **81**: F19-23. [PMID: 10375357]
7. Hellstrom-Westas L, Rosen I, SwenningsenNW. Silent seizures in sick infants in early life, diagnosis by continuous cerebral function monitoring. *Acta Paediatr Scand* 1985; **74**: 741-8. [PMID: 4050421]
8. Altfullah I, Asaikar S, Torres F. Status epilepticus: clinical experience with two special devices for continuous cerebral monitoring. *ActaNeurolScand* 1991; **84**: 374-81. [DOI: 10.1111/j.1600-0404.1991.tb04973.x]; [PMID: 1776384]
9. Reynolds P. Neonatal encephalopathy guideline. Available at: [http://www.asph.mobi/Guidelines\\_Neonatal/Neonatal%20Encephalopathy%20Guideline%20Mar%202015.pdf](http://www.asph.mobi/Guidelines_Neonatal/Neonatal%20Encephalopathy%20Guideline%20Mar%202015.pdf) (accessed at May 2018).
10. Vries L, Hellström-Westas L. Role of cerebral function monitoring in the newborn. *Arch Dis Child Fetal Neonatal Ed* 2005; **90**: F201-7. [DOI: 10.1136/adc.2004.062745]; [PMID: 15846008]
11. Lommen CM, Pasman JW, van Kranen VH, Andriessen P, Cluittmans PJ, van Rooij LG, BambangOetomo S. An algorithm for the automatic detection of seizures in neonatal amplitude-integrated EEG. *Acta Paediatr* 2007; **96**: 674-80. [DOI: 10.1111/j.1651-2227.2007.00223.x]; [PMID: 17381475]
12. Del Río R, Ochoa C, Alarcon A, Armáez J, Blanco D, García-Alix A. Amplitude integrated electroencephalogram as a prognostic tool in neonates with hypoxic-ischemic encephalopathy: a systematic review. *PLoS One* 2016; **11**: e0165744. [DOI: 10.1371/journal.pone.0165744]; [PMID: 27802300]
13. Maynard D, Prior PF, Scott DF. Device for continuous monitoring of cerebral activity in resuscitated patients. *Br Med J* 1969; **4**: 545-6. [PMID: 5354856]
14. Hellström-Westas L, Rosén I, Svenningsen NW. Predictive value of early continuous amplitude integrated EEG recordings on outcome after severe birth asphyxia in full term infants. *Arch Dis Child Fetal Neonatal Ed* 1995; **72**: F34-38. [DOI: 10.1136/fn.72.1.F34]; [PMID: 7743282]
15. Wikström S, Pupp IH, Rosén I, Norman E, Fellman V, Ley D, Hellström-Westas L. Early single-channel aEEG/EEG predicts outcome in very preterm infants. *Acta Paediatr* 2012; **101**: 719-26. [DOI: 10.1111/j.1651-2227.2012.02677.x]; [PMID: 22530996]
16. Shah NA, Van Meurs KP, Davis AS. Amplitude-integrated electroencephalography: a survey of practices in the United States. *Am J Perinatol* 2015; **32**: 755-60. [DOI: 10.1055/s-0034-1395483]; [PMID: 25519200]
17. Rakshashbhuvankar A, Paul S, Nagarajan L, Ghosh S, Rao S. Amplitude-integrated EEG for detection of neonatal seizures: a systematic review. *Seizure* 2015; **33**: 90-8. [DOI: 10.1016/j.seizure.2015.09.014]; [PMID: 26456517]
18. Shah NA, Wusthoff CJ. How to use: amplitude-integrated EEG (aEEG). *Arch Dis Child Educ Pract Ed* 2015; **100**: 75-81. [DOI: 10.1136/archdischild-2013-305676]; [PMID: 25035312]
19. Abend NS, Wusthoff CJ. Neonatal seizures and status epilepticus. *J Clin Neurophysiol* 2012; **29**: 441-8. [DOI: 10.1097/WNP.0b013e31826bd90d]; [PMID: 23027101]
20. Janáčková S, Boyd S, Yozawitz E, Tsuchida T, Lamblin MD, Gueden S, Pressler R. Electroencephalographic characteristics of epileptic seizures in preterm neonates. *Clin Neurophysiol* 2016; **127**: 2721-7. [DOI: 10.1016/S1474-4422(13)70246-1]; [PMID: 24229615]
21. Li XF, Zhou YX, Zhang L. Newborns' sleep-wake cycle development on amplitude integrated electroencephalography. *World J Pediatr* 2016; **12**: 327-34. [DOI: 10.1007/s12519-060026-x]; [PMID: 27351568]
22. Bruns N, Blumenthal S, Meyer I, Klose-Verschuur S, Felderhoff-Müser U, Müller H. Application of an Amplitude-integrated EEG monitor (cerebral function monitor) to neonates. *J Vis Exp* 2017; Sep 6; (127). [DOI: 10.3791/55985]; [PMID: 28930990]
23. Osredkar D, Toet MC, van Rooij LG, van Huffelen AC, Groenendaal F, de Vries LS. Sleep-wake cycling on amplitude-integrated electroencephalography in term newborns with hypoxic-ischemic encephalopathy. *Pediatrics* 2005; **115**: 327-32. [DOI: 10.1542/peds.2004-0863]; [PMID: 15687440]
24. Hellström-Westas L, Rosén I, de Vries LS, Greisen G. Amplitude-integrated EEG classification and interpretation in preterm and term infants. *Neo Reviews* 2006; **7**: e76-e87. [DOI: 10.1542/neo.7-2-e76]
25. Toet MC, Lemmers PM. Brain monitoring in neonates. *Early Hum Dev* 2009; **85**: 77-84. [DOI: 10.1016/j.earlhumdev.2008.11.007]; [PMID: 19150756]
26. Glass HC. Neonatal brain monitoring. Available at: [http://www.cneo.net/Neonatal2017talks/Glass\\_BrainMonitoring.pdf](http://www.cneo.net/Neonatal2017talks/Glass_BrainMonitoring.pdf) (accessed at May 2018).
27. El-Naggar WI, Keyzers M, McNamara PJ. Role of amplitude-integrated electroencephalography in neonates with cardiovascular compromise. *J Crit Care* 2010; **25**: 317-21. [DOI: 10.1016/j.jcrc.2008.11.008]; [PMID: 19327328]
28. Chandrasekaran M, Chaban B, Montaldo P, Thayyil S. Predictive value of amplitude-integrated EEG (aEEG) after rescue hypothermic neuroprotection for hypoxic ischemic encephalopathy: a meta-analysis. *J Perinatol* 2017; **37**: 684-9. [DOI: 10.1038/jp.2017.14]; [PMID: 28252661]
29. van Rooij LG, Toet MC, Osredkar D, van Huffelen AC, Groenendaal F, de Vries LS. Recovery of amplitude integrated electroencephalographic background patterns within 24 hours of perinatal asphyxia. *Arch Dis Child Fetal Neonatal Ed* 2005; **90**: F245-251. [DOI: 10.1136/adc.2004.064964]; [PMID: 15846017]
30. Azzopardi DV, Strohm B, Edwards AD, Dyet L, Halliday

- HL, Juszcak E, Kapellou O, Levene M, Marlow N, Porter E, Thoresen M, Whitelaw A, Brocklehurst P; TOBY Study Group. Moderate hypothermia to treat perinatal asphyxial encephalopathy. *N Engl J Med* 2009; **361**: 1349-58. [DOI: 10.1056/NEJMoa0900854]; [PMID: 19797281]
31. Marics G, Csekő A, Vásárhelyi B, Zakariás D, Schuster G, Szabó M. Prevalence and etiology of false normal aEEG recordings in neonatal hypoxic-ischaemic encephalopathy. *BMC Pediatr* 2013; **13**: 194. [DOI: 10.1186/1471-2431-13-194]; [PMID: 24268061]
  32. Wusthoff CJ, Dlugos DJ, Gutierrez-Colina A, Wang A, Cook N, Donnelly M, Clancy R, Abend NS. Electrographic seizures during therapeutic hypothermia for neonatal hypoxic-ischemic encephalopathy. *J Child Neurol* 2011; **26**: 724-8. [DOI: 10.1177/0883073810390036]; [PMID: 21447810]
  33. Lynch NE, Stevenson NJ, Livingstone V, Murphy BP, Rennie JM, Boylan GB. The temporal evolution of electrographic seizure burden in neonatal hypoxic ischemic encephalopathy. *Epilepsia* 2012; **53**: 549-57. [DOI: 10.1016/j.seizure.2015.10.007]; [PMID: 26571073]
  34. Toso PA, González AJ, Pérez ME, Kattan J, Fabres JG, Tapia JL, González HS. Clinical utility of early amplitude integrated EEG in monitoring term newborns at risk of neurological injury. *J Pediatr (Rio J)* 2014; **90**: 143-8. [DOI: 10.1016/j.jpeds.2013.07.004]; [PMID: 24184304]
  35. Hallberg B, Grossmann K, Bartocci M, Blennow M. The prognostic value of early aEEG in asphyxiated infants undergoing systemic hypothermia treatment. *Acta Paediatr* 2010; **99**: 531-6. [DOI: 10.1111/j.1651-2227.2009.01653.x]; [PMID: 20050830]
  36. Murray DM, Boylan GB, Ali I, Ryan CA, Murphy BP, Connolly S. Defining the gap between electrographic seizure burden, clinical expression and staff recognition of neonatal seizures. *Arch Dis Child Fetal Neonatal Ed* 2008; **93**: F187-191. [DOI: 10.1136/adc.2005.086314]; [PMID: 17626147]
  37. Glass HC, Shellhaas RA, Wusthoff CJ, Chang T, Abend NS, Chu CJ, Cilio MR, Glidden DV, Bonifacio SL, Massey S, Tsuchida TN, Silverstein FS, Soul JS; Neonatal Seizure Registry Study Group. Contemporary profile of seizures in neonates: a prospective cohort study. *J Pediatr* 2016; **174**: 98-103. [DOI: 10.1016/j.jpeds.2016.03.035]; [PMID: 27106855]
  38. Shah DK, Mackay MT, Lavery S, Watson S, Harvey AS, Zempel J, Mathur A, Inder TE. Accuracy of bedside electroencephalographic monitoring in comparison with simultaneous continuous conventional electroencephalography for seizure detection in term infants. *Pediatrics* 2008; **121**: 1146-54. [DOI: 10.1542/peds.2007-1839]; [PMID: 18519484]
  39. Shellhaas RA, Barks AK. Impact of amplitude-integrated electroencephalograms on clinical care for neonates with seizures. *Pediatr Neurol* 2012; **46**: 32-5. [DOI: 10.1016/j.pediatrneurol.2011.11.004]; [PMID: 22196488]
  40. Mastrangelo M, Fiocchi I, Fontana P, Gorgone G, Lista G, Belcastro V. Acute neonatal encephalopathy and seizures recurrence: a combined aEEG/EEG study. *Seizure* 2013; **22**: 703-7. [DOI: 10.1016/j.seizure.2013.05.006]; [PMID: 23725740]
  41. Shellhaas RA, Soaita AI, Clancy RR. Sensitivity of amplitude-integrated electroencephalography for neonatal seizure detection. *Pediatrics* 2007; **120**: 770-7. [DOI: 10.1542/peds.2007-0514]; [PMID: 17908764]
  42. Murray DM, O'Connor CM, Ryan CA, Korotchikova I, Boylan GB. Early EEG grade and outcome at 5 years after mild neonatal hypoxic ischemic encephalopathy. *Pediatrics* 2016; **138**: pii: e20160659. [DOI: 10.1542/peds.2016-0659]; [PMID: 27650049]
  43. Bourez-Swart MD, van Rooij L, Rizzo C, de Vries LS, Toet MC, Gebbink TA, Ezendam AGJ, van Huffelen AC. Detection of subclinical electroencephalographic seizure patterns with multichannel amplitude-integrated EEG in full-term neonates. *Clin Neurophysiol* 2009; **120**: 1916-22. [DOI: 10.1016/j.clinph.2009.08.015]; [PMID: 19782640]
  44. Rakshashbhavankar A, Rao S, Palumbo L, Ghosh S, Nagarajan L. Amplitude-integrated EEG for detection of neonatal seizures: a systematic review. *J Child Neurol* 2017; **32**: 815-22. [DOI: 10.1177/0883073817707411]; [PMID: 28482764]
  45. Vecchierini MF, d'Allest AM, Verpillat P. EEG patterns in 10 extreme premature neonates with normal neurological outcome: qualitative and quantitative data. *Brain Dev* 2003; **25**: 330-7; [PMID: 12850512]
  46. Burdjalov VF, Baumgart S, Spitzer AR. Cerebral function monitoring: a new scoring system for the evaluation of brain maturation in neonates. *Pediatrics* 2003; **112**: 855-61. [PMID: 14523177]
  47. Vecchierini MF, André M, d'Allest AM. Normal EEG of premature infants born between 24 and 30 weeks gestational age: terminology, definitions and maturation aspects. *Neurophysiol Clin* 2007; **37**: 311-23. [DOI: 10.1016/j.neucli.2007.10.008]; [PMID: 18063233]
  48. Olischar M, Klebermass K, Kuhle S, Hulek M, Kohlhauser C, Rücklinger E, Pollak A, Weninger M. Reference values for amplitude-integrated electroencephalographic activity in preterm infants younger than 30 weeks' gestational age. *Pediatrics* 2004; **113**: e61-6. [PMID: 14702497]
  49. Meledin I, Abu Tailakh M, Gilat S, Yogev H, Golan A, Novack V, Shany E. Comparison of Amplitude-Integrated EEG and Conventional EEG in a Cohort of Premature Infants. *Clin EEG Neurosci* 2017; **48**: 146-54. [DOI: 10.1177/1550059416648044]; [PMID: 27230038]
  50. van Leuven K, Groenendaal F, Toet MC, Schobben AF, Bos SA, de Vries LS, Rademaker CM. Midazolam and amplitude-integrated EEG in asphyxiated full-term neonates. *Acta Paediatr* 2004; **93**: 1221-7; [PMID: 15384888]
  51. Shany E. The influence of phenobarbital overdose on aEEG recording. *Eur J Paediatr Neurol* 2004; **8**: 323-5. [DOI: 10.1016/j.pediatrneurol.2008.08.005]; [PMID: 19027583]
  52. Niemarkt HJ, Halbertsma FJ, Andriessen P, Bambang Oetomo S. Amplitude-integrated electroencephalographic changes in a newborn induced by overdose of morphine and corrected with naloxone. *Acta Paediatr* 2008; **97**: 132-4. [DOI: 10.1111/j.1651-2227.2007.00583.x]; [PMID: 18201313]
  53. Del Río R, Ochoa C, Alarcon A, Arnáez J, Blanco D, García-Alix A. Amplitude integrated electroencephalogram as a prognostic tool in neonates with hypoxic-ischemic encephalopathy: A Systematic Review. *PLoS One* 2016; **11**: e0165744. [DOI: 10.1371/journal.pone.0165744]; [PMID: 27802300]
  54. Lemmers PM, Zwanenburg RJ, Benders MJ, de Vries LS, Groenendaal F, van Bel F, Toet MC. Cerebral oxygenation and brain activity after perinatal asphyxia: does hypothermia change their prognostic value? *Pediatr Res* 2013; **74**: 180-5. [DOI: 10.1038/pr.2013.84]; [PMID: 23728382]
  55. Niezen CK, Bos AF, Sival DA, Meiners LC, Ter Horst HJ. Amplitude-integrated eeg and cerebral near-infrared spectroscopy in cooled, asphyxiated infants. *Am J Perinatol* 2018; **35**: 904-10. [DOI: 10.1055/s-0038-1626712. PMID: 29421831]
  56. Brown DW, Picot PA, Naeini JG, Springett R, Delpy DT, Lee TY. Quantitative near infrared spectroscopy measurement of cerebral hemodynamics in newborn piglets. *Pediatr Res* 2002; **51**: 564-70. [DOI: 10.1203/00006450-200205000-00004]; [PMID: 11978878]
  57. Ancora G, Maranella E, Grandi S, Sbravati F, Coccolini E, Savini S, Faldella G. Early predictors of short term neurodevelopmental outcome in asphyxiated cooled infants. A combined brain amplitude integrated electroencephalography and near infrared spectroscopy study. *Brain Dev* 2013; **35**: 26-31. [DOI: 10.1016/j.braindev.2011.09.008]; [PMID: 22082686]
  58. Ferriero DM. Neonatal brain injury. *N Engl J Med* 2004; **351**: 1985-95. [DOI: 10.1056/NEJMra041996]; [PMID: 15525724]
  59. Watzman HM, Kurth CD, Montenegro LM, Rome J, Steven JM, Nicolson SC. Arterial and venous contributions to near-infrared

- cerebral oximetry. *Anesthesiology* 2000; **93**: 947-53]; [PMID: 11020744]
60. Dix LM, van Bel F, Lemmers PM. Monitoring cerebral oxygenation in neonates: an update. *Front Pediatr* 2017; **5**: 46. [DOI: 10.3389/fped.2017.00046]; [PMID: 28352624]
61. Bruns N, Dransfeld F, Hüning B, Hobrecht J, Storbeck T, Weiss C, Felderhoff-Müser U, Müller H. Comparison of two common aEEG classifications for the prediction of neurodevelopmental outcome in preterm infants. *Eur J Pediatr* 2017; **176**: 163-71. [DOI: 10.1007/s00431-016-2816-5. PMID: 27924356]
62. Marics G, Csekő A, Vásárhelyi B, Zakariás D, Schuster G, Szabó M. Prevalence and etiology of false normal aEEG recordings in neonatal hypoxic-ischaemic encephalopathy. *BMC Pediatr* 2013; **13**: 194. [DOI: 10.1186/1471-2431-13-194]; [PMID: 24268061]