

## Painful Small Fiber Neuropathy in Sarcoidosis: A Report of Two Patients

David S Younger, Kenneth B Hymes, Kurenai Tanji, Cynthia Liu, Jennifer Zeng, Roy A Raad, Kyra F Doumlele, Seth Younger

David S Younger, Kyra F Doumlele, Department of Neurology, New York University Langone Medical Center, New York University School of Medicine, and the Global Institute of Public Health, New York University, New York, the United States

Kenneth B Hymes, Department of Medicine, Division of Hematology, New York University School of Medicine, New York, the United States

Kurenai Tanji, Department of Pathology and Cell Biology, Neuro-muscular Laboratory2, College of Physicians and Surgeons, Columbia University, New York, the United States

Cynthia Liu, Department of Pathology/Hematopathology, New York University School of Medicine, and the Global Institute of Public Health, New York University, New York, the United States

Jennifer Zeng, Department of Pathology, New York University School of Medicine, and the Global Institute of Public Health, New York University, New York, the United States

Roy A Raad, Department of Radiology, New York University School of Medicine, and the Global Institute of Public Health, New York University, New York, the United States

Seth Younger, Horace Mann School, Bronx, New York, the United States

Correspondence to: David S Younger, MD, MPH, Department of Neurology, New York University Langone Medical Center, New York University School of Medicine, and the Global Institute of Public Health, New York University, New York, the United States  
Email: [david.younger@nyumc.org](mailto:david.younger@nyumc.org)

Telephone: +1-212-213-3778 Fax: +1-212-213-3779

Received: November 30, 2014 Revised: December 26, 2014

Accepted: January 2, 2015

Published online: February 2, 2015

### ABSTRACT

Two patients with histologically-proven sarcoidosis are reported, both with initial presentation of painful small fiber neuropathy. Positron emission tomography fused with computed tomography revealed the first evidence of sarcoidosis in both patients, and provided a useful

guide for bone marrow and bronchoscopic lymph node and lung tissue biopsy.

© 2015 ACT. All rights reserved.

**Key words:** Epidermal nerve fiber; Sarcoidosis; Skin biopsy

Younger DS, Hymes KB, Tanji K, Liu C, Zeng J, Raad RA, Doumlele KF, Younger S. Painful Small Fiber Neuropathy in Sarcoidosis: A Report of Two Patients. *International Journal of Neurology Research* 2015; 1(1): 14-17 Available from: URL: <http://www.ghrnet.org/index.php/ijnr/article/view/930>

### INTRODUCTION

Sarcoidosis is a multiorgan autoimmune granulomatous disorder with worldwide prevalence of less than 1 to 64 per 100,000, and predilection for adults, particularly women less than 40 years of age<sup>[1]</sup>. The lymph nodes, lung, skin, liver and spleen are the commonest sites of granuloma formation and deposition. Stern and colleagues<sup>[2]</sup> found neurological involvement in 33 (5.1%) of 649 patients with pathologically-confirmed sarcoidosis, 16 (49%) of whom presented neurologically including 1 (6%) with biopsy-proven peripheral nerve involvement and another with clinically suspected disease. Sarcoid involvement of small unmyelinated C-, and thinly myelinated A- $\delta$  intraepidermal nerve fibers (IENF) encoding thermal and nociceptive sensation, was noted in up to 40% of patients after detailed neurophysiological and histopathologic studies<sup>[3]</sup>. Such patients were categorized by the World Association of Sarcoidosis and Other Granulomatous Disorders (WASOG) Sarcoidosis Organ Assessment Instrument Investigators as "paraneurosarcoid"<sup>[4]</sup>.

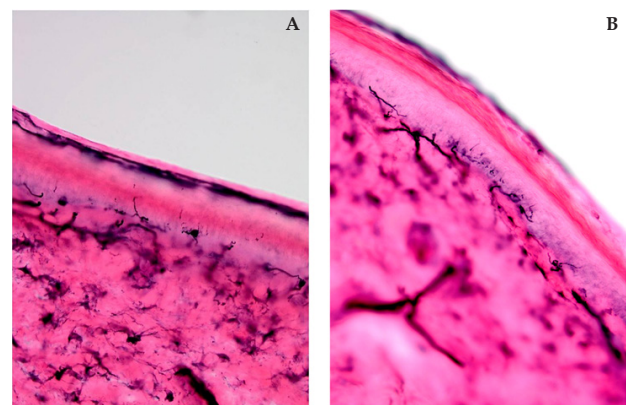
### CASE REPORT

**Patient 1:** A 47-year-old woman noted dysesthesia along the left leg and lateral chest with radiation across the midline under the breasts in May 2013, later associated with concentration difficulty,

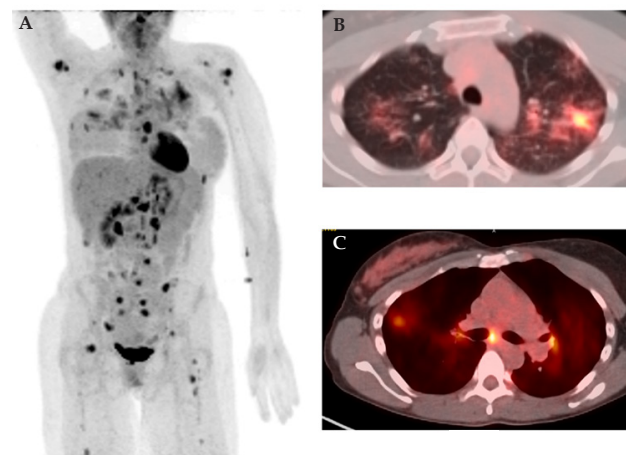
palpitation, lightheadedness, constipation, decreased libido, and extreme fatigue. Past medical history was remarkable for migraine headaches, endometriosis, polycystic ovarian disease (PCOD) and anti-phospholipid antibody (APA) syndrome. There were five miscarriages followed by successful in vitro fertilization while receiving intravenous immune globulin (IVIg) with two term gestations. She took venlafaxine hydrochloride for hot flashes, spironolactone for PCOD, aspirin for APA, gabapentin for pain, zolpidem for sleep, topiramate for headaches, and diazepam for anxiety. Neurological examination in May 2014 showed sensory loss to cold temperature in the hands and feet, with a positive Romberg sign, and normal strength, reflexes, cognition and cranial nerve function. Electromyography (EMG) and nerve conduction studies (NCS) were normal. Autonomic neurophysiological studies (WR Electronics, MN) showed 20 beat per minute acceleration in heart rate from baseline to the erect posture during tilting insufficient for the diagnosis of postural orthostatic tachycardia syndrome; deep breathing, and Valsalva maneuver (VM) were normal. IENF studies (Figure 1) of the left calf and thigh showed thin, short axons with frequent complex branching patterns and focal swellings near the dermoepidermal junction with normal IENF densities. Blood studies showed normal chemistries, complete blood count (CBC), angiotensin converting enzyme (ACE), antinuclear antibody (ANA) titers, erythrocyte sedimentation rate (ESR), C reactive protein (CRP), lymphocyte flow cytometry, B12, hemoglobin (Hg)A1c, and thyroid function tests (TFT). Magnetic resonance imaging (MRI) of the brain and spine were normal. Whole body positron emission tomography (PET) fused with computed tomography (CT) after injection of 18fluorodeoxyglucose (FDG) showed extensive FDG avid adenopathy above and below the diaphragm, lytic and sclerotic bone lesions through the axial and appendicular skeleton, and bilateral ill-defined lung air space opacities (Figure 2). Pulmonary function tests were normal. Posterior iliac crest bone marrow aspiration biopsy (Figure 3) and transbronchial biopsy of the left upper lobe and left lower lobe biopsy (Figure 4) showed multiple non-caseating granulomas composed of epithelioid cells and occasional multi-nucleated giant cells with mild central necrosis. Stains for acid fast bacilli (AFB) and Gömöri methenamine silver stain (GMS) for fungal organisms were negative. Subcarinal transbronchial and lymph node biopsies showed benign bronchial tissue. Cerebrospinal fluid (CSF) showed 0 nucleated cells, 3 red blood cells, protein 27 mg/dL, and glucose 58 mg/dL, with normal or negative IgG, oligoclonal bands, and bacterial, fungal, and acid fast cultures, and deoxynucleic and ribonucleic acid viral titers by real-time polymerase chain reaction. She was treated with 1.6 grams per kilogram of IVIg per month administered over 4 days without significant improvement in neuropathic pain when last seen in November 2014.

**Patient 2:** A previously published 32-year-old woman<sup>[5]</sup> developed pain along the left face and neck later followed by pins and needles sensation of the left hand in 2002. Past medical history was remarkable for hypergonadotropic hypogonadism and premature ovarian failure with elevated titers of anti-ovarian and APA for which she received eight months of intravenous corticosteroids and IVIg in 2005. She took no other medications. Examination in 2006 showed hyperesthesia of the left side of the face with mild distal weakness of the left wrist and foot in extension, and flexion, with a positive Romberg sign, tandem imbalance, and otherwise normal strength, sensation, tendon reflexes, cognition and cranial nerve function. EMG and NCS were normal. Autonomic neurophysiological studies showed increased sweating volume in the proximal left thigh with an absent phase IV blood pressure overshoot on VM. There was

heat-pain hypersensitivity in the left hand and foot on quantitative sensory testing (QST) employing computer assisted sensory testing (CASE IV) (WR Electronics, MN). Blood studies showed normal chemistries, CBC, ACE, ANA, ESR, CRP, lymphocyte flow cytometry, B12, HgA1c, and TFT. Non-contrast brain and spinal cord MRI were normal. Whole body FDG-PET/CT showed extensive mediastinal and bilateral hilar adenopathy without abnormal radiotracer in the lungs (Figure 5). Pulmonary function tests were normal. IENF studies showed significantly low density of the left thigh (7.2/mm, 5th% reference value 8/mm), and low normal density in the left calf (6.2/mm, 5<sup>th</sup> percentile reference value 5/mm) without histological abnormalities. Left sural nerve and soleus muscle biopsy showed no significant pathology. Posterior iliac bone marrow aspiration and biopsy showed mildly hypocellularity without evidence of granulomas or lymphoid aggregates. Right paratracheal lymph node biopsy showed extensive non-caseating granuloma composed of epithelioid cells and occasional multi-nucleated giant cells with mild central necrosis (Figure 6). Immunohistochemical stains performed on formalin-fixed, paraffin-embedded tissue sections for CD3 and CD20 highlighted the presence of scattered T-cells and B-cells at the peripheral of the granulomas. Immunotyping analysis by flow

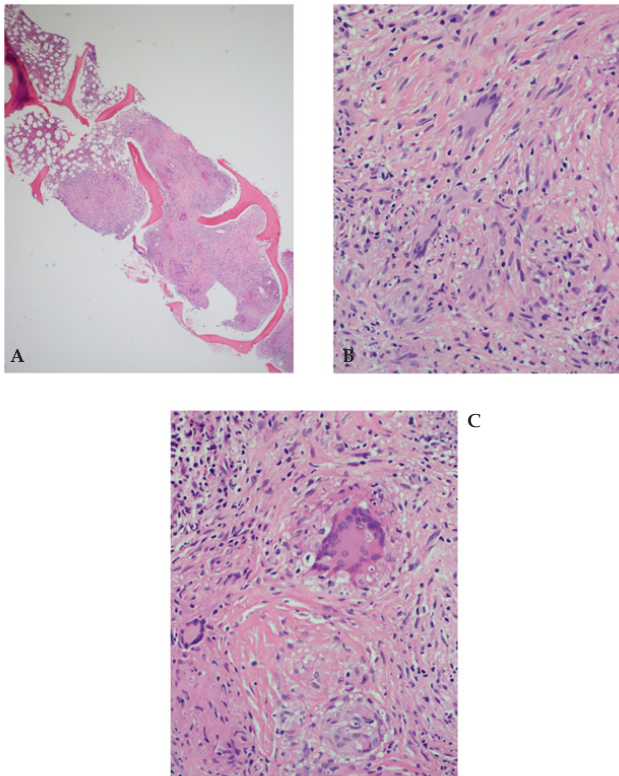


**Figure 1 A-B.** Left thigh and distal leg skin biopsy for intraepidermal nerve fibers of Patient 1. (A) Epidermal nerve axons are often short, thin, or tortuous. (B) They exhibit complex patterns of branching around the dermoepidermal junction (250 $\times$ , PGP9.5 antibody).

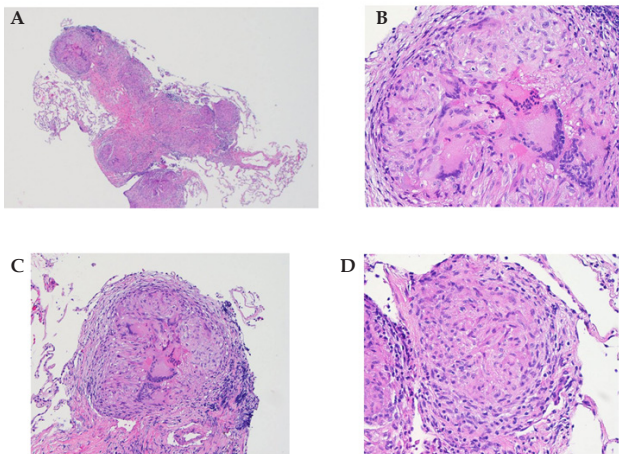


**Figure 2 A-C.** Whole body positron emission tomography fused with computed tomography after injection of 18fluorodeoxyglucose (FDG) in Patient 1. There is extensive uptake as shown by dark areas of FDG avid adenopathy above and below the diaphragm, lytic and sclerotic bone lesions through the axial and appendicular skeleton, and bilateral ill-defined lung air space opacities.

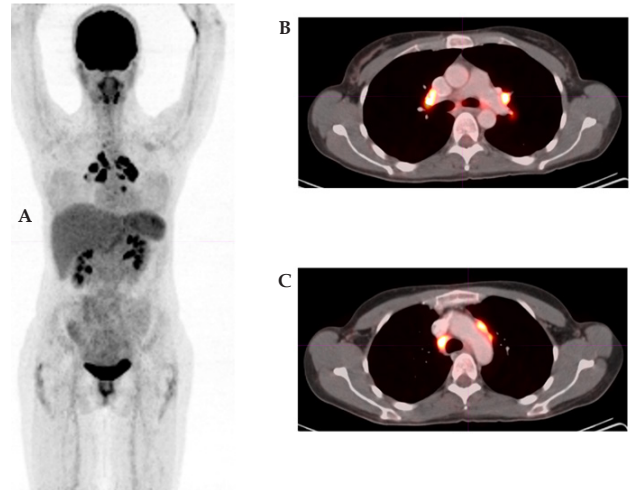




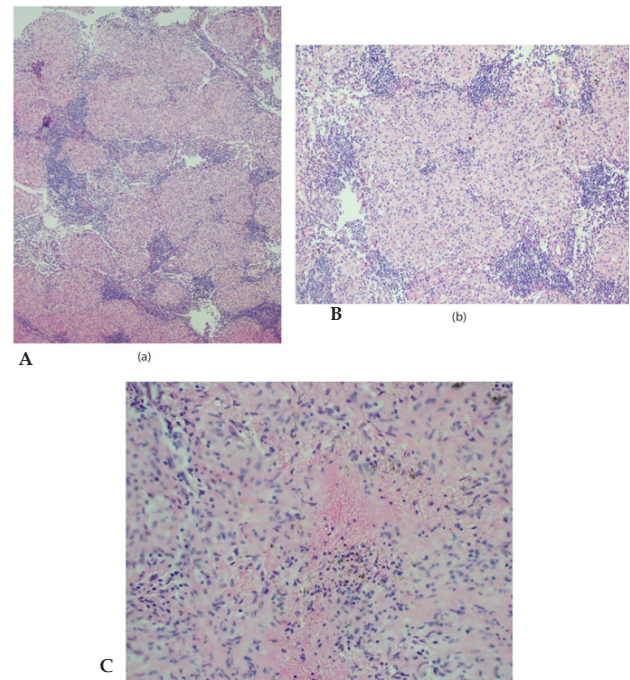
**Figure 3** A-C Right posterior iliac crest bone marrow aspiration biopsy of Patient 1. (A) There are multiple noncaseating granulomas involving about half of the biopsy at low magnification. (B-C) At higher magnification there are scattered multinucleated giant cells. A rim of mixed T/B cells is seen at the periphery by Immunohistochemical stains (not shown) (Hematoxylin and eosin, 4× and 40×).



**Figure 4** A-D. Right upper lobe biopsy of Patient 1. (A) Multiple well-formed non-caseating granulomas expand the interstitium. (B) The non-caseating granulomas are composed of epithelioid histiocytes and multi-nucleated giant cells. (C-D) The non-caseating granulomas are composed of epithelioid histiocytes and multi-nucleated giant cells (Hematoxylin and eosin, 4×, 20×, and 40×).



**Figure 5** A-C. Whole body positron emission tomography fused with computed tomography after injection of 18fluorodeoxyglucose (FDG) in Patient 2.



**Figure 5** A-C. Right paratracheal lymph node biopsy of Patient 2. (A-B) There are fragments of lymphoid tissue with totally effaced nodal architecture by confluent epithelioid granulomas. (C) A few granulomas with mild central necrosis are seen (Hematoxylin and eosin 10×, 20×, and 40×).

cytometry revealed polyclonal B-cells and a normal CD4/CD8 ratio; AFB and GMS stains were negative. There was no improvement after three months of 2 grams per kilogram of IVIg administered over 5 days per month. However, treatment with infliximab followed by methotrexate for one year led to sustained neurological improvement. She was normal at followup examination in August 2014 and repeat chest-CT showed no evidence of sarcoidosis.

## DISCUSSION

Although similar in presentation of painful small fiber neuropathy, dysautonomia, and APA, our two patients differed in the extent of sarcoid involvement as detected by whole body FDG-PET/CT and the findings of IENF analysis. Extensive lytic bone lesions were noted in the first patient with qualitative IENF changes and normal density measures, whereas the second patient had less extensive lesions with low nerve fiber density.

It is unclear whether IENF measures accurately predict the prognosis of sarcoidosis or associated dysautonomia. The concurrence of APA syndrome and sarcoidosis was uniquely described in two patients<sup>[6]</sup>, both of whom had concomitant systemic lupus erythematosus, neither of whom had painful small fiber neuropathy or dysautonomia. The presence of APA in both of our patients suggested a possible common predisposing common autoimmune etiopathogenesis in addition to sarcoidosis. While useful in the treatment of concomitant APA, IVIg did not show clear benefit in sarcoidosis-associated painful small fiber neuropathy or dysautonomia.

A Joint Task Force of the European Federation of Neurological Societies and the Peripheral Nerve Society<sup>[7]</sup> found that IENF analysis was a reliable technique to ascertain small fiber neuropathy but questionably useful in screening for peripheral autonomic neuropathy. Further studies of IENF studies in small fiber neuropathy and dysautonomia are needed before integrating them into clinical practice, especially as a useful outcome measure in patients with sarcoidosis, painful small fiber neuropathy or dysautonomia.

## CONFLICT OF INTERESTS

The Author has no conflicts of interest to declare.

## REFERENCES

- 1 Said G. Sarcoidosis of the peripheral nervous system. *Handb Clin Neurol* 2013; **115**: 485-495
- 2 Stern BJ, Krumholz A, Johns C, Scott P, Nissim J. Sarcoidosis and its neurological manifestations. *Arch Neurol* 1985; **42**:909-917.
- 3 Bakkens M, Merkies ISJ, Lauria G. Intraepidermal nerve fiber density and its application in sarcoidosis. *Neurology* 2009; **73**: 1142-1148
- 4 Judson MA, Costabel U, Drent M, Wells A, Maier L, Koth L, Shigemitsu H, Culver DA, Gelfand J, Valeyre D, Sweiss N, Crouser E, Morgenthau AS, Lower EE, Azuma A, Ishihara M, Morimoto S, Tetsuo Yamaguchi T, Shijubo N, Grutters JC, Rosenbach M, Li HP, Rottoli P, Inoue Y, Prasse A, Baughman RP, Organ Assessment Instrument Investigators TW. The WASOG Sarcoidosis Organ Assessment Instrument Investigators. The WASOG sarcoidosis organ assessment instrument; an update of a previous clinical tool. *Sarcoidosis Vasc Diffuse Lung Dis* 2014; **31**: 19-27
- 5 Younger DS. Sarcoidosis associated painful autoimmune ganglionopathy and dysautonomia improvement after immunotherapy. *Clin Auto Res* 2007; **17**: 264-327
- 6 Wesemann DR, Costenbader KH, Coblyn JS. Co-existing sarcoidosis, systemic lupus erythematosus and the antiphospholipid syndrome: case reports and discussion from the Brigham and Women's Hospital Lupus Center. *Lupus* 2009; **18**: 202-205
- 7 European Federation of Neurological Societies and the Peripheral Nerve Society Guideline on the use of skin biopsy in the diagnosis of small fiber neuropathy. Report of a joint task force of the European Federation of Neurological Societies and the Peripheral Nerve Society. *Eur J Neurol* 2010; **17**: 903-912

**Peer reviewer:** Janny Sun, Emeritus Professor, Hong Kong, Editor-In-Chief of International Journal of Neurology Research, ACT Publishing Group Limited Company.