

## Scapular Dyskinesia: Related Pathology

Emilio López-Vidriero, MD PhD, Rosa López-Vidriero, MD, Luis Fernandez Rosa, Emiliano Gallardo, M.Sp.Phty, Jose Antonio Fernández, MD, Rafael Arriaza, MD, PhD, Julian Ballesteros

Emilio López-Vidriero, Rosa López-Vidriero, Emiliano Gallardo, Jose Antonio Fernández, Julian Ballesteros, International Sports Medicine Clinic (ISMEC), Sevilla, Calle Arjona 10, bajo, 41001, Sevilla, Spain

Luis Fernandez Rosa, University of Fisioterapia. San Pablo CEU, Urbanización Montepríncipe, 28668 Boadilla del Monte, Madrid, Spain

Emilio López-Vidriero, Madrid Open Masters 1000 Medical Department, Camino de Perales, Madrid Caja Mágica, 28041 Madrid, Spain

Rafael Arriaza, Arriaza Associates. La Coruña, Edificio Coruña Sport Centre, C/ Enrique Mariñas s/n, 15009 A Coruña, Spain

Correspondence to: Emilio López-Vidriero, MD PhD, International Sports Medicine Clinic (ISMEC), Sevilla, Calle Arjona 10, bajo, 41001, Sevilla, Spain

Email: [director@traumatologiadepportiva.com](mailto:director@traumatologiadepportiva.com)

Telephone: +34 628400710

Received: September 13, 2014 Revised: October 11, 2014

Accepted: October 15, 2014

Published online: February 23, 2015

### ABSTRACT

Shoulder pain is one of the most frequent causes of disability in overhead sports and often forces athletes and workers to stop their activities. Scapular dyskinesia is not an injury or a musculoskeletal diagnosis, but rather an alteration of the normal position or motion of the scapula during coupled scapulohumeral movements. The underlying pathology can be multifactorial in nature, and understanding the various contributing factors is important in order to properly diagnose and treat the patient. An additional goal should be the prevention of further pathology or symptoms. In the present article the concept of scapular dyskinesia is reviewed along with a review of the literature regarding related pathology and our observations. Scapular dyskinesia can exist in asymptomatic individuals. In symptomatic patients with shoulder pain the scapular rhythm should be evaluated and treated. Some of the associated pathologies could be subacromial impingement, internal

impingement, chronic acromioclavicular dislocations grade III, chronic neck pain. Physical therapy is usually the preferred treatment of choice and effective to treat these patients.

© 2015 ACT. All rights reserved.

**Key words:** Scapular dyskinesia; Scapulohumeral rhythm; Athlete's shoulder; GIRD; Physiotherapy protocol

López-Vidriero E, López-Vidriero R, Gallardo E, Fernández JA, Arriaza R, Ballesteros J. Scapular Dyskinesia: Related Pathology. *International Journal of Orthopaedics* 2015; 2(1): 191-195 Available from: URL: <http://www.ghrnet.org/index.php/ijo/article/view/1049>

### INTRODUCTION

Shoulder pain is one of the most frequent causes of disability in overhead sports<sup>[1]</sup> and often forces athletes and workers to stop their activities.

The underlying pathology can be multifactorial in nature, and understanding the various contributing factors is important if the patient is to be properly treated and rehabilitated. An additional goal should be the prevention of further pathology or symptoms.

Dyskinesia in and of itself is not an injury or a musculoskeletal diagnosis<sup>[2-5]</sup>.

The alteration of the normal position or motion of the scapula during coupled scapulohumeral movements<sup>[4]</sup>, is the definition of dyskinesia.

A large number of factors related to the suspensory shoulder complex and the scapulotorathic joint may cause dyskinesia<sup>[5]</sup>.

It is important to emphasize that scapular dyskinesia is rarely the cause of referral and is usually encountered only through physical evaluation.

Conservative treatment of dyskinesia and GIRD by means of physiotherapy has shown to be effective in terms of return to sports and workplace activities<sup>[2,3,6-8]</sup>.

Unfortunately, in some cases the patient presents to the clinic too

late for conservative treatment and surgery may be needed to treat the underlying pathology. Favorable results may still be obtained if the pathophysiology is fully evaluated and understood<sup>[9]</sup>.

A holistic/comprehensive approach to the athlete's shoulder is advisable to correctly diagnose, treat and prevent these conditions.

In this article the concept of dyskinesis is reviewed along with a review of the literature regarding related pathology and our observations.

## METHODS

A comprehensive and thorough research of the databases 'Medline', 'Cochrane', 'Science Direct' was performed with the keywords 'Scapular Dyskinesis', obtaining 20 manuscripts.

## RESULTS

Only one manuscript met all search criteria within the title.

56 manuscripts were found with the keyword 'motocross'. A thorough search of every abstract was performed to obtain the final 19 references used within the present manuscript.

## CONCEPT OF DYSKINESIS

Dyskinesis in and of itself is not an injury or a musculoskeletal diagnosis<sup>[2,5]</sup>.

The alteration of the normal position or motion of the scapula during coupled scapulohumeral movements<sup>[4]</sup> is the definition of dyskinesis.

'Dys' (alteration of) 'kinesis' (motion) is a general term that reflects the loss of normal control of scapular motion.

Dyskinesia is often used as an alternative term, but both terms do not refer to the same concept.

Dyskinesia is usually applied to abnormal voluntary movements such as tardive dyskinesia. Since there are many other factors that can cause the altered position and motion, such as clavicle fractures, AC joint separations and muscle detachments, the more inclusive term dyskinesis is preferred<sup>[2,3,5]</sup>.

Dyskinesis has been hypothesized to relate to changes in GH angulation, AC joint strain, subacromial space dimension, shoulder muscle activation and humeral position and motion<sup>[5]</sup>.

## CAUSES OF DYSKINESIS

A large number of factors related to the suspensory shoulder complex and the scapulotorathic joint might cause dyskinesis: these include<sup>[5]</sup>: (1) Bone causes: clavicle fracture non-union or shortened malunion, kyphosis, bone tumors; (2) Joint causes: AC instability, AC osteoarthritis, GH internal derangement; (3) Neurological causes: cervical radiculopathy, long thoracic or spinal accessory nerve palsy, suprascapular nerve entrapment; (4) Soft tissue causes: rotator cuff injuries, inflexibility or stiffness of the pectoralis minor and short head of the biceps, infraspinatus inflexibility and posterior capsule tightness that leads to GIRD, which results in winging of the scapula.

## CLASSIFICATION

There have been many attempts to classify scapular dyskinesis.

Kibler<sup>[10]</sup> defined the most accepted classification as 3 different types of motion abnormalities: **Type I:** inferior medial scapular angle prominence. Associated with excessive anterior tilting of the

scapula. **Type II:** entire medial border prominence. Associated with excessive scapular internal rotation. **Type III:** excessive superior border elevation. Associated with excessive upward translation of the scapula. **Type IV:** Normal, symmetric scapular motion.

Due to the fact that this classification has a low inter- and intraobserver reliability, another method of classification has been defined using the YES/NO criteria<sup>[10]</sup>.

The results of Tim's study showed that the yes/no method increased the inter-rater agreement and increased the sensitivity (76%) and PPV (74%) over the original 4-type method; however, it should be noted that specificity was 30%. The authors concluded that because the yes/no method took into account multiple-plane asymmetries it could be considered a beneficial screening tool.

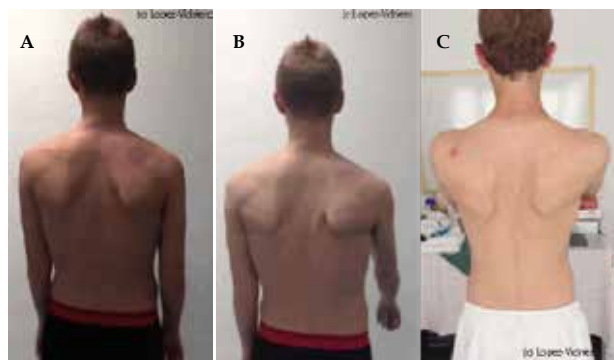
## ASSESSMENT/EVALUATION

Although many clinical assessment methods for scapular dyskinesis have been developed, during the dyskinesis summit<sup>[2,3,5]</sup> the experts concluded that the most valid ones were as follows:

### Physical Examination & evaluation

#### (1) Observation

Static observation is useful. But because dyskinesis is a dynamic entity, it must be assessed while the scapula moves. The experts agreed that the best method is the dynamic scapular dyskinesis test. This consists of weighted shoulder flexion and abduction movement while the scapular motion is closely observed. Any deviation from the norm is noted as a "yes" (dyskinesis) (Figure 1) or "no" (normal motion)<sup>[10]</sup>. In our practice, the medial side of the scapula is observed while the patient moves both arms up and down in the scapular plane at least 3 times. If the medial side of the scapula wings or deviates from the normal plane the test is considered positive.



**Figure 1** Scapular dyskinesis in professional tennis players. A: Static observation of scapular dyskinesis; B: Dynamic observation. Unilateral movement; C: Dynamic observation. Bilateral movement.

#### (2) Manual correction Tests<sup>[8,11-13]</sup>

**Scapular assistance test (SAT):** consists of manually assisting scapular upward rotation during shoulder elevation. This is achieved by pushing the inferior medial border of the scapula laterally and upward while stabilizing the upper medial border. Finally, the evaluator determines if this maneuver decreases or alleviates the pain. This test is based on the theory of subacromial impingement being caused by malposition of the acromion tilted forward impinging on the bursa and cuff causing pain while forward flexion. The test is positive if the impingement symptoms are alleviated or disappear when correcting the shoulder blade dyskinesis. Therefore, this particular test is helpful only in evaluation of athletes symptomatic with impingement syndrome.

**Scapular reposition test (SRS)**<sup>[11,13]</sup>: consists of manually repositioning the scapula into greater retraction and posterior tilt. It is positive if there is a reduction in pain or an increase in strength during isometric arm elevation.

It is important to remember that patients with shoulder complaints typically localize the pain to the anterior or lateral part of their upper arm. Thus the posterior part of the shoulder is frequently overlooked during the physical examination.

In our opinion the evaluation of the scapular rhythm observed from the back should be routinely included in the physical examination protocol of the shoulder.

## ASSOCIATED PATHOLOGY

Common pathologies are associated with scapular dyskinesia. As noted previously, when a patient seeks consultation for any of these pathologies, the posterior aspect of the shoulder in motion should be observed in order to both better diagnose and treat the underlying condition.

### Subacromial impingement

There are many factors that may cause subacromial impingement.

It has been demonstrated that in many cases the impingement results from a dynamic alteration of the positions of the humeral head, rotator cuff and acromion, rather than a static alteration such as a bone spur<sup>[3]</sup>.

Many individuals with scapular dyskinesia suffer from subacromial impingement because upon elevating the arm, the scapula experiences an increase in upward rotation and anterior tilt causing the anterior part of the acromion to move forward and downwards thus reducing the size of the subacromial space<sup>[14]</sup>.

Amee L *et al* studied<sup>[12]</sup> the effects of the scapular assistance test (SAT) in patients with impingement. In this study, the SAT is considered a corrective maneuver to decrease pain, presumably due to an increased subacromial space by way of increased scapular posterior tilt and upward rotation. Accepting this conclusion would therefore validate the SAT as helpful to identifying individuals where subacromial compression produces symptoms.

Additionally, Amee's study also showed that participants with dyskinesia had a greater scapular upward rotation with the SAT than those without, indicating potential scapular hypermobility<sup>[15]</sup>.

### Internal impingement

Mihata T *et al* studied<sup>[15]</sup> the effect of scapular orientation on shoulder internal impingement in a cadaveric model of the cocking phase of throwing. They demonstrated that a scapular position of less upward rotation and increased internal rotation (protraction), commonly seen in scapular dyskinesia, increased the area of contact of the head of the humerus with the posterior superior glenoid. As a result, increased scapular internal rotation was observed which thus increased the GH contact pressure.

### Chronic AC grade III dislocations

Alteration of the suspensory shoulder complex by interrupting the connection of the acromion and the clavicle can disrupt the mechanics of normal scapular rhythm<sup>[16]</sup>.

If such is the case, scapular dyskinesia results in functional loss of the AC joint as a stable fulcrum for the shoulder girdle or possibly due to the superior shoulder pain caused by the separation.

Recently, Burkhart *et al*<sup>[1]</sup> have related the disabled throwing shoulder to a specific overuse muscle fatigue syndrome: "The SICK scapula".

The SICK syndrome stands for Scapular malposition, Inferior medial border prominence, Coracoid pain and malposition, and scapular dyskinesia<sup>[1]</sup>.

Patients affected by a chronic type III AC dislocation develop scapular dyskinesia and SICK syndrome in 70% and 58% of cases respectively.

Kibler *et al*<sup>[1,16]</sup> proposed a rehabilitation program consisting of strengthening and stretching the scapular muscles with exercises to regain control of scapular protraction, retraction, depression, elevation and rotation. Currently, there are no published studies of clinical results in patients with dyskinesia related to chronic AC dislocation. Unfortunately, whether these patients would benefit more from physical therapy or surgical treatment is not known.

### Chronic neck pain

The scapula serves as the connection between the axial and appendicular skeletons. Logically, injuries affecting the neck may alter the biomechanics of the shoulder and arm; as expected, the converse is also true.

Studies investigating the relationship between neck pain and scapular dysfunction have only recently begun to emerge<sup>[17]</sup>.

It has been demonstrated that increased cervical and thoracic curves and a slouched posture affect scapular orientation, shoulder muscle strength and shoulder range of motion<sup>[18]</sup>.

Recently, Helgadottir *et al* studied scapular orientation disorders<sup>[19]</sup>, at rest and during arm elevation, in patients with insidious onset neck pain and whiplash-associated disorders (WAD). They showed that neck pain was associated to scapular dyskinesia and proposed a physiotherapeutic protocol that includes parascapular muscle stretching, cross chain kinetic exercises and stiff structures stretching. This protocol showed good results not only in regards to improving scapular dyskinesia but also reducing neck pain<sup>[18]</sup>.

When evaluating a patient with neck pain, scapular motion should be carefully observed. In case of scapular dyskinesia, a physiotherapeutic program should be recommended.

## PHYSIOTHERAPEUTIC PROTOCOL FOR SCAPULAR DYSKINESIS

Based on Anne Cools' studies<sup>[17]</sup> and on our practice we have developed a physiotherapeutic protocol for scapular dyskinesia.

It is divided into 3 phases: (1) Conscious muscle control; (2) Muscle control and strength necessary for daily activities; (3) Advance control during sports movements.

### Phase 1: Conscious muscle control

During this first phase, the objective is to gain conscious muscle control.

The most physiologic way to it is with the exercises that involve closed-chain activities (scapular clock), which are elevation, depression, and retraction/protraction exercises with the hand on a wall. Each exercise should be repeated on 3 series of 15 repetitions each.

### Phase 2: Muscle control and strength necessary for daily activities

Once muscle balance is restored, the patient should start general scapular strengthening exercises.

Elastic bands are recommended to perform these exercises that consist on: Closed chain exercises and eccentric exercises for biceps.

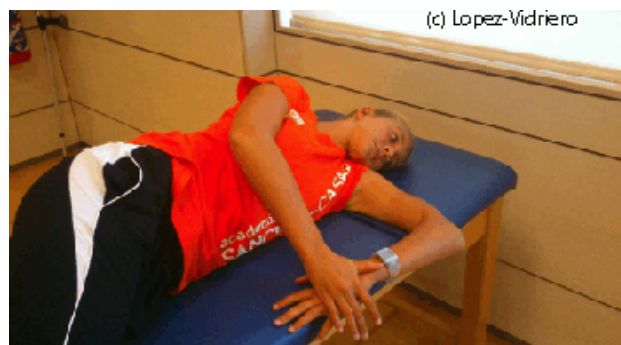For posterior capsule stretching: sleeper stretch and cross body

stretch exercises (Figures 2 and 3).

For the scapular dyskinesis, cross-kinetic chain exercises are instructed with elastic bands in the prone position elevating one arm and the contralateral leg at the same time (Figures 4 and 5).




**Figure 2** Correct sleeper's stretch in the lateral decubitus position. Correct way to perform the exercise by leaning on the shoulder girdle to stabilize the scapula. Because the tennis player performs this exercise by herself she needs to be well instructed in how to do it correctly.



**Figure 3** Incorrect sleeper's stretch. Incorrect way to perform the exercise. Notice how the tennis player leans backwards allowing the shoulder to internally rotate free. Although she had a severe internal rotation deficit. This is a cause of failure of this type of treatment.



**Figure 4** Cross chain kinetic strengthening exercises. Based on Anne Cool's approach. Strengthening of the parascapular muscles in combination with cross kinetic chain reinforcement is of most importance.



**Figure 5** Parascapular muscle strengthening. Using rubber bands and focusing on stabilizing the scapulae in 3 different planes.

Closed chain exercises are believed to improve dynamic glenohumeral stability through stimulation of the intra-articular and periarticular proprioceptors and enhance co-contraction of the rotator cuff, thus being beneficial in case of shoulder instability<sup>[17]</sup>.

### Phase 3: Advance control during sports movements

During this last stage of muscle control and strength, special attention should BE paid to integrate kinetic chain into the exercise program and implement sport-specific demands by performing plyometric and eccentric exercises, such as back push-ups, push-ups in parallel bars and on the floor.

Throwing athletes should perform eccentric exercises for external rotators with weight balls and elastic resistance-tubing.

Swimmers on the other hand should focus on core stability exercises doing exercises such as W-V exercises, in which the patient is prone on a Swiss ball and perform movements, forming a W and a V with his arms<sup>[18]</sup>.

In our experience, the described protocol was very effective in a pilot study<sup>[20]</sup>. The athletes/patients were able to return to their former occupation and sportive activities in a month and almost without any pain.

## CONCLUSION

The altered motion of the scapula defines scapular dyskinesis during elevation and descent of the arm. Observation of the medial wall of the scapula during motion is of most importance.

Whether scapular dyskinesis is adaptive or pathologic is not well understood.

Scapular dyskinesis can exist in asymptomatic individuals. In symptomatic patients with shoulder pain the scapular rhythm should be evaluated and treated.

Scapular dyskinesis usually appears in combination with other pathologic entities like: subacromial impingement, internal impingement, chronic AC dislocations, neck pain, long head of biceps tenderness.

When a patient is referred with one of these pathologies the dynamics of the scapular movement should be evaluated and treated if altered.

Most of the time conservative treatment based on conscious parascapular muscle control, strengthening and advance performance during daily life and sport specific tasks, is useful

Conservative comprehensive physiotherapy treating all the pathologic entities is effective.

## ACKNOWLEDGEMENTS

To the medical department of Madrid Open Tennis Masters 1000. To Sebastian Tobaruela. Technical director of the Andalusian Tennis federation FATENIS. To our father, Dr Emilio López-Vidriero, who showed us the way of research and clinical improvement.

## CONFLICT OF INTERESTS

There are no conflicts of interest with regard to the present study.

## REFERENCES

- Burkhart SS, Morgan CD, Kibler WB. The disabled throwing shoulder: spectrum of pathology Part III: The SICK scapula, scapular dyskinesis, the kinetic chain, and rehabilitation. *Arthroscopy* 2003; **19**(6): 641-661



- 2 Kibler WB, Ludewig PM, McClure P, Uhl TL, Sciascia A. Scapular Summit 2009: introduction. July 16, 2009, Lexington, Kentucky. *J Orthop Sports Phys Ther* 2009; **39(11)**: A1-A13
- 3 Kibler WB, Ludewig PM, McClure PW, Michener LA, Bak K, Sciascia AD. Clinical implications of scapular dyskinesia in shoulder injury: the 2013 consensus statement from the 'Scapular Summit'. *Br J Sports Med* 2013; **47(14)**: 877-885
- 4 Kibler WB, Sciascia A. Current concepts: scapular dyskinesia. *Br J Sports Medicine* 2010; **44(5)**: 300-305
- 5 Kibler WB, Sciascia AD. Introduction to the Second International Conference on Scapular Dyskinesia in Shoulder Injury--the 'Scapular Summit' Report of 2013. *Br J Sports Med*. 2013;47(14):874.
- 6 Kibler WB, Sciascia A, Wilkes T. Scapular dyskinesia and its relation to shoulder injury. *J Am Acad Orthop Surg* 2012; **20(6)**: 364-372
- 7 Lopez-Vidriero E. The shoulder of professional tennis players: gird, tenosynovitis of biceps and dyskinesia. *Knee Surg Sports Traumatol Arthrosc* 2014; **22**: S396
- 8 Merolla G, De Santis E, Campi F, Paladini P, Porcellini G. Infraspinatus scapular retraction test: a reliable and practical method to assess infraspinatus strength in overhead athletes with scapular dyskinesia. *J Orthop Traumatol* 2010; **11(2)**: 105-110
- 9 Arriaza R, Ballesteros J, Lopez-Vidriero E. Suprascapular neuropathy as a cause of swimmer's shoulder: results after arthroscopic treatment in 4 patients. *Am J Sports Med* 2013; **41(4)**: 887-893
- 10 Uhl TL, Kibler WB, Gecewich B, Tripp BL. Evaluation of clinical assessment methods for scapular dyskinesia. *Arthroscopy* 2009; **25(11)**: 1240-1248
- 11 McClure P, Tate AR, Kareha S, Irwin D, Zlupko E. A clinical method for identifying scapular dyskinesia, part 1: reliability. *J Athl Train* 2009; **44(2)**: 160-164
- 12 Seitz AL, McClure PW, Lynch SS, Ketchum JM, Michener LA. Effects of scapular dyskinesia and scapular assistance test on subacromial space during static arm elevation. *J Shoulder Elbow Surg* 2012; **21(5)**: 631-640
- 13 Tate AR, McClure P, Kareha S, Irwin D, Barbe MF. A clinical method for identifying scapular dyskinesia, part 2: validity. *J Athl Train* 2009; **44(2)**: 165-173
- 14 Han KJ, Cho JH, Han SH, Hyun HS, Lee DH. Subacromial impingement syndrome secondary to scapulothoracic dyskinesia. *Knee Surg Sports Traumatol Arthrosc* 2012; **20(10)**: 1958-1960
- 15 Mihata T, Jun BJ, Bui CN, et al. Effect of scapular orientation on shoulder internal impingement in a cadaveric model of the cocking phase of throwing. *J Bone Joint Surg Am* 2012; **94(17)**: 1576-1583
- 16 Gumina S, Carbone S, Postacchini F. Scapular dyskinesia and SICK scapula syndrome in patients with chronic type III acromioclavicular dislocation. *Arthroscopy* 2009; **25(1)**: 40-45
- 17 Cools AM, Struyf F, De Mey K, Maenhout A, Castelein B, Cagnie B. Rehabilitation of scapular dyskinesia: from the office worker to the elite overhead athlete. *Br J Sports Med* 2014; **48(8)**: 692-697
- 18 Cools AM, Borms D, Cottens S, Himpe M, Meersdom S, Cagnie B. Rehabilitation Exercises for Athletes With Biceps Disorders and SLAP Lesions: A Continuum of Exercises With Increasing Loads on the Biceps. *Am J Sports Med* 2014; **42(6)**: 1315-1322
- 19 Helgadottir H, Kristjansson E, Mottram S, Karduna AR, Jonsson H, Jr. Altered scapular orientation during arm elevation in patients with insidious onset neck pain and whiplash-associated disorder. *J Orthop Sports Phys Ther* 2010; **40(12)**: 784-791
- 20 Lopez-Vidriero E. Biceps tenosynovitis and scapular dyskinesia. Treatment protocol and results. *Knee Surg Sports Traumatol Arthrosc* 2014; **22**: S378

**Peer reviewer:** Amr Mohamad Abdelhady, Professor, Department of Orthopaedic, Faculty of Medicine, Ain Shams University. Abbasia Square, Cairo Egypt.