

Role of Growth Factors in Bone-Tendon-Bone ACL Surgery: Time for Maturation of the ACL Graft and the Patellar Tendon Donor Site

Roberto Seijas, MD, PhD, Oscar Ares, MD, PhD, Jordi Català, Xavier Cuscó, MD, Pedro Álvarez, MD, Montserrat García-Balletbó, Ramón Cugat, MD, PhD

Roberto Seijas, Oscar Ares, Xavier Cuscó, Pedro Álvarez, Ramón Cugat, Department of Orthopaedic Surgery, Fundación García Cugat, Quirón Hospital, Barcelona, Spain

Roberto Seijas, Oscar Ares, Professor in Anatomy Department. Internacional University of Catalunya, Barcelona, Spain

Oscar Ares, Pedro Álvarez, Profesor in Orthopaedic and Trauma Surgery. Internacional University of Catalunya, Barcelona, Spain

Montserrat García-Balletbó, Department of Regenerative Medicine, Fundación García Cugat. Quirón Hospital, Barcelona, Spain

Pedro Álvarez, Ramón Cugat, Catalan Soccer Delegation's Health Insurance Company, Spanish Soccer Federation, Barcelona, Spain

Jordi Català, Medical Director Alomar Centers, Barcelona, Spain

Correspondence to: Roberto Seijas, MD, PhD, Department of Orthopaedic Surgery, Fundación García Cugat, Quirón Hospital, Barcelona, Internacional University of Catalunya, Plaza Alfonso Comín 5-7, 08023 Barcelona, Spain

Email: seijastraumatologia@gmail.com

Telephone: +34932172252

Fax: +34932381634

Received: September 13, 2014

Revised: October 11, 2014

Accepted: October 15, 2014

Published online: February 23, 2015

ABSTRACT

AIM: Anterior Cruciate Ligament surgery can be complemented with biological treatments, including plasma rich in growth factors, which have been demonstrated by numerous authors to accelerate the process of tendon maturation. Studies both *in vitro* and in animals, including human studies have shown improved results in ligament strength and structure, as well as earlier ACL graft maturation. We present the results of two studies on maturation with the use of PRGF-Endoret®. ACL graft and donor site.

METHODS: 100 soccer players were randomly divided into two groups, group A received a dose of PRGF-Endoret while the other one was used as a control. MRI was performed to assess the grade

of maturation at several time schedules. Another group of patients (40) were divided into with the same characteristics but assessing the donor site with ultrasounds.

RESULTS: In the first group study, The MRI showed statistically different maturation grade at 4 months and at 6 months. Once they reached the year no significant differences ($p=0.354$) between both groups were observed. The second study groups were composed of 23 and 19 patients, who underwent ACL surgery with and without PRGF-Endoret® at the donor site. The PRGF group showed significantly increased maturation speed at 4th postoperative month.

DISCUSSION: The results show that the use of PRGF-Endoret® significantly accelerates the processes of maturation of both anatomical regions.

© 2015 ACT. All rights reserved.

Key words: ACL; Knee; Platelet-rich plasma; PRGF

Seijas R, Ares O, Cuscó X, Álvarez P, García-Balletbó M, Cugat R. Role of Growth Factors in Bone-Tendon-Bone ACL Surgery: Time for Maturation of the ACL Graft and the Patellar Tendon Donor Site. *International Journal of Orthopaedics* 2015; 2(1): 196-201 Available from: URL: <http://www.ghrnet.org/index.php/ijo/article/view/1050>

INTRODUCTION

Knee injury is common in sports. Anterior Cruciate Ligament (ACL) injury is one of the most frequent, reaching 70% and typically with an indirect injury mechanism of deceleration-rotation without contact^[1]. In the United States, 50,000 patients require ACL surgery annually^[2-4].

The majority of these injuries are sports related and affect patients between 15 and 45 years old with 47% taking place during the decade from 30 to 40 years old^[1]. It is estimated that one ACL tear occurs every 1,500 hours of sports practice, including sports such as soccer, basketball, rugby and skiing, which is equivalent to one injury

for every 1,750 citizens of the U.S.^[1]

The cost of an ACL reconstruction surgery in the U.S. is an estimated \$ 17,000 to which one can add an additional \$ 2,000 for the cost of the initial care of all ACL injuries and/or the conservative treatment of the patients who do not undergo ACL reconstruction. The annual cost of treating only ACL injuries is an estimated 1 billion dollars^[1]. Overall costs of sport-related injuries in the U.S. in 2002 were estimated at about 15.8 billion dollars^[5].

ACL reconstruction in a high number of cases is performed with BTB (patellar tendon) of which 4–60% present anterior knee pain^[4,6–8].

Recovery from joint injuries in active athletes is increasingly faster due in part to the progress and improvement of surgical techniques and the application of biological elements that promote rapid tissue regeneration^[9]. This improved ligamentization has been shown in ACL graft maturation^[10–13] and the patellar tendon donor site^[4,14–17].

In recent years the application of platelet-rich plasma (PRP) or plasma rich in growth factors (PRGF) has been linked to faster tissue regeneration in bone, cartilage, ligaments and tendons, for studies *in vitro*, *in vivo* and in humans^[9,18–20]. There are different ways to obtain PRP. The PRGF[®] system is the longest used technique and the Food and Drug Administration (FDA) in the U.S. and Conformité Européenne (CE) in European Community have approved the system^[4,13].

The assessment of tendon regeneration has led to the realization of various studies with both Magnetic Resonance Imaging (MRI) and Ultrasound, depending on the location and accessibility of the tissue^[21–23]. In ligaments and tendons such as the ACL, MRI has been used most^[11,13,24].

The present study assessed the impact PRGF-Endoret[®] had on the processes of ligament maturation and the time required for maturation to take place in both the ACL graft and the patellar tendon donor site. Our hypothesis was that PRGF would accelerate the process of maturation with respect to the non-PRGF group.

METHODS

Inclusion criteria were patients who had suffered acute injury of the ACL with rotational instability of the knee, both symptomatically and upon exploration with normal joint mobility and not presenting bone edema, with reconstructive surgery as the proposed treatment option not scheduled to take place until 6 weeks post injury. Exclusion criteria were previous surgery in the affected knee, infectious or tumor diseases around the knee joint and surgeries performed later than 6 weeks after the injury. After selection and enrollment all subjects were automatically randomized into group A or B using the function RANDOM from MICROSOFT EXCEL, (Microsoft Office 2007). Once assigned to a group the only differential in treatment between patients was at the end of surgery when growth factors were either applied or not, in accordance with their randomly assigned group. The rest of the treatment including follow-up, control periods and additional tests were synonymous for all patients included in the trial.

The results of two studies are included in this paper. The first, randomized 100 football players into two groups that underwent BTB ACL ligamentoplasty and after randomly dividing them into two groups, at the end of the surgery group A received a dose of PRGF-Endoret[®] while the other was used as control. MRI was performed on all of the patients at 4, 6 and 12 months to assess the grade of graft maturation. The MRI classification system by Howell *et al.*^[24] was the used for the present study, with certain variants added by our image expert Dr. Jordi Català, which lead to the creation of the Català Classification^[13].

In the second study, a clinical trial was performed by calculating an n of 40 patients, wherein group A, that included half of the patients, received PRGF-Endoret[®] exclusively at the donor site and the rest served as control. A follow up protocol was applied with Ultrasound to assess the donor site at 4, 8, 16, 24, 48 and 96 weeks, comparing the grade of maturation^[4].

Populations with complete ACL tear were included in both studies, all of them athletes, as described in papers^[4,13]. The same surgical team that employed the same surgical technique with inclusion and exclusion criteria described in both papers performed the surgical procedures.

In the ultrasonographic assessment, a classification was created (Rius classification) based on a previous study on 10 patients, 50 measurements and two sonographers with correlation higher than 95% (46). The patellar tendons were examined by ultrasonography before and after the ACL surgery by the same examiner. The study was performed with the equipment “ACUSON Antares (Siemens, Erlangen, Germany)” with a multi-frequency linear probe, between 7.27 and 11.43 Mhz.

Written and informed consent was obtained from all patients included in the study. Approval from the Hospital’s Ethics Committee and from the national state commission was obtained for the present.

RESULTS

In the first study, one patient in each group failed to complete the study, leaving two groups of 49 patients each. The MRI at 4 months showed statistically different maturation grade ($p=0.003$) between the two groups (Figure 1), as well as the assessment at 6 months ($p=0.0001$) (Figure 2). Once they reached the year no significant differences ($p=0.354$) between both groups were observed (Figure 3).

In the second study groups were composed of 23 and 19 patients, who underwent ACL surgery with and without PRGF-Endoret[®] at the donor site. The PRGF group showed significantly increased maturation speed at 4th postoperative month ($p=0.0037$) (Figure 4). 40 patients were the number of patients calculated to for the clinical trial and an additional 10% were added taking into consideration the possible loss of patients. Finally, 2 patients from the second group were lost during follow-up, making the final 23-19 patients. A significant association of maturity with the presence of PRGF in the fourth month of follow-up ($p=0.0037$) was observed

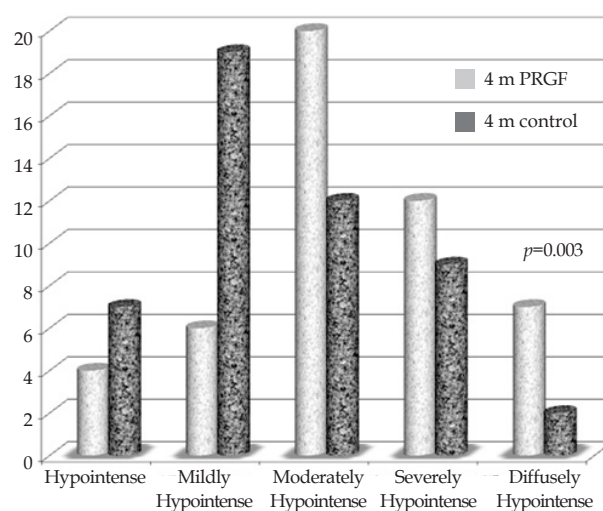


Figure 1 There is statistical significance between PRGF and control group at 4 months following surgery (MRI).

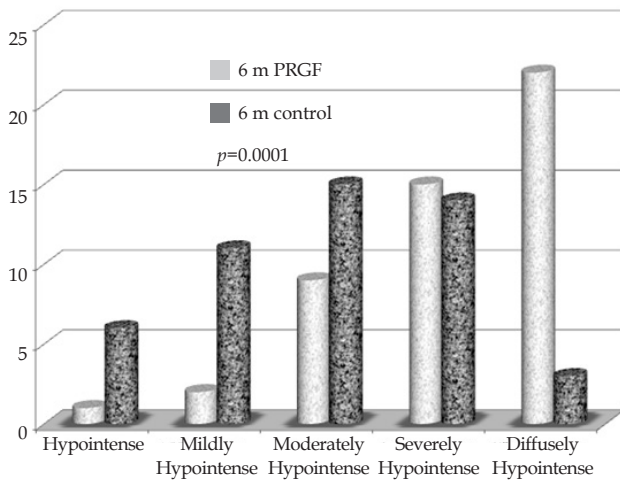


Figure 2 There is statistical significance between PRGF and control group at 6 months following surgery (MRI).

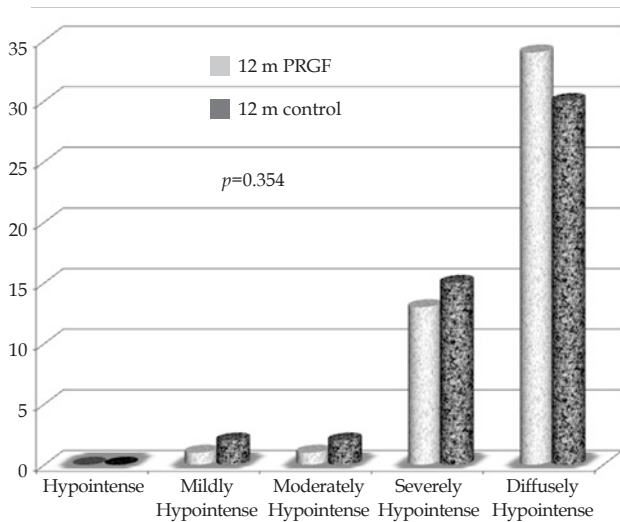


Figure 3 There is no statistical significance between PRGF and control group at 12 months following surgery (MRI).

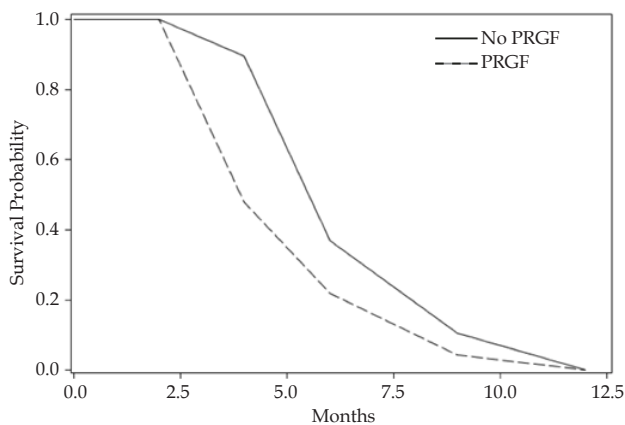


Figure 4 Increased velocity towards stages of complete maturation in the PRGF group, with statistically significant differences (Ultrasound). The PRGF group showed significantly increased maturation speed at 4th postoperative month.

DISCUSSION

The studies reviewed show that the application of PRGF-Endoret[®], both at an articular level and at the donor site, favours a faster maturation process in the ligaments evaluated, which is in line with results published in the present study^[10,11,25].

Different animal studies show a series of stages in the revascularization of the patellar graft used as anterior cruciate ligament. After a phase of graft avascular necrosis, with hypocellularity and collagen fragmentation, revascularization is produced through a synovial cover which originates from both the distal and proximal insertions of the graft that starts covering it and promotes intratendinous vascular growth up to complete coverage and cellularization at one year post-surgery^[26,27].

It is known that in order for the tissue repair-regeneration process to take place, a multitude of elements must interact, from various cellular components to proteins, metabolites and electrolytes, all encompassed within an appropriate environment^[5].

During this process, both in the acute inflammatory phase and in the cellular proliferation and remodelling phase^[28,29], platelets play an important role, not only based on haemostatic capacity, but also on their chemotactic activity and on growth, morphogenesis and cell differentiation^[30].

Over the last twenty years, several studies have been published which aimed at taking advantage of the benefits offered by this cell type in tissue repair, stimulating research and development in the field of regenerative medicine^[20,31-34].

The tissue repair process is based on a complex cascade of biological events controlled by a long list of growth factors and proteins with biological activity. The spatiotemporal action of this group of mediators at the area of damaged tissue regulates the mechanisms and phases that govern tissue repair and regeneration. Throughout this process, another set of factors regulates the dynamic balance between stimulation and inhibition of cell proliferation, angiogenesis and the formation of extracellular matrix^[31]. The tissue repair process involves several phases including angiogenesis, tissue proliferation and extracellular matrix deposition. The remodelling and maturation processes are combined with the mechanical stresses to which the tissue in question is subjected^[20].

Growth factors are substances of polypeptide nature, soluble and diffusible regulating growth, differentiation and phenotype of many cell types^[35]. These provide the initial signals for the activation of the cells in surrounding tissue. In response to signals provided by these molecules, local cells and those infiltrated, undergo changes in proliferation, differentiation, and protein synthesis with different biological functions.

These proteins act in an autocrine and/or paracrine manner. They affect cell behaviour, binding to specific receptors located in cell membranes. Not all cell phenotypes have the same receptors; therefore, the effect of the growth factors will not be the same in all tissues and in all situations^[36]. All these phenomena, together, define the process known as cell activation^[37].

The system for obtaining plasma rich in growth factors is not always uniform, with different techniques being followed by various authors, making the resultant products significantly different without reaching any conclusion about the degree of effectiveness from one to the other^[38].

PRGF-Endoret[®] is obtained from small volumes of the patients' blood (20 cc). It is not a platelet concentrate and is obtained after single stage centrifugation. It does not contain leukocytes and is

simply platelet-rich plasma. White cells, and especially leukocytes, contain proinflammatory cytokines and express metalloproteinases (MMP-8 and 9) capable of degrading the extracellular matrix. PRGF-Endoret[®] is 100% autologous and biocompatible^[31].

PRGF-Endoret[®] activation is performed with a standard dosage of calcium chloride, taking advantage of the patient's own thrombin and not using bovine thrombin, hence biosecurity risks are avoided. It obtains a platelet concentration of 2 to 3 times higher than the physiological, which is the optimum concentration, as lower doses would be sub-therapeutic and superior concentrations do not induce superior effects, they can even exert inhibitory actions^[31].

Culture studies with the use of PRGF-Endoret[®] have shown a cellular increase in tendon tissues and especially an increase in collagen levels^[31,39-41]. Animal studies also show increases in cell density, neovascularization, resistance force between 30% and 65% according to studies^[42-45] with an improvement within biomechanical properties in the medial collateral ligament in its early stages. Weiler showed how the application of autologous PDGF into the graft during surgery was able to alter natural maturation, improving tension, resistance, increasing the rate of maturation and improving collagen quality^[23]. The study by Xie *et al* suggested a role of PRGF in promoting synthesis of extracellular matrix after ACL reconstruction, in a study performed with dogs^[34]. Along the same lines, the study by Fernandez-Sarmiento *et al* showed histological changes at eight weeks, consistent with an accelerated early healing process in repaired Achilles tendons in sheep after surgical disruption and repair treated with PRGF-Endoret[®]^[25]. The work by Xie *et al* also states that the use of PRP alters the expression of some target genes at certain time points, especially during the early stages of graft remodelling, which might explain the enhancing effect of PRP on the ACL graft maturation process, which at a cellular level, could explain the result in both animals and human studies, including the two studies evaluated^[4,13,25,34].

With specific reference to the ACL graft, PDGF, FGF-1 and some TGF subtypes are responsible for the acceleration of tissue healing and increased graft tension^[11].

PRGF was associated with histological changes consistent with an accelerated early healing process in repaired Achilles tendons in sheep after experimental surgical disruption. PRGF-treated tendons showed improvements in the morphometric features of fibroblast nuclei, suggesting a more advanced stage of healing. At eight weeks, histological examination revealed more mature organization of collagen bundles, lower vascular densities, and decreased fibroblast densities in PRGF-treated tendons than in tendons infiltrated with saline solution. These findings were consistent with a more advanced stage of the healing process^[25].

Kondo *et al* also demonstrated that the application of growth factors in ACL elongations achieved improved tension compared with patients where growth factors were not applied^[18].

Studies have shown growth factors to be useful in achieving early mobility and earlier return to sports in Achilles tendons and rotator cuff repair^[20,46]. Meanwhile Foster *et al*^[9] published the series on medial collateral ligament injuries in soccer players with reductions of 27% in recovery times.

Studies show maturation of patellar graft evolution in terms of vascularization, cellularity, collagen fibre pattern and the presence of metaplasia with a high correlation^[22] showed maturity with a peak at just after 1-year post surgery but with vascularity and fibre pattern similar to normal in a period of 6 to 12 months.

Aim^[21] studied the patellar graft viability by micro angiography and histology showing revascularization at 8 weeks with tissues rich

in collagen and a similar structure to the original ligament at 4-5 months.

In the first months the grafted plasty is in the process of maturation, a fact that has left ACL surgeons reluctant to carry out aggressive rehabilitation in the initial period for fear of plasty failure^[47].

Rougraff in his study of graft biopsies in patellar ligamentoplasties showed tissue obtained in the early postoperative period (3-8 weeks post-op) show no more than 30% tissue necrosis, in contrast to animal studies where the percentage is much higher. Therefore he concluded that postoperative rehabilitation programs proposing an acceleration of physical therapy, not only don't have detrimental outcomes, but if not followed could lead to worse outcomes^[47].

Even patellar tendon studies to evaluate the maturation process that takes place at the donor site show an enhanced maturation process in histological studies in animals in accordance with Sarmiento and the study by our team with ultrasound evaluation^[4,16,17,25].

MRI is the most accurate method of diagnosis for acute anterior cruciate ligament injury^[48]. Howell^[24] illustrates how different grades in maturation stages can be assessed using MRI. The system differentiates four levels based on the signal provided by different regions of the graft. These 5 categories could better show the different stages of ligament maturation.

From the clinical point of view the published studies present conflicting results. On one hand studies like that by Orrego showed greater maturation for the patellar graft assessed by MRI at 6 months without an increased tibial tunnel diameter^[10]. Studies like that by Magnussen^[49] with two years clinical evaluation or that by Nin^[50] show no significant differences with the application of plasma rich in growth factors in ligament grafts. The results obtained with the assessment carried out at one year post surgery are concurrent with those obtained in our study showing equal numbers of completely mature ligaments in both groups with no differences between the two groups. The main difference between the author's study and previous studies is that the authors assessed the grade of maturity at earlier intervals, noting that although the two groups (PRP and control) reach maturity at one and two years at similar rates, the speed at which they do so is different.

In 2010 Radice published graft maturation rates, assessed by MRI, which showed figures 48% faster for grafts treated with growth factors with respect to the speed of maturity^[11]. Sanchez for his part showed how the use of PRGF also accelerated the maturation process in hamstring grafts^[12]. De Almeida showed that PRP had a positive effect on patellar tendon harvest site healing on MRI after 6 months and also reduced pain in the immediate postoperative period^[15].

The studies performed by our group show enhanced maturation speed in both the donor site and the graft around 4 to 6 months. The results at one year show that there are no differences between the two groups, and maturation is observed to be complete in both groups^[4,13]. These results are similar to those previously referenced by Magnussen and Nin, wherein no significant differences were found at one and two years follow-up^[49,50].

Some limitations must be taken into consideration when reviewing the current manuscript. Ours is a single-center study with a limited number of patients. Furthermore, evaluation was performed with a non-validated ultrasonographic evaluation scale; however, no other evaluating scales are available nowadays. Further multi-center clinical trials should be carried out.

CONCLUSION

Both the current work and those reviewed insist that the role PRGF

plays in the maturation process of ligaments takes place in the early stages. Therefore, the changes that may be proposed at a clinical level should be based on these biological findings.

The next lines of research will be speeding up the rehabilitation process and evaluating the biochemical and histological structural components of neoligaments, assessing the similarity to normal ligaments.

ACKNOWLEDGMENTS

The authors gratefully acknowledge Mr. Thomas Michael Oxlee in the preparation and translation of this work.

CONFLICT OF INTERESTS

There are no conflicts of interest with regard to the present study.

REFERENCES

- Griffin LY, Agel J, Albohm MJ, Arendt EA, Dick RW, Garrett WE, Garrick JG, Hewett TE, Huston L, Ireland ML, Johnson RJ, Kibler WB, Lephart S, Lewis JL, Lindenfeld TN, Mandelbaum BR, Marchak P, Teitz CC, Wojtys EM. Noncontact anterior cruciate ligament injuries: risk factors and prevention strategies. *J Am Acad Orthop Surg* 2000 May-Jun; **8(3)**: 141-50
- Cimino F, Volk BS, Setter D. Anterior cruciate ligament injury: diagnosis, management and prevention. *Am Fam Physician* 2010 Oct 15; **82(8)**: 917-22
- Insall JN, Scott WN. Surgery of the knee, 3rd ed.. Philadelphia, USA, 2007; 600-650
- Seijas R, Rius M, Ares O, García-Ballebó M, Serra I, Cugat R. Healing of donor site in bone-tendon-bone ACL reconstruction accelerated with plasma rich in growth factors: a randomized clinical trial. *Knee Surg Sports Traumatol Arthrosc* 2013 Nov 27
- Taylor DW, Petretera M, Hendry M, Theodoropoulos JS. A systematic review of the use of platelet-rich plasma in sports medicine as a new treatment for tendon and ligament injuries. *Clin J Sport Med* 2011 Jul; **21(4)**: 344-352
- Beaufils P, Gaudot F, Drain O, Boisrenoult P, Pujol N. Mini-invasive technique for bone patellar tendon bone harvesting: its superiority in reducing anterior knee pain following ACL reconstruction. *Curr Rev Musculoskelet Med* 2011; **4(2)**: 45-51
- Magnussen RA, Carey JL, Spindler KP. Does autograft choice determine intermediate-term outcome of ACL reconstruction? *Knee Surg Sports Traumatol Arthrosc* 2011 Mar; **19(3)**: 462-72
- Noyes FR, Butler DL, Grood ES. Biomechanical analysis of human ligament grafts used in knee-ligament repairs and reconstructions. *J Bone Joint Surg Am* 1984; **66(3)**: 344-352
- Foster TE, Puskas BL, Mandelbaum BR, Gerhardt MB, Rodeo SA. Platelet-Rich Plasma. From Basic Science to Clinical Applications. *Am J Sports Med* 2009; **37**: 2259-2272
- Orrego M, Larrain C, Rosales J, Valenzuela L, Matas J, Durruty J, Sudy H, Mardones R. Effects of platelet concentrate and bone plug on the healing of hamstring tendons in bone tunnel. *Arthroscopy* 2008; **24**: 1373-1380.
- Radice F, Yáñez R, Gutiérrez V, Rosales J, Pinedo M, Coda S. Comparison of magnetic resonance imaging findings in anterior cruciate ligament grafts with and without autologous platelet-derived growth factors. *Arthroscopy* 2010 Jan; **26(1)**: 50-57
- Sánchez M, Anitua E, Azofra J, Prado R, Muruzabal F, Andia I. Ligamentization of tendon grafts treated with an endogenous preparation rich in growth factors: gross morphology and histology. *Arthroscopy* 2010 Apr; **26(4)**: 470-480
- Seijas R, Ares O, Catala J, Alvarez-Diaz P, Cusco X, Cugat R. Magnetic resonance imaging evaluation of patellar tendon graft remodelling after anterior cruciate ligament reconstruction with or without platelet-rich plasma. *J Orthop Surg (Hong Kong)* 2013 Apr; **21(1)**: 10-14
- Cervellin M, de Girolamo L, Bait C, Denti M, Volpi P. Autologous platelet-rich plasma gel to reduce donor-site morbidity after patellar tendon graft harvesting for anterior cruciate ligament reconstruction: a randomized, controlled clinical study. *Knee Surg Sports Traumatol Arthrosc* 2012 Jan; **20(1)**: 114-120
- De Almeida AM, Demange MK, Sobrado MF, Rodrigues MB, Pedrinelli A, Hernandez AJ. Patellar tendon healing with platelet-rich plasma: a prospective randomized controlled trial. *Am J Sports Med* 2012 Jun; **40(6)**: 1282-1288
- Lyras DN, Kazakos K, Verettas D, Botaitis S, Agrogiannis G, Kokka A, Pitiakoudis M, Kotzakarlis A. The effect of platelet-rich plasma gel in the early phase of patellar tendon healing. *Arch Orthop Trauma Surg* 2009; **129(11)**: 1577-1582
- Lyras DN, Kazakos K, Verettas D, Chronopoulos E, Folaranmi S, Agrogiannis G. Effect of combined administration of transforming growth factor- β 1 and insulin-like growth factor I on the mechanical properties of a patellar tendon defect model in rabbits. *Acta Orthop Belg* 2010; **76(3)**: 380-386
- Kondo EI, Yasuda K, Yamanaka M, Minami A, Tohyama H. Effects of administration of exogenous growth factors on biomechanical properties of the elongation-type anterior cruciate ligament injury with partial laceration. *Am J Sports Med* 2005; **33**: 188-196
- Randelli PS, Arrigoni P, Cabitza P, Volpi P, Maffulli N. Autologous platelet rich plasma for arthroscopic rotator cuff repair: a pilot study. *Disabil Rehabil* 2008; 1-6
- Sánchez M, Anitua E, Azofra J, Andía I, Padilla S, Mujika I. Comparison of surgically repaired achilles tendon tears using platelet-rich fibrin matrices. *Am J Sports Med* 2007; **35**: 245-251
- Aim A, Liljedahl SO, Stromberg B. Clinical and experimental experience in the reconstruction of the anterior cruciate ligament. *Orthop Clin North Am* 1979; **7**: 181-189
- Falconiero RP, DiStefano VJ, Cook TM. Revascularization and ligamentization of autogenous anterior cruciate ligament grafts in humans. *Arthroscopy* 1998; **14**: 197-205
- Weiler A, Förster C, Hunt P, Falk R, Jung T, Unterhauser FN, Bergmann V, Schmidmaier G, Haas NP. The influence of locally applied platelet-derived growth factor-BB on free tendon graft remodeling after anterior cruciate ligament reconstruction. *Am J Sports Med* 2004; **32**: 881-891
- Howell SM, Clark JA, Blasler RD. Serial magnetic resonance imaging of hamstring anterior cruciate ligament autografts during the first year of implantation. *Am J Sports Med* 1991; **19**: 42-47
- Fernández-Sarmiento JA, Domínguez JM, Granados MM, Morgaz J, Navarrete R, Carrillo JM, Gómez-Villamandos RJ, Muñoz-Rascón P, Martín de Las Mulas J, Millán Y, García-Ballebó M, Cugat R. Histological study of the influence of plasma rich in growth factors (ORGF) on the healing of divided Achilles tendons in sheep. *J Bone Joint Surg Am* 2013; **95(3)**: 246-255
- Arnoczky SP, Tarvin GB. Anterior cruciate ligament replacement using patellar tendon: An evaluation of graft revascularization in the dog. *J Bone Joint Surg Am* 1982; **64**: 217-224
- Braun HJ, Wasterlain AS, Dragoo JL. The use of PRP in ligament and meniscal healing. *Sports Med Arthrosc* 2013 Dec; **21(4)**: 206-212
- Bennett NT, Schultz GS. Growth factors and wound healing: biochemical properties of growth factors and their receptors. *Am J Surg* 1993 Jun; **165(6)**: 728-737
- Bennett NT, Schultz GS. Growth factors and wound healing: Part II. Role in normal and chronic wound healing. *Am J Surg* 1993 Jul; **166(1)**: 74-81
- Anitua E, Andia I, Ardanza B, Nurden P, Nurden AT. Autologous platelets as a source of proteins for healing and tissue regeneration. *Thromb Haemost* 2004 Jan; **91(1)**: 4-15
- Anitua E, Sanchez M, Orivea G, Andía I. The potential impact of

- the preparation rich in growth factors (PRGF) in different medical fields. *Biomaterials* 2007; **28**: 4551-4560.
- 32 Lopez-Vidriero E, Goulding KA, Simon DA, Sanchez M, Johnson DH. The use of plateletrich plasma in arthroscopy and sports medicine: optimizing the healing environment. *Arthroscopy*. 2010 Feb; **26**(2): 269-278
 - 33 Wang-Saegusa A1, Cugat R, Ares O, Seijas R, Cuscó X, Garcia-Balletbó M. Infiltration of plasma rich in growth factors for osteoarthritis of the knee short-term effects on function and quality of life. *Arch Orthop Trauma Surg* 2011 Mar; **131**(3): 311-317
 - 34 Xie X, Wu H, Zhao S, Xie G, Huangfu X, Zhao J (2013) The effect of platelet-rich plasma on patterns of gene expression in a dog model of anterior cruciate ligament reconstruction. *J Surg Res* **180**(1): 80-88
 - 35 Vega JA, García-Suárez O, Martínez Almagro A. Cartilago articular y factores de crecimiento (primera parte). *Mapfre Medicina* 2000; **11**: 212-225
 - 36 Stone DK. Receptors: structure and function. *Am J Med* 1998; **105** (3): 244-50
 - 37 Reed GL, Fitzgerald ML, Polgár J. Molecular mechanisms of platelet exocytosis: insights into the “secrete” life of thrombocytes. *Blood* 2000 Nov 15; **96**(10): 3334-3342
 - 38 Weibrich G, Kleis WK. Curasan PRP kit vs PCCS PRP system: collection efficiency and platelets counts of two different methods for the preparation of platelet rich plasma. *Clin Oral Implants* 2002; **13**: 437-443
 - 39 de Mos M, van der Windt AE, Jahr H, van Schie HT, Weinans H, Verhaar JA, van Osch GJ. Can platelet-rich plasma enhance tendon repair? A cell culture study. *Am J Sports Med* 2008; **36**: 1171-1178
 - 40 Kajikawa Y1, Morihara T, Sakamoto H, Matsuda K, Oshima Y, Yoshida A, Nagae M, Arai Y, Kawata M, Kubo T. Platelet-rich plasma enhances the initial mobilization of circulation-derived cells for tendon healing. *J Cell Physiol* 2008; **215**: 837-845
 - 41 Yasuda K, Tomita F, Yamazaki S, Minami A, Tohyama H (2004) The effect of growth factors on biomechanical properties of the bone–patellar tendon–bone graft after anterior cruciate ligament reconstruction: A canine model study. *Am J Sports Med* **32**: 870-880
 - 42 Anderson K, Seneviratne AM, Izawa K, Atkinson BL, Potter HG, Rodeo SA. Augmentation of tendon healing in an intraarticular bone tunnel with use of a bone growth factor. *Am J Sports Med* 2001; **29**: 689-698
 - 43 Anitua E, Sanchez M, Nurden AT, Zalduendo M, de la Fuente M, Orive G, Azofra J, Andia I. Autologous fibrin matrices: a potential source of biological mediators that modulate tendon cell activities. *J Biomed Mater Res A* 2006; **77**(2): 285-293
 - 44 Aspenberg P, Virchenko O. Platelet concentrate injection improves Achilles tendon repair in rats. *Acta Orthop Scand* 2004; **75**: 93-99
 - 45 Schnabel LV, Mohammed HO, Miller BJ, McDermott WG, Jacobson MS, Santangelo KS, Fortier LA. Platelet rich plasma (PRP) enhances anabolic gene expression patterns in flexor digitorum superficialis tendons. *J Orthop Res* 2007; **25**(2): 230-240
 - 46 Kovacevic D, Rodeo SA. Biological augmentation of rotator cuff tendon repair. *Clin Orthop* 2008; **466**: 622-33
 - 47 Rougraff BT, Shelbourne KD. Early histologic appearance of human patellar tendon autografts used for anterior cruciate ligament reconstruction. *Knee Surg Sports Traumatol Arthrosc* 1999; **7**: 9-14
 - 48 Grøntvedt T, Engebretsen L, Rossvoll I, Smevik O, Nilsen G. Comparison between magnetic resonance imaging findings and knee stability: Measurements after anterior cruciate ligament repair with and without augmentation. A five- to seven year follow-up of 52 patients. *Am J Sports Med* 1996; **23**: 729-735
 - 49 Magnussen RA, Flanigan DC, Pedroza AD, Heinlein KA, Kaeding CC. Platelet rich plasma use in allograft ACL reconstructions: two-year clinical results of a MOON cohort study. *Knee* 2013 Aug; **20**(4): 277-80
 - 50 Nin JR, Gasque GM, Azcárate AV, Beola JD, Gonzalez MH. Has platelet-rich plasma any role in anterior cruciate ligament allograft healing? *Arthroscopy* 2009 Nov; **25**(11): 1206-1213
- Peer reviewers:** Pauline Po Yee LUI, Senior Executive (Scientific Review), Research Office, Strategy & Planning Division, Headquarter, Hospital Authority, Hong Kong, Chian; Joao Pedro Oliveira, Urb. Quinta do Cedro, Lt 8, 3000-038 Coimbra, Portugal.