

Utility of Pain Mapping in Shoulder Disorders

Sudhir Singh, Farid Mohammad, Sumit Gill, Dharmendra Kumar, Sanjiv Kumar

Sudhir Singh, Farid Mohammad, Sumit Gill, Sanjiv Kumar,
Department of Orthopaedics, Era Medical College, Lucknow, U.p.,
India

Dharmendra Kumar, Department of Orthopaedics, King George'S
Medical University Lucknow, India

Correspondence to: Sudhir Singh, Professor & Head, Depart-
ment of Orthopaedics, Era Medical College, Sarfarazganj, Hardoi
road, Lucknow, U.p., India.

Email: susi59@live.in

Telephone: +91-8799544905

Received: February 28, 2015

Revised: March 23, 2015

Accepted: March 28, 2015

Published online: June 23, 2015

ABSTRACT

BACKGROUND: The most common causes of shoulder pain are rotator cuff disorder, acromioclavicular joint disorder and glenohumeral joint disorder. Use of pain map for specific disorder has been described for back and hip pain. We conducted a study to assess the utility of pain maps in shoulder pathologies.

AIMS: The aim of present study was to evaluate the utility of shoulder pain mapping as a diagnostic tool in common shoulder disorders.

MATERIAL AND METHODS: This is a prospective hospital based cross-sectional study. One hundred and thirty patients with non-traumatic shoulder pain, swelling or stiffness of more than 3 months were studied. Clinical diagnosis was made by first investigator who was blinded for the results of pain maps done by the second investigator. Pain distribution, severity and type of pain were recorded by the patients on a pain diagram. Pain severity, type and distribution of pain in a particular disorder were then correlated with the clinical diagnosis.

RESULTS: The mean age of the patients was 51.36+11.86 years (range: 23-69 years). A predominance of females was observed. The commonest cause of shoulder pain was Periarthritis (adhesive capsulitis) (43.1%) followed by SA impingement (13.8%), rotator

cuff disorders (13.1%), GH arthritis (10.0%), AC arthritis (8.5%) and miscellaneous causes (myalgia and unclear diagnosis). Maximum pain score was found for glenohumeral arthritis (8.46+0.52) followed by acute rotator cuff injury (8.41+0.51) and minimum pain score was for AC arthritis (6.0+0.00). Pain maps were relatively more accurate in cases of AC arthritis, rotator cuff disorder and periarthritis but were not able to differentiate between cases of GH arthritis and SA impingement.

CONCLUSIONS: Pain mapping of shoulder disorders is accurate in cases of AC Arthritis, rotator cuff disorder and periarthritis but is not helpful in cases of GH arthritis and SA impingement. It can be used as an additional tool but with caution as the parameter of "pain type" is dependent on patient's educational status.

© 2015 ACT. All rights reserved.

Key words: Pain mapping; Periarthritis; Glenohumeral arthritis; Subacromial arthritis

Singh S, Mohammad F, Gill S, Kumar D, Kumar S. Utility of Pain Mapping in Shoulder Disorders. *International Journal of Orthopaedics* 2015; 2(3): 323-327 Available from: URL: <http://www.ghrnet.org/index.php/ijo/article/view/1078>

INTRODUCTION

In literature, the common causes of shoulder pain are reported to be rotator cuff disorder, acromioclavicular (AC) joint disorder and glenohumeral (GH) joint disorder^[1-3]. However, inconsistent diagnostic terminology^[4], lack of universally accepted diagnostic classification criteria^[5] and poor specificity of many physical examination tests^[6,7] hamper confidence in classification systems that use clinical test criteria alone. We do have diagnostic methods like arthroscopy and MRI for diagnosis of shoulder disorders but either they are invasive or costly. One of the clinical characteristic through which shoulder problem can successfully be diagnosed is - Pain^[8]. The intensity, location, type and duration of pain might help

to diagnose the disease. Use of pain map for specific disorder has been described for back and hip pain. In recent years, some attempts have been made to come up with some systematic methodology to understand these patterns in order to understand the etiology, chronicity and severity of shoulder pain^[8,9]. No study has specifically reported distribution and type of pain in common shoulder disorders. Hence, we conducted a study to assess the pain pattern and their role as an additional diagnostic tool in common shoulder pathologies.

Aims and objectives: The aim of present study is to evaluate the utility of shoulder mapping as a diagnostic tool in common shoulder disorders.

MATERIALS AND METHODS

Study Design and Patient Selection

This is a prospective hospital based cross-sectional study carried in department of Orthopedics of a tertiary care hospital catering suburban and rural population of Lucknow. The study was done after clearance and approval from the Institutional Ethical Committee. An informed and written consent was obtained from all the subjects. Patients presenting with pain, swelling or stiffness with no history of trauma to shoulder in preceding three months were included. Patients with cervical pain with or without radiculopathy, previous surgical intervention to shoulder joint, history of infection in or around shoulder joint, shoulder problems secondary to vascular, neurological and systemic conditions and any other pathology with pain radiating to shoulder region of ipsilateral limb were excluded from the study.

After recording of demographic information, a detailed history and clinical examination was done including specific shoulder tests (Jobe apprehension relocation test, Hawkins-Kennedy impingement test, Gerber lift-off test, Jobe test, Internal rotation resistance stress test, Gerber subcoracoid impingement test, Speed test, Yergason sign, Belly press test, External rotation stress test, External rotation lag sign, Drop sign, Internal rotation lag sign, Inferior sulcus test, Callaway test, Hamilton ruler test, Duga test, Bryant sign) wherever needed by first investigator. Pain characteristics like: duration, location, intensity and type of pain were recorded. Intensity of pain was recorded on a ten point visual analogue scale (VAS). First investigator was blinded for the results of pain mapping.

Pain mapping

Distribution and type of pain was recorded on a printed diagrams given to the patients similar as in earlier study⁹ (Figure 1). The pain diagram showed both anterior and posterior aspect of the arm, neck and shoulder including axilla. Both anterior and posterior view diagram of the limb was divided into 14 cells each making a total of 28 cells. Method of marking on the pain diagram was explained by the second investigator and patients were then asked to draw and shade in the area of their pain on the pain diagram in presence of second investigator. Patients were asked to draw the area where they had pain and also to indicate by alphabets in the shaded area which of the three types of pain they felt as “S” for sharp, stabbing, or shooting pain, as “B” for burning pain and as “D” for dull aching type of pain. The second investigator was blinded for the results clinical examination results and the final diagnosis.

After clinical examination and pain mapping, investigations like radiography, ultrasonography (USG), computed tomography (CT) and/or magnetic resonance imaging (MRI) was done, wherever indicated to confirm the diagnosis. Arthrography, arthroscopy and local diagnostic injections were performed by first investigator if required. Final diagnosis was made by first investigator after

correlation with results of all tests but not with results of pain maps. Pain severity, type and distribution of pain in a particular disorder were then correlated with the clinical diagnosis. The data was analyzed by SPSS software (version 16.0).

RESULTS

All patients attending the orthopaedics department within two year period with shoulder pain were included in the study. A total of 783 patients attended our orthopaedics outpatients department with neck and upper back pain radiating to shoulder and shoulder pain of more than 3 months duration. Of all these patients 296 had signs and symptoms pertaining to cervical pathology (cervical disc disease and cervical spondylosis), and 357 patients had fibromyalgia/fibrositis of upper back and scapular region with pain radiating to shoulder and hence excluded from the study. Remaining 130 patients who had only shoulder pain were included in the study. Age of patients ranged between 23-69 years (51.36 ± 11.86 years). A predominance of females was observed (Male: Female ratio - 0.81:1. (Table 1)

Rotator cuff disorder patients were youngest (28.3 years) followed by miscellaneous group (myalgia and unclear diagnosis) which had a mean age 42.8 years. Subacromial (SA) impingement (49.4 years), GH arthritis (51.2 years), Periarthritis (adhesive capsulitis) (51.4 years) and AC arthritis (52.7 years) all had similar age group.

The commonest cause of shoulder pain was Periarthritis (adhesive capsulitis) (43.1%) followed by SA impingement (13.8%), rotator cuff disorders (13.1%), GH arthritis (10.0%), AC arthritis (8.5%) and miscellaneous causes (myalgia and unclear diagnosis) (11.5%) (Table1). Gender and age wise distribution of patients is shown in table 1 and table 2.

The location of pain was mapped and the area of distribution of pain is shown in figure 2. Intensity of pain was measured by VAS score independently. Highest pain score was reported by glenohumeral arthritis (8.46 ± 0.52) and rotator cuff disorder (8.41 ± 0.51) patients and lowest pain score was reported by AC arthritis (VAS: 6.42 ± 0.21) patients (Table 3).

The type of pain recorded by patient in specific disorder is given in table 3 and figure 2. No patient reported “pins & needles” type of pain. Pain maps drawn by patients having AC arthritis was distinct in having smallest area of distribution (3-4 cells) with mild severity

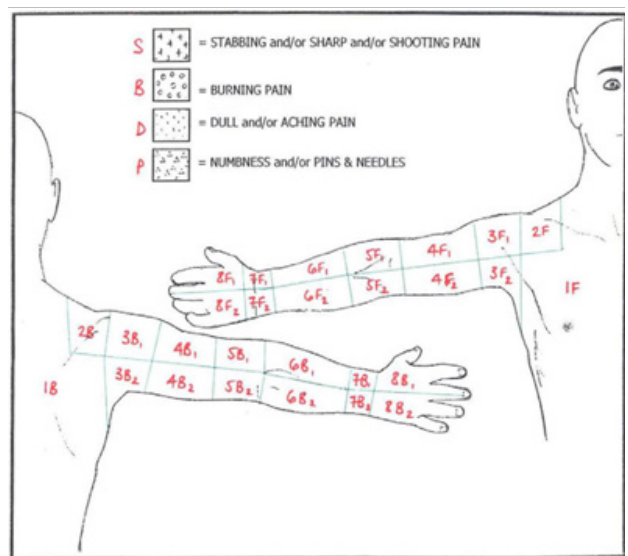


Figure 1 Legend Showing distribution of pain cells over front and back of upper limb.

Table 1 Clinical diagnosis, mean age, and gender of study patients.

DIAGNOSES	Patients (n = 130)	Females (n = 72)	Males (n = 58)	Mean Age (years)	Male Vs Female X ²	p
Periarthritis (adhesive capsulitis)	56 (43.1%)	35 (48.61%)	21(36.20%)	51.4	2.016	0.156
Subacromial Impingement	18 (13.8%)	08 (11.11%)	10 (17.24%)	49.4	1.012	0.314
Rotator Cuff disorder	17 (13.1%)	01(01.38%)	16 (27.58%)	28.3	19.395	<0.001
Glenohumeral Arthritis	13 (10.0%)	08 (11.11%)	05 (08.62%)	51.2	0.221	0.638
Acromioclavicular Arthritis	11 (08.5%)	10 (13.88%)	01 (01.72%)	52.7	6.137	0.013
Miscellaneous group	15 (11.5%)	10 (13.88%)	05 (08.62%)	42.8	0.873	0.350

Table 2 Association of diagnosis with age.

Age group (years)	Periarthritis n (%)	SA impingement n (%)	Rotator Cuff Injury n (%)	GH arthritis n (%)	AC arthritis n (%)	Misc. n (%)	
21 - 30	-	-	13 (76.47)	-	-	03(20.00)	
31 - 40	03(5.36)	03 (16.67)	04 (23.53)	01 (07.69)	-	02(13.33)	
41 - 50	35 (62.50)	07 (38.89)	-	03 (23.08)	04 (36.36)	06(40.00)	
51 - 60	10 (17.86)	06 (33.33)	-	06 (46.15)	06 (54.55)	04 (26.67)	
>60	08 (14.29)	02 (11.11)	-	03 (23.08)	01 (09.09)	-	
Age > 50	18 (32.14)	08 (44.44)	(0)	09 (69.23)	07 (63.63)	06(40.00)	
Age <50 Vs >50	X ² p	0.452 0.501	0.750 0.386	10.71 0.001	7.237 0.007	4.195 0.041	0.564 0.453

Table 3 Pain type, severity and radiation area on anterior and posterior aspect of the limb.

Diagnosis	VAS (mean)	No. of Cells involved	Cases	Predominant pain type								
				Shoulder & Upper arm			Distal arm			Forearm		
				S	B	D	S	B	D	S	B	D
Periarthritis	6.95(0.44)	5-6	56	13	8	35	13	-	20	-	-	-
SA impingement	7.72(0.46)	7-8	18	13	1	5	-	-	-	-	-	-
Rotator cuff disorder	8.41(0.51)	6-7	17	5	13	-	-	9	-	-	-	-
GH arthritis	8.46(0.52)	11-12	13	9	3	4	6	-	7	-	-	10
AC arthritis	6.42(0.21)	3-4	11	11	-	-	0	-	-	-	-	-
Miscellaneous group	6.60(0.51)	5	15	3	2	10	1	-	1	-	-	-

S: Sharp, Stabbing, or Shooting pain, B: Burning pain, D: Dull aching pain.

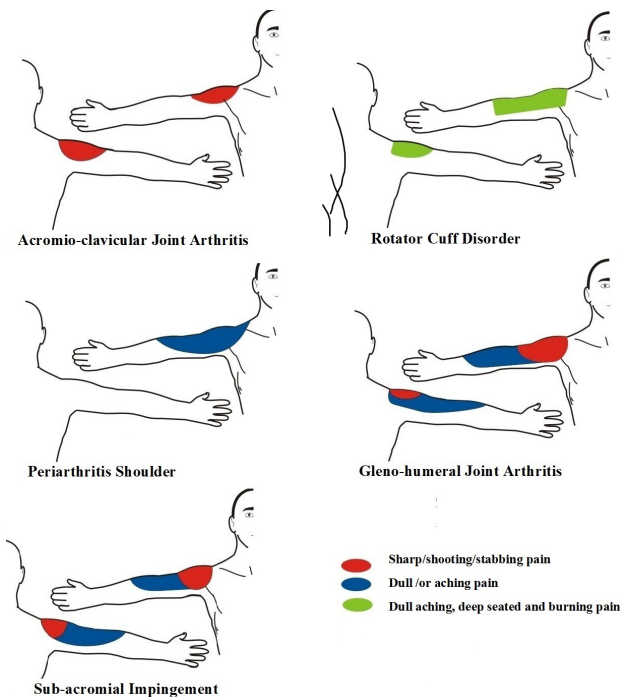


Figure 2 Showing location and type of pain in various disorders.

(VAS: 6.42±0.21). GH arthritis patients reported the largest area of pain distribution (11-12 cells) which extended beyond elbow joint while rotator cuff disorder patients reported area of pain distribution in much smaller area (6-7 cells) though had similar pain severity (VAS: 8.41±0.51). Periarthritis, SA impingement and rotator cuff disorder

patients had more or less similar area of pain distribution but the pain was dull and deep aching type with greater intensity in rotator cuff disorder and a mixture of sharp shooting pain and dull aching type pain in SA impingement.

DISCUSSION

The medical literature describes pain maps for neck, face, back, and hip pain^[10-12], but not for shoulder disorders. There is only one study reporting the use of shoulder pain maps^[9]. A definitive pattern of pain distribution and specific types of pain in common shoulder pathologies has been demonstrated. Detailed online search did not reveal any such study done and reported from India. Our data is the first such report from India. We undertook this study to assess the utility of shoulder pain mapping in diagnosis of common shoulder disorders.

The correlation of site of pain perceived by the patient and the organ where the pain originates is of utmost importance in making a diagnosis but is not always precisely deciphered. The classical teaching is that pain arising near the skin is mostly localized precisely, but the pain arising from the deeper structures is more diffuse and may have an unusual distribution^[13,14]. The explanation for this unusual pain distribution is the extensive convergence of afferent signals from this area to the dorsal horn of the spinal cord. In shoulder disorders pain sensations are usually distributed over deltoid, the trapezius (upper part) and the over suprascapular area. Location of pain sensation may or may not correspond to proximity of pain generator^[15].

There are many types of self-reported pain scales: (1) the VAS, (2) the Verbal rating scale, (3) the numerical rating scale, (4) the pain drawings. Each method has its advantages and disadvantages^[16]. The

VAS and the numerical rating scale create ratio-level data that are more easily comparable. In our study, we used VAS to compare pain severity.

The pain from rotator cuff disorder and periarthritis (adhesive capsulitis) was located on the front, back and lateral aspect of shoulder and arm extending distally up to elbow involving 6-7 cells. The pain was dull and deep seated but the distinguishing feature was the severity of pain which was much more in rotator cuff disorder (VAS: 8.41) than periarthritis (VAS: 6.95). Pain severity and area where pain was felt in cases of rotator cuff disorders were slightly more in our series than reported by other author (VAS: 7.05, area: 5.60 cells)^[9].

Pain mapping of SA impingement showed predominantly sharp/shooting pain over the front, back and lateral aspect of the shoulder and dull aching pain over anterolateral and posterolateral aspect of the arm. This again correlates with the results reported by other author^[9,17]. The pain in GH arthritis was again sharp shooting type over shoulder, anterolateral and posterolateral aspect of arm and dull aching type up to mid forearm. The extension of pain in forearm (11-12 cells) and severity of pain (VAS: 8.46) was the differentiating feature with SA disorder pathology.

AC joint involvement resulted pain over the joint, deep in the supraspinatus fossa, and in the upper trapezius. The pain was mainly the sharp stabbing type involving less number of cells (3-4 cells) and showed lesser pain intensity (VAS: 6.42). This corroborates with the findings of other authors^[9,17].

The most severe pain was reported by GH arthritis patients (VAS: 8.46, area: 11-12 cells) followed by rotator cuff disorders (VAS: 8.41, area: 6-7 cells), SA impingement (VAS: 7.72, area: 7-8 cells) and periarthritis (VAS: 6.95, area: 6 cells). GH arthritis can be distinguished with rotator cuff disorders by larger area of pain distribution as reported by Bayam *et al* earlier^[9]. SA impingement is characterized by sharp shooting pain. Pain from AC pathology was the least severe and most pinpointed (VAS: 6.42, area: 3-4 cells) on pain map as was also reported by Bayam *et al*^[9].

Our study has shown that pain maps, in terms of area of distribution and pain type, are more accurately reported by patients of AC arthritis, rotator cuff arthritis and periarthritis shoulder. This may be because the pain of only one type has been experienced by most of the patients. In AC arthritis all 11 patients reported same pain type. But patients of GH arthritis and SA impingement groups reported a mix of two types of pain (dull aching in distal half of arm and sharp/shooting pain in deltoid area proximally). Hence, it is difficult to differentiate between these two pathologies by pain types alone. These two conditions can be still differentiated by the area of distribution as pain is distributed beyond elbow in GH arthritis in majority of cases, while no patient of SA impingement reported pain in forearm.

There are three main elements of a pain mapping on a pain diagram – Type of pain, Area of pain distribution and Pain intensity. Of these pain intensity (VAS score) and area of distribution (number of pain cells involved) are relatively much easier to measure and report by the patient than pain type. This may be because not many persons can label their pain in terms of words like “sharp”, “shooting”, “burning” or “dull” type. Moreover the patient many times uses words of his/her own vernacular language or dialect which does not fit in to any of these pain describing words of English language. Describing pain type in words of English language is heavily dependent on the literacy level of the patient which varies greatly with the western world. In our study we experienced this situation very often and the investigator had to fill in on behalf the patient depending on his

interpretation patient’s description of pain type. Hence, we believe that until we develop a more scientific method of reporting “pain type” the use of pain maps should be used with caution.

Statistical analysis of the differences in various parameters of pain diagram (VAS score, number of cells involved and area of distribution of pain) in different pathologies was not done as the sample size was inadequate.

In making a diagnosis of shoulder disorder pain mapping can be used as an additional tool but it does not show any distinct advantage over traditional thorough clinical examination. GH arthritis and rotator cuff lesions have similar intensity of pain but pain also radiates to forearm in GH arthritis which can be a differentiating feature. AC joint involvement is characterized by localized pain of least severity.

CONCLUSION

Pain mapping can be used as an additional tool to diagnose shoulder disorders but the parameter of “pain type” has a limitation as it depends largely on patient’s educational status. Moreover, multicentric studies with larger sample size are needed to show a definite role of pain maps in routine clinical practice.

CONFLICT OF INTERESTS

There are no conflicts of interest with regard to the present study.

REFERENCES

- 1 Mitchell C, Adebajo A, Hay E, Carr A: Shoulder pain: diagnosis and management in primary care. *Br Med J* 2005, 331:1124-1128.
- 2 Bot SDM, van der Waal JM, Terwee CB, Van der Windt DAWM, Schellevis FG, Bouter LM: Incidence and prevalence of complaints of the neck and upper extremity in general practice. *Ann Rheum Dis* 2005, 64(1):118-123.
- 3 Feleus A, Bierma-Zeinstra SM, Miedema HS, Bernsen RM, Berhaar JA, Koes BW: Incidence of non-traumatic complaints of arm, neck and shoulder in general practice. *Man Ther* 2008, 13: 426-433.
- 4 Schellingerhout JM, Verhagen AP, Thomas S, Koes BW: Lack of uniformity in diagnostic labeling of shoulder pain: time for a different approach. *Man Ther* 2008, 13:478-483.
- 5 Boocock MG, Collier JMK, McNair PJ, Simmonds M, Larmer PJ, Armstrong B. A framework for the classification and diagnosis of work-related upper extremity conditions: systematic review. *Semin Arthritis Rheum* 2009, 38(4): 296-311.
- 6 Hegedus EJ, Goode A, Campbell S, Morin A, Tamaddoni M, Moorman CT, Cook C. Physical examination tests of the shoulder: a systematic review with meta-analysis of individual tests. *Br J Sports Med* 2008; 42: 80-92.
- 7 Hegedus EJ, Goode AP, Cook CE, Michener L, Myer CA, Myer DM, Wright AA. Which physical examination tests provide clinicians with the most value when examining the shoulder? Update of a systematic review with meta-analysis of individual tests. *Br J Sports Med*. 2012 Nov; 46 (14): 964-78.
- 8 Carter T, Hall H, McIntosh G, Murphy J, MacDougall J, Boyle C. Intertester reliability of a classification system for shoulder pain. *Physiotherapy*. 2012 Mar; 98 (1): 40-6.
- 9 Bayam L, Ahmad MA, Naqui SZ, Chouhan AK, Funk L. Pain Mapping for Common Shoulder Disorders. *Am J Orthop*. 2011; 40(7): 353-358.
- 10 Toomingas A. Characteristics of pain drawings in the neck-shoulder region among the working population. *Int Arch Occup Environ Health*. 1999; 72 (2): 98106.
- 11 Machacek P, Friedrich M. Pain patterns of disc lesions of the lum-

- bar spine. *Z Orthop Ihre Grenzgeb.* 2006;144(1):19-26.
- 12 Turp JC, Kowalski CJ, O'Leary N, Stohler CS. Pain maps from facial pain patients indicate a broad pain geography. *J Dent Res.* 1998;77(6):1465-1473
 - 13 Dee R, Hurst LC, Gruber MA, Kottmeier SA. Principles of orthopaedic practice. In: Rodowsky MW, Bigliani LU. *The Shoulder and the Shoulder Girdle.* 2nd ed. New York, NY: McGraw-Hill; 1997:1063.
 - 14 Apley AG, Solomon L. *Apley's System of Orthopaedics and Fractures.* 7th ed. Oxford, England: Butterworth-Heinemann; 1993.
 - 15 Sizer-Phillip S Jr, Phelps V, Gilbert K. Diagnosis and management of the painful shoulder. Part 2: examination, interpretation, and management. *Pain Pract.* 2003;3(2):152-185.
 - 16 Disorbio JM, Bruns D. Diagnosis specific norms for the 0-10 pain scale. Paper presented at: World Congress on Pain; Vienna, Austria; 1999.
 - 17 Gerber C, Galantay RV, Hersche O. The pattern of pain produced by irritation of the acromioclavicular joint and the subacromial space. *J Shoulder Elbow Surg.* 1998;7(4):352-355.

Peer reviewers: Filippo Familiari, The Johns Hopkins University, Department of Orthopaedics, Division of Shoulder Surgery, 10753 Falls Road, Lutherville, 21093, Maryland, USA; Amr Mohamad Abdelhady, Professor Amr Mohamad Abdelhady, Orthopaedic department, Faculty of Medicine, Ain Shams University. Abbasia Square, Cairo Egypt.