

Trochanteric Femoral Fracture Classification: Relevance of the Fracture Line Angle, a Radiological Study

Daphne van Embden, Mark S Gaston, Lucy A Bailey, A Hamish RW Simpson

Daphne van Embden, Mark S Gaston, Lucy A Bailey, A Hamish RW Simpson, Department of Orthopaedics, University of Edinburgh, Royal Infirmary of Edinburgh, Little France, United Kingdom
Daphne van Embden, Department of Surgery, Leiden University Medical Center, Leiden, The Netherlands

Correspondence to: D. van Embden, MD, Leiden University Medical Centre, Albinusdreef 2, 2333 ZA Leiden, Postbus 9600, 2300 RC Leiden, The Netherlands

Email: daphnevanembden@hotmail.com

Telephone: +31-0-715269111

Received: November 21, 2014 Revised: December 24, 2014

Accepted: December 28, 2014

Published online: April 23, 2015

Key words: Hip fracture classification; Trochanteric fractures; Stability; Hip fracture treatment; Patho-anatomy

van Embden D, Gaston MS, Bailey LA, Simpson AHRW. Trochanteric Femoral Fracture Classification: Relevance of the Fracture Line Angle, A Radiological Study. *International Journal of Orthopaedics* 2015; 2(2): 250-255 Available from: URL: <http://www.ghrnet.org/index.php/ijo/article/view/1146>

ABSTRACT

AIM: The aim of this study was to evaluate the trochanteric fracture line in terms of the fracture line angle and anatomical location.

METHODS: The preoperative AP radiographs of 164 randomly selected patients with trochanteric fractures were obtained. Measurements were made of: (1) the angle between the mid-shaft femoral axis and the fracture line, (2) the intersection point of the fracture line with the greater trochanter.

RESULTS: An increase in comminution correlated with an increased fracture line angle. The angle of the fracture line relative to the femoral shaft showed a mean of 43° (SD 10), but a range from 19° to 146°.

DISCUSSION: This study provides information on the fracture line properties of trochanteric fractures and demonstrates a massive range in fracture line inclination and fragment size. Theoretical Engineering modelling studies have indicated that the measurements described in this study will have a major bearing on fracture stability. These findings can be applied to improve classifications for stable and unstable trochanteric fractures.

INTRODUCTION

The trochanteric femoral fracture is still regarded as a major orthopaedic challenge as high rates of failure of fixation occur^[1-4].

To optimise fracture fixation, the fracture pattern needs to be understood^[5]. A number of classification systems have been developed for trochanteric hip fractures. In 1949 Evans described an anatomical classification based on the number of fragments and whether or not the lesser trochanter is split off as a separate fragment^[6]. The AO-classification of Müller is comprehensive but is difficult to apply in detail in the clinical setting^[7]. Currently, no single classification system for trochanteric fractures is unanimously accepted because most show low inter- and intra-observer agreement and are therefore considered unreliable^[8-11]. Moreover, classification of trochanteric fractures is often considered of low clinical relevance because classifying the fracture does not indicate a prognosis or guide treatment, since both stable and unstable fractures are fixated with a sliding hip screw (SHS) or an intramedullary device (IM)^[11]. Studies assessing new implants or comparing existing implant types rarely use fracture classification systems despite their possible value^[12].

Reverse type trochanteric fractures with a reversed oblique fracture line have been shown to be a biomechanically different type of fracture and are for this sub type intramedullary nailing has been recommended^[13]. In addition, clinical studies suggest that the integrity of the lateral wall is a factor in trochanteric fracture stability which indicates that the site where the fracture line breaches the lateral cortex is important^[14]. Therefore, the aim of this study was to

evaluate the variation in anatomy of the trochanteric fracture line, in particular its inclination and the integrity of the lateral wall was assessed.

METHODS

All pre-operative antero-posterior (AP) radiographs of the hip and pelvis and post-operative AP hip radiographs of femoral trochanteric fracture patients treated by SHS at the Royal Infirmary of Edinburgh over a 6 month period were analyzed. The radiographs were not standardized, but the images were obtained in routine clinical practice and therefore the ones available to the treating orthopaedic surgeon.

The radiographs were digitized with a high-resolution flat-bed scanner especially designed to scan radiographs (UMAX™ Powerlook 2100XL)^[15]. The images were imported into Image J™, a Java image processing program, and parameters were recorded by 2 orthopaedic residents and confirmed by two orthopaedic consultants. Each image was corrected for magnification error by recording the barrel width of the SHS on the post-operative image. (Dynamic Hip System, DePuy Synthes, Switzerland) The real width of this was known and was not affected by rotation on the radiographs, as it was a cylinder. The use of known SHS dimensions to correct for magnification has been reported previously^[16]. Magnification was then corrected for the pre-operative image by measuring the smallest femoral neck width on the post-operative radiographs and the smallest femoral neck width on the preoperative radiograph. Any difference in the preoperative film was corrected throughout all measurements made on this image. Data that needed correction for magnification from eight fractures were excluded from analysis because of poor postoperative radiograph quality.

All fractures were classified according to the AO/ASIF classification and Jensen's modification of the Evans classification (Figure 1). Fractures that showed a sub-trochanteric extension (fracture extending distally outside trochanteric area as defined in the AO/ASIF classification)^[7] were excluded.

Measurements of the fractured femur were taken from the pre-operative AP scanned radiograph (Figure 2A and Figure 2B). In particular, the greater trochanter was scrutinized to determine whether the lateral wall was intact and the greater trochanter was measured to assess whether the fracture line was in the proximal, middle or distal one-third of the greater trochanter (Figure 3). If the fracture was displaced or comminuted, the fracture line was ascertained from the proximal end of the distal fragment of the fractured femur. If the height of the greater trochanter was difficult to assess due to it being fractured, its height was estimated from the contra-lateral femur on the pelvic radiograph. The area of the greater and lesser trochanter fragments was measured using a pixilation technique (Image J™).

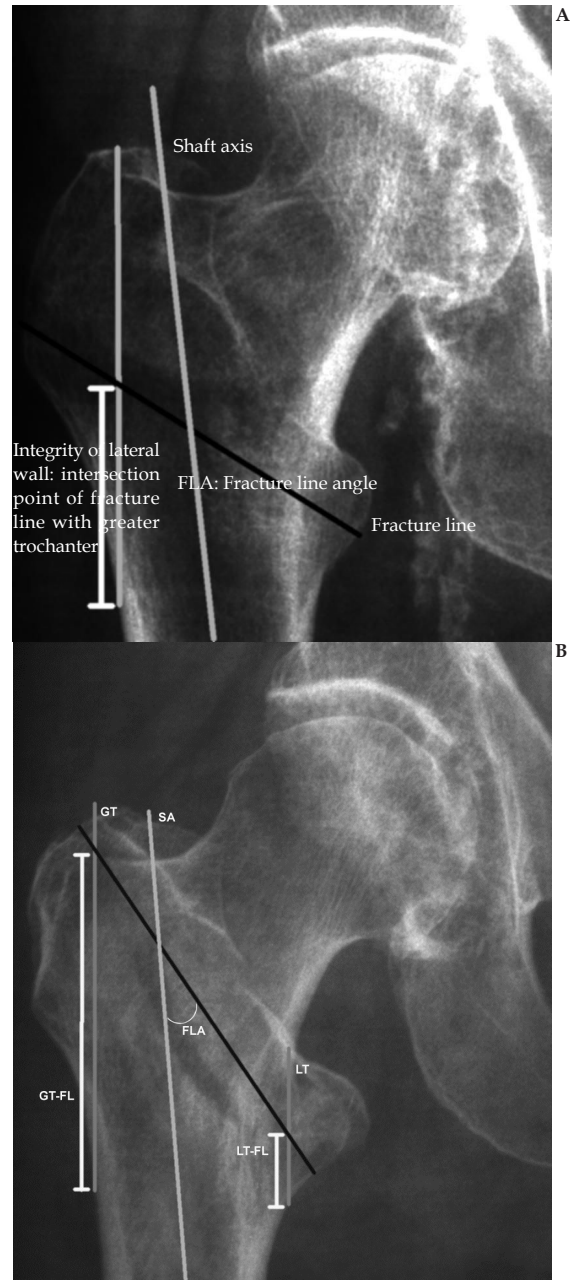


Figure 2 Measurements made using Image J™ on preoperative radiographs. Example of measurements made using Image J™ on preoperative radiographs, Key: FL: fracture line, GT and LT: lines that represent the length of the greater and lesser trochanter, GT-FL length of GT to the point where it intersects with the fracture line (FL), (LT-FL: length of the lesser trochanter line to the point where it intersects with line the fracture line was not included in this study).

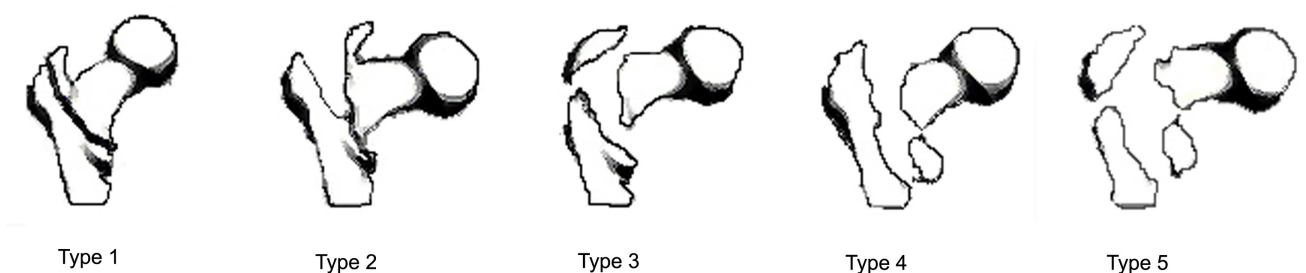


Figure 1 Jensen modification of the Evans classification.

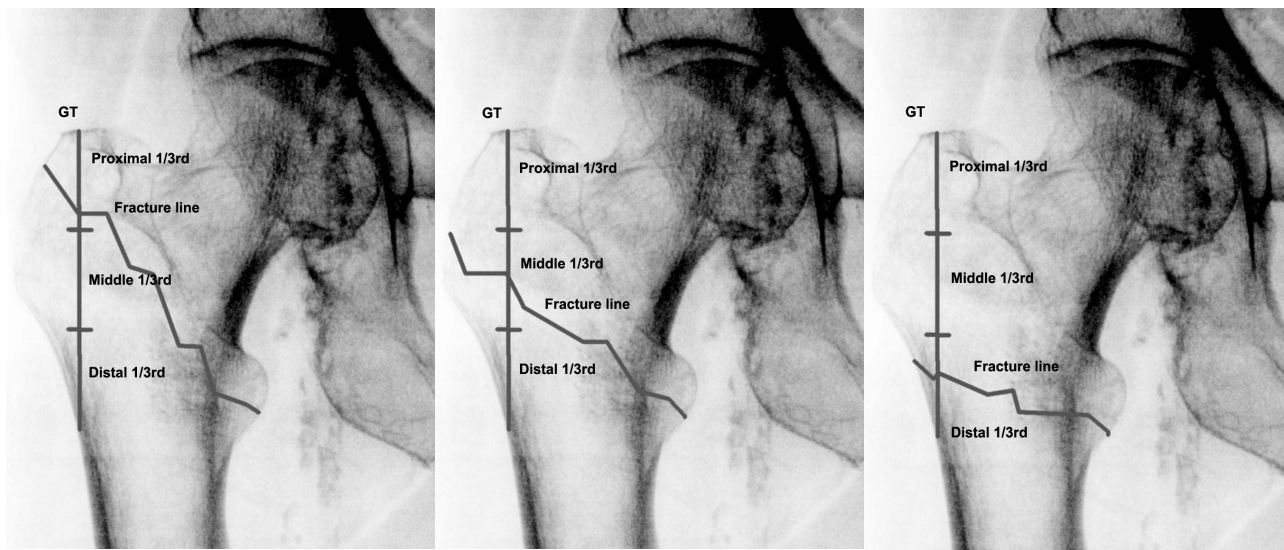


Figure 3 Lateral wall integrity: Fracture line crossing proximal, middle and distal one-third of the greater trochanter.

The AP area of the lesser trochanter fragment was calculated and the percentage of the width of the bone that this fracture fragment extended across the femur (the intrusion distance) was measured.

Accuracy was assessed using repeat measurements ($N=10$), yielding a 3.5 % RSD (relative standard deviation) for the linear measures, 2.2 % RSD for the angular measures and 10.1% for the area measurements.

Data was collected and analysed using statistical computer software SPSS version 14. Statistical significance accepted at $p < 0.05$ (ANOVA).

RESULTS

There were 31 male and 133 female patients. The mean age was 80.5 years (S.D. 12.7). The results of classification according to the Jensen's modification of the Evans' grading and the AO/ASIF are shown in table 1. All patients could be classified with both classification systems (all fractures with subtrochanteric extensions were excluded).

The mean length of the fracture line was 74 mm (S.D. 13).

The angle of the fracture line to the femoral shaft showed a median of 43° and a mean of 45° (S.D. 17°) with an extensive range from 19° to 90° for those of standard obliquity and 105° to 146° for those of reversed obliquity. Figure 4 shows the distribution of angle of the fracture line with the femoral shaft.

Excluding the reversed oblique fractures, the mean angle of the two-part fractures was 41° (S.D. 8°), of three-parts was 43° (S.D. 10°) and of the fractures with four- or more parts 46° (S.D. 13°). The distribution for simple 2-part fracture is compared to comminuted fractures with three-parts of more in Figure 5. An increase in comminution correlated with an increased fracture line angle ($p=0.048$, ANOVA).

The fracture line angle is presented according to the AO/ASIF classification in figure 6.

In the 156 fractures that could be analyzed (8 excluded due to poor post-operative X-ray image quality), 63 fractures (40%) had an intact lateral wall, i.e. the fracture line intersected the proximal third of the greater trochanter ($N=61$) or passed proximal to the greater trochanter ($N=2$). These included 29 two-part and 34 three-part or more part fractures.

Table 1 Jensen's modification of the Evans grading and the AO/ASIF classification.

Jensen's modification	Count
Type 1: Two part undisplaced	15 (9%)
Type 2: Two part displaced	46 (28%)
Type 3: Three part, loss of posterolateral support	21 (13%)
Type 4: Three part, loss of medial support	38 (23%)
Type 5: Four part	44 (27%)
Total	164

AO classification	Count
AO31-1.1: Fractures along intretrochanteric line	14 (9%)
AO31-1.2: Fractures through greater trochanter	40 (24%)
AO31-1.3: Fractures below lesser trochanter	9 (6%)
AO31-2.1: One intermediate fragment (lesser trochanter)	21 (13%)
AO31-2.2: Intermediate fragments	37 (23%)
AO31-2.3: More than 2 intermediate fragments	38 (23%)
AO31-3.1: Simple, oblique	0 (0%)
AO31-3.2: Simple, transverse	0 (0%)
AO31-3.3: Reversed oblique, with medial fragment	5 (3%)
Total	164

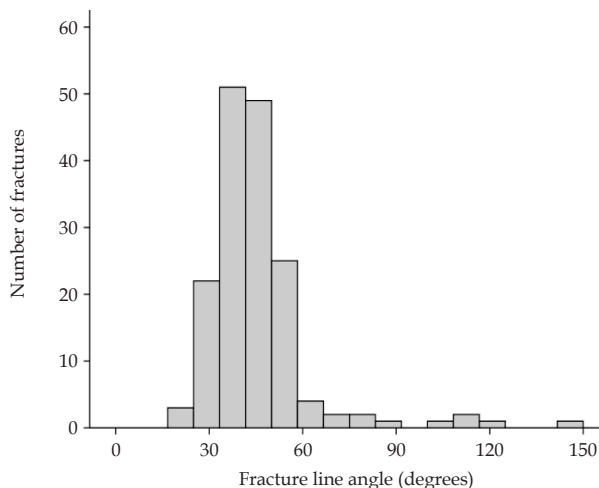


Figure 4 Frequency plot for the fracture line angle.

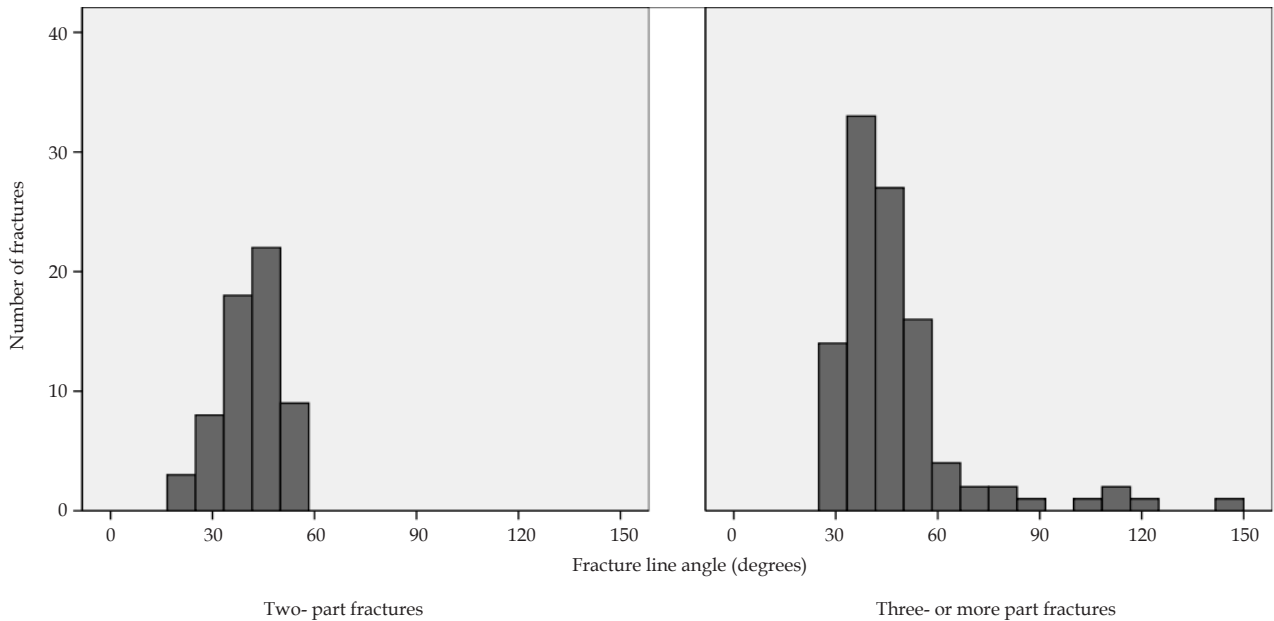


Figure 5 Frequency plot for the fracture line angle of simple two part fracture compared two multifragmentary fractures.

The lateral wall integrity for the fractures was classified according to the AO and Jensen classification. There was a tendency of more distal intersection of the trochanter as the fracture becomes more unstable (Table 2).

The sizes of medial and lateral fragments have major implications for load sharing. The area of the lateral fragment on the AP radiograph had a mean of 15.1 cm² (SD 7.8 cm²) with a range from 3.6 cm² to 35.3 cm². The medial fragment had a mean area size of 7.4 cm² (SD 5.2 cm²) with a range from 1.3 cm² to 29.6 cm². The lateral fragment had a larger mean area size than the medial fragment ($p<0.05$).

The intrusion distances along the fracture line showed a mean of 70% intrusion of the lateral fragment. The medial fragment extended at most 60% into the fracture complex and 62% of the fractures with a lesser trochanter fragment extended to 25% percent of the fracture line (Figure 7).

DISCUSSION

It remains unclear what implant should be used for the different subtypes of trochanteric fractures. Most surgeons agree that simple two- part fractures (AO-A1) should be treated with a SHS. Reverse obliquity fractures (AO-A3) should be considered as biomechanically unstable. Their tendency for medial displacement caused by the reversed oblique course of the fracture line results in fixation failure rates of up to 56% when a conventional sliding hip screw device is used^[12,13]. This is because the lag screw does not cross the primary fracture line and controlled collapse of the fracture with the head of the femur sliding on to the metaphysis, promotes separation rather than impaction of the fracture^[13,16-18]. This group of fractures is routinely treated with an intramedullary device (IMN).

Some patterns are considered unstable such as four-part fractures and fractures with medial cortical comminution but the evidence for these assertions is absent or weak^[6,19-21]. Although, certain subtypes of trochanteric fractures have different biomechanical properties, the current classifications are rarely used for clinical purposes and prospective randomized studies comparing the SHS and IM-nail

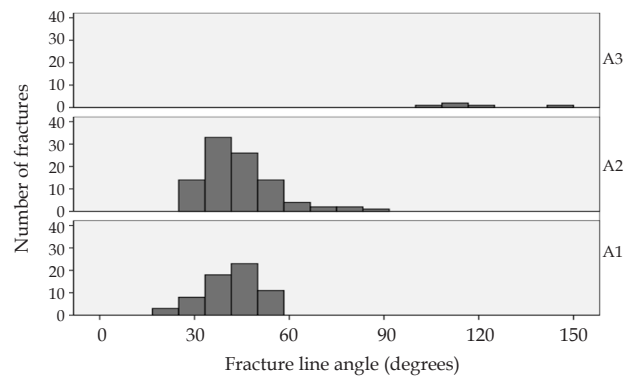


Figure 6 Frequency plot for the angle between the mid-shaft axis and the fracture line in relation to AO/ASIF classification.

Table 2 Fracture line crossing proximal, middle and distal one-third of the greater trochanter.

AO classification	Proximal 1/3 rd Number of fractures	Middle 1/3 rd Number of fractures	Distal 1/3 rd Number of fractures	Total
A1	28 (46%)	30 (42%)	0 (0%)	58
A2	33 (54%)	41 (58%)	16 (89%)	90
A3	0 (0%)	0 (0%)	2 (11%)	2
Total	61	71	18	150

Jensen classification	Proximal 1/3 rd Number of fractures	Middle 1/3 rd Number of fractures	Distal 1/3 rd Number of fractures	Total
Type 1	10 (16%)	4 (6%)	0 (0%)	14
Type 2	19 (31%)	23 (32%)	0 (0%)	42
Type 3	3 (5%)	11 (16%)	3 (17%)	17
Type 4	18 (30%)	15 (21%)	3 (17%)	36
Type 5	11 (18%)	18 (25%)	12 (67%)	41
Total	61	71	18	150

* Excluded data ($n=14$) in this table: the fracture line crossing proximal ($n=2$) of, or not crossing with the greater trochanter ($n=4$). Two of these four fractures were reversed oblique fractures. Eight fractures were excluded due to poor quality of the post-operative radiograph ($n=8$).

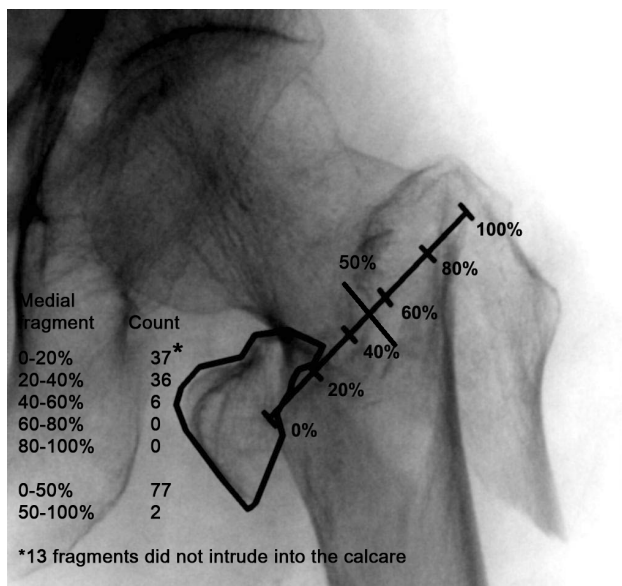


Figure 7 The intrusion of the medial fragment or fractured lesser trochanter into the fracture complex.

have failed to show differences between the implants^[12]. This lack of difference, may be because the aspects of the fracture anatomy that affect the mechanical stability have not been taken into account. Recently, Goffin *et al* (2013)^[14] using a finite element model have shown that the predicted chance of fixation failure with a SHS increases considerably when the lesser trochanter fragment intrusion distance reaches 40%. Our data shows that 53% of the patients with 3-part fractures or 4-part fractures fall into the category of an intrusion distance of 20%-60% and we recommend that future studies on proximal femoral fractures should include this variable.

Based on the known biomechanical properties of trochanteric fractures and currently used classifications, we believed there might be a role for using the angle of the fracture line and its position in grading the stability of the trochanteric fractures. In this study we provide a more detailed analysis of these fracture line characteristics.

We have demonstrated that the fracture line crosses the upper third of the greater trochanter in only 50% of two-part fractures. In these patients, it would be expected that the integrity of the lateral wall is maintained and that after fixation, collapse of the fracture would be expected to be small. These findings regarding lateral wall integrity are of interest considering the study of Gotfried *et al*^[22] concerning the key role of an intact lateral wall in the stabilization of trochanteric fractures. In addition, Gotfried *et al* have commented that fixation failure is often caused by perioperative fracturing and instability of the lateral wall^[22].

In order to improve our care for patients with trochanteric fractures, new studies, comparing or introducing new implants, should take the different subtypes of trochanteric fractures into account. A clinically relevant and reliable classification system would be of value for selecting the optimal implant and evaluating new implants. Our study has shown that it may be of value to incorporate the inclination of the fracture line into trochanteric femoral fracture classification systems.

The limitations of this study are firstly, that the used radiographs were not standardized. This was pragmatic and these would be the standard images available to the treating orthopedic surgeon. CT scanning would enable further definition of the fracture anatomy, but these are not routinely available.

Despite above mentioned limitations, we conclude that this study provides information on the fracture line properties of trochanteric fractures and shows a wide variation in the inclination of the fracture line even within current subtypes and a lack of categorization of lateral wall integrity with current classification systems.

No benefits in any form have been received or will be received from a commercial party related directly or indirectly to the subject of this article. No funds were received in support of this study. Author's contributions: DvE first author, prepared manuscript, carried out analysis. MSG prepared manuscript, assisted in analysis. LAB carried out the analysis. AHRWS senior researcher, designed study, prepared manuscript. All authors signed a ICMJE form.

CONFLICT OF INTERESTS

There are no conflicts of interest with regard to the present study.

REFERENCES

- Bannister GC, Gibson AG, Ackroyd CE *et al.* The fixation and prognosis of trochanteric fractures. A randomized prospective controlled trial. *Clin Orthop Relat Res* 1990; 242-246
- Leung KS, So WS, Shen WY *et al.* Gamma nails and dynamic hip screws for peritrochanteric fractures. A randomised prospective study in elderly patients. *J Bone Joint Surg Br* 1992; **74**: 345-351.
- Michaelsson K, Weiderpass E, Farahmand BY *et al.* Differences in risk factor patterns between cervical and trochanteric hip fractures. Swedish Hip Fracture Study Group. *Osteoporos Int* 1999; **10**: 487-494
- Morris AH, Zuckerman JD. National Consensus Conference on Improving the Continuum of Care for Patients with Hip Fracture. *J Bone Joint Surg Am* 2002; **84-A**: 670-674
- Topliss CJ, Jackson M, Atkins RM. Anatomy of pilon fractures of the distal tibia. *J Bone Joint Surg Br* 2005; **87**: 692-697.
- Evans EM. The treatment of trochanteric fractures of the femur. *J Bone Joint Surg Br* 1949; **31B**: 190-203
- Muller ME, Nazarian S, Koch P *et al.* The comprehensive classification of fractures of the long bones. Berlin: Springer, 1990
- Jin WJ, Dai LY, Cui YM *et al.* Reliability of classification systems for intertrochanteric fractures of the proximal femur in experienced orthopaedic surgeons. *Injury* 2005; **36**: 858-861
- Pervez H, Parker MJ, Pryor GA *et al.* Classification of trochanteric fracture of the proximal femur: a study of the reliability of current systems. *Injury* 2002; **33**: 713-715
- Schipper IB, Steyerberg EW, Castelein RM *et al.* Reliability of the AO/ASIF classification for peritrochanteric femoral fractures. *Acta Orthop Scand* 2001; **72**: 36-41
- Embden van D, Rhemrev SJ, Meylaerts SA *et al.* The comparison of two classifications for trochanteric femur fractures: the AO/ASIF classification and the Jensen classification. *Injury* 2010 Apr; **41(4)**: 377-81
- Parker MJ, Bowers TR, Pryor GA. Sliding hip screw versus the Targon PF nail in the treatment of trochanteric fractures of the hip: a randomised trial of 600 fractures. *J Bone Joint Surg Br* 2012 Mar; **94(3)**: 391-7
- Haidukewych GJ, Israel TA, Berry DJ. Reverse obliquity fractures of the intertrochanteric region of the femur. *J Bone Joint Surg Am* 2001; **83-A**: 643-650
- Goffin JM, Pankaj P, Simpson AH. A computational study on the effect of fracture intrusion distance in three- and four-part trochanteric fractures treated with Gamma nail and sliding hip screw. *J Orthop Res* 2014 Jan; **32(1)**: 39-45

- 15 Chen SK, Hollender L. Digitizing of radiographs with a flatbed scanner. *J Dent* 1995; **23**: 205-208
- 16 Simpson AH, Varty K, Dodd CA. Sliding hip screws: modes of failure. *Injury* 1989; **20**: 227-231
- 17 Bendo JA, Weiner LS, Strauss E et al. Collapse of intertrochanteric hip fractures fixed with sliding screws. *Orthop Rev* 1994; **Suppl**: 30-37
- 18 Gundle R, Gargan MF, Simpson AH. How to minimize failures of fixation of unstable intertrochanteric fractures. *Injury* 1995; **26**: 611-614
- 19 Dimon JH, Hughston JC. Unstable intertrochanteric fractures of the hip. *J Bone Joint Surg Am* 1967; **49**: 440-450
- 20 Gotfried Y. Percutaneous compression plating of intertrochanteric hip fractures. *J Orthop Trauma* 2000; **14**: 490-495
- 21 Sarmiento A, Williams EM. The unstable intertrochanteric fracture: treatment with a valgus osteotomy and I-beam nail-plate. A preliminary report of one hundred cases. *J Bone Joint Surg Am* 1970; **52**: 1309-1318
- 22 Gotfried Y. The lateral trochanteric wall: a key element in the reconstruction of unstable pertrochanteric hip fractures. *Clin Orthop Relat Res* 2004; 82-86

Peer reviewers: Bakir Kadum, Orthopedic Department, Sundsvall hospital, 856 43 Sundsvall, Sweden; Ahmadreza Mirbolook, Orthopedic Research Center, Guilan University of Medical Sciences, Rasht, IRAN.