

## Severe Ulnar Nuyropathy in Guyon'S Canal Caused By a Distal Tendon Sheath Ganglion Cyst

IK Konstantinidis, TA Pagonis, AG Christodoulou, PK Givissis

IK Konstantinidis, AG Christodoulou, PK Givissis, 1st Orthopaedic Department of Aristotle University of Thessaloniki, "G. Papanikolaou" Hospital of Thessaloniki, Hellas, Hellenic Republic, Greece  
TA Pagonis, Trauma and Orthopaedic Department, The Ipswich Hospital, 106 Foundry Lane, IP4 1DJ, Ipswich, Suffolk, the United Kingdom

Correspondence to: Ioannis Konstantinidis, 1st Orthopaedic Department, Hospital "G.Papanikolaou", Exohi, 57010, Thessaloniki, Greece.

Email: jokons4@yahoo.com

Telephone: +30-2313307681

Fax: +30-2310358292

Received: September 28, 2014

Revised: December 2, 2014

Accepted: December 8, 2014

Published online: April 23, 2015

### ABSTRACT

We present the case of a 53 years old woman with rapidly worsening ulnar neuropathy so as to accentuate the misleading complexity of the symptoms that can be attributed to the rare location of the ganglion. She first presented with upper limb symptoms due to pressure of the ulnar nerve in guyon's canal. She complained for severe pain and numbness in the palmar hand distribution of ulnar nerve and clinical examination revealed claw hand and positive Froment sign. A feeling of causalgia was present for many years but the aforementioned symptoms developed suddenly in just a month. The preoperative MRI showed a multilobed ganglion. During the excision operation, we found the ganglion originating from the tendon sheath of flexor digitorum profundus of the little finger. It was compressing both the deep motor branch of the ulnar nerve and the 4th common digital nerve. One year later, the patient shows significant decline of symptoms. The ulnar tunnel neuropathy, although rare, should be diagnosed quickly because it sometimes shows rapid deterioration. To our knowledge, it is a very scarce case because of its difficulty for classification and the ganglion's distal location and origin.

© 2015 ACT. All rights reserved.

**Key words:** Ulnar Canal; Guyon; Ulnar Neuropathy; Ganglion

Konstantinidis IK, Pagonis TA, Christodoulou AG, Givissis PK. Severe Ulnar Nuyropathy in Guyon'S Canal Caused By a Distal Tendon Sheath Ganglion Cyst. *International Journal of Orthopaedics* 2015; 1(4): 262-265 Available from: URL: <http://www.ghrnet.org/index.php/ijo/article/view/1170>

### INTRODUCTION

Guyon's canal, which French urologist Jean Casimir Félix Guyon first described in 1861, contains the ulnar artery, the ulnar nerve, and its bifurcation into the superficial and the deep motor branch. The canal's borders have been thoroughly defined<sup>[1,2]</sup>, as well as the correlation between the site of compression and the symptoms experienced by the patient<sup>[2,3]</sup>. Compression of the ulnar nerve in the Guyon's canal has a varied etiology. One of the most common causes is ganglia<sup>[2,3]</sup>. The majority of those that were presented in the literature were mostly originated from the pisotriquetral joint and the pisohamate joint<sup>[4,5]</sup>. Few of them were originating from the midpalmar region<sup>[6-8]</sup> and only one was reported to originate from a tendon. Seddon in 1952 presented a case report caused by a ganglion arising from the insertion of the flexor carpalis ulnaris into the pisiform<sup>[5]</sup>. This was a ganglion originating more proximally than the guyon's canal. We present another case of ulnar neuropathy caused by a ganglion arising from the tendon sheath of the flexor digitorum profundus of the little finger, far distally from the distal end of Guyon's canal.

### CASE REPORT

A 53 year old female patient presented in our hospital's outpatient hand clinic with severe pain located in the volar and ulnar aspect of her right, dominant hand, just in the palmar cutaneous distribution of the ulnar nerve. She reported a 5 years long mild causalgia in that region that, however, did not cause any nuisance in her daily work, so she never visited a doctor before for that particular symptom. During the baseline clinical examination, the pain was associated with numbness, mild claw hand (Figure 1) of the ring and little finger,

positive Wartenberg sign (Figure 2) and atrophy of the adductor pollicis muscle with positive Froment sign. Wartenberg sign is the presence of little finger abduction caused by the unopposed ulnar insertion of the extensor digiti quinti. The VAS score (pain scale) was 8/10. All of the above symptoms had a sudden onset one month before the examination, supervening upon the aforesaid causalgia and deteriorated rapidly in a 2 weeks period. In that period the patient's grip ability had almost disappeared. Just preoperatively it was measured 4kg that was the 25% of the grip strength of the healthy, left side. The patient scored 63,9 and 100 at the DASH questionnaire respectively for her daily and occupational activities.

Her profession was associated with agriculture but her daily work was sedentary office work that included a lot of hand- and keyboard typewriting. She reported no previous hand trauma. The patient's previous medical history included only hypothyroidism.

After the baseline clinical evaluation, we proceeded with further investigation of her wrist by way of an MRI of her upper limb and neuro-physiological studies by use of electromyography (EMG). The MRI (Figures 3 and 4) showed a two-lobe ganglion, medial to abductor digiti quinti. The bigger lobe had a 7mm diameter and the mass didn't show any pathological image attenuation after administrating an intravenous contrast agent.

EMG confirmed the clinical findings of ulnar neuropathy in Guyon's canal while showing low compound muscle action potential (CMAP) in the right hand distally to the wrist and extremely low sensory nerve action potential (SNAP) of ring finger. F-response was prolonged for the ulnar nerve. However, the results weren't excessive enough to explain the intensity of clinical symptoms and the severe intrinsic muscle atrophy the patient presented with. Right median nerve conduction tests were normal.

Radiological exams showed nothing remarkable besides a positive ulnar variance (Figure 5).

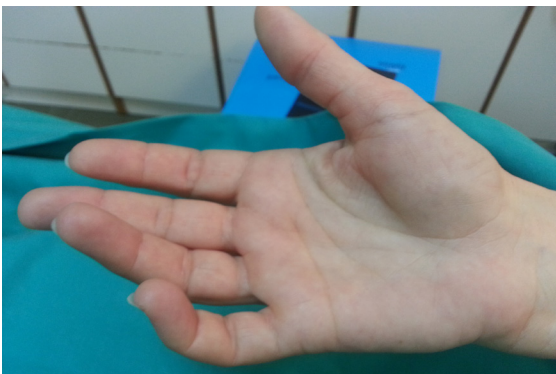

Figure 1 Patient originally presented with clawing of ring and little finger.

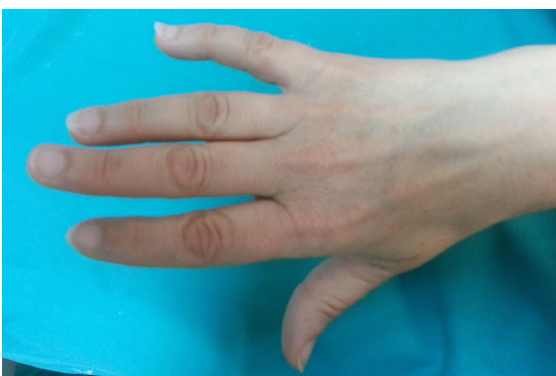

Figure 2 (+) Wartenberg sign.

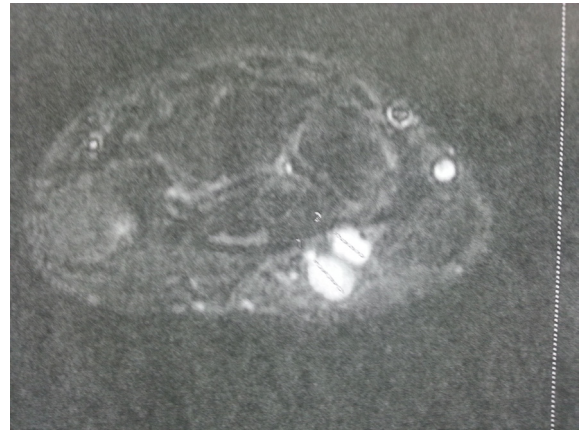


Figure 3 MRI capture (1) showing 2-lobe cystic lesion in ulnar tunnel.

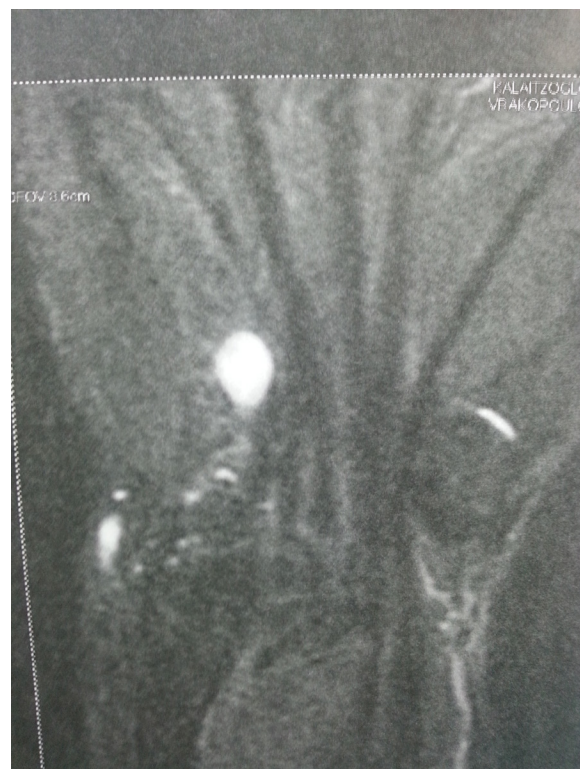

Figure 4 MRI capture (2) showing 2-lobe cystic lesion in ulnar tunnel.

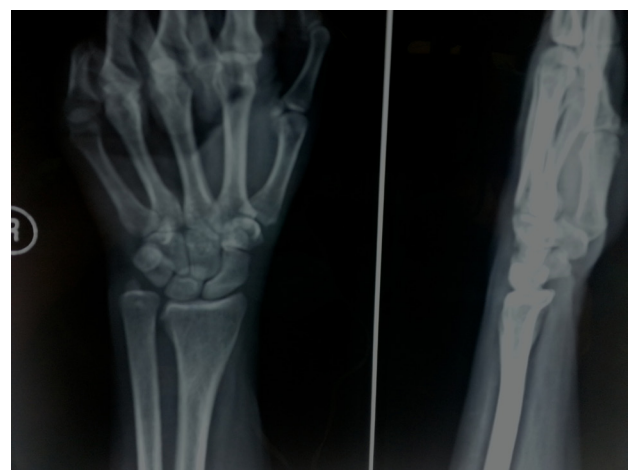

Figure 5 (+) ulnar variance.

## TREATMENT AND RESULTS

In the operating theater, we performed a typical approach for the ulnar tunnel (Figure 6). First, the main trunk of the ulnar nerve was exposed at the level of the wrist and the approach continued distally where the ganglion appeared, attached to the deep motor branch of the ulnar nerve (Figures 7, 8 and 9). The ganglion was carefully dissected from the surrounding soft tissues and then detached from the deep motor branch, leaving a lesion on its epineurium. This lesion was then repaired, under loupes magnification, with non-absorbable prolene sutures 9-0. After detaching the ganglion from its symphysis with the deep motor branch of the ulnar nerve, we identified its originating anchor to the tendon sheath of the flexor digitorum profundus of the little finger, by pulling ganglion's mass outwards (Figure 10). Its anchor was found at the level of the neck of the 5<sup>th</sup> metacarpal, just proximal to the A1 pulley. This distal origin of the ganglion was compressing the fourth common digital nerve (Figure 11). The ganglion was fully removed and sent for biopsy that confirmed the diagnosis of a ganglion.

A postoperative anatomic thermoplastic splint was applied for comfort.

On post-op follow up, the pain had immediately subsided after a week and diminished to VAS 1/10 a month postoperatively. After 6 weeks, clawing subsided and the patient started to regain a normal range of finger adduction. Nine months postoperatively, Wartenberg sign was still present and she still could not abduct her fingers fully. However, the gripping strength of her operated hand equalized the one of the healthy left hand, measuring 16kg bilaterally. The DASH score decreased to 14,8 and the DASH score for her occupational activities to 50. Improvement of both grip strength and DASH score was statistically significant ( $p < 0.05$ ).

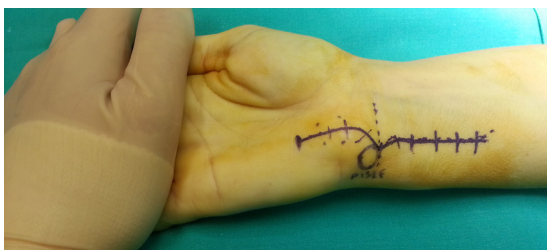


Figure 6 Preoperative planning of exposure. The pisiform is circled.

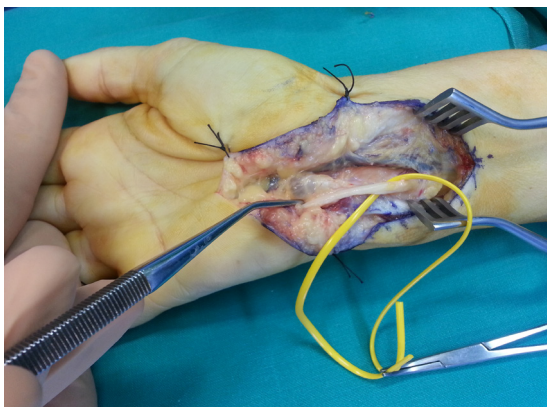


Figure 7 Dissection of ulnar nerve in the Guyon's canal. The ganglion is starting to appear, attached to the deep motor branch of the ulnar nerve.

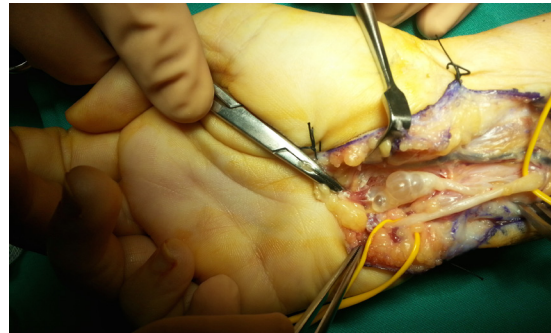


Figure 8 Dissection of the three-lobed ganglion. Yellow loops around the main ulnar nerve proximally and the superficial branch distally.

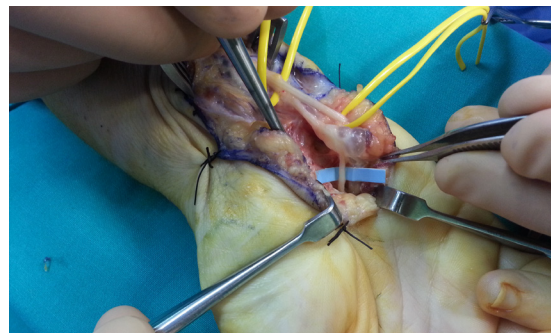


Figure 9 Continuation of dissection of the three-lobed ganglion. Yellow loops around the main ulnar nerve proximally and the superficial branch distally.

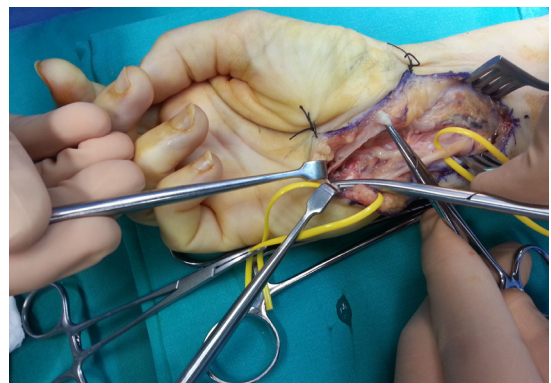


Figure 10 Pulling the ganglion we stretch its origin from the tendon sheath of the FDP of the little finger.

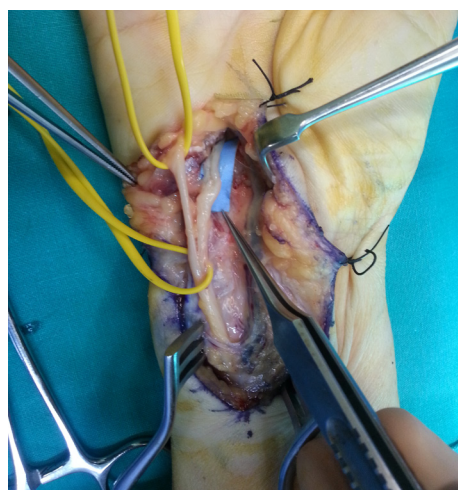


Figure 11 The condition of ulnar nerve after ganglion's removal.

## DISCUSSION

Ganglia of the ulnar tunnel (Guyon's canal) are the commonest cause of ulnar neuropathy at that site<sup>[9]</sup>. Symptoms are associated with the anatomical site and the part of the ulnar nerve that is compressed. Shea and McClain divided ulnar tunnel neuropathy in three grades, where type I is presenting with both sensory and motor symptoms, type II with motor pathology only and type III with sensory deficit<sup>[3]</sup>. Gross and Gelberman then associated these syndromes with 3 anatomical zones in Guyon's canal<sup>[2]</sup>. The three ulnar neuropathy syndromes, that Shea and McClain described, are presented depending on the location of the compression site.

Another, refined classification based on the classification by Gross and Gelberman is a subclassification of zone 2 neuropathies. According to this, there is zone 2-A, proximal to the innervation of the hypothenar muscles, zone 2-B that is distal to the innervation of hypothenar muscles and inside the ulnar tunnel and zone 2-C. In the latter the compression of the deep motor branch occurs distal to the innervation of the hypothenar muscles but also distal to the Guyon's canal<sup>[7]</sup>.

The majority of ganglia in Guyon's canal derive from the pisotriquetral joint<sup>[4]</sup> and the pisohamate joint<sup>[5]</sup>. The origin of a ganglion causing an ulnar neuropathy from the midpalmar region<sup>[6-8,10]</sup>, usually originating from the carpometacarpal joints, especially the third one, is much more rare. The rarest origin of a ganglion causing ulnar neuropathy at the wrist ever presented in the literature, is a tendon origin in a case presented by Brooks in 1952<sup>[11]</sup>. The case was about a 33 years old man with pain, tenderness and swelling at the anterior side of his right wrist. The palpable cystic swelling was proximal to the hypothenar eminence, in the course of the ulnar nerve. The patient presented both motor and sensory deficit in his hand, alike to the type I syndrome Shea and McClain described. At the operation, a ganglion arising from the margin of the insertion of flexor carpi ulnaris was found. The ganglion was compressing the ulnar nerve against the overlying deep fascia. Nonetheless, this ganglion was not inside the Guyon's canal.

To our knowledge, the case we are presenting is the first reported case of a ganglion in the ulnar tunnel arising from a tendon. We also consider that the ganglion's origin just proximal to the A1 pulley is the most distal origin of a ganglion in the ulnar tunnel ever presented. This ganglion originated from the flexor digitorum profundus of the little finger and migrated backwards and proximally, mainly compressing the deep motor branch of the ulnar nerve and forming an adhesion to it. The sudden deterioration of symptoms recorded in our patient could be correlated to the formation of this adhesion as the movement of the tendon is then transferred to the deep motor branch of the nerve. There are cases presented in the current literature that had sudden onset of symptoms associated to compression of the deep motor branch of the ulnar nerve by a ganglion, like the one presented by Kwak *et al.*<sup>[12]</sup>. Kwak suggests that, in such a sudden clinical setting, the clinician should consider a ganglion cyst as the most possible cause of the underlying compression.

According to the aforementioned classifications, our case cannot be clearly classified. This is because apart from the deep motor branch of the ulnar nerve that would classify the neuropathy as zone 2-C, the fourth common digital nerve was also compressed by the distal part of the ganglion and its originating base in the tendon of FDP of the little finger. The latter would classify the neuropathy as type III, according to Shea and McClain. It is obvious that these two types of ulnar neuropathy when occur simultaneously can mislead

the diagnosis that the responsible cause of the neuropathy lies in zone I, before the bifurcation of ulnar nerve.

## CONCLUSION

Hand surgeons should be always alert for early signs of ulnar neuropathy in Guyon's canal. In case of rapid aggravation of early symptoms, suspicion should be raised that a ganglion even arising from a tendon may be responsible for this entity. Immediate operative therapy usually leads to the best prognosis with a good chance of recovery of all symptoms.

## CONFLICT OF INTERESTS

The authors declare that the study was conducted according to the ethical standards provided by the Helsinki Declaration as revised in 2008. The patient signed a written consent form, allowing the publication of his case. None of the authors received funding, grants or any other support for the research or the preparation of the manuscript. None of the authors has association or financial involvement with any organization or commercial entity having a financial interest or financial conflict with the subject matter or research presented in the manuscript.

## REFERENCES

- 1 Denman EE. The anatomy of the space of Guyon. *Hand* 1978; **10**: 69-76.
- 2 Gross MS, Gelberman RH. The anatomy of the distal ulnar tunnel. *Clin Orthop Relat Res* 1985; 238-47.
- 3 Shea JD, McClain EJ. Ulnar-nerve compression syndromes at and below the wrist. *J Bone Joint Surg Am* 1969; **51**: 1095-103.
- 4 Bowers WH, Hurst LC. An intraarticular-intraosseous carpal ganglion. *J Hand Surg Am* 1979; **4**: 375-7.
- 5 Seddon HJ. Carpal ganglion as a cause of paralysis of the deep branch of the ulnar nerve. *J Bone Joint Surg Br* 1952; **34-B**: 386-90.
- 6 Duggal A, Anastakis DJ, Salonen D, Becker E. Compression of the deep palmar branch of the ulnar nerve by a ganglion : a case report. *Hand (N Y)* 2006; **1**: 98-101.
- 7 Feldman MD, Rotman MB, Manske PR. Compression of the deep motor branch of the ulnar nerve by a midpalmar ganglion. *Orthopedics* 1995; **18**: 65-7.
- 8 Kobayashi N, Koshino T, Nakazawa A, Saito T. Neuropathy of motor branch of median or ulnar nerve induced by midpalm ganglion. *J Hand Surg Am* 2001; **26**: 474-7.
- 9 Kuschner SH, Gelberman RH, Jennings C. Ulnar nerve compression at the wrist. *J Hand Surg Am* 1988; **13**: 577-80.
- 10 Osei DA, Williams AA, Weiland AJ. Concomitant compressive neuropathy of the ulnar and median nerves in the hand by midpalmar ganglion. *Hand (N Y)* 2012; **7**: 317-9.
- 11 Brooks DM. Nerve compression by simple ganglia. *J Bone Joint Surg Br* 1952; **34-B**: 391-400.
- 12 Kwak KW, Kim MS, Chang CH, Kim SH. Ulnar Nerve Compression in Guyon's Canal by Ganglion Cyst. *J Korean Neurosurg Soc* 2011; **49**: 139-41

**Peer reviewers:** Amanda Esquivel, Ph.D, Wayne State University, Division of Kinesiology, Health and Sport Studies, 2339 Eugene Applebaum, Detroit, MI 48201, USA; Mei-Shu Shi, DVM, PhD, Chief Scientific Officer, PharmaLegacy Laboratories (Shanghai) Co., Ltd., Building 7, 388 Jialilue Road, Pudong, Shanghai, China.